

R

1500001 GUPTA-3ZY/M P1208924 O CHEST PA 16 03 2021 10.00 AM
RADICAL AT CHEST



UHID	PT208924	LAB No.	XRY2310900
Name	Mr. KSHITIJ GUPTA	Regn. No.	GEN2342869
Age / Sex	37 Yrs / M	Receiving Dt/Time	16-Mar-2024 10:46
		Reporting Dt/Time	16-Mar-2024 10:48 AM



XRAY

CHEST (PA)

Both lung fields are normal.

Cp angles are clear.

Hila are normal...

Heart size appears within normal limits.

Soft tissue shadows and bony thorax are normal.

IMP- NORMAL CHEST X-RAY

Advised....please correlate clinically.

***** END OF REPORT *****

DR. K. K. SINHA
 M.B.B.S., D.M.R.D.
 SENIOR CONSULTANT
 Reg. No. 25437 (DMC)

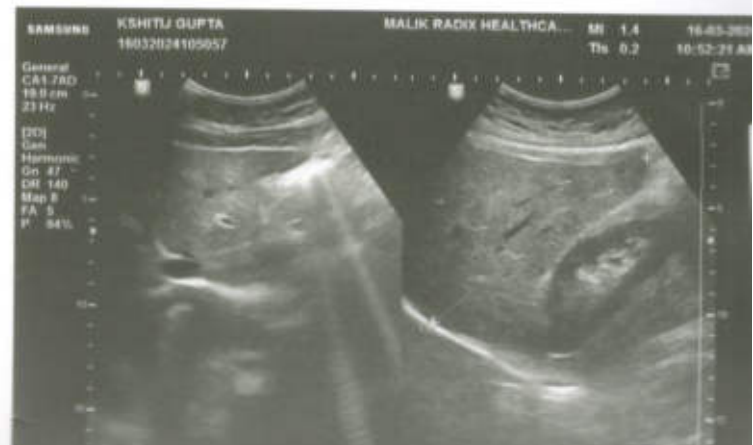
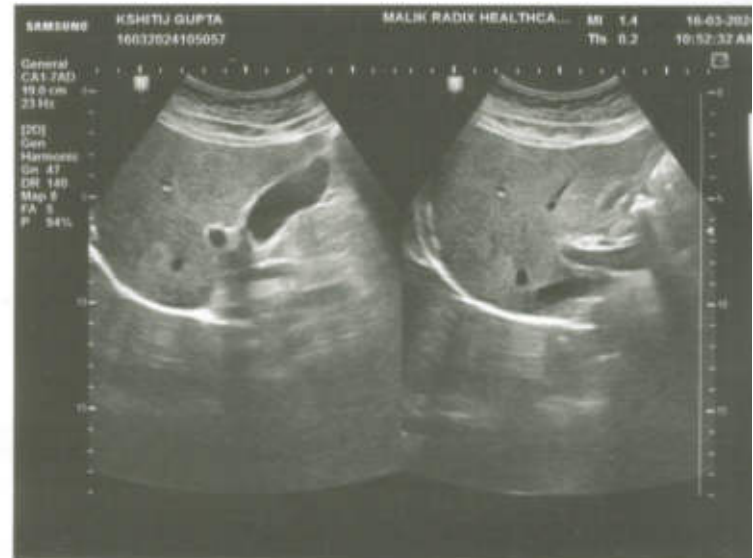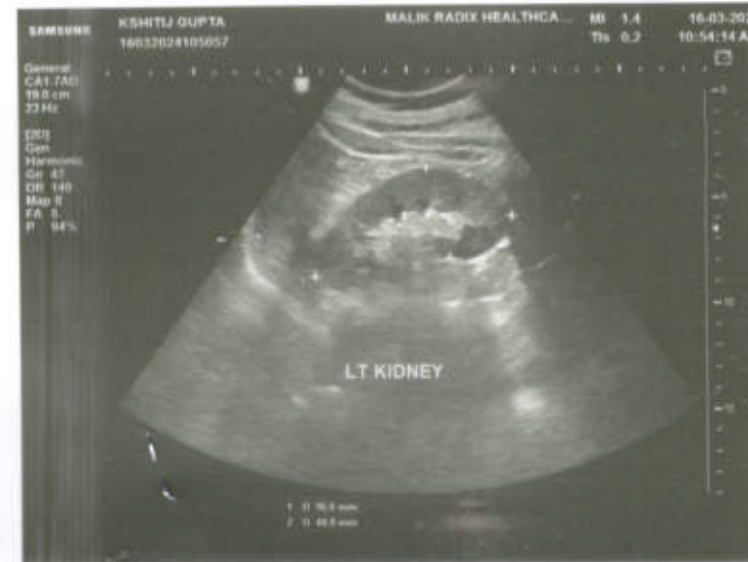
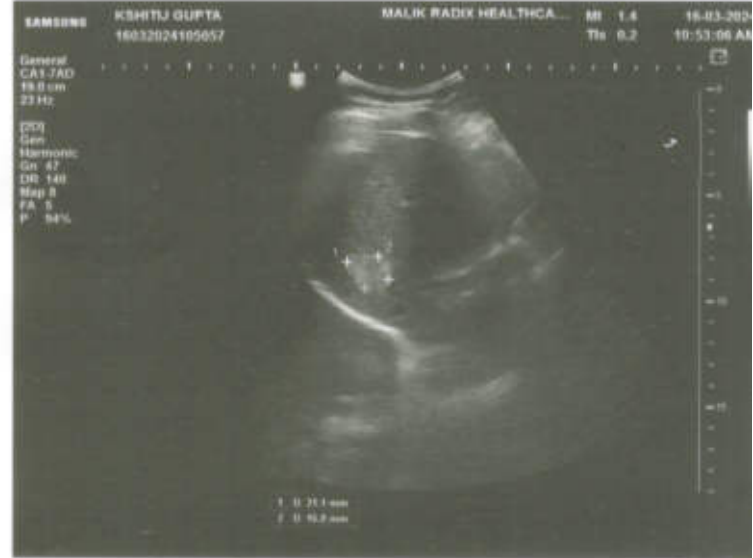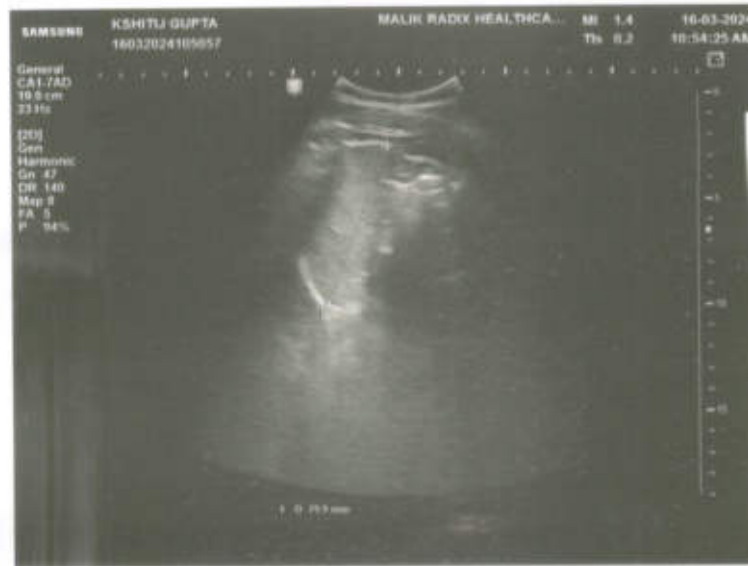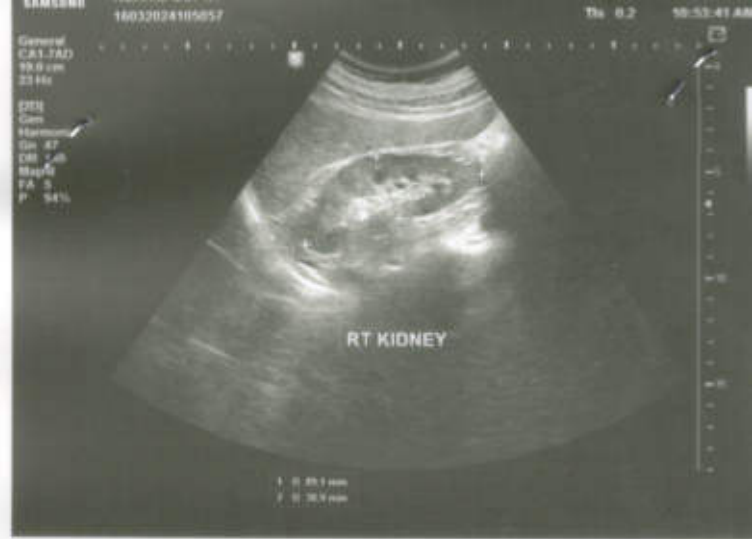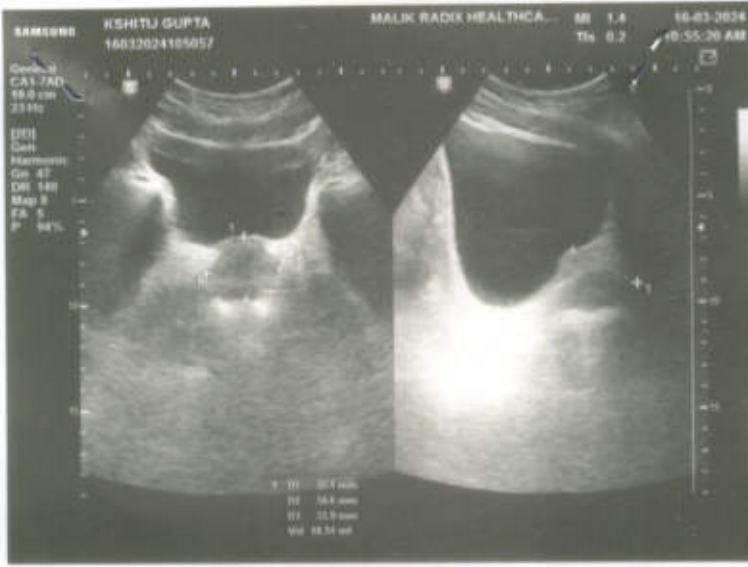
DR. RAJESH MALHOTRA
 MBBS, MD (RADIOLOGY)
 CONSULTANT RADIOLOGY
 Reg.No.DMC9296

DR. T. K VOHRA
 MD (RADIODIAGNOSIS)
 SENIOR CONSULTANT
 Reg. No. 3272 (DMC)

DR. MUKESH KOSHAL
 MBBS, MD (RADIOLOGY)
 CONSULTANT RADIOLOGY
 Reg.No.DMC10407

DR. SHREYASH TIWARY
 MBBS, MD (RADIOLOGY)
 CONSULTANT RADIOLOGY
 Reg.No.DMC85802

Facilities Available





NAME	MR. KSHITIJ GUPTA	AGE	37 YRS/M
REFD. BY.	HEALTH CHECK UP	DATE	16.03.24

Ultrasound Examination of Whole Abdomen & Pelvis:

Liver: Liver appears normal in size (12.7 cm) with normal outlines and shows normal parenchymal echotexture. An ovoid echogenic lesion is seen in segment VIII measuring about 21 x 16 mm likely hemangioma. IHBR & portal radicles are normal.

Gallbladder: Gallbladder is well distended. No evidence of cholecystitis or cholelithiasis seen. Common bile duct is normal in course & caliber.

Pancreas: Pancreas shows normal size, outlines & echotexture. No focal lesion is seen. MPD is not dilated.

Spleen: Spleen shows normal size (7.9 cm), outline & echotexture.

Kidneys: Kidneys show normal size, shape, position & echotexture. No calculus/ hydronephrosis or SOL is seen in kidneys. Cortico- medullary differentiation and cortical thickness is normal on both sides.

Right kidney measures -8.9 X 3.0 cm

Left kidney measures -9.6 X 4.4 cm

Great abdominal vessels are normal.

No ascites seen.

No para-aortic lymph nodes seen.

Urinary bladder Urinary bladder is well distended. Walls and lumen appear normal.

Prostate is normal in size (18.5 cc) with normal outline and echotexture. No focal lesion is seen.

IMPRESSION: Hepatic hemangioma as described.

Dr Shreyash Tiwary MD (Rad- diag)

Regn. No. DMC 85802

RADIOLOGIST :

Facilities Available



MALIK RADIX HEALTH CARE PVT. LTD.
C-217, C-218, Nirman Vihar,
Delhi-110092
Ph.: 011-49287456, 011-61381379
Regd. No. 607

11/12/21
Kshitiij



RADIX COSMO DENTAL

(UNIT OF MALIK RADIX HEALTHCARE PVT. LTD.)
C-216, 217, 218, Nirman Vihar, Vikas Marg, Delhi - 110092
Ph. : 011-22508272, 22520249 • M. : 9999254639
E-mail : radixhealthcare@yahoo.co.in • www.radixhealthcare.org



CONSULTANTS ON PANEL

PAEDIATRICS

Dr. Ravi Malik (MBBS, MD)
Dr. Harit Prasad (MBBS, MD, Pdi)
Dr. Ritu Jain (MBBS, MD)

GYNAECOLOGY

Dr. Renu Malik (MBBS, MD)
Dr. Meena Malhotra (MBBS, MD)
Dr. Rajni (MBBS, MD)
Dr. Manju Gupta (MBBS, MS)
Dr. Vaishali Saini (MBBS, DGO)
Dr. Rupam Arora (MBBS, MD)

DENTAL

Dr. Shruti Malik (BDS, MDS)
Dr. Annu Saini (BDS, MDS)
Dr. Ruchi Thakral (BDS, MDS)
Dr. Mohit Mangla (BDS, MDS)
Dr. Tarun Mittal (BDS, MDS)
Dr. Geetika Sharma (BDS)
Dr. Shilpa Verma (BDS)

CHILD GASTROENTEROLOGY

Dr. S. K. Mittal (MBBS, MD)

MEDICINE

Dr. A. S. Talwar (MBBS, MD)
Dr. Sunny Lippal (MBBS, MD)
Dr. Surendra Rajpal (MBBS, MD)

RESPIRATORY MEDICINE/PULMONOLOGY

Dr. Abhinav Bhanot (MBBS, DNB)

LAPAROSCOPY SURGERY

Dr. Ajay Jain (MBBS, MS)
Dr. Deepak Saran (MBBS, MS)
Dr. Pradeep Saini (MBBS, MS)
Dr. G. S. Garg (MBBS, MS)

ORTHOPAEDICS

Dr. Vikas Bhardwaj (MBBS, MS ORTHO, DNB)
Dr. Prabhakar Aggarwal (MBBS, MS ORTHO)
Dr. KB Tawari (MBBS, MS ORTHO)
Dr. Deepak Kumar Arora (MBBS, MS ORTHO)

EYE/OPTHALMOLOGY

Dr. Nidhi Gupta (MBBS, MS, DNB, PGDM)
Dr. Himanshu Singh Pundir (MBBS, MS)

ENT

Dr. Sharad Kumar Singh (MBBS, MS)
Dr. Prateek Sharma (MBBS, MS)
Dr. Ashok Singh (MBBS, MS)
Dr. A. K. Lohia (MBBS, MS)

RADIOLOGY (ULTRASOUND)

Dr. K. K. Sinha (MBBS, DMRB)
Dr. T. K. Vohra (MBBS, MD)
Dr. Rajesh Malhotra (MBBS, MD)
Dr. Ashish Tomar (MBBS, MD)

PATHOLOGY

Dr. Reema Dahiya (MBBS, MD PATH)
Dr. Meenu Aggarwal (MBBS, MD PATH)

ANAESTHESIA

Dr. Rajesh Dhall (MBBS, MD)
Dr. Rakshit Atrey (MBBS, MD)
Dr. R. K. Arora (MBBS, MD)
Dr. Swaraj Garg (MBBS, MD)

DERMATOLOGY

Dr. Niharika Jha (MBBS, MD)

PLASTIC & COSMETIC SURGERY

Dr. Avush Jain (MBBS, MS, MCh)

PAEDIATRIC SURGERY

Dr. Dharmendra Singh (MBBS, MS, M.Ch)
Dr. Satish Aggarwal (MBBS, MS, M.Ch)

PAEDIATRIC NEPHROLOGY

Dr. A. S. Vasudev (MD, Dip.in. Paed.)

NEPHROLOGY

Dr. Javed (MBBS, MD, Nephrol)

CARDIOLOGY

Dr. Nishant Tyagi (MBBS, MD)

NEUROLOGY

Dr. Amit Batra (MBBS, MD)

GASTROENTEROLOGY

Dr. Deepak Lahoti (MBBS, MD)
Dr. Nareesh Aggarwal (MBBS, MD)
Dr. Ashok Goyal (MBBS, MD)
Dr. Ankur Singhal (MBBS, MD)

UROLOGY

Dr. Nikhil Sharma (MBBS, MCh)
Dr. Ankur Singhal (MBBS, MD)

PSYCHIATRY

Dr. Mohit Sharma (MBBS, MD)

PHYSIOTHERAPY

Dr. Kirti Dwivedi
Dr. Ravi Kumar

NUTRITIONIST

Dr. Deepika Kohli
Dr. Sakshi Rana

CLINICAL PSYCHOLOGIST

Dr. Sarika Singh

Dr. Shruti Malik

BDS, MDS (Endodontics)
☎ +91-9899561092

Timings : 10:00 am. to 2:00 pm.
6:00 pm. to 8:30 pm.

CLINICAL EXAMINATION:-

1. TMJ:-

Routine dental check up

2. DENTAL STATUS:

M/H - Nothing relevant reported

- a. Caries Teeth :
- b. Fracture Teeth :
- c. Root Stumps :
- d. Gingivitis :
- e. Periodontitis :
- f. Impacted Teeth :
- g. Malaligned Teeth :

0/2

Stains +
Calculus +

3. ORAL LESIONS:-

None

Oral Prophylaxis

4. DIAGNOSIS:-

Periodontal mouthwash

5. TREATMENT PLANNING:

BD
3 months

6. FOLLOW UP:-

Referral To Other Consultant: Yes/ No

If Yes, please mention the Name:

Doctor's Signature

Anny

Facilities Available :

- * MULTI-SPECIALITY HOSPITAL * MODULAR FULLY EQUIPPED OT * NURSERY * LAPROSCOPIC SURGERY
- * 24X7 EMERGENCY * OPG * DENTAL * 24X7 DIAGNOSTICS * LABOUR ROOM * ECHO * EEG * DIGITAL X-RAY * CT SCAN
- * ECG * ULTRASOUND * RICU/ICU * ALL SPECIALITY OPD * PLASTIC & COSMETIC SURGERY * DIALYSIS * PHARMACY



Name - Mr. Kshitij⁰⁰ Gupta
Age - 37yrs/M

16/03/24

(Pre-insurance)

Routine Checkup

Wt 6/6 ~~2/2~~
8/6 ~~2/2~~

Temp 15
16

Color vision:

Mea ✓: No
No ✓

Yes

9 Myopia

Cap Berpomega

Facilities Available

Kshitiij Gupta

ID: 9654081123

37years Male

Vent. rate 81 bpm
 QRS duration 80 ms
 QT/QTc 376/436 ms
 PR interval 130 ms
 P duration 92 ms
 RR interval 740 ms
 P-R-T axes 64 83 60

12/15/2024

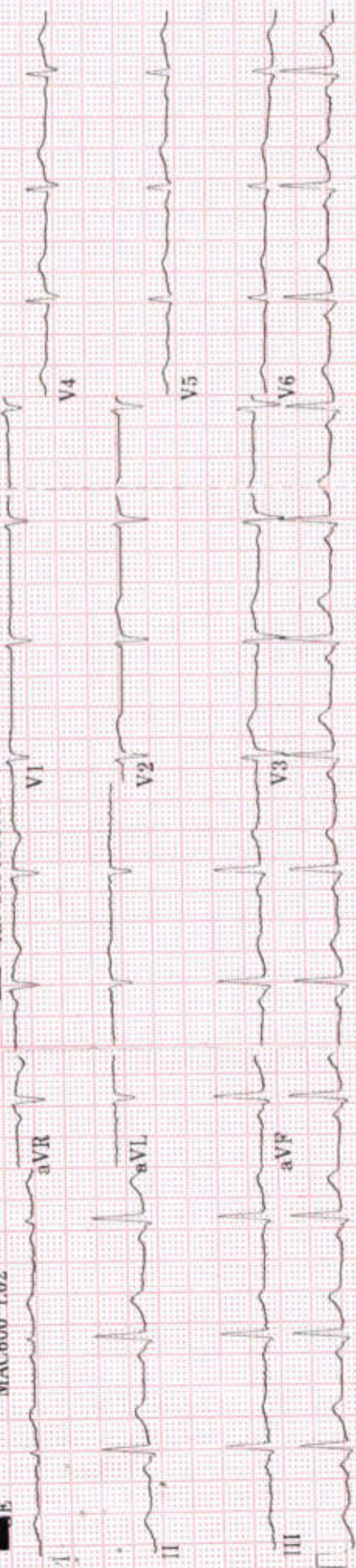
12SL™ v239

MAC600 1.02

16-Mar-2024 12:30:42

ID: 9654081123

MAC600 1.02



† by 2.5s + 1 rhythm 1d

81 bpm

50Hz

10.0||5.0 mm/mV

25.0 mm/s

Auto gain applied
0.16-20Hz

Malik Radix HealthCare.

ELECTROCARDIOGRAM

Name: MR. KSHITIJ GUPTA

Age & Sex: 37 YR/ MALE

Ref By: MEDIWHEEL

Date: 16/03/2024

ECG FINDINGS:

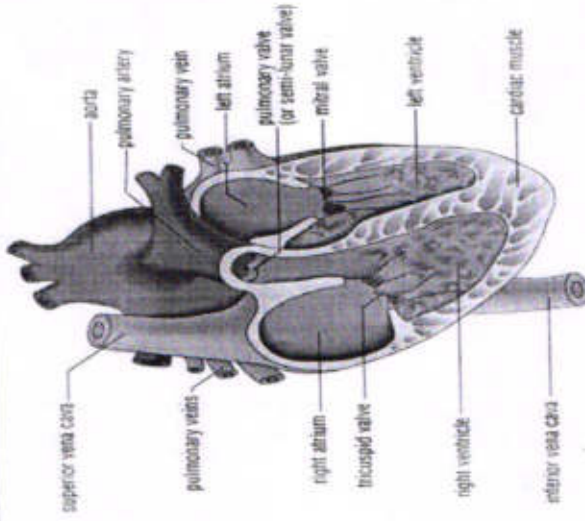
Rate 81 bpm Rhythm Sinus Mechanism Normal

Axis Normal P Wave Normal PR Interval 0.13/Sec

QRS Complex Normal QT Interval Normal Q Wave Normal

ST Segment Abnormal T Wave Abnormal

Conclusion Sinus Rhythm, Normal Axis, WNL.



Doctors Signature Dr. SHEIKH MAZIR AHMED
M.D. Physician
 PGDCC
 DMC-46499



Echocardiogram Report

Patient Name	MR. KSHITIJ GUPTA
Date of Test	16/03/2024
Age	37 YRS/ MALE
Ref. by	MEDIWHEEL

Dimensions	Result	Normal Range
AO (ed)	2.7 cm	(2.1 -3.7cm)
LA (es)	2.9 cm	(2.1 -3.7cm)
RVID (ed)	1.7 cm	(1.1-3.0cm)
LVID (ed)	4.5 cm	(3.6 – 5.5 cm)
LVID (es)	3.1 cm	(2.3-3.9cm)
IVS (ed)	1.1 cm	(0.6 – 1-2 cm)
LVPW (ed)	1.1 cm	(0.6 – 1-2 cm)
EF	60 %	
FS	30 %	(28 % - 42 %)

Impression:

- NO REGIONAL WALL MOTION ABNORMALITY SEEN.
- LVEF= 60 %
- NORMAL CHAMBER DIMENSIONS.
- NORMAL MIP.
- NORMAL COLOR FLOW.
- NO INTRA CARDIAC CLOT/MASS/ VEGETATION/PERICARDIAL EFFUSION SEEN.

Dr. Sheikh Nazir Ahmed
M.D. "Physician" PGDCC
(Consultant Non – Invasive Cardiologist)

Facilities Available

- Multispeciality Hospital - 24 Hours Emergency - X-Ray/ ECG/ Ultrasound/ CT Scan - Dental- Fully Equipped Operation Theatre
- Fully Functional Lab - 24/7 Casualty/ ICU-Nursery 24/7 Pharmacy - Labour Room - All Speciality OPD - Laproscopic Surgery -
ECHO - Plastic Surgery



LAB REPORT

Reg. Date	16/03/2024	Patient Id	2403160005	DOB.	
Name	MR. KSHITIJ GUPTA	Gender	M	Perm. ID	
Age	37 Yrs.	Panel	MEDIWHEEL	Reported	16/03/2024 17:22:21
Ref. By	MEDIWHEEL				

Test Name	Result	Units	Ref. Range
-----------	--------	-------	------------

MEDIWHEEL ANNUAL PLUS

HAEMATOLOGY

COMPLETE HAEMOGRAM

HAEMOGLOBIN (HB%)	13.1	gm/dl	13 - 18
-------------------	------	-------	---------

TOTAL LEUCOCYTE COUNT (TLC)	5,800	/cumm	4000 - 11000
-----------------------------	-------	-------	--------------

DIFFERENTIAL LEUCOCYTE COUNT (DLC)

NEUTROPHIL	48	%	40 - 80
------------	----	---	---------

LYMPHOCYTE	46	%	28 - 55
------------	----	---	---------

MONOCYTE	04	%	02 - 10
----------	----	---	---------

EOSINOPHIL	02	%	01 - 06
------------	----	---	---------

BASOPHIL	00	%	0 - 0
----------	----	---	-------

ESR (WESTEGREN'S METHOD)	10	mm/1st hr.	0 - 10
--------------------------	----	------------	--------

R B C COUNT	4.61	Millions/cmm	4.247 - 5.4
-------------	------	--------------	-------------

P.C.V / HAEMATOCRIT	41.1	%	40 - 54
---------------------	------	---	---------

M C V	89.2	fl.	80 - 100
-------	------	-----	----------

M C H	28.4	Picogram	27.0 - 31.0
-------	------	----------	-------------

M C H C	31.9	gm/dl	33 - 37
---------	------	-------	---------

PLATELET COUNT	2.55	Lakh/cu mm	1.50 - 4.50
----------------	------	------------	-------------

BLOOD GROUP ABO	" AB "		
-----------------	--------	--	--

RH TYPING	Positive		
-----------	----------	--	--

BLOOD SUGAR FASTING	90.43	mg/dl	70 - 100
---------------------	-------	-------	----------

BLOOD SUGAR PP	95.1	mg/dl	90 - 140
----------------	------	-------	----------

THYROID PROFILE

Free T3 ELISA	1.91	ng/ml	02 - 04
------------------	------	-------	---------

Free T4 ELISA	1.15	ug/dl	0.8 - 2.7
------------------	------	-------	-----------

Checked by : _____
Page 1 Contd...2

If test results are alarming or unexpected, patient is advised to contact the laboratory immediately for possible remedial action.

Facilities Available

- Multispeciality Hospital - 24 Hours Emergency - X-Ray/ ECG/ Ultrasound/ CT Scan - Dental- Fully Equipped Operation Theatre
- Fully Functional Lab - 24/7 Casualty/ ICU-Nursery 24/7 Pharmacy - Labour Room - All Speciality OPD - Laproscopic Surgery -
ECHO - Plastic Surgery



LAB REPORT

Reg. Date	16/03/2024	Patient Id	2403160005	DOB.	
Name	MR. KSHITIJ GUPTA	Gender	M	Perm. ID	
Age	37 Yrs.	Panel	MEDIWHEEL	Reported	16/03/2024 17:22:21
Ref. By	MEDIWHEEL				

Test Name	Result	Units	Ref. Range
TSH Serum/ELFA	1.850	uIU/ml	0.25 - 5.50 uIU/ml

Interpretation

Clinical Use

- Diagnose Hypothyroidism and Hyperthyroidism
- Monitor T4 replacement or T4 suppressive Therapy
- Quantify TSH levels in the subnormal range

Increased Levels : Primary Hypothyroidism Subclinical Hypothyroidism. TSH dependent. Thyroid Hormone Resistance.

Decreased Levels : Grave's Disease, Autonomous Thyroid Hormone Secretion. TSH Deficiency

LIPID PROFILE

TOTAL CHOLESTEROL	166.80	mg/dL	130.0 - 200.0 (< 200)
TRIGLYCERIDES	88.00	mg/dL	80.5 - 150.0 (< 150)
H D L CHOLESTEROL DIRECT	60.1	mg/dL	35.0 - 60.0 (< 40- 59)
V L D L	17.6	mg/dL	4.0 - 30. (23-45)
L D L CHOLESTEROL	89.1	mg/dL	50.0 - 150.0 (50-150)
TOTAL CHOLESTEROL / HDL RATIO	2.8		3.3 - 5.1
LDL / HDL CHOLESTEROL RATIO	1.5		1.5 - 3.5
<u>LIVER FUNCTION TEST (LFT)</u>			
BILIRUBIN TOTAL	1.17	mg/dl	0.2 - 1.2

Checked by : _____
Page 2 Contd...3

If test results are alarming or unexpected, patient is advised to contact the laboratory immediately for possible remedial action.

Facilities Available

- Multispeciality Hospital - 24 Hours Emergency - X-Ray/ ECG/ Ultrasound/ CT Scan - Dental- Fully Equipped Operation Theatre
- Fully Functional Lab - 24/7 Casualty/ ICU-Nursery 24/7 Pharmacy - Labour Room - All Speciality OPD - Laproscopic Surgery - ECHO - Plastic Surgery



LAB REPORT

Reg. Date	16/03/2024	Patient Id	2403160005	DOB.	
Name	MR. KSHITIJ GUPTA	Gender	M	Perm. ID	
Age	37 Yrs.	Panel	MEDIWHEEL	Reported	16/03/2024 17:22:21
Ref. By	MEDIWHEEL				

Test Name	Result	Units	Ref. Range
CONJUGATED (D. BILIRUBIN)	0.23	mg/dl	0.00 - 0.3
UNCONJUGATED (I.D. BILIRUBIN)	0.94	mg/dl	0.2 - 0.9
SGOT / AST	18.50	IU/L	0 - 35
SGPT / ALT	18.6	IU/L	0 - 35
ALKALINE PHOSPHATASE	64.70	U/L	64 - 306
TOTAL PROTEIN	7.18	gm/dl	6.0 - 8.3
ALBUMIN	4.06	gm/dl	3.2 - 5.0
GLOBULIN	3.12	gm/dl	2.5 - 5.6
A/G RATIO	1.30		0.9 - 2.0
GAMMA GT	20.14	IU/L	0.0 - 45.0
SERUM CREATININE	1.00	mg/dl	0.7 - 1.4
SERUM URIC ACID	5.09	mg/dl	3.4 - 7.0
BLOOD UREA NITROGEN (BUN)	9.21	mg/dl	6.0 - 21.0
BUN/CREAT RATIO	9.21	mg/dl	10 - 20

Urine Routine Examination

PHYSICAL EXAMINATION

QUANTITY	30	ml.	
COLOUR	Pale Yellow		Pale Yellow
TRANSPARENCY	Clear		
SPECIFIC GRAVITY	1.025		
PH	6.0		

CHEMICAL EXAMINATION

ALBUMIN	Nil
SUGAR	Nil

MICROSCOPIC EXAMINATION

PUS CELLS	1-2	HPF
-----------	-----	-----

Checked by : _____
Page 3 Contd...4

If test results are alarming or unexpected, patient is advised to contact the laboratory immediately for possible remedial action.

Facilities Available

- Multispeciality Hospital - 24 Hours Emergency - X-Ray/ ECG/ Ultrasound/ CT Scan - Dental- Fully Equipped Operation Theatre
 - Fully Functional Lab - 24/7 Casualty/ ICU-Nursery 24/7 Pharmacy - Labour Room - All Speciality OPD - Laproscopic Surgery -
 ECHO - Plastic Surgery



LAB REPORT

Reg. Date	16/03/2024	Patient Id	2403160005	DOB.	
Name	MR. KSHITIJ GUPTA	Gender	M	Perm. ID	
Age	37 Yrs.	Panel	MEDIWHEEL	Reported	16/03/2024 17:22:21
Ref. By	MEDIWHEEL				

Test Name	Result	Units	Ref. Range
RBC'S	Nil	/HPF	
CASTS	Nil		
CRYSTALS	NIL		
EPITHELIAL CELLS	1-2	/HPF	
BACTERIA	Nil		
OTHERS	Nil		

DR. MEENU AGGARWAL
M.B.B.S, MD (Path.)

Dr. REEHA DABHYA
M.B.B.S, MD (Path.)

Checked by: _____

Page 4 of 4

If test results are alarming or unexpected, patient is advised to contact the laboratory immediately for possible remedial action.

Facilities Available

- Multispeciality Hospital - 24 Hours Emergency - X-Ray/ ECG/ Ultrasound/ CT Scan - Dental- Fully Equipped Operation Theatre
- Fully Functional Lab - 24/7 Casualty/ ICU-Nursery 24/7 Pharmacy - Labour Room - All Speciality OPD - Laproscopic Surgery - ECHO - Plastic Surgery