

Patient Name : Mrs.PONNAGANTI PADMINI	Collected : 09/Nov/2024 10:22AM
Age/Gender : 32 Y 7 M 18 D/F	Received : 09/Nov/2024 11:54AM
UHID/MR No : CKOR.0000259389	Reported : 09/Nov/2024 02:01PM
Visit ID : CKOROPV431236	Status : Final Report
Ref Doctor : Self	Sponsor Name : ARCOFEMI HEALTHCARE LIMITED
Emp/Auth/TPA ID : 22S32505	


DEPARTMENT OF HAEMATOLOGY

ARCOFEMI - MEDIWHEEL - FULL BODY HEALTH ANNUAL PLUS CHECK - FEMALE - 2D ECHO - PAN INDIA - FY2324

Test Name	Result	Unit	Bio. Ref. Interval	Method
BLOOD GROUP ABO AND RH FACTOR , WHOLE BLOOD EDTA				
BLOOD GROUP TYPE	O			Microplate Hemagglutination
Rh TYPE	Positive			Microplate Hemagglutination



Dr. Vidya Aniket Gore
M.B.B.S,M.D(Pathology)
Consultant Pathologist



Dr Priya Murthy
M.B.B.S,M.D(Pathology)
Consultant Pathologist



Patient Name : Mrs.PONNAGANTI PADMINI
 Age/Gender : 32 Y 7 M 18 D/F
 UHID/MR No : CKOR.0000259389
 Visit ID : CKOROPV431236
 Ref Doctor : Self
 Emp/Auth/TPA ID : 22S32505

Collected : 09/Nov/2024 10:22AM
 Received : 09/Nov/2024 12:12PM
 Reported : 09/Nov/2024 12:38PM
 Status : Final Report
 Sponsor Name : ARCOFEMI HEALTHCARE LIMITED

DEPARTMENT OF BIOCHEMISTRY

ARCOFEMI - MEDIWHEEL - FULL BODY HEALTH ANNUAL PLUS CHECK - FEMALE - 2D ECHO - PAN INDIA - FY2324

Test Name	Result	Unit	Bio. Ref. Interval	Method
GLUCOSE, FASTING , NAF PLASMA	98	mg/dL	70-100	HEXOKINASE


Comment:

As per American Diabetes Guidelines, 2023

Fasting Glucose Values in mg/dL	Interpretation
70-100 mg/dL	Normal
100-125 mg/dL	Prediabetes
≥126 mg/dL	Diabetes
<70 mg/dL	Hypoglycemia

Note:

- 1.The diagnosis of Diabetes requires a fasting plasma glucose of > or = 126 mg/dL and/or a random / 2 hr post glucose value of > or = 200 mg/dL on at least 2 occasions.
2. Very high glucose levels (>450 mg/dL in adults) may result in Diabetic Ketoacidosis & is considered critical.


 Dr Priya Murthy
 M.B.B.S.,M.D(Pathology)
 Consultant Pathologist



Patient Name : Mrs.PONNAGANTI PADMINI	Collected : 09/Nov/2024 10:22AM
Age/Gender : 32 Y 7 M 18 D/F	Received : 09/Nov/2024 12:38PM
UHID/MR No : CKOR.0000259389	Reported : 09/Nov/2024 03:11PM
Visit ID : CKOROPV431236	Status : Final Report
Ref Doctor : Self	Sponsor Name : ARCOFEMI HEALTHCARE LIMITED
Emp/Auth/TPA ID : 22S32505	

DEPARTMENT OF BIOCHEMISTRY


ARCOFEMI - MEDIWHEEL - FULL BODY HEALTH ANNUAL PLUS CHECK - FEMALE - 2D ECHO - PAN INDIA - FY2324

Test Name	Result	Unit	Bio. Ref. Interval	Method
LIPID PROFILE , SERUM				
TOTAL CHOLESTEROL	196	mg/dL	<200	CHO-POD
TRIGLYCERIDES	224	mg/dL	<150	GPO-POD
HDL CHOLESTEROL	46	mg/dL	40-60	Enzymatic Immunoinhibition
NON-HDL CHOLESTEROL	150	mg/dL	<130	Calculated
LDL CHOLESTEROL	105.4	mg/dL	<100	Calculated
VLDL CHOLESTEROL	44.8	mg/dL	<30	Calculated
CHOL / HDL RATIO	4.27		0-4.97	Calculated
ATHEROGENIC INDEX (AIP)	0.33		<0.11	Calculated


Comment:

Reference Interval as per National Cholesterol Education Program (NCEP) Adult Treatment Panel III Report.

	Desirable	Borderline High	High	Very High
TOTAL CHOLESTEROL	< 200	200 - 239	≥ 240	
TRIGLYCERIDES	<150	150 - 199	200 - 499	≥ 500
LDL	Optimal < 100 Near Optimal 100-129	130 - 159	160 - 189	≥ 190
HDL	≥ 60			
NON-HDL CHOLESTEROL	Optimal <130; Above Optimal 130-159	160-189	190-219	>220



Dr.Govinda Raju N L
MSc,PhD(Biochemistry)
Consultant Biochemistry



Dr Priya Murthy
M.B.B.S,M.D(Pathology)
Consultant Pathologist



SIN No:KOR241100541

This test has been performed at Apollo Health & Lifestyle Ltd, RRL BANGALORE Laboratory.

APOLLO HEALTH AND LIFESTYLE LIMITED - RRL BANGALORE
Apollo Health and Lifestyle Limited
Regd. Office: 10, 22nd, Anand Nagar, 4th Cross, 4th Stage, 4th Cross, Anand Nagar, 4th Stage, Bangalore - 560016
www.apolloclinics.com | Email ID: enquiry@apolloclinics.com, Ph.No: 080-9687 7777, Fax No: 080-9687 7766

APOLLO CLINICS NETWORK

Telangana: Hyderabad (45) | Andhra Pradesh: Vizag (1) | Karnataka: Bangalore (2) | Kerala: Kochi (1) | Maharashtra: Mumbai (1) | Odisha: Bhubaneswar (1) | Punjab: Chandigarh (1) | Rajasthan: Jaipur (1) | Tamil Nadu: Chennai (1) | Uttar Pradesh: Lucknow (1) | West Bengal: Kolkata (1) | Andhra Pradesh: Hyderabad (45) | Karnataka: Bangalore (2) | Kerala: Kochi (1) | Maharashtra: Mumbai (1) | Odisha: Bhubaneswar (1) | Punjab: Chandigarh (1) | Rajasthan: Jaipur (1) | Tamil Nadu: Chennai (1) | Uttar Pradesh: Lucknow (1) | West Bengal: Kolkata (1)

Patient Name : Mrs.PONNAGANTI PADMINI	Collected : 09/Nov/2024 10:22AM
Age/Gender : 32 Y 7 M 18 D/F	Received : 09/Nov/2024 12:38PM
UHID/MR No : CKOR.0000259389	Reported : 09/Nov/2024 03:11PM
Visit ID : CKOROPV431236	Status : Final Report
Ref Doctor : Self	Sponsor Name : ARCOFEMI HEALTHCARE LIMITED
Emp/Auth/TPA ID : 22S32505	

DEPARTMENT OF BIOCHEMISTRY

ARCOFEMI - MEDIWHEEL - FULL BODY HEALTH ANNUAL PLUS CHECK - FEMALE - 2D ECHO - PAN INDIA - FY2324

Test Name	Result	Unit	Bio. Ref. Interval	Method
LIVER FUNCTION TEST (LFT) , SERUM				
BILIRUBIN, TOTAL	0.43	mg/dL	0.3-1.2	DPD
BILIRUBIN CONJUGATED (DIRECT)	0.07	mg/dL	<0.2	DPD
BILIRUBIN (INDIRECT)	0.36	mg/dL	0.0-1.1	Dual Wavelength
ALANINE AMINOTRANSFERASE (ALT/SGPT)	17	U/L	<35	IFCC
ASPARTATE AMINOTRANSFERASE (AST/SGOT)	21.0	U/L	<35	IFCC
AST (SGOT) / ALT (SGPT) RATIO (DE RITIS)	1.2		<1.15	Calculated
ALKALINE PHOSPHATASE	94.00	U/L	30-120	IFCC
PROTEIN, TOTAL	7.44	g/dL	6.6-8.3	Biuret
ALBUMIN	4.63	g/dL	3.5-5.2	BROMO CRESOL GREEN
GLOBULIN	2.81	g/dL	2.0-3.5	Calculated
A/G RATIO	1.65		0.9-2.0	Calculated

Comment:

LFT results reflect different aspects of the health of the liver, i.e., hepatocyte integrity (AST & ALT), synthesis and secretion of bile (Bilirubin, ALP), cholestasis (ALP, GGT), protein synthesis (Albumin) Common patterns seen:

1. Hepatocellular Injury:

*AST – Elevated levels can be seen. However, it is not specific to liver and can be raised in cardiac and skeletal injuries.*ALT – Elevated levels indicate hepatocellular damage. It is considered to be most specific lab test for hepatocellular injury. Values also correlate well with increasing BMI. Disproportionate increase in AST, ALT compared with ALP. AST: ALT (ratio) – In case of hepatocellular injury AST: ALT > 1 In Alcoholic Liver Disease AST: ALT usually >2. This ratio is also seen to be increased in NAFLD, Wilson’s diseases, Cirrhosis, but the increase is usually not >2.

2. Cholestatic Pattern:*ALP – Disproportionate increase in ALP compared with AST, ALT. ALP elevation also seen in pregnancy, impacted by age and sex.*Bilirubin elevated- predominantly direct , To establish the hepatic origin correlation with elevated GGT helps.

3. Synthetic function impairment:*Albumin- Liver disease reduces albumin levels, Correlation with PT (Prothrombin Time) helps.

4. Associated tests for assessment of liver fibrosis - Fibrosis-4 and APRI Index.

Dr.Govinda Raju N L
 MSc,PhD(Biochemistry)
 Consultant Biochemistry

Dr Priya Murthy
 M.B.B.S,M.D(Pathology)
 Consultant Pathologist




SIN No:KOR241100541

Patient Name : Mrs.PONNAGANTI PADMINI	Collected : 09/Nov/2024 10:22AM
Age/Gender : 32 Y 7 M 18 D/F	Received : 09/Nov/2024 12:38PM
UHID/MR No : CKOR.0000259389	Reported : 09/Nov/2024 02:44PM
Visit ID : CKOROPV431236	Status : Final Report
Ref Doctor : Self	Sponsor Name : ARCOFEMI HEALTHCARE LIMITED
Emp/Auth/TPA ID : 22S32505	

DEPARTMENT OF BIOCHEMISTRY

ARCOFEMI - MEDIWHEEL - FULL BODY HEALTH ANNUAL PLUS CHECK - FEMALE - 2D ECHO - PAN INDIA - FY2324

Test Name	Result	Unit	Bio. Ref. Interval	Method
GAMMA GLUTAMYL TRANSPEPTIDASE (GGT) , SERUM	14.00	U/L	<38	IFCC



Dr Priya Murthy
M.B.B.S.,M.D(Pathology)
Consultant Pathologist



Patient Name : Mrs.PONNAGANTI PADMINI	Collected : 09/Nov/2024 10:22AM
Age/Gender : 32 Y 7 M 18 D/F	Received : 09/Nov/2024 12:39PM
UHID/MR No : CKOR.0000259389	Reported : 09/Nov/2024 05:21PM
Visit ID : CKOROPV431236	Status : Final Report
Ref Doctor : Self	Sponsor Name : ARCOFEMI HEALTHCARE LIMITED
Emp/Auth/TPA ID : 22S32505	

DEPARTMENT OF IMMUNOLOGY

ARCOFEMI - MEDIWHEEL - FULL BODY HEALTH ANNUAL PLUS CHECK - FEMALE - 2D ECHO - PAN INDIA - FY2324

High	High	High	High	Pituitary Adenoma; TSHoma/Thyrotropinoma
------	------	------	------	--

Govinda Raju
Dr.Govinda Raju N L
 MSc,PhD(Biochemistry)
 Consultant Biochemistry

Priya Murthy
Dr Priya Murthy
 M.B.B.S,M.D(Pathology)
 Consultant Pathologist



SIN No:KOR241100543

This test has been performed at Apollo Health & Lifestyle Ltd, RRL BANGALORE Laboratory

APOLLO HEALTH AND LIFESTYLE LIMITED - RRL BANGALORE

APOLLO Health and Lifestyle Limited - RRL BANGALORE

Regd Office: 10/22/20, Anand Nagar, 4th Cross, 4th Stage, 4th Cross, Anand Nagar, Hyderabad, Telangana - 500016

www.apolloclinic.com | Email ID: enquiry@apolloclinic.com, Ph No: 040-6664 7777, Fax No: 040-6664 7766

APOLLO CLINIC'S NETWORK

Telangana: Hyderabad (45), Rao Nagar | Chandigarh: Sector 29 | Karnataka: Bangalore (14), Bannerghatta | Kerala: Kochi | Maharashtra: Pune (1), Kharadi | Odisha: Bhubaneswar (1), Bhubaneswar | West Bengal: Kolkata (1), Beliaghata

APOLLO CLINIC'S NETWORK

APOLLO CLINIC'S NETWORK

APOLLO CLINIC'S NETWORK

APOLLO CLINIC'S NETWORK

APOLLO CLINIC'S NETWORK

Patient Name : Mrs.PONNAGANTI PADMINI	Collected : 09/Nov/2024 01:32PM
Age/Gender : 32 Y 7 M 18 D/F	Received : 09/Nov/2024 04:44PM
UHID/MR No : CKOR.0000259389	Reported : 09/Nov/2024 06:10PM
Visit ID : CKOROPV431236	Status : Final Report
Ref Doctor : Self	Sponsor Name : ARCOFEMI HEALTHCARE LIMITED
Emp/Auth/TPA ID : 22S32505	

DEPARTMENT OF CLINICAL PATHOLOGY

ARCOFEMI - MEDIWHEEL - FULL BODY HEALTH ANNUAL PLUS CHECK - FEMALE - 2D ECHO - PAN INDIA - FY2324

Test Name	Result	Unit	Bio. Ref. Interval	Method
URINE GLUCOSE(POST PRANDIAL)	NEGATIVE		NEGATIVE	GOD-POD

Dr. Rajalakshmi D
 M.B.B.S,M.D
 Consultant Pathologist


Dr. Vidya Aniket Gore
 M.B.B.S,M.D(Pathology)
 Consultant Pathologist



Patient Name	: Mrs.PONNAGANTI PADMINI	Collected	: 09/Nov/2024 01:09PM
Age/Gender	: 32 Y 7 M 18 D/F	Received	: 10/Nov/2024 02:25PM
UHID/MR No	: CKOR.0000259389	Reported	: 12/Nov/2024 05:00PM
Visit ID	: CKOROPV431236	Status	: Final Report
Ref Doctor	: Self	Sponsor Name	: ARCOFEMI HEALTHCARE LIMITED
Emp/Auth/TPA ID	: 22S32505		

TERMS AND CONDITIONS GOVERNING THIS REPORT

1. Reported results are for information and interpretation of the referring doctor or such other medical professionals, who understand reporting units, reference ranges and limitation of technologies. Laboratories not be responsible for any interpretation whatsoever.
2. It is presumed that the tests performed are, on the specimen / sample being to the patient named or identified and the verifications of particulars have been confirmed by the patient or his / her representative at the point of generation of said specimen.
3. The reported results are restricted to the given specimen only. Results may vary from lab to lab and from time to time for the same parameter for the same patient (within subject biological variation).
4. The patient details along with their results in certain cases like notifiable diseases and as per local regulatory requirements will be communicated to the assigned regulatory bodies.
5. The patient samples can be used as part of internal quality control, test verification, data analysis purposes within the testing scope of the laboratory.
6. This report is not valid for medico legal purposes. It is performed to facilitate medical diagnosis only.



Dr. Reshma Stanly
M.B.B.S, DNB(Pathology)
Consultant Pathologist



THIS REPORT HAS BEEN APPROVED BY APOLLO HEALTH AND LIFESTYLE LIMITED'S QUALITY CONTROL

SIN No:KOR241100601

Apollo Health and Lifestyle Limited, Global Reference Laboratory Hyderabad

Regd. Office: 101-102, Apollo Knowledge Centre, 10th Floor, Ring Road, Hyderabad - 500076
www.apolloh.com | Email: Doenquiry@apolloh.com, Ph: 0044-964 7777, Fax No: 964 7744

APOLLO CLINICS NETWORK

Mumbai | Hyderabad | Bangalore | Chennai | Kolkata | New Delhi | Ahmedabad | Gurgaon | Pune | Jaipur | Lucknow | Patna | Ranchi | Bhopal | Indore | Bhubaneswar | Guwahati | Thiruvananthapuram | Coimbatore | Mysore | Tiruchirappalli | Tirunelveli | Karaikal | Pondicherry | Kavaratti | Silvassa | Diu | Daman | Dadra | Chandernagore | Karaikal | Pondicherry | Kavaratti | Silvassa | Diu | Daman | Dadra | Chandernagore



Patient Name	: Mrs. Ponnaganti Padmini	Age	: 32Yrs 7Mths 19Days
UHID	: CKOR.0000259389	OP Visit No.	: CKOROPV431236
Printed On	: 09-11-2024 05:43 AM	Advised/Pres Doctor	: --
Department	: Radiology	Qualification	: --
Referred By	: Self	Registration No.	: --
Employer Id	: 22S32505		

DEPARTMENT OF RADIOLOGY

ULTRASOUND ABDOMEN AND PELVIS

Liver is normal in size and shows normal echo pattern. No biliary dilatation. No focal lesion

Portal vein is normal in size, course and caliber. CBD is not dilated.

Gall bladder is normal without evidence of calculi, wall thickening or pericholecystic fluid

Pancreas to the extent visualized, appears normal in size, contour and echogenicity

Spleen is normal in size, shape, contour and echopattern. No evidence of mass or focal lesion.

Right kidney is normal in size, position, shape and echopattern. Corticomedullary differentiation is maintained. No evidence of calculi or hydronephrosis.

Left kidney is normal in size, position, shape and echopattern. corticomedullary differentiation is maintained. No evidence of calculi or hydronephrosis.

Urinary Bladder is well distended. wall thickness is normal. No internal echoes.

Uterus: is normal in size. Endometrial echoes are normal

Endometrium: measures 2.0mm.

Right ovary is normal in size and echopattern. Left ovary is not visualized

Both adnexa: Normal, no mass seen.

There is no ascites.

IMPRESSION: NO SIGNIFICANT ABNORMALITY DETECTED

---End Of The Report---

P.J. Vinod

Dr.VINOD P JOSEPH
MBBS, DNB, DMRD
25487
Radiology

Patient Name	: Mrs. Ponnaganti Padmini	Age	: 32Yrs 7Mths 19Days
UHID	: CKOR.0000259389	OP Visit No.	: CKOROPV431236
Printed On	: 09-11-2024 06:15 AM	Advised/Pres Doctor	: --
Department	: Cardiology	Qualification	: --
Referred By	: Self	Registration No.	: --
Employer Id	: 22S32505		

DEPARTMENT OF CARDIOLOGY

Observation :-

1. Normal Sinus Rhythm.
2. Heart rate is 68 beats per minutes.
3. No pathological Q wave or ST-T changes seen.
4. Normal P,Q,R,S,T waves and axis.
5. No evidence of chamber, hypertrophy or enlargement seen.

Impression:

NORMAL RESTING ECG.

NOTE:KINDLY TAKE A PHOTOCOPY OF THE GRAPH FOR FUTURE REFERENCE IF NEEDED

---End Of The Report---



Dr.MOHAN MURALI
MBBS, DNB General Medicine, DrNB Cardiology
ANP20130001911KTK
Cardiology

Patient Name	: Mrs. Ponnaganti Padmini	Age	: 32Yrs 7Mths 22Days
UHID	: CKOR.0000259389	OP Visit No.	: CKOROPV431236
Printed On	: 12-11-2024 07:11 AM	Advised/Pres Doctor	: --
Department	: Cardiology	Qualification	: --
Referred By	: Self	Registration No.	: --
Employer Id	: 22S32505		

DEPARTMENT OF CARDIOLOGY

ECHO

---End Of The Report---



Dr.MOHAN MURALI
MBBS, DNB General Medicine, DrNB Cardiology
ANP20130001911KTK
Cardiology

Patient Name : Mrs. Ponnaganti Padmini Age : 32Yrs 7Mths 19Days
UHID : CKOR.0000259389 OP Visit No. : CKOROPV431236
Printed On : 09-11-2024 08:02 AM Advised/Pres Doctor : --
Department : Radiology Qualification : --
Referred By : Self Registration No. : --
Employer Id : 22S32505

DEPARTMENT OF RADIOLOGY

X RAY CHEST PA

Both lungs fields appear normal.

Both hilae are normal.

Both costophrenic and cardiophrenic angles are normal.

The cardiac and mediastinal shadows appear normal.

Bones and soft tissues appear normal.

IMPRESSION : NORMAL STUDY.

---End Of The Report---



Dr.VINOD P JOSEPH
MBBS, DNB, DMRD
25487
Radiology



Apollo Clinic

Consent Form

Patient Name: Padmini Ponnaganti Age: 32
UHID Number: Company Name:

I Mr/Mrs/Miss: Employee of
(Company) want to inform you that I am ~~not~~ getting the Consultation
Test which is a part of health check package.

Reason If any: I will be coming on Wednesday
And I claim the above statement in my full consciousness.

Patient Signature: [Signature] Date:



Patient Name : Mrs. P Padmini

Patient ID: 259389

Age : 32 Year(s)

Sex: Female

Referring Doctor : H/C

Date: 31.08.2024

ULTRASOUND ABDOMEN AND PELVIS

Liver is normal in size and shows normal echo pattern. No biliary dilatation. No focal lesion

Portal vein is normal in size, course and caliber. CBD is not dilated.

Gall bladder is normal without evidence of calculi, wall thickening or pericholecystic fluid

Pancreas to the extent visualized, appears normal in size, contour and echogenicity

Spleen is normal in size, shape, contour and echopattern. No evidence of mass or focal lesion.

Right kidney is normal in size, position, shape and echopattern. Corticomedullary differentiation is maintained. No evidence of calculi or hydronephrosis.

Left kidney is normal in size, position, shape and echopattern. corticomedullary differentiation is maintained. No evidence of calculi or hydronephrosis.

Urinary Bladder is well distended. wall thickness is normal. No internal echoes.

Uterus: is normal in size. Endometrial echoes are normal

Endometrium: measures 2.0mm.

Right ovary is normal in size and echopattern. Left ovary is not visualized

Both adnexa: Normal, no mass seen.

There is no ascites.

IMPRESSION: NO SIGNIFICANT ABNORMALITY DETECTED

**DR VINOD JOSEPH DNB,DMRD
RADIOLOGIST**



Dr. Vijayalakshmi



Apollo Medical Centre
Expertise. Closer to you.

DR. SHURTI CHANNIKEDIA
MBBS, MS (ENT)
KMC REG NO: J19251

09/11/24

HEALTH CHECK - ENT

NAME:

P

AGE:

EAR:

RE:

LE:

EXTERNAL EAR

MIDDLE EAR

INNER EAR (FN)

Neelmal

HEARING ASSESSMENT:

RE:

LE:

RHINNE

WEBER

ABC

Neelmal

NOSE

THROAT

AIRWAY

ORAL CAVITY

SEPTUM

OROPHARYNX

TURBINATES

PHARYNX

OTHERS

LARYNX

Neelmal

Neelmal

NECK

NECK NODES

OTHER

Neelmal

AUDIOMETRY

IMPRESSION

Neelmal

[Signature]

SIGNATURE

Apollo Health and Lifestyle Limited

(CIN - U851 10TG2000PLC046088) Regd. Office: #7-1-617/A, 615 & 616, Imperial Towers, 7th Floor; Ameerpet, Hyderabad, Telangana - 500 038 | Email ID: enquiry@apollohl.com

APOLLO CLINICS NETWORK KARNATAKA

Bangalore (Basavanagudi | Bellandur | Electronics City | HSR Layout | Indira Nagar | JP Nagar | Kundalahalli | Koramangala | Sarjapur Road) **Mysore** (Kalidasa Road)

Online appointments: www.apolloclinic.com

TO BOOK AN APPOINTMENT

1860 500 7788

OPHTHAL REPORT

NAME: Mrs. Ponnagarbi Padmini
AGE: 32... GENDER: MALE/FEMALE

RIGHT EYE

	SPH	CYL	AXIS	VA
DV	-0.75			6/6
NV				N6

LEFT EYE

	SPH	CYL	AXIS	VA
DV	-3.25			6/6
NV				N6

REMARK:

DATE: 9.11.2024

Alv
OPTOMETRIST

BRING THIS PRESCRIPTION IN YOUR NEXT VISIT

NAME: Mrs. PONNUGANTI PADMINI

AGE: 32Y

SEX: FEMALE

DATE: 09/11/2024

ECHOCARDIOGRAPHY REPORT

MEASUREMENT

AO - 25 (20 - 35) mm	LIVD d - 38 (36-52) mm	IVS - 10 (06 - 11) mm
LA - 26 (19- 40) mm	LVID s 25 (23- 39) mm	PWD - 11 (06- 11) mm
EF - 60 (>50%)	RVID - 20	

VALVES

Mitral Valve : NORMAL
Aortic Valve : NORMAL
Tricuspid Valve : Normal,
Pulmonary Valve : Normal,

CHAMBERS

Left Atrium : Normal
Right Atrium : Normal
Left Ventricle : Normal
Right Ventricle : Normal

SEPTAE

IVS : Intact
IAS : Intact



GREAT ARTERIES

Aorta : Normal
Pulmonary Artery : Normal

DOPPLER DATA

Mitral : E > A , 0.7 / 0.5
Aortic : Normal , 1.0 m/s,
Tricuspid : Normal , 0.4 / 0.6
Pulmonary : Normal, 1.10

WALL MOTION ABNORMALITIES : No RWMA

Pericardium : Normal

FINAL DIAGNOSIS

**NORMAL CHAMBERS AND DIMESNIONS
NO RWMA , NORMAL LV EF -60%
NORMAL DIASTOLIC FUNCTION
NO OBVIOUS CLOTS/ EFFUSION/ VEGETATION**


**DR. MOHAN MURALI
DNB(MED), Dr NB(CARDIOLOGY)
CONSULTANT CARDIOLOGIST**

M/C

Date : 9/11/24
MR No :
Name : *mm Radmini*
Age/Gender : 32y
Mobile no :

Department : OBSTERICS&GYNAECOLOGY
Consultant : DR JYOTHI RAJESH
REG NO;KMC-42823
Qualification :DGO,(DNB)
Consulting Timings:9.30am TO 12.00PM
phone no: 9972044580,7338064558

Height :	Weight :	BMI :	Waist Circum :
Temp :	Pulse :	Resp :	B.P :

General Examination / Allergies
History

Clinical Diagnosis & Management Plan

US pelvis @

*No gynaec complaints
mm. irreg-regular menses - 4/11
OBN. P2L2 LSC 10-2yrs
BPT done*

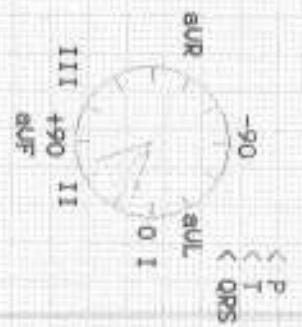*Past H- was
family H- was
O/E. P/A - soft
PV - Co 1 @ LBC taken
vagina
Plu - clear*

Follow up date:

[Signature]
Doctor Signature

Arro W

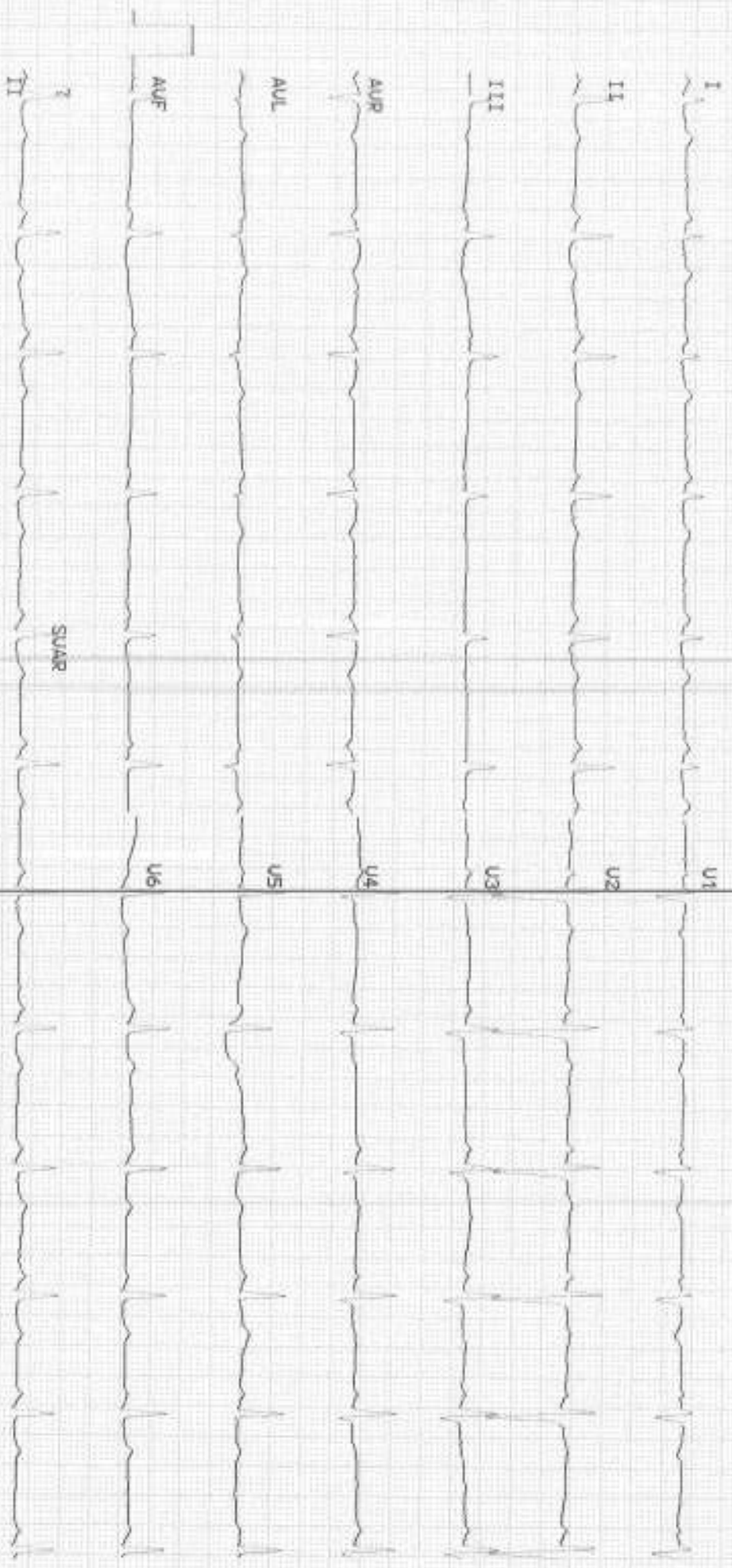
AGE: 32
 Measurement Results:
 QRS : 102 ms
 QT/QTcB : 382 / 407 ms
 PR : 136 ms
 P : 110 ms
 RP/PP : 882 / 900 ms
 P/QRS/T : 40 / 70 / 20 degrees
 QTd/QTcBd : 50 / 53 ms
 Sokolow : 1.1 mV
 NK : 10



Interpretation:

(Handwritten signature)

Unconfirmed report.





Patient Name : Mrs. Ponnaganti Padmini Age : 32Yrs 7Mths 18Days
UHID : CKOR.0000259389 OP Visit No. : CKOROPV431236
Printed On : 09-11-2024 11:45 AM Advised/Pres Doctor : ---
Department : Cardiology Qualification : ---
Referred By : Self Registration No. : ---
Employee Id : 22S32505

DEPARTMENT OF CARDIOLOGY

Observation :-

1. Normal Sinus Rhythm.
2. Heart rate is 68 beats per minutes.
3. No pathological Q wave or ST-T changes seen.
4. Normal P,Q,R,S,T waves and axis.
5. No evidence of chamber, hypertrophy or enlargement seen.

Impression:

NORMAL RESTING ECG.

NOTE:KINDLY TAKE A PHOTOCOPY OF THE GRAPH FOR FUTURE REFERENCE IF NEEDED

---End Of The Report---

Dr.MOHAN MURALI
MBBS, DNB General Medicine, DrNB Cardiology
ANP20130001911KTK
Cardiology

Apollo Health and Lifestyle Limited

(CIN - U65110TG2000PLC046089) Regd. Office: #7-1-617/A, 618 & 616, Imperial Towers, 7th Floor | Ambarpet, Hyderabad, Telangana - 500 098 | Email ID: enquiry@apollohi.com

APOLLO CLINICS NETWORK KARNATAKA

Bangalore (Basavanagudi) | Bellandur | Electronics City | HSR Layout | Indira Nagar | JP Nagar | Kundalahalli | Koramangala | Sarjapur Road | Mysore (Kaldasa Road)

Online appointments: www.apolloclinic.com

TO BOOK AN APPOINTMENT

1860 500 7733



**Apollo Medical
Centre**

32Yrs 7Mths 18Dys *Artise Closer to you*

Patient Name : Mrs. Ponnaganti Padmini
UHID : CKOR.0000259389
Printed On : 09-11-2024 01:32 PM
Department : Radiology
Referred By : Self
Employee Id : 22S32505

Age : 32Yrs 7Mths 18Dys
OP Visit No. : CKOROPV431236
Advised/Pres Doctor : ---
Qualification : ---
Registration No. : ---

DEPARTMENT OF RADIOLOGY

X RAY CHEST PA

Both lungs fields appear normal.

Both hilae are normal.

Both costophrenic and cardiophrenic angles are normal.

The cardiac and mediastinal shadows appear normal.

Bones and soft tissues appear normal.

IMPRESSION : NORMAL STUDY.

---End Of The Report---

P.J Vinod

Dr.VINOD P JOSEPH
MBBS, DNB, DMRD
25487
Radiology

Apollo Health and Lifestyle Limited

(CIN - U85110TG2000PLC046089) Regd. Office: #7-1-617/A, 615 & 616, Imperial Towers, 7th Floor ; Ameerpet, Hyderabad, Telangana - 500 038 | Email ID: enquiry@apollohl.com

APOLLO CLINICS NETWORK KARNATAKA

Bangalore (Basavanagudi | Bellandur | Electronics City | HSR Layout | Indira Nagar | JP Nagar | Kundalahalli | Koramangala | Sarjapur Road) **Mysore** (Kallidasa Road)

Online appointments: www.apolloclinic.com

TO BOOK AN APPOINTMENT

1860 500 7788

Outlook

Fw: Health Check up Booking Confirmed Request(22S32505), Package Code-PKG10000377, Beneficiary Code-300059

From KOLLI RAMA KISHORE <KOLLI.KISHORE@bankofbaroda.com>
Date Sat 09-11-2024 10:00
To Koramangala Apolloclinic <koramangala@apolloclinic.com>

Get Outlook for Android

From: Mediwheel <wellness@mediwheel.in>
Sent: Thursday, November 7, 2024 3:37:12 PM
To: KOLLI RAMA KISHORE <KOLLI.KISHORE@bankofbaroda.com>
Cc: customercare@mediwheel.in <customercare@mediwheel.in>
Subject: Health Check up Booking Confirmed Request(22S32505), Package Code-PKG10000377, Beneficiary Code-300059

ते तो मेल में दी गयी लिंक पर क्लिक ना करें या अटैचमेंट ना खोलें.
<'S DOMAIN. DO NOT CLICK ON LINKS OR OPEN ATTACHMENTS UNLESS YOU KNOW THE SEN

011-41195959

Dear K Rama Kishore ,

We are pleased to confirm your health checkup booking request with the following details.

Hospital Package Name : Mediwheel Full Body Health Annual Plus Check
Name of Diagnostic/Hospital : Apollo Medical Centre - Koramangala
Address of Diagnostic/Hospital : Apollo Medical centre, Plot 51, 5th Block, Opp. Jyothi Nivas College, Koramangala - 5600095
City : Bangalore
State : Karnataka
Pincode : 560095
Appointment Date : 09-11-2024
Confirmation Status : Booking Confirmed
Preferred Time : 08:00 AM - 08:30 AM
Booking Status : Booking Confirmed

Member Information		
Booked Member Name	Age	Gender
Ponnaganti Padmini	32 year	Female

Note - Please note to not pay any amount

ಭಾರತ ಸರ್ಕಾರ
Government of India

ಭಾರತ ಸರ್ಕಾರ
Padma Ponnappa
ಜನ್ಮ ದಿನ/DOB: 22/03/1992
ಲಿಂಗ / GENDER
FEMALE

Issue Date: 24/10/2012

5312 2724 7074
VID : 9121 2970 8636 2033
ಪಾದ್ಮಾ ಪ. ಪುನಪ್ಪಾ