



Medicover Hospitals

VENKOJIPALAM VISAKHAPATNAM - 530017
ANDHRA PRADESH - INDIA
PHONE NO - 0891 6829999



Dr. MEGHANATH YENNI
M.B.B.S., D.N.B - GENERAL MEDICINE
CONSULTANT GENERAL MEDICINE

3p - 120/7am
paj - 73/min

AW
Chp B nch f/w
K 2y (2)



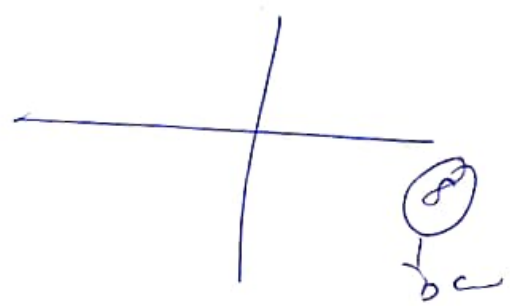
MEDICOVER HOSPITALS

VENKOJIPALEM VISAKHAPATNAM -530017
ANDHRA PRADESH -INDIA
PHOpppNE NO ; 0891-6829999

Dr. DENTAL CONSULTATION
CONSULTANT DENTAL

NAME : _____ AGE : _____

Pt has come for general check up



Adv
Ultrix - 1st tooth brush - ①

Paul

Medicover Unit - I
18-1-3, KGH Down, Maharani-peta,
Jagadamba Junction, Visakapatnam,
Andhrapradesh - 530 002.
Ph: +91 96526 69351

Medicover Unit - III
Sry. No. 27, Plot No. 05, BRTS Road,
Health City, Arilova, Chinnagadalu Mandal,
Visakhapatnam, Andhrapradesh - 530 040.
Ph: +91 08916677888

Medicover - MVP
1-1-83, Sector -6, Venkojipalem,
MVP Colony, Visakapatnam,
Andhrapradesh -530017,
Ph: +91 8886655677



Medicover Hospitals
VENKOJIPALAM VISKHAPATNAM -530017
ANDHRA PRADESH -INDIA
PHONO NO : 0891-6829999

OPHTHALMOLOGIST CONSULTATION

NAME: M. Gopi AGE: 34 Male

DATE: 8/3/24

AR $\begin{cases} R - 0.50 - 1.00 \times 72^\circ \\ L - 2.50 - 6.00 \times 151^\circ \end{cases}$

SUR $\begin{cases} R - 6/6 - 0.50 \times 78^\circ 6/6 \\ L - 6/24P - 1.00 - 1.75 \times 150^\circ 6/6P \end{cases}$

Low $\begin{cases} 10^{\circ} \text{ in } R \\ 10^{\circ} \text{ in } L \end{cases}$

(L) ? Keratocony

detials (BE)

K1 K2 (BE)

(R)

(L)

$\begin{matrix} \times 69^\circ \\ R_1 - 44.25 & K_1 - 45.00 \times 154^\circ \\ & K_2 - 48.35 \\ R_2 - 44.50 \end{matrix}$

Ad

- Squam

- R/c Orbscan

Adh - Orbscan (BE)

lh



Medicover Hospitals
VENKOJIPALAM VISAKHAPATNAM - 530017
ANDHRA PRADESH - INDIA



Lab Report

Patient Name : **Mr. MODALAVALASA GOPI** Age /Gender : **34 Y(s)/Male**
 Bill No/ UMR No : **V4BC211656/V4U173310** Referred By : **Dr. CMO**
 Received Dt : **08-Mar-24 09:27 am** Report Date : **08-Mar-24 11:05 am**
 Lab No : **108/24**

Parameters **Result** **Biological Reference Intervals**

CUE (COMPLETE URINE EXAMINATION)

CHEMISTRY TEST

UROBILINOGEN	NIL	Negative
BILIRUBIN	Negative	Negative
KETONE BODIES	Negative	Negative
BLOOD	Negative	Negative
PROTEIN	NIL	NIL
NITRITE	Negative	Negative
LEUCOCYTES	Negative	
GLUCOSE	NIL	NIL
SPECIFIC GRAVITY	1.010	1.005 - 1.030
PH	6.0	5.0 - 8.0

MICROSCOPY MORPHOLOGY

RBC	NIL	0 - 3 /HPF
WBC (WHITE BLOOD CELL)	* 1-2	0 - 5 /HPF
SQEP (SQUAMOUS EPITHELIAL CELL)	1-2	0 - 5 /HPF
UNCC (PATHOLOGICAL CAST)	NIL	0 - 0 /HPF
UNCX (UNCLASSIFIED CRYSTALS)	NIL	0 - 5 /HPF

*** End Of Report ***

Doctor Incharge

Dr.MUDUGANTI SRINIVAS
MBBS, MD
CONSULTANT PATHOLOGIST

Dr.SRUJANA
MBBS, MD PATHOLOGY
CONSULTANT PATHOLOGIST

Dr.MOHAMMAD SIMI IQBAL
M.B.B.S, M.D
CONSULTANT BIOCHEMIST

Medicover Unit - I
18-1-3, KGH Down, Maharani-peta,
Jagadamba Junction, Visakhapatnam,
Andhrapradesh - 530 002.
Ph: +91 96526 69351

Medicover Unit - III
Sry. No. 27, Plot No. 05, BRTS Road,
Health City, Arilova, Chinagadani Mandal,
Visakhapatnam, Andhrapradesh - 530 040.
Ph: +91 0891-6677888

Medicover - MVP
1-1-83, Sector-6, Venkojipalem,
MVP Colony, Visakhapatnam,
Andhrapradesh-530017.
Ph: +91 8886655677



Medicover Hospitals

VENKOJIPALAM VISAKHAPATNAM - 530017
ANDHRA PRADESH - INDIA



MEDICOVER HOSPITALS

A UNIT OF SAHRUDAYA HEALTHCARE PVT LTD

Lab Report

Patient Name	: Mr. MODALAVALASA GOPI	Age /Gender	: 34 Y(s)/Male
Bill No/ UMR No	: V4BC211656/V4U173310	Referred By	: Dr. CMO
Received Dt	: 08-Mar-24 09:27 am	Report Date	: 08-Mar-24 10:03 am
Lab No	: 120000572195		

Parameter	Result Values	Biological Reference
CBC (COMPLETE BLOOD COUNT)		
RBC		
HAEMOGLOBIN	15.2	13.0 - 17.0 g/dl
R B C COUNT	5.3	4.5 - 5.5 10 ⁶ /μL
PCV/HCT	43	40 - 50 %
MCV	* 82	83 - 101 fl
MCH	29	27 - 32 pg
MCHC	* 35	31.5 - 34.5 g/dL
RDW(cv)	* 15.0	11.6 - 14.0 %
WBC		
TC (TOTAL LEUCOCYTE COUNT)	6200	4000 - 11000 cells/cumm
DIFFERENTIAL COUNT		
NEUTROPHILS	60	40 - 80 %
LYMPHOCYTES	33	20 - 40 %
MONOCYTES	05	02 - 10 %
EOSINOPHILS	02	00 - 06 %
BASOPHILS	00	00 - 01 %
PLATELET COUNT		
PLATELET COUNT	1.69	1.50 - 4.50 Lakhs/cumm
BLOOD GROUPING AND RH		
BLOOD GROUP	" O "	
RH TYPE	POSITIVE	
ESR	08	0 - 10 mm/1st hour

*** End Of Report ***

Doctor Incharge

Dr.MUDUGANTI SRINIVAS
MBBS, MD
CONSULTANT PATHOLOGIST

Dr.SRUJANA
MBBS, MD PATHOLOGY
CONSULTANT PATHOLOGIST

Dr.MOHAMMAD SIMI IQBAL
M.B.B.S, M.D
CONSULTANT BIOCHEMIST



Medicover Hospitals

VENKOJPALAM VISAKHAPATHAM - 530017
ANDHRA PRADESH - INDIA



A UNIT OF SAMRUDDHA HEALTHCARE PVT LTD

Lab Report

Patient Name	: Mr. MODALAVALASA GOPI	Age /Gender	: 34 Y(s)/Male
Bill No/ UMR No	: V4BC211656/V4U173310	Referred By	: Dr. CMO
Received Dt	: 08-Mar-24 09:27 am	Report Date	: 08-Mar-24 11:21 am
Lab No	: 120000572193		

Parameters

Result

Biological Reference Intervals

HBA1C (GLYCOSYLATED HAEMOGLOBIN)

HBA1C 5.6

Non -Diabetic : <= 5.6 %
Pre Diabetic : 5.7 - 6.4 %
Diabetic : >= 6.5 %

LIPID PROFILE

TOTAL CHOLESTEROL 167

HDL CHOLESTEROL 32

LDL CHOLESTEROL * 93

VLDL 42

SERUM TRYGLYCERIDES 208

CHO/HDL RATIO 5.22

LDL/HDL RATIO 2.91

FBS (FASTING BLOOD GLUCOSE)

FASTING BLOOD GLUCOSE 100

CREATININE * 0.7

GAMMA GT

GAMMA GLUTAMYL TRANSFERASE(GGT) 19

LFT(LIVER FUNCTION TEST)

TOTAL BILIRUBIN 0.5

DIRECT BILIRUBIN 0.2

INDIRECT BILIRUBIN 0.3

SGPT (ALT) 37

SGOT (AST) 22

ALKALINE PHOSPHATASE (ALP) 80

TOTAL PROTEINS 6.8

No risk : < 200 mg/dL
Moderate risk : 200 - 239
High risk : > 240
<40 Low
>60 High
Border line : 100 - 130 mg/dL
High : > 130 mg/dL
Desirable : < 100 mg/dL
100 - 130 mg/dL

Very High : > 500 mg/dL
High : >= 200 - 499 mg/dL
Border line High : >= 150 - 199 mg/dL
Normal : < 150 mg/dL
Normal : < 4.0
Low risk : 4.0 - 6.0
High risk : > 6.0

Normal : 70-99 mg/dL
Impaired : 100-125 mg/dL
Diabetic : >= 126 mg/dL
0.9 - 1.3 mg/dL

10 - 71 U/L

< 1.2 mg/dL

<= 0.20 mg/dL

<= 1.0 mg/dL

<= 41 U/L

<= 40 U/L

40 - 129 U/L

1-2 years : 5.6-7.5 g/dL

> 3 years : 6.0-8.0 g/dL

Adults : 6.4-8.3 g/dL

Medicover Unit - I

18-1-3, KGH Down, Maharanipeta,
Jagadamba Junction, Visakhapatnam,
Andhrapradesh - 530 002.
Ph: +91 96526 69351

Medicover Unit - III

Sry. No. 27, Plot No. 05, BRTS Road,
Health City, Arilova, Chinagaddi Mandal,
Visakhapatnam, Andhrapradesh - 530 040.
Ph: +91 0891-6677888

Medicover - MVP

1-1-83, Sector-6, Venkojipalem,
MVP Colony, Visakhapatnam,
Andhrapradesh-530017.
Ph: +91 8886655677



Medicover Hospitals
VENKOJJIPALAM VISAKHAPATNAM - 530017
ANDHRA PRADESH - INDIA



Lab Report

Patient Name : **Mr. MODALAVALASA GOPI** Age /Gender : **34 Y(s)/Male**
Bill No/ UMR No : **V4BC211656/V4U173310** Referred By : **Dr. CMO**
Received Dt : **08-Mar-24 11:49 am** Report Date : **08-Mar-24 01:51 pm**
Lab No : **120000572335**

Parameters

Result

Biological Reference Intervals

PLBS (POST LUNCH BLOOD GLUCOSE)

PLBS (POST LUNCH BLOOD GLUCOSE)

126

Normal : 70- 139 mg/dL
Impaired : 140 - 199 mg/dL
Diabetic : >= 200 mg/dL

*** End Of Report ***

Suggested Clinical Correlation * If necessary, Please discuss

Verified By : : 14645

Test results related only to the item tested.

No part of the report can be reproduced without written permission of the laboratory.

Md. Simi Iqbal

Dr. MOHAMMAD SIMI IQBAL, M.B.B.S, M.D

Dr. MUDUGANTI SRINIVAS
MBBS, MD
CONSULTANT PATHOLOGIST

Dr. SRUJANA
MBBS, MD PATHOLOGY
CONSULTANT PATHOLOGIST

Dr. MOHAMMAD SIMI IQBAL
M.B.B.S, M.D
CONSULTANT BIOCHEMIST

Medicover Unit - I

18-1-3, KGH Down, Maharanipeta,
Jagadamba Junction, Visakhapatnam,
Andhrapradesh - 530 002.
Ph: +91 96526 69351

Medicover Unit - III

Sry. No. 27, Plot No. 05, BRTS Road,
Health City, Arilova, Chinagauli Mandal,
Visakhapatnam, Andhrapradesh - 530 040.
Ph: +91 0891-6677888

Medicover - MVP

1-1-83, Sector-6, Venkojjipalem,
MVP Colony, Visakhapatnam,
Andhrapradesh-530017.
Ph: +91 8886655677



Medicover Hospitals

VI NKOJIPALAM VISAKHAPATNAM - 530017
ANDHRA PRADESH - INDIA



DEPARTMENT OF RADIOLOGY

Patient Name	: Mr. MODALAVALASA GOPI	Age / Gender	: 34 Y(s)/Male
Bill No/ UMR No	: V4BC211656/V4U173310	Referred By	: Dr. CMO
Received Dt	: 08-Mar-24 09:23 am	Report Date	: 08-Mar-24 11:29 am

USG ABDOMEN (MALE)

LIVER

Measuring 12.0 cm. Normal in size with normal homogenous echotexture. There is no evidence of IHBR/EHBR dilatation seen.
The portal and hepatic vessels are normal. No S.O.L. noted.

GALL BLADDER

Distended. Wall thickness is normal.
Small polyp of size 2 mm seen in the gall bladder lumen.
Common bile duct appears normal with no intraluminal mass/ calculi.

PANCREAS

Head, Body & Tail are identified with normal echopattern & smooth outlines. The pancreatic duct system appears normal. The peri pancreatic fat planes are well preserved.

SPLEEN

Normal in size (11.6 cm) with homogenous echotexture.

RIGHT KIDNEY

Measuring 10.0 cm. Normal in size and echopattern.
Cortico-Medullary differentiation maintained.
No evidence of mass / calculi / hydroureteronephrosis seen.

LEFT KIDNEY

Measuring 9.7 cm. Normal in size and echopattern.
Cortico-Medullary differentiation maintained.
No evidence of mass / calculi / hydroureteronephrosis seen.
No evidence of suprarenal / retroperitoneal mass noted.

URINARY BLADDER

Partially distended.

PROSTATE

Measuring 15 cc. Normal in size and echopattern.

No evidence of ascites/ pleural effusion seen.
No detectable bowel pathology seen.

IMPRESSION

* Small gall bladder polyp.

Medicover Unit - I

1B-1-3, KGH Down, Maharanieta,
Jagadamba Junction, Visakapatnam,
Andhrapradesh - 530 002.
Ph: +91 96526 69351

Medicover Unit - III

Sry. No. 27, Plot No. 26, BR 75 Road,
Health City, Arilova, Chinnagadalu Mandal,
Visakhapatnam, Andhrapradesh - 530 040.
Ph: +91 08916677888

Medicover - MVP

1-1-83, Sector -6, Venkojipalem,
MVP Colony, Visakapatnam,
Andhrapradesh-530017.
Ph: +91 8886655677



Medicover Hospitals

VENKOJIPALAM VISAKHAPATNAM - 530017
ANDHRA PRADESH - INDIA



Lab Report

Patient Name	: Mr. MODALAVALASA GOPI	Age /Gender	: 34 Y(s)/Male
Bill No/ UMR No	: V4BC211656/V4U173310	Examined By	: Dr. CMO
Received Dt	: 08-Mar-24 09:23 am	Report Date	: 08-Mar-24 01:17 pm
Lab No	: 0		

2D ECHO WITH COLOUR DOPPLER

MEASUREMENTS

LVID(D)	5.0 Cms
LVID(s)	3.3 Cms
LVEF	64 %
IVS (d)	1.0 Cms
PWD (d)	1.0 Cms

VALVES

MITRAL VALVE	NORMAL
AORTIC VALVE	NORMAL
TRICUSPID VALVE	NORMAL
PULMONARY VALVE	NORMAL

CHAMBER

RIGHT ATRIUM	NORMAL
RIGHT VENTRICLE	NORMAL
LEFT ATRIUM	3.2 Cms
LEFT VENTRICLE	NORMAL
RWMA	NO
SYSTOLIC FUNCTION	GOOD
DIASTOLIC DYSFUNCTION	NO
CLOT	NO

SEPTAE

INTER ATRIAL SEPTUM	INTACT
INTER VENTRICULAR SEPTUM	INTACT

GREAT ARTERY AND OTHERS

AORTA	2.6 Cms
PULMONARY ARTERY	NORMAL
PERICARDIUM	NORMAL
IVC/SVC/CS	NORMAL

DOPPLER STUDY

MITRAL FLOW	E > A
AORTIC FLOW	1.4 M/sec
PULMONARY FLOW	1.1 M/sec
TRICUSPID FLOW	NORMAL
OTHER FLOWS	NIL

COLOUR DOPPLER

MR	NO
AR	NO
TR	NO
PR	NO

FINAL IMPRESSION

Medicover Unit - I
18-1-3, KGH Down, Maharani-peta,
Jagadamba Junction, Visakhapatnam,
Andhrapradesh - 530 002.
Ph: +91 96526 69351

Medicover Unit - III
Sry. No. 27, Plot No. 05, BRTS Road,
Health City, Arilova, Chinagiri-Mandal,
Visakhapatnam, Andhrapradesh - 530 040.
Ph: +91 0891-6677888

Medicover - MVP
1-1-83, Sector-6, Venkojipalem,
MVP Colony, Visakhapatnam,
Andhrapradesh-530017.
Ph: +91 8886655677



Medicover Hospitals
VENKOJIPALAM VISAKHAPATNAM - 530017
ANDHRA PRADESH - INDIA



Lab Report

Patient Name	: Mr. MODALAVALASA GOPI	Age /Gender	: 34 Y(s)/Male
Bill No/ UMR No	: V4BC211656/V4U173310	Referred By	: Dr. CMO
Received Dt	: 08-Mar-24 09:23 am	Report Date	: 08-Mar-24 01:17 pm
Lab No	: 0		

- * NO RWMA OF LV
- * GOOD LV SYSTOLIC FUNCTION (EF : 64 %)
- * NO MR / AR / TR/ PAH

*** End Of Report ***

Doctor Incharge

Dr.ARCHANA BEHRA
MD.,DNB(CARDIOLOGY)
CONSULTANT CARDIOLOGIST

Dr.BODEPUDI SRIKANTH
MD DM
CONSULTANT CARDIOLOGIST

Dr.K P RANGANAYAKULU
MD., DM.
INTERVENTIONAL CARDIOLOGIST

Dr.S.SRIKARA SAMIR NANDAN
MD., DM.
INTERVENTIONAL CARDIOLOGIST

Dr.RAVIKUMAR GURUGUBELLI
MD, DM
CONSULTANT CARDIOLOGIST

Dr.A.SURESH
MBBS,MD(GM),DM-CARDIOLOGY,
SENIOR CONSULTANT

Medicover Unit - I
18-1-3, KGH Down, Maharanieta,
Jagadamba Junction, Visakhapatnam,
Andhrapradesh - 530 002.
Ph: +91 96526 69351

Medicover Unit - III
Sry. No. 27, Plot No. 05, BRJS Road,
Health City, Arilova, Chinnaagallu Mandal,
Visakhapatnam, Andhrapradesh - 530 040.
Ph: +91 0891-6677888

Medicover - MVP
1-1-83, Sector-6, Venkojipalem,
MVP Colony, Visakhapatnam,
Andhrapradesh-530017.
Ph: +91 8886655677



Medicover Hospitals

VENKOJJIPALEM, VISAKHAPATNAM - 530017
ANDHRA PRADESH - INDIA



DEPARTMENT OF RADIOLOGY

Patient Name	: Mr. MODALAVALASA GOPI	Age / Gender	: 34 Y(s)/Male
Bill No/ UMR No	: V4BC211656/V4U173110	Referred By	: Dr. CMO
Received Dt	: 08-Mar-24 09:23 am	Report Date	: 08-Mar-24 01:29 pm

X-RAY CHEST PA VIEW

FINDINGS

- The cardiac size & configuration appear normal.
- The Aorta and pulmonary vasculature appear normal.
- There is no evidence of mediastinal widening.
- Both the lungs and CP angles are clear.
- Focal tenting of right hemidiaphragm.
- The soft tissues and the bones of the rib cage displayed no abnormality.

IMPRESSION

- * Focal tenting of right hemi diaphragm.

*** End Of Report ***


Dr. VENKATA SUMAN KUNA, MBBS , M.D,
PDCC(MSK)
 CONSULTANT RADIOLOGIST

34 Years

M GOPI
Male

08/03/2024 09:33:36

MEDCOVER HOSPITALS MYP VZAG

Rate 69 . SINUS RHYTHM.....normal P axis, V-rate 50-99
 . LOW VOLTAGE IN FRONTAL LEADS.....all frontal leads <0.5mv

WELLNESS

PR 168
 QRSD 90
 QT 400
 QTc 429

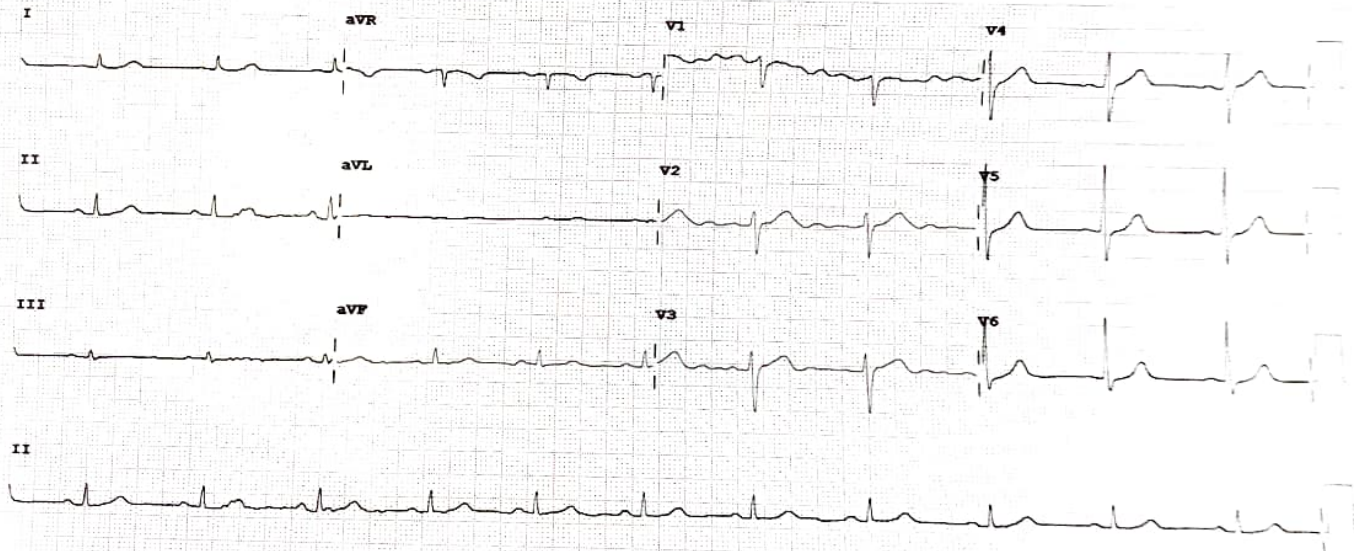
--AXIS--

P 58
 QRS 51
 T 45

- OTHERWISE NORMAL ECG -

12 Lead; Standard Placement

Unconfirmed Diagnosis



Device: Speed: 25 mm/sec Limb: 10 mm/mV Chest: 10.0 mm/mV

F 50- 0.50- 40 Hz W

PH090A CL7