


 भारत सरकार
 Government of India
 

Ram Chandra Kumawat
 Ram Chandra Kumawat
 जन्म तिथि/DOB: 10/10/1998
 लिंग/ MALE

Issue Date: 27/01/2014



7685 3614 6860
 VID : 9160 2126 2200 9056

मेरा आधार, मेरी पहचान

Handwritten signature


 भारतीय विशिष्ट पहचान प्राधिकरण
 Unique Identification Authority of India
 

पता:
 S/O: Shankar Lal Kumawat, Khano ka Rasta,
 Dhoinda, Rajsamand, Rajsamand,
 Rajasthan - 313324

Address:
 S/O: Shankar Lal Kumawat, Khano ka Rasta,
 Dhoinda, Rajsamand, Rajsamand,
 Rajasthan - 313324



7685 3614 6860
 VID : 9160 2126 2200 9056

1947 | help@uidai.gov.in | www.uidai.gov.in



Aravali Hospital

332, Ambamata Scheme, Udaipur - 313 004

T: 91 294 2430222, 2431222

email : aravalihospital@yahoo.com



गुणवत्ता पूर्ण चिकित्सा सेवाओं के लिये
भारत सरकार की
क्वालिटी काउंसिल ऑफ इण्डिया (QCI-NABH)
द्वारा प्रमाणित

TO WHOM SO EVER IT MAY CONCERN


This is to certify **MR. RAM CHANDRA KUMAWAT AGE 26** years male has undergone his physical check- up and routine blood test. He has no physical illness detected. He is physically fit.

Vitals:-

Pulse	:	86 per minute
BP	:	110/80 mmHg
Height	:	173 cms.
Weight	:	52 Kgs.
BMI	:	17.4
Medical history	:	No
Surgical History	:	H/O Appendix Operate in 2019.

Clinical Findings: -

Per Abdomen	:	NAD
CVS/CNS	:	NAD
Lungs	:	Clear
Skin	:	NAD
Eye Vision	:	Normal
Color Vision	:	Normal
Dental	:	NAD


(Dr. Sangeeta Gupta)
Reg. No. 018332 (RMC)

Dated: 14/09/2024



Helpline : 9352 108 108

www.aravalihospital.in



Aravali Hospital

332, Ambamata Scheme, Udaipur - 313 004
T: 91 294 2430222, 2431222
email : aravalihospital@yahoo.com



गुणवत्ता पूर्ण चिकित्सा सेवाओं के लिये
भारत सरकार की
क्वालिटी काउंसिल ऑफ इण्डिया (QCI-NABH)
द्वारा प्रमाणित

Name Mr. RAMCHANDRA KUMAWAT 12722	Visit Date & Time 14/09/2024 10:31:38	PATIENT ID APL 11246615
Age 26 Yrs Sex Male	Sample Accepted : 14/09/2024 16:26:34	Ref. By
	Test Authenticated at : 14/09/2024 17:43:16	



HAEMATOLOGY

Test Name	Value	Status	Unit	Biological Ref Interval
HAEMOGLOBIN (HB)	14.9		gm %	11.0 - 16.0
RBC Count	4.71		X10 ⁶ /UL	3.50 - 5.50
PCV	38.5		%	36.0 - 48.0
MEAN CORP. VOLUME (MCV)	81.8		fL	80.0 - 99.0
MEAN CORP. HB (MCH)	31.7		pg	27.0 - 32.0
MEAN CORP. HB CON. (MCHC)	38.8	H	g/dL	32.0 - 36.0
RDW-CV	13.9		%	11.0 - 16.0
RDW-SD	41.7		fl	35.0 - 56.0
TLC Count	5.86		/cmm	4.00 - 11.00
Differential Leucocyte Count (DLC)				
POLYMORPH	63		%	45 - 75
LYMPHOCYTE	26		%	20 - 45
EOSINOPHIL	05		%	01 - 06
MONOCYTE	06		%	01 - 10
BASOPHIL	00		%	00 - 01
TOTAL PLATELET COUNT	172		x10 ³ /uL	150 - 450
MPV	9.9			7.4 - 10.4
PDW	14.5		%	10.0 - 17.0
PCT	0.2		%	0.1 - 0.3
P-LCR	30.4		%	11.0 - 45.0
P-LCC	52.0			30.0 - 90.0

DR. NARENDRA MOGRA
RMC NO5394

Helpline : 9352 108 108

www.aravalihospital.in





Aravali Hospital

332, Ambamata Scheme, Udaipur - 313 004
T: 91 294 2430222, 2431222
email : aravalihospital@yahoo.com



गुणवत्ता पूर्ण चिकित्सा सेवाओं के लिये
भारत सरकार की
क्वालिटी काउंसिल ऑफ इण्डिया (QCI-NABH)
द्वारा प्रमाणित

Name Mr. RAMCHANDRA KUMAWAT 12722	Visit Date & Time 14/09/2024 10:31:38	PATIENT ID APL 11246615
Age 26 Yrs Sex Male	Sample Accepted : 14/09/2024 16:26:34	Ref. By
	Test Authenticated at : 14/09/2024 17:43:16	



HAEMATOLOGY

Test Name	Value	Status	Unit	Biological Ref Interval
ESR	4		mm/1st hr.	0 - 20
Blood Group (ABORH)	'O'	POSITIVE		

DR. NARENDRA MOGRA
RMC NO5394

Helpline : 9352 108 108

www.aravalihospital.in





Aravali Hospital

332, Ambamata Scheme, Udaipur - 313 004
T: 91 294 2430222, 2431222
email : aravalihospital@yahoo.com



गुणवत्ता पूर्ण चिकित्सा सेवाओं के लिये
भारत सरकार की
क्वालिटी काउंसिल ऑफ इण्डिया (QCI-NABH)
द्वारा प्रमाणित

Name Mr. RAMCHANDRA KUMAWAT	12722	Date & Time	14/09/2024 10:31:38	PATIENT ID	APL 11246615
Age	26 Yrs	Sex	Male	Sample Accepted :	14/09/2024 16:26:34
				Test Authenticated at :	14/09/2024 17:43:16
				Ref. By	



BIOCHEMISTRY

Test Name	Value	Status	Unit	Biological Ref Interval
BILIRUBIN-TOTAL	0.66		mg/dl	0.20 - 1.20
BILIRUBIN-DIRECT	0.18		mg/dl	0.00 - 0.40
BILIRUBIN-INDIRECT	0.48	H	mg/dl	0.10 - 0.40
BLOOD SUGAR (FASTING)	80.3		mg/dl	60.0 - 110.0
BLOOD SUGAR (PP)	96.0	L	mg/dl	110.0 - 140.0
CREATININE	0.75		mg/dl	0.50 - 1.17
BUN	13.50		mg/dl	7.00 - 22.00
SGPT-ALT	21.80		U/L	0.00 - 49.00

DR. NARENDRA MOGRA
RMC NO5394



Helpline : 9352 108 108

www.aravalihospital.in



Aravali Hospital

332, Ambamata Scheme, Udaipur - 313 004
T: 91 294 2430222, 2431222
email : aravalihospital@yahoo.com



गुणवत्ता पूर्ण चिकित्सा सेवाओं के लिये
भारत सरकार की
क्वालिटी काउंसिल ऑफ इण्डिया (QCI-NABH)
द्वारा प्रमाणित

Name Mr. RAMCHANDRA KUMAWAT 12722	Visit Date & Time 14/09/2024 10:31:38	PATIENT ID APL 11246615
Age 26 Yrs Sex Male	Sample Accepted : 14/09/2024 16:26:34	Ref. By
	Test Authenticated at : 14/09/2024 17:43:16	



CLINICAL PATHOLOGY

Test Name	Value	Status	Unit	Biological Ref Interval
URINE EXAMINATION				
<u>PHYSICAL EXAMINATION</u>				
QUANTITY	20			
COLOUR	PALE YELLOW			
SPECIFIC GRAVITY	QNS			
APPEARANCE	CLEAR			
DEPOSITS	NIL			
PH	ACIDIC			
<u>CHEMICAL EXAMINATION</u>				
ALBUMIN	NIL			
SUGAR	NIL			
<u>MICROSCOPY EXAMINATION</u>				
EPITHELIAL CELLS	OCCASIONAL		/HPF	
PUS CELLS	2-3		/HPF	
RBC'S	NIL		/HPF	
CASTS	ABSENT			
CRYSTALS	ABSENT			
BACTERIA	NIL			
YEAST CELLS	NIL			
TRICHOMONAS VAGINALIS	NIL			
SPERMATOZOA	NIL			
OTHERS	NIL			

DR. NARENDRA MOGRA* End of Report ***

RMC NO5394

DR. HUSSAIN ALI RANGWALA Helpline : 9352 108 108





Aravali Hospital

332, Ambamata Scheme, Udaipur - 313 004
T: 91 294 2430222, 2431222
email : aravalihospital@yahoo.com



गुणवत्ता पूर्ण चिकित्सा सेवाओं के लिये
भारत सरकार की
क्वालिटी काउंसिल ऑफ इण्डिया (QCI-NABH)
द्वारा प्रमाणित

Ref No.	Date : 14-09-2024		
Patient's Name :	MR. RAMCHANDRA KUMAWAT	Age: 26 yrs	Sex: M
Ref. By :	DR		

X-RAY EXAMINATION REPORT

Part X-Rayed : CHEST PA View


Contrast Medium Used : None

Report :

- ❖ The lungs on either side show equal translucency and show normal vasculature.
- ❖ No focal lung parenchymal or interstitial lesion is seen.
- ❖ No evidence of any infiltration is seen.
- ❖ The hilar shadows are normal in size, shape and position.
- ❖ The pleural cavities are clear.
- ❖ The domes of the diaphragm are smooth.
- ❖ The cardiac size is normal.

Impression:

❖ **NO CARDIO PULMINARY ABNORMALITY IS SEEN.**


RADIOLOGIST

Note: This report is not valid for medico legal purpose.
Every report needs to be correlated and interpreted clinically.



Helpline : 9352 108 108

www.aravalihospital.in

health

ram chandra 26 yrs
Male

9/14/2024 1:09:56 PM

Rate 74 . Age not entered, assumed to be 50 years old for purpose of ECG interpretation
Sinus rhythm.....normal P axis, V-rate 50- 99

PR 146
QRSD 106
QT 379
QTc 421

--AXIS--

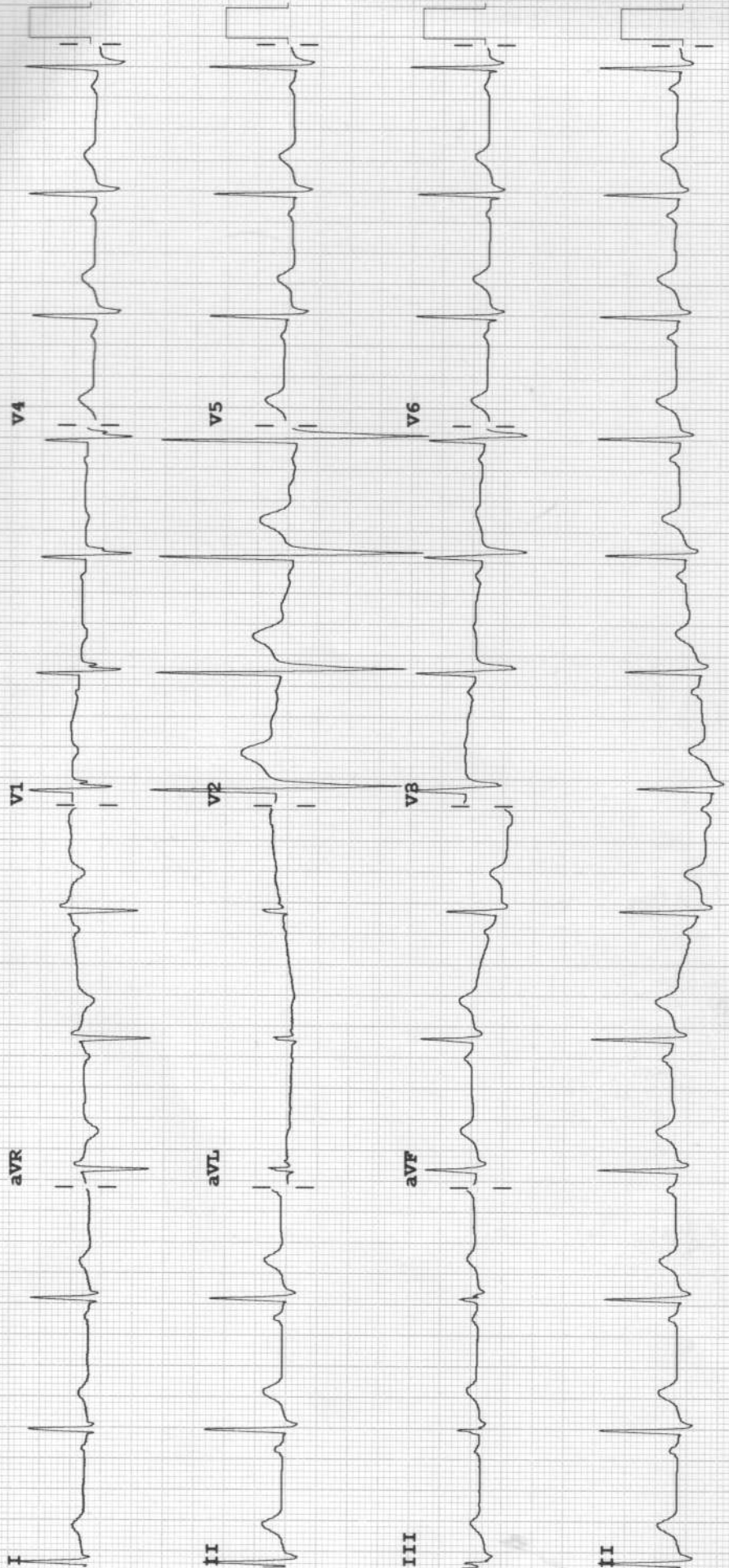
P 64
QRS 42
T 60

12 Lead; Standard Placement

TWNL
B

- NORMAL ECG -

Unconfirmed Diagnosis



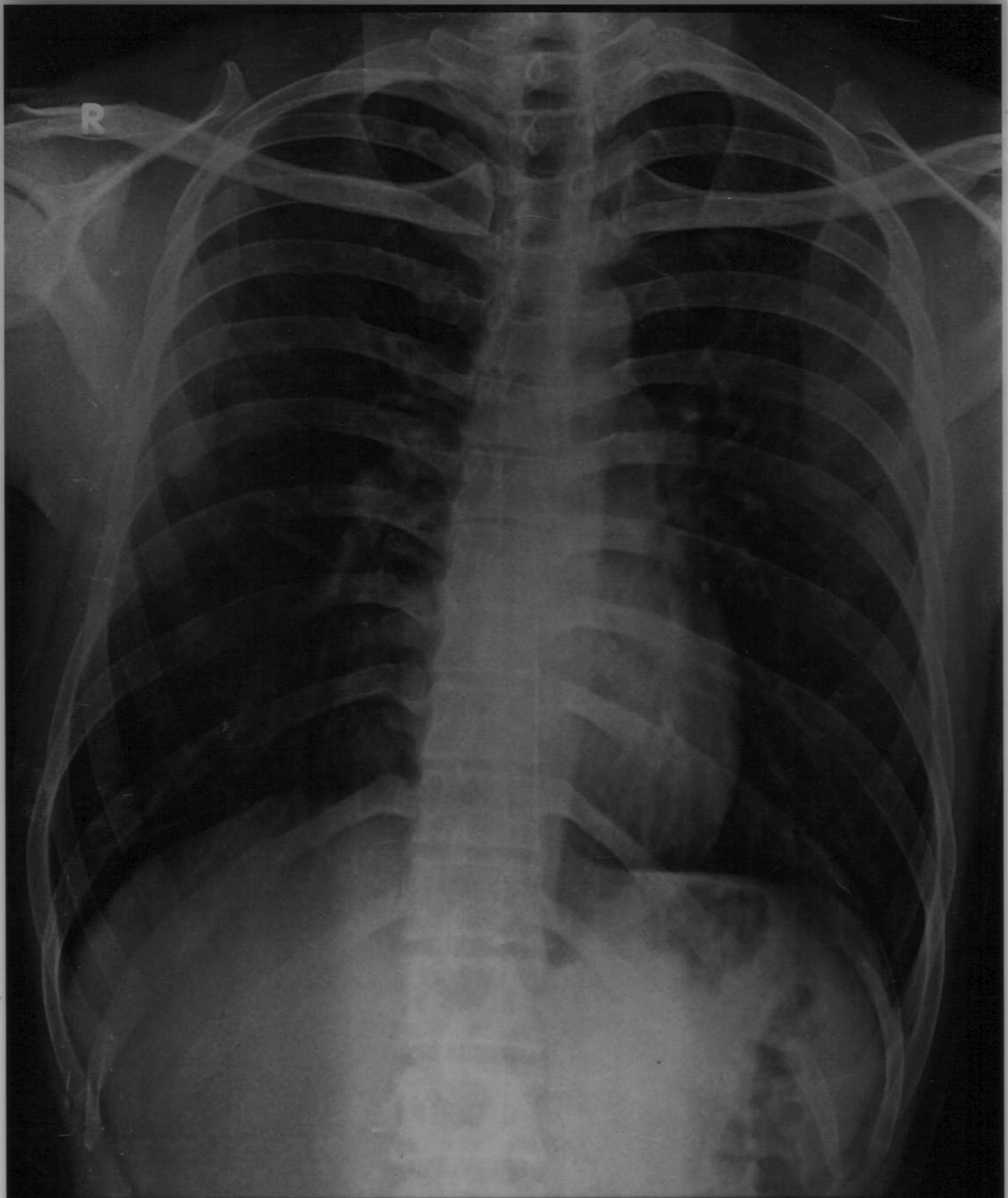
Device:

Speed: 25 mm/sec Limb: 10 mm/mV Chest: 10.0 mm/mV

F 60~ 0.15-100 Hz

100B CL

P?



MR RAMCHANDRA KUMAWAT 26YR INS 12722 M CHEST PA 14
ARAVALI HOSPITAL, 332 AMBAMATA SCHEME UDAIPUR