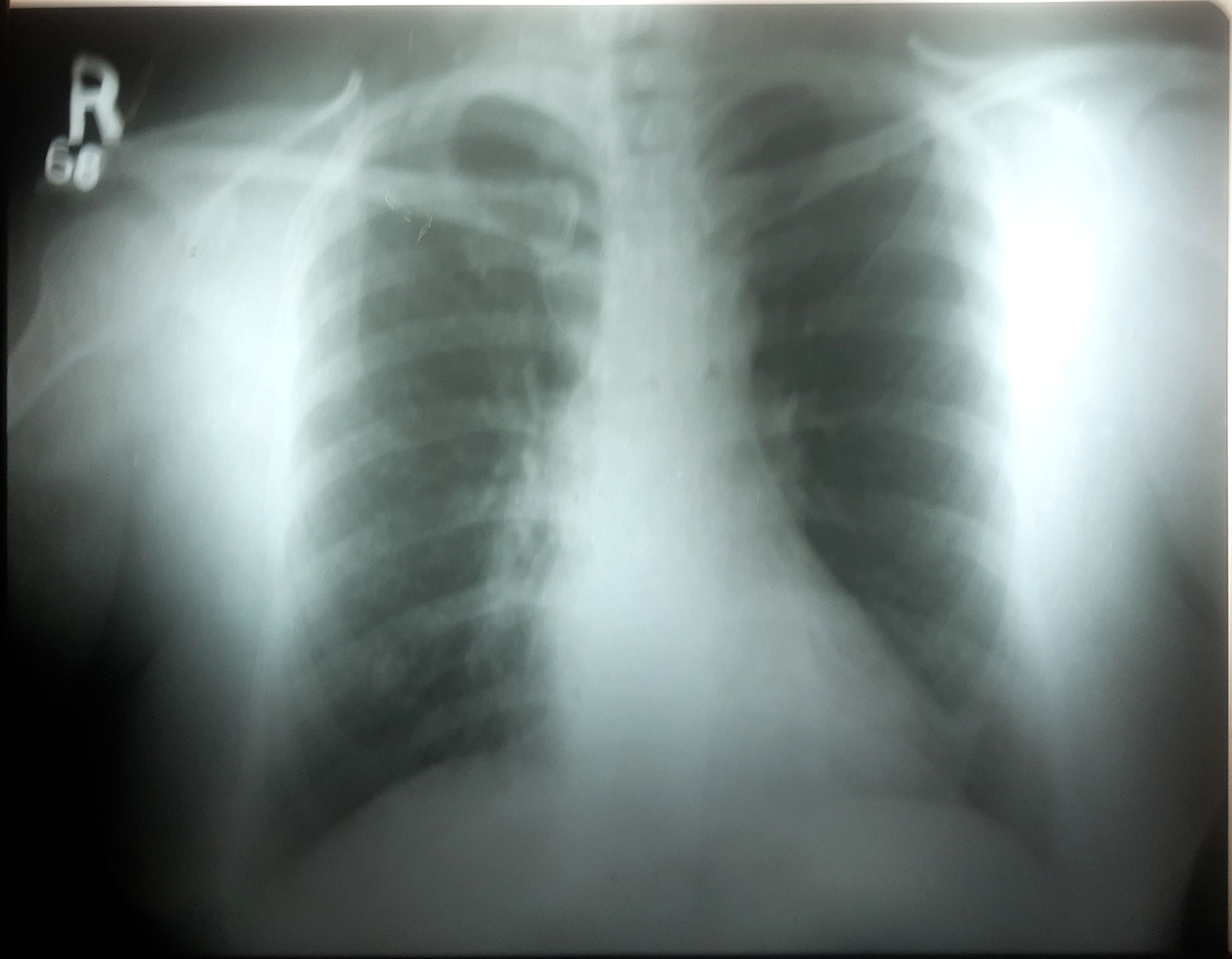

R
68



MEDIWHEEL HEALTH

Appointment Date:- 09-12-2023

Name of Client:- Mrs Sujata Naragund

Age / Gender:- 47 Years / Female

Phone No. 9886632361

TEST DETAILS ARE BELOW

Please login to your account to confirm the same.

Also you mail us for confirmation Package

Name: Medi-wheel Full Body Health Checkup Male

Includes (37)Tests Tests included in this Package: Ecg,

TSH, X-ray Chest, Stress Test (tmt)/ 2d Echo, Blood

Sugar Postprandial, A:g Ratio, Blood Group, Total

Cholesterol, Triglycerides, Fasting Blood Sugar,

Ultrasound Whole Abdomen , Glycosylated

Haemoglobin (hba1c), Hdl, Vldl, Urine Analysis, LDL,

Total Protine, General Consultation, HDL/ LDL ratio,

GGT(Gamma-glutamyl Transferase), Eye Check-up

consultation, ALP (ALKALINE PHOSPHATASE), Uric

Acid, AST/ALT Ratio, Serum Protein, CBC with ESR,

Stool Analysis, Urine Sugar Fasting, Urine Sugar PP, T3,

T4, Cholesterol Total / HDL Ratio, BUN,

BUN/Creatinine Ratio, Bilirubin Total & Direct and

Indirect, Albumin, Globulin

HEBSUR HOSPITAL
Deshnagar,
HUBLI-580 029.
Ph: 0836-2355699, 4250871

MEDIWHEEL HEALTH

Appointment Date:- 09-12-2023

Name of Client:- Mrs Sujata Naragund

Age / Gender:- 47 Years / Female

Phone No. 9886632361

TEST DETAILS ARE BELOW

Please login to your account to confirm the same.

Also you mail us for confirmation Package

Name: Medi-wheel Full Body Health Checkup Male

Includes (37)Tests Tests included in this Package: Ecg,

TSH, X-ray Chest, Stress Test (tmt)/ 2d Echo, Blood

Sugar Postprandial, A:g Ratio, Blood Group, Total

Cholesterol, Triglycerides, Fasting Blood Sugar,

Ultrasound Whole Abdomen , Glycosylated

Haemoglobin (hba1c), Hdl, Vldl, Urine Analysis, LDL,

Total Protine, General Consultation, HDL/ LDL ratio,

GGT(Gamma-glutamyl Transferase), Eye Check-up

consultation, ALP (ALKALINE PHOSPHATASE), Uric

Acid, AST/ALT Ratio, Serum Protein, CBC with ESR,

Stool Analysis, Urine Sugar Fasting, Urine Sugar PP, T3,

T4, Cholesterol Total / HDL Ratio, BUN,

BUN/Creatinine Ratio, Bilirubin Total & Direct and

Indirect, Albumin, Globulin

HEBSUR HOSPITAL

Deshnagar, Nagol,

HUBLI-580 029.

Ph: 0836-2355699, 4250871

Date:- 09 / 12 /2023

FITNESS CERTIFICATE

Mediwheel Health Checkup Insurances

This is to certify that Mrs. Sujata Naragund Age 47yrs, Female was examined at our centre for Medical Fitness she does not carry any contagious disease. And she is found to be mentally fit.

Hight	:	163
Weight	:	80 Kg
Chest	:	93 To 97
Abdomen	:	102
B. P. Reading	:	140 / 100 mmgh 130 / 80 mmhg
Pulse / Min		72 / Min

Medical Officer,

Dr. N.I. Hebsur. M.S
Hebsur Hospital,
Deshpande Nagar,
Hubli.

Dr. N. I. Hebsur
Medical Officer, **M.S.**
HEBSUR HOSPITAL,
Deshpande Nagar, HUBLI-29.
Reg. No. 31764

ಭಾರತ ಸರ್ಕಾರ
GOVERNMENT OF INDIA

ಸುಜಾತಾ ನರಗುಂದ
Sujata Naragund
ಪುಟ್ಟಿದ ವರ್ಷ / Year of Birth : 1976
ಸ್ತ್ರೀ / Female

6930 6674 7499

ಆಧಾರ್ - ಶ್ರೀಸಾಮಾನ್ಯನ ಅಧಿಕಾರ

ಭಾರತೀಯ ಉದ್ದೇಶಗುರುತಿಸುವ ಪ್ರಾಧಿಕಾರ
UNIQUE IDENTIFICATION AUTHORITY OF INDIA

ವಿಳಾಸ:
W/O: ಲಿಂಗಮೂರ್ತಿ, # 28,
ಶ್ರೇಯನಗರ, 6ನೇ ಅಡ್ಡ ರಸ್ತೆ,
ಗೋಕುಲ ರಸ್ತೆ, ಪುಟ್ಟುಳ್ಳಿ, ಧಾರವಾಡ,
ಪುಟ್ಟುಳ್ಳಿ ಉದ್ಯಮನಗರ, ಕರ್ನಾಟಕ,
580030

Address:
W/O: Lingamurthy, # 28,
Shreyanagar, 6th Cross,
Gokul Road, Hubli, Dharwad,
Hubli Udyamnagar,
Karnataka, 580030

1947
1900 180 1947

help@uidai.gov.in

www.uidai.gov.in

ಒ.ಲ. ದಾಖಲೆ ಸೆಲ್ 1947,
ಬೆಂಗಳೂರು-560001

Dr. N. I. Hebsur
M.S.
Medical Officer,
HEBSUR HOSPITAL,
Deshpande Nagar, HUBLI-29.
Reg. No. 31764

(Handwritten signature)

Dr. VENKATRAM KATTI

M.S.(Ophthal)

K.M.C. Reg. No. 57057

JAYAPRIYA HOSPITAL

No. 2, Ashok Nagar Road, Bailappanavar Nagar,
Near Sawai Gandharva Hall
HUBLI-580 029, Karnataka



ಡಾ|| ವೆಂಕಟರಾಮ ಕಟ್ಟಿ

ಎಮ್.ಎಸ್. (ಅಫ್ಠಲ್)

ಕೆ.ಎಮ್.ಸಿ.ರಜಿಸ್ಟರ್ ನಂ. 57057

ಜಯಪ್ರಿಯಾ ಹಾಸ್ಪಿಟಲ್

ನಂ. 2, ಅಶೋಕನಗರ ರೋಡ,
ಬೈಲಪ್ಪನವರನಗರ ಸವಾಯಿ ಗಂಧರ್ವ ಹಾಲ್ ಹತ್ತಿರ,
ಹುಬ್ಬಳ್ಳಿ-580 029. ಕರ್ನಾಟಕ

SPECIALITY EYE CARE CENTRE

TO

Date: 9/12/23

Dr. Hebsur

Hebsur Hospital

Hubli

Respected Sir

Thanks for Referring Shri/Smt. Sujata Naigund, 47 years,
Male/Female Patient for ocular examination.

On examination

	RE	LE
1) VISION	6/6	6/6
2) NEAR VISION	N ₆	N ₆
3) COLOUR VISION	Normal	Normal
4) IOP	19 mmHg	20 mmHg
5) ANTERIOR SEGMENT	within normal limit (BE)	
6) FUNDUS	within normal limit (BE)	

ADVICE : Review every 6mts.

HEBSUR HOSPITAL

Deshpande Nagar,

HUBLI-580 029,

Ph: 0836-2355699, 4250871

Polina
JAYPRIYA HOSPITAL
No: 2, Ashok Nagar Road,
Bailappanavar Nagar,
HUBLI-580029. Ph: 0836-2251767.

HEBSUR HOSPITAL

A Multi Speciality & Research Centre. Narayan Deshpande Nagar.

HUBLI - 580029

Phone No: 0836 2355699, 4250871, 2352616

Email_ID: hebsurgeon@yahoo.com

Patient ID: 2023120053

Name: Mrs. sujata

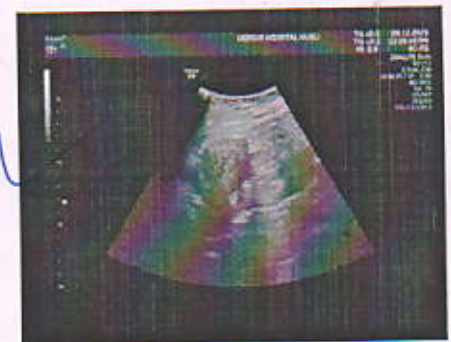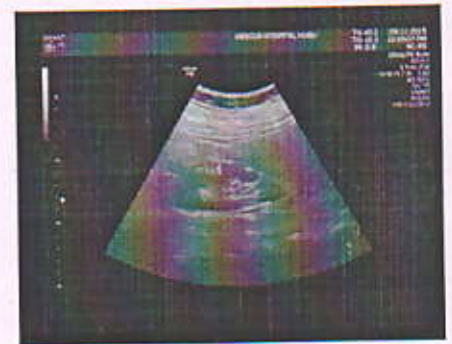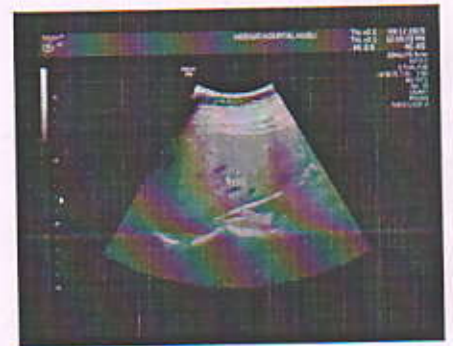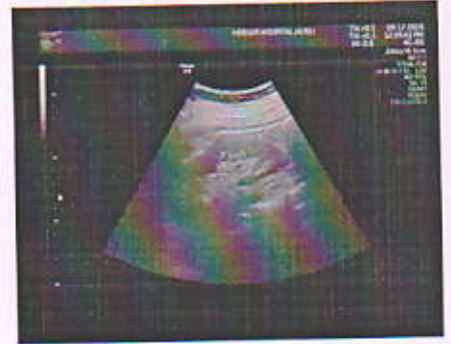Sex: F

Date: 09-Dec-2023

Ref By: SELF

Study: PELVIS ULTRASONOGRAPHY

Examined By: Dr. Nagarekha N Hebsur MBBS, DGO



Dr. N. I. Hebsur

Medical Officer, M.S.

HEBSUR HOSPITAL,
Deshpande Nagar, HUBLI-29.

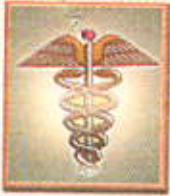Reg. No. 31764

HEBSUR HOSPITAL

Deshpande Nagar,

HUBLI-580 029.

Ph: 0836-2355699, 4250871



HEBSUR HOSPITAL

MULTI SPECIALITY CENTRE

A SPECIAL CENTRE FOR LAPROSCOPIC SURGERY

'Narayan' Deshpande Nagar,
HUBLI-580 029,
Tel : 0836-(Hos) 2355699,
5250871 / 2257354
E-mail : hebsurgeon@yahoo.co.in

PATIENT : Mrs. Sujata Nargund AGE : 47 SEX : Female
REF. : medicine DATE : 09/12/23

THANKS FOR THE REFERRANCE
ABDOMEN ULTRASONOGRAPHY REPORT

LIVER : NORMAL IN SIZE AND ECHOTEXTURE,
NO EVIDENCE OF SOL/BILIARYDILATATION

GB : SHOWS NORMAL LUMEN, NO EVIDENCE
OF CALCULUS.

SPLEEN : NORMAL IN SIZE AND ECHOTEXTURE.

PANCREAS : NO EVIDENCE OF PARENCHYMAL PATHOLOGY

KIDNEYS : BOTH THE KIDNEYS ARE NORMAL IN SIZE AND
ECHOTEXTURE. NO EVIDENCE OF
HYDRONEPHROSES

UB : WELL DISTENDED, NO EVIDENCE OF CALCULUS

UTERUS : ANTEVERTED NORMAL IN SIZE AND ECHOTEXTURE
ENDOMETRIAL ECHOREFLECTIVITY IS MAINTAINED

OVARIES : LEFT OVARY NORMAL
RIGHT OVARY - NORMALY
NO EVIDENCE OF FREE FLUID /
LYMPHADENOPATHY.

NO EVIDENCE OF FREE FLUID/LYMPHADENOPATHY.

PLEASE NOTE :

All anomalies can not be detected by Ultrasound.
Ultrasound has certain limitations.

SONOLOGIST

X-RAY NO. 68

Date: 09 / 12 / 2023

Client Name:- Mrs. Sujata Naragund

Age: 47 Years Gender / Female

Ref Doctor : Dr. N. I. Hebsur

HEBSUR HOSPITAL

X-RAY - CHEST - PA VIEW

- LUNG FIELDS ARE CLEAR
- CARDIAL SHADOW IS NORMAL
- BOTH CP ANGLES ARE CLEAR

Impression: Normal Chest X-Ray Report.

Dr. N. I. Hebsur
MS.
Medical Officer,
HEBSUR HOSPITAL,
Deshpande Nagar, HUBLI-29.
Reg. No. 31764



DISHA

Direction for Better Health

DIAGNOSTICS

Fully Computerized Diagnostic Centre

HEBSUR HOSPITAL

Opp. State Bank of India,
Deshpande Nagar, HUBLI.
Ph: (Hospital) 0836-2355699
Lab - 9035071970
Email: disha2001diagnostics@gmail.com

CLIENT NAME: Mrs : SUJATA NARAGUND

DATE 09.12.2023

AGE /GENDER : 47/FEMALE

LAB REG NO : 841/23

BIO CHEMISTRY REPORT

FASTING BLOOD GLUCOSE:	76.0 mg/dl	60 – 120 mg/dl
POST PRANDIAL BLOOD GLUCOSE	121.0 mg/dl	80-160 mg/dl
SR.CREATININE	0.89 mg/dl	0.8 – 1.4 mg/dl
BLOOD UREA NITROGEN (BUN)	12.0 mg/dl	10 – 20 mg/dl
URIC ACID	4.4 mg dl	2.0 – 7.2 mg/dl

LIVER PROFILE:

S.BILIRUBIN TOTAL	0.6mg/dl	0.0 – 1.0 mg/dl
S.BILIRUBIN DIRECT	0.2 mg/dl	0.0 – 0.2 mg/dl
S.BILIRUBIN INDIRECT	0.4mg/dl	0.1 – 1.0 mg/dl
S G O T	17.0 IU/L	8 – 37 IU/L
S G P T	22.0 IU/L	6 – 40 IU/L
ALKALINE PHOSPHATE	98.0 IU/L	60 – 140 IU/L
TOTAL PROTEINS	6.7gm/dl	6.0 – 8.5 gm/dl
Serum ALBUMIN	4.1 gm/dl	3.8 – 5.0 gm/dl
GLOBULIN	2.6gm/dl	2.3 - 3.5 gm/dl
G G P T	18.0 U/L	20 – 45 U/L


HEBSUR HOSPITAL
 Deshpande Nagar,
 HUBLI-580 029.
 Ph: 0836-2355699, 4250871





DISHA

Direction for Better Health

DIAGNOSTICS

Fully Computerized Diagnostic Centre

HEBSUR HOSPITAL

Opp. State Bank of India,
Deshpande Nagar, HUBLI.
Ph: (Hospital) 0836-2355699
Lab - 9035071970
Email: disha2001diagnostics@gmail.com

CLIENT NAME: Mrs : SUJATA NARAGUND

DATE 09.12.2023

AGE / GENDER : 47/FEMALE

LAB REG NO : 841/23

COMPLETE HEMOGRAM

HAEMOGLOBIN	11.5gm/dl	12.5 – 15.0 gm/dl
TOTAL WBC COUNT	7,300 cells/cumm	4,000 – 10,000 cells/cumm

WBC DIFFERENTIAL COUNT:

NEUTROPHIL	60%	40 – 75 %
LYMPHOCYTES	36%	25 – 45 %
EOSINOPHILS	04%	01 – 05 %
MONOCYTES	00 %	02 – 08 %
BASOPHILS	00 %	00 – 01%

R B C COUNT 4.6/cumm 4.5 – 5.5 million/cumm

PLATELET COUNT 3.8 lakh /cumm 1.5 – 4.0 lakh/cumm

E S R 50mm at 1st hr 00 – 15 mm at 1st hr

PACKED CELL VOLUME (PCV) 40.0 % 37 – 49 %

M C V 86.9 l 80 – 100 fl

M C H 27.2pg 27 – 32 pg

M C H C 28.5 gm/dl 32 – 38 gm/dl

BLOOD GROUP/RH: "O" NEGATIVE


HEBSUR HOSPITAL
Deshpande Nagar,
HUBLI-580 029.
Ph: 0836-2355699, 4250871





DISHA

Direction for Better Health

DIAGNOSTICS

Fully Computerized Diagnostic Centre

HEBSUR HOSPITAL

Opp. State Bank of India,
Deshpande Nagar, HUBLI.
Ph: (Hospital) 0836-2355699
Lab - 9035071970
Email: disha2001diagnostics@gmail.com

CLIENT NAME: Mrs : SUJATA NARAGUND

DATE 09.12.2023

AGE /GENDER : 47/FEMALE

LAB REG NO : 841/23

LIPID PROFILE

CHOLESTEROL:	159.0 mg/dl	Desirable: less than 200.0 mg/dl Borderline: 200 – 240 mg/dl Elevated: More than 240.0 mg/dl
TRIGLYCERIDES:	118.0 mg/dl	Desirable: less than 200.0 mg/dl Borderline: 150 – 199.0 mg/dl Elevated: More than 200.0 mg/dl
H D L	44.0 mg%	Border line: 35 – 60 mg/dl Desirable: More than 60.0 mg/dl High risk : Less than 35.0 mg/dl
L D L	102.0 mg%	Desirable: less than 130.0 mg/dl Borderline: 130 – 159.0 mg/dl Elevated: More than 160.0 mg/dl
V L D L	22.0 mg%	Less than 30.0 mg/dl
CHOL / HDL RATIO	3.6	Desirable: 3.3 – 4.4 Borderline: 4.4 - 11 Elevated: More than 11.0
LDL / HDL RATIO	2.6	Desirable 0.5 – 3.0 Borderline: 3.1 – 6.0 Elevated: More than 6.0

HEBSUR HOSPITAL

Deshpande Nagar,
HUBLI-580 029,
Ph: 0836-2355699, 4250871





DISHA

Direction for Better Health

DIAGNOSTICS

Fully Computerized Diagnostic Centre

HEBSUR HOSPITAL

Opp. State Bank of India,
Deshpande Nagar, HUBLI.
Ph: (Hospital) 0836-2355699
Lab - 9035071970
Email: disha2001diagnostics@gmail.com

CLIENT NAME: Mrs : SUJATA NARAGUND

DATE 09.12.2023

AGE /GENDER : 47/FEMALE

LAB REG NO : 841/23

URINE EXAMINATION

PHYSICAL

VOLUME	1.0 ml
APPEARANCE	AMBER YELLOW
SEDIMENT	CLEAR
REACTION	ACIDIC
SPECIFIC GRAVITY	1.011

CHEMICAL

PROTEIN	ABSENT
GLUCOSE	ABSENT
KETONES	ABSENT
OCCULT BLOOD	ABSENT
BILE SALT	ABSENT
BILE PIGMENT	ABSENT
UROBILINOGEN	ABSENT

MICROSCOPY

PUS CELLS	OCCASIONAL
RBC	NIL
CASTS	NIL
CRYSTALS	NIL
EPITHELIAL CELLS	NIL

STOOL EXAMINATION

APPEARANCE SEMI SOLID

MICROSCOPY:

PUS CELLS	NIL
RBC	NIL
OVA, CYST	NIL

R.S.
HEBSUR HOSPITAL

Deshpande Nagar,
HUBLI-580 029.
Ph: 0836-2355699, 4250871



Date/Time: 2023-12-09 12:00:01

ID :
Name: sujata naragund
Sex : Female
Divisions:

Age : 47 Years
BP : 140/100 mmHg
Bed No. :

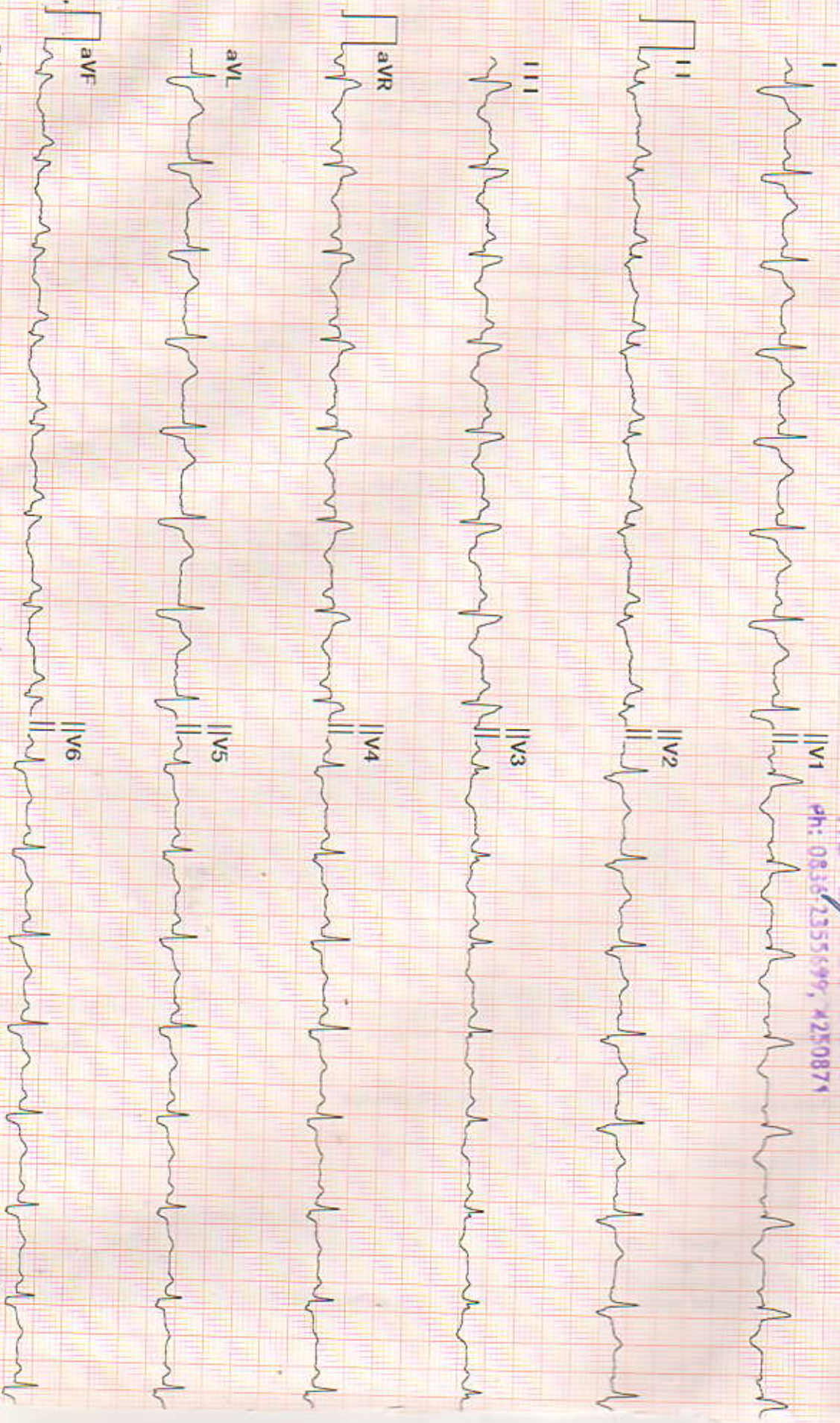
Hospital: hebsur hospital
Height : 163 cm
Weight : 80 kg
Hospital No. :

ECG: Normal.

HR 93 bpm
P Dur/PR int 99/145ms
QRS Dur 126ms
QT/QTc int 360/447 ms
P/QRS/T axis 69/157/-3°

RV5/SV1 amp 0.398/0.075mV
RV5+SV1 amp 0.473mV
RV6/SV2 amp 0.433/0.308mV

HEBSUR HOSPITAL
Postgraduate Deptt.,
MURTI 580 029.
Ph: 0836 2355699, 4250871



Diagnosis for reference, ask your doctor to confirm
AUTO PRINT 6X2 93bpm 10 mm/mV 0.50Hz-25Hz 25 mm/sec

Confirmed By:

Echocardiography and Colour Doppler Study Report

Patient Name: <i>Sujata. PV</i>	Age- <i>47</i> Years	Sex- <i>F</i>
Ref By: <i>N. Hebsur</i> Thanks for referral	Date: <i>9/12/23</i>	

M Mode	Normal Range		Normal Range
IVSd : <i>1.0</i> cm	0.6-1.0 cm	RVDd : <i>1.7</i> cm	0.7-2.1 cm
LVIDd : <i>4.4</i> cm	3.8-5.8 cm	Aorta : <i>2.9</i> cm	2.3-3.2 cm
Pwd : <i>1.0</i> cm	0.6-1.0 cm	LA : <i>3.3</i> cm	1.8-4.0 cm
LVIDs : <i>2.8</i> cm	2.2-4.0 cm	EF : <i>60</i> %	52-74 %

Chambers: Left ventricle: Normal.

Left Atrium: Normal. Right Atrium: Normal. Right Ventricle: Normal.

Valves:

Mitral Valve: Normal.

Aortic Valve: Normal.

Pulmonary Valve: Normal.

Tricuspid Valve: Normal.

Septae: Normal.

Great Arteries: Normal.

Aorta: Normal.

Pulmonary Artery: Normal.

Doppler Study:

Mitral Valve: Normal.

Aortic Valve: Normal.

Tricuspid Valve: Normal.

Pulmonary Valve: Normal.

LV Systolic function: Normal.

LV Diastolic dysfunction:

LV wall motion Abnormality: Normal.

Clots/Vegetation: -- NO.

IMPRESSION

*Normal Study
@ LVEF 60%
no RWMA
no valvular abnormality*

HEBSUR HOSPITAL

Deshpande Nagar,

HUBLI-580 029.

Ph: 0836-2355699, 42508

Dr. N. L. Hebsur

M.S.

Medical Officer,

HEBSUR HOSPITAL,

Deshpande Nagar, HUBLI-29.

Reg. No. 31764

DR. SHARAT. M. VIJAPUR

M.B.B.S., M.D.

D.M. CARDIOLOGY, FSCAI

Consultant Interventional Cardiologist

www.securehospital.in

NAME : **Sujata Naragund**
AGE/SEX : 47 Years / Female
LAB NO : LL-4421-23
REF BY : Dr. N I Hebsur

DATE OF REGISTRATON : 09/12/2023
DATE OF COLLECTION : 09/12/2023 16:39
DATE OF REPORT : 11/12/2023 20:21

GYNAECOLOGICAL EXFOLIATIVE CYTOLOGY

NO: OF SLIDE : 02


ADEQUACY : ADEQUATE

SATISFACTORY : Endocervical cells and squamous metaplastic cells seen.

MICROSCOPY : Smears show superficial, intermediate cells seen, along with moderate inflammatory cell infiltrate composed of neutrophils and few lymphocytes. Background shows hemorrhage. Few reactive squamous cells seen.

GENERAL INFORMATION - NEGATIVE FOR INTRAEPITHELIAL LESION OR MALIGNANCY WITH REACTIVE ATYPIA ASSOCIATED WITH INFLAMMATION

NOTE : Reported as per - The 2014 Bethesda system for reporting cervical cytology.



Dr. Bhavana Pratik Khona
MBBS,MD(Path)
Consultant Pathologist
Hans Hi-Tech Lab



Dr. Pradeep S. Khona
MBBS,DCP
Senior Pathologist
Hans Hi-Tech Lab


HEBSUR HOSPITAL
Deshpande Nagar,
HUBLI-580 029.
Ph: 0836-2355699, 4250871