



DEPARTMENT OF PATHOLOGY

Patient Name : Mrs. SURABHI YADAV
MR No : 29117
Age/Sex : 37 Years 11 Months 16 Days / Female
Type : OPD
TPA/Corporate : MEDIWHEEL

Bill Date : 16/12/2023
Reporting Date : 16/12/2023
Sample ID : 54913
Bill/Req. No. : 23073052
Ref Doctor : Dr. CONSULTANT

Test	Result	Bio. Ref. Interval	Units
HB A1C GLYCOSYLATED HAEMOGLOBIN			
HBA1C	5.4		%

Note : Non-Diabetics 4.0 - 6.0 %

In Diabetics
Good Control 6.1 - 6.8 %
Fair Control 6.9 - 7.6 %
Poor Control > 7.6 %

***** END OF THE REPORT *****

OUT SOURCE
PARK HOSPITAL
GGN



Sample no.

Dr. VAISHALI YADAV
CONS.PATHOLOGIST

Dr. REETU JADHAV
CONS.PATHOLOGIST

Dr. PARDIP KUMAR
MICROBIOLOGIST & ICO

S.C. GAUR
LAB INCHARGE

USER NM SUNIL

(This is only professional opinion and not the diagnosis, Please correlate clinically)

J-Block, Sector-10, Near Court, Faridabad - 121004, Haryana
Tel.: 0129-4200000 E-mail : parkfaridabad@gmail.com

West Delhi • South Delhi • Gurgaon • Karnal • Panipat • Hodal • Ambala • Behror



DEPARTMENT OF PATHOLOGY

Patient Name : Mrs. SURABHI YADAV	Bill Date : 16/12/2023
MR No : 29117	Reporting Date : 16/12/2023
Age/Sex : 37 Years 11 Months 16 Days / Female	Sample ID : 54913
Type : OPD	Bill/Req. No. : 23073052
TPA/Corporate : MEDIWHEEL	Ref Doctor : Dr.CONULTANT

Test	Result	Bio. Ref. Interval	Units
PAP SMEAR (FOR ONLY FEMALE)			
PAP SMEAR	C/516/2023 Convention Pap smear.		
SPECIMEN TYPE	PAP SMEAR		
GROSS	Received 02 unstained slide . All slide were stained and examined.		
SPECIMEN ADEQUACY	Satisfactory for evaluation.		
TRANSFORMATION ZONE	Present		
MICROSCOPY	Smear shows benign superficial and intermediate squamous cells which shows mild reactive changes of inflammation. Background consist of polymorphs and lactobacilli . No atypical cell / granuloma seen. No candida / trichomonas or other organism seen.		
IMPRESSION :-	Negative For Intraepithelial lesion or Malignancy .		
NOTE	Report according to The Bethesda system for Reporting cervical cytology , 2014.		

***** END OF THE REPORT *****



Sample no.

Dr. VAISHALI YADAV Dr.REETU JADHAV Dr. PARDIP KUMAR S.C.GAUR
CONS.PATHOLOGIST CONS.PATHOLOGIST MICROBIOLOGIST & ICO LAB INCHARGE USER NM SUNIL

(This is only professional opinion and not the diagnosis, Please correlate clinically)

J-Block, Sector-10, Near Court, Faridabad - 121004, Haryana
Tel.: 0129-4200000 E-mail : parkfaridabad@gmail.com



DEPARTMENT OF PATHOLOGY

Patient Name :	Mrs. SURABHI YADAV	Bill Date :	16/12/2023
MR No :	29117	Reporting Date :	16/12/2023
Age/Sex :	37 Years 11 Months 16 Days / Female	Sample ID :	54913
Type :	OPD	Bill/Req. No. :	23073052
TPA/Corporate :	MEDIWHEEL	Ref Doctor :	Dr.CONULTANT

Test	Result	Bio. Ref. Interval	Units
------	--------	--------------------	-------

URINE ROUTINE AND MICROSCOPY

PHYSICAL CHARACTERSTICS

QUANTITY	20.0 ML	5 - 100	ML
COLOUR	Pale Yellow		
TURBIDITY	Turbid	clear	
SPECIFIC GRAVITY	1.005	1.003 - 1.030	
PH	6.0	Acidic	

CHEMICAL EXAMINATION-1

URINE PROTEIN	NIL	NIL
GLUCOSE	NIL	NIL

MICRO.EXAMINATION

PUS CELL	5 - 6/HPF		CELLS/HPF
RED BLOOD CELLS	Nil	0-2	CELLS/HPF
EPITHELIAL CELLS	6-8/HPF	0-5	CELLS/HPF
CASTS	NIL	NIL	CELLS/HPF
CRYSTALS	NIL	NIL	CELLS/HPF
OTHER	YEAST / BUDDING CELLS PRESENT.		

***** END OF THE REPORT *****



Sample no.

Dr. VAISHALI YADAV Dr. REETU JADHAV Dr. PARDIP KUMAR S.C. GAUR
CONS.PATHOLOGIST CONS.PATHOLOGIST MICROBIOLOGIST & ICO LAB INCHARGE USER.NM PRIYANKA

(This is only professional opinion and not the diagnosis, Please correlate clinically)

J-Block, Sector-10, Near Court, Faridabad - 121004, Haryana



DEPARTMENT OF PATHOLOGY

Patient Name : Mrs. SURABHI YADAV
 MR No : 29117 Bill Date : 16/12/2023
 Age/Sex : 37 Years 11 Months 16 Days / Female Reporting Date : 17/12/2023
 Type : OPD Sample ID : 54913
 TPA/Corporate : MEDIWHEEL Bill/Req. No. : 23073052
 Ref Doctor : Dr.CONSULTANT

Test	Result	Bio. Ref. Interval	Units
------	--------	--------------------	-------

THYROID PROFILE

TRI-IODOTHYRONINE (T3)	0.82	0.60 - 1.81	ng/ml
THYROXINE (T4)	10.0	5.01 - 12.45	µg/dL
THYROID STIMULATING HORMONE	6.69 H <i>H</i>	0.5-5.50	µIU/ml

***** END OF THE REPORT *****

OUT SOURCE
PARK HOSPITAL
GGN



Sample no.

Dr. VAISHALI YADAV Dr.REETU JADHAV Dr. PARDIP KUMAR S.C.GAUR
 CONS.PATHOLOGIST CONS.PATHOLOGIST MICROBIOLOGIST & ICO LAB INCHARGE USER NM SUNIL

(This is only professional opinion and not the diagnosis, Please correlate clinically)

J-Block, Sector-10, Near Court, Faridabad - 121004, Haryana
 Tel.: 0129-4200000 E-mail : parkfaridabad@gmail.com



DEPARTMENT OF PATHOLOGY

Patient Name : Mrs. SURABHI YADAV
MR No : 29117
Age/Sex : 37 Years 11 Months 16 Days / Female
Type : OPD
TPA/Corporate : MEDIWHEEL

Bill Date : 16/12/2023
Reporting Date : 16/12/2023
Sample ID : 54913
Bill/Req. No. : 23073052
Ref Doctor : Dr.CONULTANT

Test	Result	Bio. Ref. Interval	Units
CBC			
HAEMOGLOBIN	12.7	12 - 15	gm/dL
PACKED CELL VOLUME	39.4	35.0 - 50.0	%
RED BLOOD CELL COUNT	4.21	3.5 - 5.5	millions/ μ L
MEAN CORPUSCULAR VOLUME	93.5	83 - 101	fL
MEAN CORPUSCULAR HAEMOGLOBIN	30.2	27 - 31	pg
MEAN CORPUSCULAR HB CONC	32.2 L	33 - 37	g/dl
RDW	12.9	11.6 - 14.5	%
TOTAL LEUCOCYTE COUNT	5970	4000-11000	/ μ L
DIFFERENTIAL COUNT			
NEUTROPHILS	50	40.0 - 80.0	%
LYMPHOCYTES	40	20 - 40	%
MONOCYTES	07	2.0 - 10.0	%
EOSINOPHILS	03	0.0 - 5.0	%
BASOPHILS	00	0.0 - 2.0	%
PLATELET COUNT	2.00	1.50 - 4.50	lac/cumm

***** END OF THE REPORT *****



Sample no.

Dr. VAISHALI YADAV Dr.REETU JADHAV Dr. PARDIP KUMAR S.C.GAUR
CONS.PATHOLOGIST CONS.PATHOLOGIST MICROBIOLOGIST & ICO LAB INCHARGE USER NM PRIYANKA

(This is only professional opinion and not the diagnosis, Please correlate clinically)

J-Block, Sector-10, Near Court, Faridabad - 121004, Haryana

Tel.: 0129-4200000 E-mail : parkfaridabad@gmail.com



DEPARTMENT OF PATHOLOGY

Patient Name : Mrs. SURABHI YADAV
MR No : 29117
Age/Sex : 37 Years 11 Months 16 Days / Female
Type : OPD
TPA/Corporate : MEDIWHEEL

Bill Date : 16/12/2023
Reporting Date : 16/12/2023
Sample ID : 54913
Bill/Req. No. : 23073052
Ref Doctor : Dr. CONSULTANT

Test	Result	Bio. Ref. Interval	Units
------	--------	--------------------	-------

BLOOD GROUPING AND rh FACTOR

BLOOD GROUP	" B " Rh POSITIVE		
-------------	-------------------	--	--

***** END OF THE REPORT *****



Sample no.

Dr. VAISHALI YADAV Dr. REETU JADHAV Dr. PARDIP KUMAR S.C. GAUR
CONS. PATHOLOGIST CONS. PATHOLOGIST MICROBIOLOGIST & ICO LAB INCHARGE USER NM PRIYANKA

(This is only professional opinion and not the diagnosis. Please correlate clinically)

J-Block, Sector-10, Near Court, Faridabad - 121004, Haryana

Tel.: 0129-4200000 E-mail : parkfaridabad@gmail.com



DEPARTMENT OF PATHOLOGY

Patient Name :	Mrs. SURABHI YADAV	Bill Date :	16/12/2023
MR No :	29117	Reporting Date :	16/12/2023
Age/Sex :	37 Years 11 Months 16 Days / Female	Sample ID :	54913
Type :	OPD	Bill/Req. No. :	23073052
TPA/Corporate :	MEDIWHEEL	Ref Doctor :	Dr.CONSULTANT

Test	Result	Bio. Ref. Interval	Units
BLOOD SUGAR FASTING			
PLASMA GLUCOSE FASTING	87.78	60 - 110	mg/dl

***** END OF THE REPORT *****



Sample no.

Dr. VAISHALI YADAV Dr.REETU JADHAV Dr. PARDIP KUMAR S.C.GAUR
CONS.PATHOLOGIST CONS.PATHOLOGIST MICROBIOLOGIST & ICO LAB INCHARGE USER NM/ PRIYANKA

(This is only professional opinion and not the diagnosis, Please correlate clinically)

J-Block, Sector-10, Near Court, Faridabad - 121004, Haryana
Tel.: 0129-4200000 E-mail : parkfaridabad@gmail.com



DEPARTMENT OF PATHOLOGY

Patient Name : Mrs. SURABHI YADAV
 MR No : 29117
 Age/Sex : 37 Years 11 Months 16 Days / Female
 Type : OPD
 TPA/Corporate : MEDIWHEEL

Bill Date : 16/12/2023
 Reporting Date : 16/12/2023
 Sample ID : 54913
 Bill/Req. No. : 23073052
 Ref Doctor : Dr.CONSULTANT

Test	Result	Bio. Ref. Interval	Units
LFT (LIVER FUNCTION TEST)			
LFT			
TOTAL BILIRUBIN	1.1	0 - 1.2	mg/dL
DIRECT BILIRUBIN	0.4	0 - 0.4	mg/dL
INDIRECT BILIRUBIN	0.7 H <i>H</i>	0.10 - 0.6	mg/dL
SGOT (AST)	22	0 - 45	U/L
SGPT (ALT)	39	0 - 45	U/L
ALKALINE PHOSPHATASE	109.9	30 - 170	IU/L
TOTAL PROTEIN	7.7	6.4 - 8.0	g/dL
ALBUMIN	4.4	3.3 - 5.5	g/dL
GLOBULIN	3.3	2.3 - 4.5	g/dL
A/G RATIO	1.33	1.1 - 2.2	

***** END OF THE REPORT *****



Sample no.

Dr. VAISHALI YADAV Dr.REETU JADHAV Dr. PARDIP KUMAR S.C.GAUR
 CONS.PATHOLOGIST CONS.PATHOLOGIST MICROBIOLOGIST & ICO LAB INCHARGE USER NM PRIYANKA

(This is only professional opinion and not the diagnosis, Please correlate clinically)

J-Block, Sector-10, Near Court, Faridabad - 121004, Haryana
 Tel.: 0129-4200000 E-mail : parkfaridabad@gmail.com



DEPARTMENT OF PATHOLOGY

Patient Name : Mrs. SURABHI YADAV
 MR No : 29117
 Age/Sex : 37 Years 11 Months 16 Days / Female
 Type : OPD
 TPA/Corporate : MEDIWHEEL

Bill Date : 16/12/2023
 Reporting Date : 16/12/2023
 Sample ID : 54913
 Bill/Req. No. : 23073052
 Ref Doctor : Dr.CONSULTANT

Test	Result	Bio. Ref. Interval	Units
KFT (RENAL PROFILE)			
KFT			
SERUM UREA	32	10 - 45	mg/dL
SERUM CREATININE	0.9	0.4 - 1.4	mg/dL
SERUM URIC ACID	5.6	2.5 - 7.0	mg/dL
SERUM SODIUM	146	136 - 148	mmol/L
SERUM POTASSIUM	3.9	3.5 - 5.5	mmol/L
CHLORIDE	101.0	96 - 106	mmol/L

***** END OF THE REPORT *****



Sample no.

Dr. VAISHALI YADAV Dr. REETU JADHAV Dr. PARDIP KUMAR S.C. GAUR
 CONS.PATHOLOGIST CONS.PATHOLOGIST MICROBIOLOGIST & ICO LAB INCHARGE USER NM PRIYANKA

(This is only professional opinion and not the diagnosis, Please correlate clinically)

J-Block, Sector-10, Near Court, Faridabad - 121004, Haryana
 Tel.: 0129-4200000 E-mail : parkfaridabad@gmail.com



DEPARTMENT OF PATHOLOGY

Patient Name : Mrs. SURABHI YADAV
MR No : 29117
Age/Sex : 37 Years 11 Months 16 Days / Female
Type : OPD
TPA/Corporate : MEDIWHEEL
Bill Date : 16/12/2023
Reporting Date : 16/12/2023
Sample ID : 54913
Bill/Req. No. : 23073052
Ref Doctor : Dr. CONSULTANT

Test	Result	Bio. Ref. Interval	Units
LIPID PROFILE			
LIPID PROFILE			
TOTAL CHOLESTEROL	148.72	120.0 - 200.0	mg/dL
SERUM TRIGLYCERIDES	93.96	40.0 - 160.0	mg/dl
HDL-CHOLESTEROL	39.82	30 - 70	mg/dl
VLDL CHOLESTEROL	18.79	6 - 32	mg/dL
LDL	90.11	50 - 135	mg/dl
LDL CHOLESTEROL/HDL RATIO	2.26	1.0 - 3.0	mg/dL
TOTAL CHOLESTEROL/HDL RATIO	3.73	2.0 - 5.0	mg/dl

***** END OF THE REPORT *****



Sample no.

Dr. VAISHALI YADAV Dr. REETU JADHAV Dr. PARDIP KUMAR S.C. GAUR
 CONS. PATHOLOGIST CONS. PATHOLOGIST MICROBIOLOGIST & ICO LAB INCHARGE USER NM / PRIYANKA

(This is only professional opinion and not the diagnosis, Please correlate clinically)

J-Block, Sector-10, Near Court, Faridabad - 121004, Haryana
 Tel.: 0129-4200000 E-mail : parkfaridabad@gmail.com



DEPARTMENT OF RADIOLOGY

Patient Name	Mrs. SURABHI YADAV	Billed Date	: 16/12/2023	10.02 AM
Reg No	29117	Reported Date	: 16/12/2023	
Age/Sex	37 Years 11 Months 16Days / Female	Req. No.	: 23073052	
Type	OPD	Consultant Doctor	: Dr. CONSULTANT	

USG WHOLE ABDOMEN

LIVER : The liver is enlarged in size (18.1cm), normal in shape and echotexture. No evidence of any focal lesion. IHBR is not dilated.

GALL BLADDER: The gall bladder is not visualized (Post operative status). The common bile duct is normal.

SPLEEN :The spleen is normal in size and shape. Its echotexture is homogeneous. No evidence of focal lesion is noted.

PANCREAS :The pancreas is normal in size, shape, contours and echotexture.

BILATERAL KIDNEYS : The bilateral kidneys are normal in size and echotexture. Cortico-medullary differentiation is maintained. There is no evidence of obvious calculus or hydronephrosis seen.

URINARY BLADDER :The urinary bladder is well distended. Wall thickness within normal limits. No evidence of calculus is seen. No evidence of mass or diverticulum is noted.

UTERUS: The uterus is normal in size, shape and echopattern. Endometrium echo is normal in thickness (8.3mm).

A cystic lesion of approx size ~ 8x4.6cm is seen in left ovary. The lesion shows hyperechoic areas in it. Another small hyperechoic lesion measuring ~ 15x14mm is seen in right ovary.

No free fluid is seen in peritoneal cavity.

No evidence of obvious retroperitoneal or mesenteric lymphadenopathy is seen.

IMPRESSION: USG WHOLE ABDOMEN REVEALS

Hepatomegaly.

Bilateral ovarian dermoid cysts (L>R).

DR BINOD KR CHAUDHARY
MBBS, MD
CONSULTANT RADIOLOGIST

(This is only professional opinion and not the diagnosis, Please correlate clinically)

J-Block, Sector-10, Near Court, Faridabad - 121004, Haryana

Tel : 0129-4200000 E-mail : info@parkhospital.com



ECHO REPORT

Name of the patient: MRS. SURABHS YADAV Age: 3A Sex: Male Female
 UHID No: 2911A IPD No: 230A3052 Date: 16/12/2018
 Refer By Doctor: DR R. Arora

LVEF% 60%

2D ECHO

> Mitral Value Normal Pulmonary Value H Pulm
 > Artery H
 > Aortic avive H Tricuspid valve H

2D RWMA

> NO RWMA (Regional wall motion abnormality) at rest

COLD DOPPLER

> NO Significant Vavular stenosis / Regurgiation

COMMENTS AND SUMMARY

> All cardiac chambers of H size and shape NO dilatation or hypertrophy.

> NO RWMA (Regional wall motion abnormality) at rest

> NO Cloth / Vegetation/ pericardial effusion

> LV 60% Systolic function

> NO Significant Vavular stenosis / Regurgiation

Final Impression

> EF at Rest 60%

COMMENTS

2DECHO & Color Doppler Study wnl

Consultant Cardiology

Doctor Name : Dr.
Date :

[Signature]

Dr. Rakesh Kumar Arora
MBBS, MD (Cardiology)
Signature :
Time :
Consultant Cardiology
Park Hospital, Faridabad

J BLOCK SEC-10, FARIDABAD
29117/MRS. SURABHI YADAV
37 Yrs/Female
74 Kg/155 Cms
Date: 16-Dec-2023 12:18:31 PM

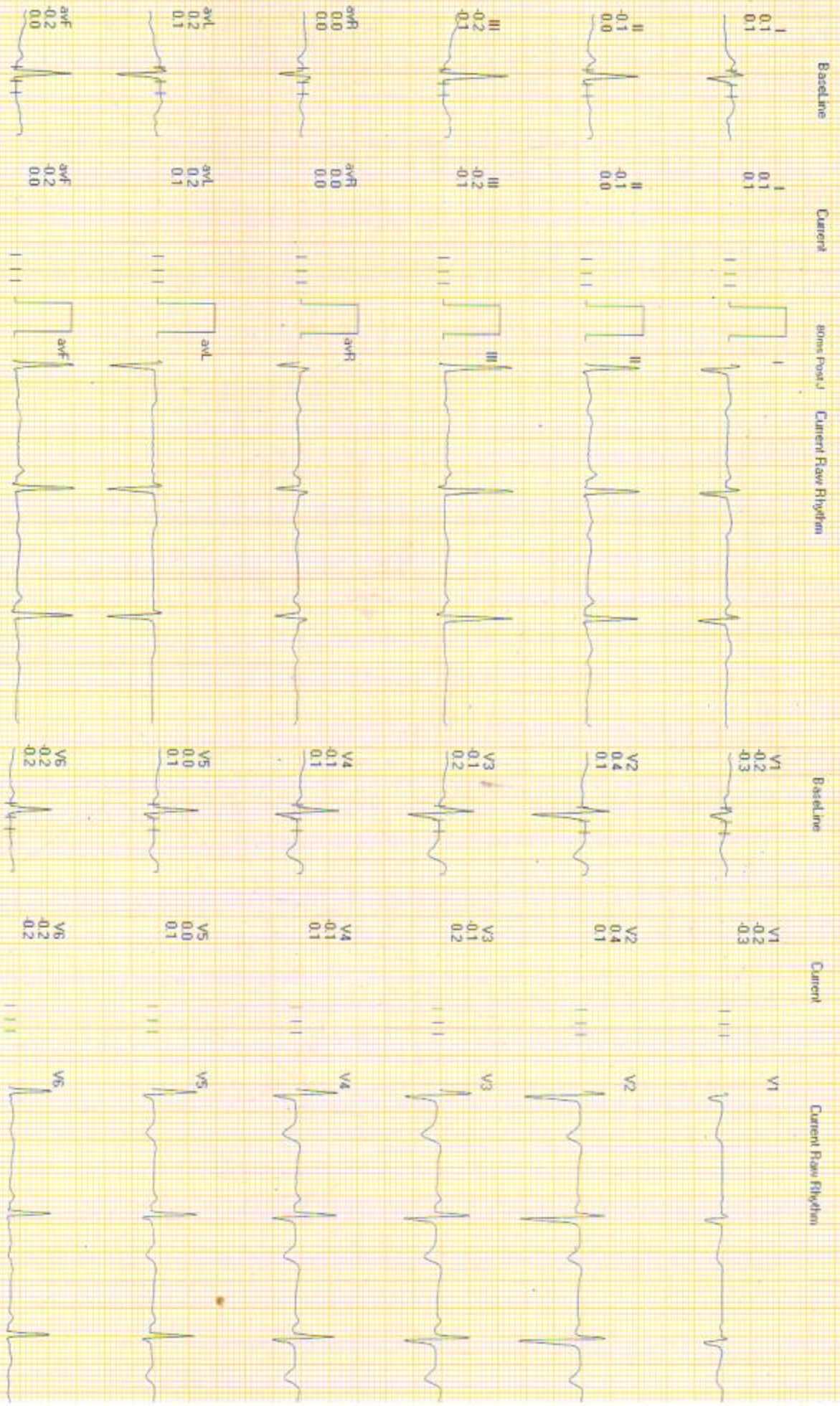
HR: 70 bpm
METS: 1.0
BP: 120/90

MPHR: 38% of 183
Speed: 0.0 mph
Grade: 0.0%

Raw ECG
□□□□□□□□□□
(0.05-100)Hz

Ex Time 00:00
BLC: On
Notch: On

ExStt
10.0 mm/mV
25 mm/Sec.





DEPARTMENT OF RADIOLOGY

Patient Name	Mrs. SURABHI YADAV	Billed Date	: 16/12/2023	10.02 AM
Reg No	29117	Reported Date	: 16/12/2023	
Age/Sex	37 Years 11 Months 16Days / Female	Req. No.	: 23073052	
Type	OPD	Consultant Doctor	: Dr. CONSULTANT	

X-RAY CHEST AP/PA

Bilateral lungs appears normal.

Both hila are normal in size, have equal density and bear normal relationship.

The heart and trachea are central in position and no mediastinal abnormality is visible.

The cardiac size is normal for patient age and view.

The domes of the diaphragms are normal in position and show smooth outline.

To be correlated clinically

DR BINOD KR CHAUDHARY
MBBS,MD
CONSULTANT RADIOLOGIST



DEPARTMENT OF RADIOLOGY

Patient Name	Mrs. SURABHI YADAV	Billed Date	: 16/12/2023	10.02 AM
Reg No	29117	Reported Date	: 16/12/2023	
Age/Sex	37 Years 11 Months 16Days / Female	Req. No.	: 23073052	
Type	OPD	Consultant Doctor	: Dr. CONSULTANT	

X-RAY CHEST AP/PA

Bilateral lungs appears normal.

Both hila are normal in size, have equal density and bear normal relationship.

The heart and trachea are central in position and no mediastinal abnormality is visible.

The cardiac size is normal for patient age and view.

The domes of the diaphragms are normal in position and show smooth outline.

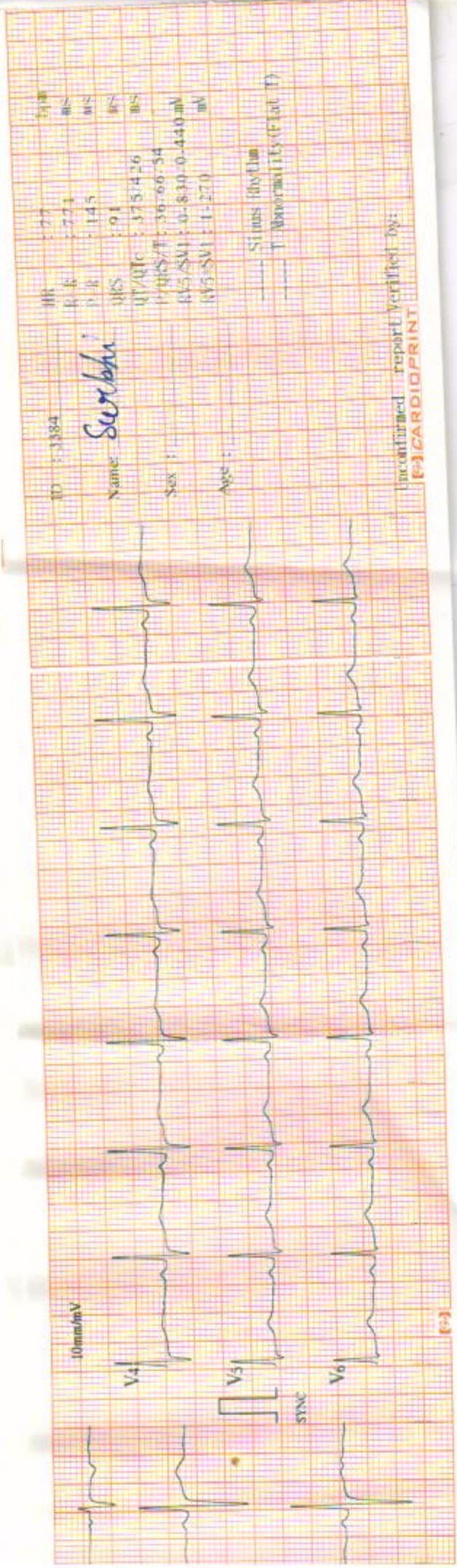
To be correlated clinically

DR BINOD KR CHAUDHARY
MBBS,MD
CONSULTANT RADIOLOGIST

(This is only professional opinion and not the diagnosis, Please correlate clinically)

J-Block, Sector-10, Near Court, Faridabad - 121004, Haryana

Tel.: 0129-4200000 E-mail : parkfaridabad@gmail.com



III : 77
 I : 77
 aVR : 145
 aVL : 91
 aVF : 91
 QT/QTc : 375/426
 PR/PRc : 145/145
 QRS/QT : 91/375
 RV5/SVI : 0.830-0.440 mV
 RV5/SVI : 1.270 mV

ID : 3384
 Name: *Serahi*
 Sex :
 Age :

--- Sinus Rhythm
 --- T Abnormality (Flat T)

Uncalibrated report Verified by:
ECG CARDIOPRINT