


Name : Mr. Manjunath M	Age : 36 Y	UHID :CJPN.000008160
Address : No 2 Vismaya 1st floor 1st cross 3rd main Bilekahalli Bannerghatta Road	Sex : M	 *CJPN.000008160*
Plan : ARCOFEMI MEDIWHEEL MALE AHC CREDIT PAN INDIA OP AGREEMENT		OP Number :CJPNOPV185962 Bill No :CJPN-OCR-68646 Date : 16.01.2024 09:03

Sno	Service Type/ServiceName	Department
1	ARCOFEMI - MEDIWHEEL - FULL BODY ANNUAL PLUS MALE - 2D ECHO - PAN INDIA - FY2324	
1	GAMMA GLUTAMYL TRANSFERASE (GGT)	
2	2 D ECHO <u>0</u> .	
3	LIVER FUNCTION TEST (LFT)	
4	GLUCOSE, FASTING	
5	HEMOGRAM + PERIPHERAL SMEAR	
6	DIET CONSULTATION - <u>(16)</u>	
7	COMPLETE URINE EXAMINATION	
8	URINE GLUCOSE (POST PRANDIAL) X	
9	PERIPHERAL SMEAR	
10	ECG	
11	RENAL PROFILE/RENAL FUNCTION TEST (RFT/KFT)	
12	DENTAL CONSULTATION <u>B-22</u>	
13	GLUCOSE, POST PRANDIAL (PP), 2 HOURS (POST MEAL) - <u>11:15</u> by <u>11:00</u>	
14	URINE GLUCOSE (FASTING)	
15	HbA1c, GLYCATED HEMOGLOBIN	
16	X-RAY CHEST PA	
17	ENT CONSULTATION <u>→</u>	
18	FITNESS BY GENERAL PHYSICIAN <u>0</u>	
19	BLOOD GROUP ABO AND RH FACTOR	
20	LIPID PROFILE	
21	BODY MASS INDEX (BMI)	
22	OPHTHAL BY GENERAL PHYSICIAN <u>F2-3</u>	
23	ULTRASOUND - WHOLE ABDOMEN <u>10-30 min.</u>	
24	THYROID PROFILE (TOTAL T3, TOTAL T4, TSH)	

Audio - 2 16
Physio - 04

B.P - 127/91 mmHg
wt - 69.4 kg
ht - 177 cm
waist - 86 cm
hip - 96 cm
pulse - 86 bpm

0-6
0-6
0-6

Name - Manjunatha M

Age - 36yrs

Date - 16/01/24

Height :	Weight :	BMI :	Waist Circum :
Temp :	Pulse :	Resp :	B.P :

**General Examination / Allergies
History**

Clinical Diagnosis & Management Plan

C/O - Routine
Eye checkup

H/O PUP - No

H/O Eye Sx - No

Unum { 616 NG
616 NG

Eurotopia

Colour vision is normal in SE

Follow up date:

After 6 months

Doctor Signature

Mr manjunath m
ID: cph08160

36 Years 177 cm Male
69.0 kg

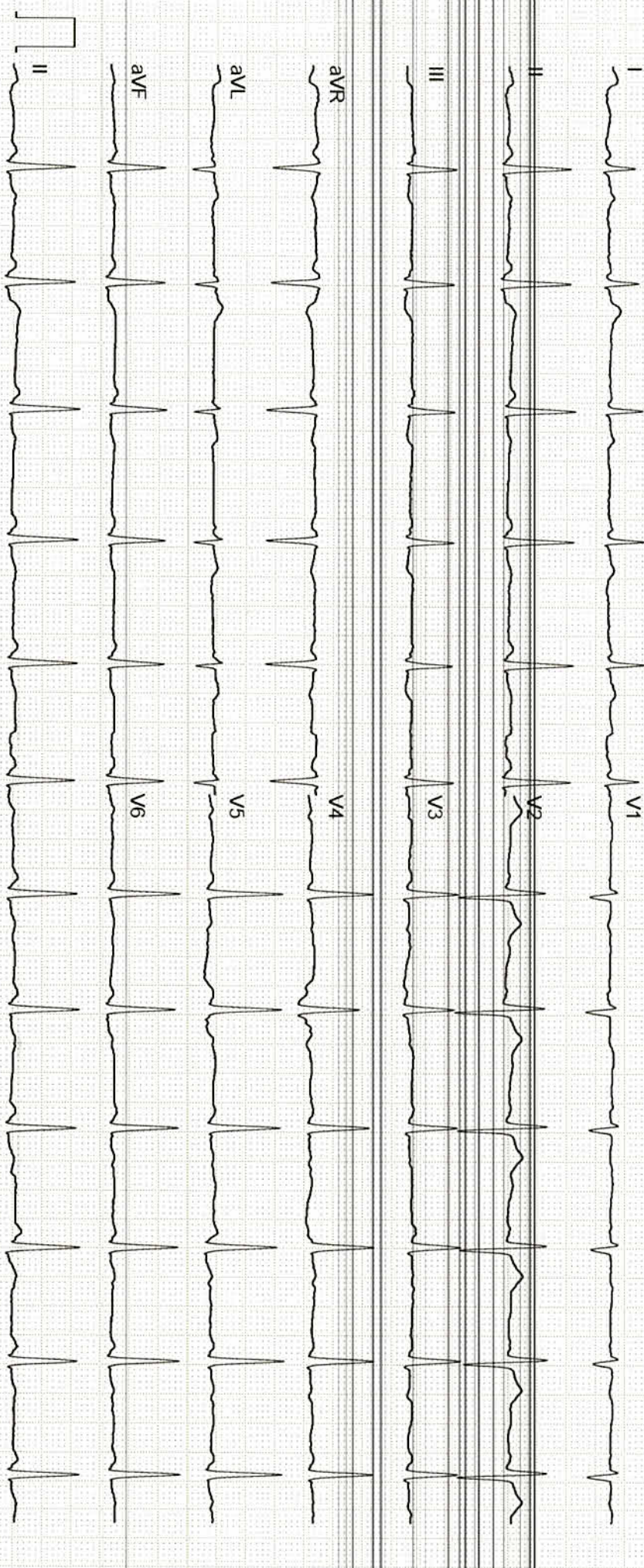
16.01.2024 10:16:25
Apollo Clinic
J.P. Nagar
Bangalore

QRS	94 ms
QT / QTcBaz	332 / 368 ms
PR	120 ms
P	102 ms
RR / PP	812 / 810 ms
P / QRS / T	43 / 64 / 23 degrees

Normal sinus rhythm
Nonspecific T wave abnormality
Abnormal ECG

74 bpm
127 / 91 mmHg

WAS
[Signature]



Unconfirmed

Mr. Mayunath M

16.11.2024

Dr. Shweta Gadge

Height :	Weight :	BMI :	Waist Circum :
Temp :	Pulse :	Resp :	B.P :

General Examination / Allergies
History

Clinical Diagnosis & Management Plan

Came for health check up

no SMT complaints

As.

Gen:- B/L Intact
119

Throat:- (A)

nose: (A)

Ex

No SMT abnormality seen at present

Follow up date:

Doctor Signature

NAME: Mr. MANJUNATHA M AGE: 36 YRS/ M DATE: 16 /01/2024 CJPN : 8160

2D ECHO WITH COLOR DOPPLER

Ao Diam : 3.1cm , LA Diam : 2.8 cm,
IVSd : 1.9cm , IVSs:1.2 cm, LVIDd :3.2cm , LVIDs : 2.3 cm LVPWd :0.9cm ,
LVPWS : 1.1 cm , EF – 70% , FS – 39% , RVIDd – 1.1cm

2D VALVES

MITRAL VALVE -----: NORMAL
TRICUSPID VALVE-----: NORMAL
AORTIC VALVE-----: NORMAL
PULMONARY VALVE-----: NORMAL

CHAMBERS

LEFT ATRIUM-----: NORMAL
RIGHT ATRIUM-----: NORMAL
LEFT VENTRICULAR-----: NORMAL
RIGHT VENTRICULAR---: NORMAL

DOPPLER

MV E Vel---- : 0.5 m/s , MV A Vel : 0.5 m/s
TRICUSPID VALVE : NORMAL
PERICARDIUM-----: NORMAL
CLOT/VEGETATION----- : NIL

IMPRESSION

NORMAL VALVES AND CHAMBERS
NORMAL LV SYSTOLIC FUNCTION
NO CLOT /VEGETATION/EFFUSION/PAH
NO REGIONAL WALL MOTION ABNORMALITIES



DR. SHILPA JAYAPRAKASH, MD,DM
CONSULTANT CARDIOLOGIST

