

Name : Mrs. YESHASREE CHINADODDI  
Address : Kondhwa Bk Pune Maharashtra INDIA 411048  
Plan : ARCOFEMI MEDIWHEEL FEMALE AHC  
CREDIT PAN INDIA OP AGREEMENT

Age : 32Y 5M 30D

sex : Female

UHID : CNAL.0000057297



CNAL.0000057297

OP No: CWANOPV239910

Bill No: CWAN-OCR-52084

Date: Sep 14th, 2024, 10:18 AM

Sno.	Service Type/Service Name	Department	
1	ARCOFEMI - MEDIWHEEL - FULL BODY HEALTH ANNUAL PLUS CHECK - FEMALE - 2D ECHO - PAN INDIA - FY2324		
✓ 1	ULTRASOUND - WHOLE ABDOMEN	Ultrasound Radiology	<input type="checkbox"/>
✓ 2	OPHTHAL BY GENERAL PHYSICIAN	Consultation	<input type="checkbox"/>
3	URINE GLUCOSE(POST PRANDIAL)	Clinical Pathology	<input type="checkbox"/>
✓ 4	GAMMA GLUTAMYL TRANSFERASE (GGT)	Biochemistry	<input type="checkbox"/>
✓ 5	HbA1c, GLYCATED HEMOGLOBIN	Biochemistry	<input type="checkbox"/>
6	GYNAECOLOGY CONSULTATION	Consultation	<input type="checkbox"/>
7	DIET CONSULTATION	General	<input type="checkbox"/>
8	BODY MASS INDEX (BMI)	General	<input type="checkbox"/>
✓ 9	ECG	Cardiology	<input type="checkbox"/>
✓ 10	THYROID PROFILE (TOTAL T3, TOTAL T4, TSH)	Biochemistry	<input type="checkbox"/>
✓ 11	2 D ECHO	Cardiology	<input type="checkbox"/>
✓ 12	BLOOD GROUP ABO AND RH FACTOR	Blood Bank	<input type="checkbox"/>
✓ 13	X-RAY CHEST PA	X Ray Radiology	<input type="checkbox"/>
✓ 14	URINE GLUCOSE(FASTING)	Clinical Pathology	<input type="checkbox"/>
15	LBC PAP TEST- PAPSURE	Histopathology	<input type="checkbox"/>
16	FITNESS BY GENERAL PHYSICIAN	Consultation	<input type="checkbox"/>
✓ 17	GLUCOSE, POST PRANDIAL (PP), 2 HOURS (POST MEAL) 2015.	Biochemistry	<input type="checkbox"/>
✓ 18	GLUCOSE, FASTING	Biochemistry	<input type="checkbox"/>
19	ENT CONSULTATION	Consultation	<input type="checkbox"/>
✓ 20	LIPID PROFILE	Biochemistry	<input type="checkbox"/>
✓ 21	DENTAL CONSULTATION	Consultation	<input type="checkbox"/>
✓ 22	HEMOGRAM + PERIPHERAL SMEAR	Haematology	<input type="checkbox"/>
✓ 23	PERIPHERAL SMEAR	Haematology	<input type="checkbox"/>
✓ 24	COMPLETE URINE EXAMINATION	Clinical Pathology	<input type="checkbox"/>
✓ 25	RENAL PROFILE/RENAL FUNCTION TEST (RFT/KFT)	Biochemistry	<input type="checkbox"/>
✓ 26	LIVER FUNCTION TEST (LFT)	Biochemistry	<input type="checkbox"/>

BP - 110/60 mmHg

HT - 155 cm

WT - 56.2 kg

## CERTIFICATE OF MEDICAL FITNESS

This is to certify that I have conducted the clinical examination

of Mrs. Yashashree Chinadoddi on 16/8/2024

After reviewing the medical history and on clinical examination it has been found that he/she is

	Tick
<ul style="list-style-type: none"><li>• Medically Fit</li></ul>	<input checked="" type="checkbox"/>
<ul style="list-style-type: none"><li>• Fit with restrictions/recommendations</li></ul> <p>Though following restrictions have been revealed, in my opinion, these are not impediments to the job.</p> <p>1.....</p> <p>2.....</p> <p>3.....</p> <p>However the employee should follow the advice/medication that has been communicated to him/her.</p> <p>Review after _____</p>	<input type="checkbox"/>
<ul style="list-style-type: none"><li>• Currently Unfit. Review after _____ recommended</li></ul>	<input type="checkbox"/>
<ul style="list-style-type: none"><li>• Unfit</li></ul>	<input type="checkbox"/>

Dr. Mushfiya  
Medical Officer  
The Apollo Clinic, (Location)

*This certificate is not meant for medico-legal purposes*

**DR. MUSHFIYA BAHRAINWALA**  
M.B.B.S  
Reg. No.: 47527  
Apollo Clinic Wandurwarie  
NIBM Road, Kondi wa.

Date : 9/14/2024 Department : General Physician  
 Patient Name : Mrs. YESHASREE CHINADODDI Doctor : Dr. MUSHFIYA BAHRAINWALA  
 UHID : CNAL.0000057297 Registration No. : 2020010062  
 Age / Gender : 32Yrs 5Mths 30Days / Female Qualification : MBBS and PG in Hospital Management  
 Consultation Timing : 10:20 AM

Height : 155 cm.	Weight : 56.2 kg	BMI :	Waist Circum :
Temp :	Pulse :	Resp :	B.P : 110/70 mmHg

**General Examination / Allergies History**

On  
 Thyroidism 25 mcg.

**Clinical Diagnosis & Management Plan**

For AHC  
 - Has had mild act. loss in the past 1 month. Also has polyarthritis.

O/E - CVS  
 CVS  
 Resp. } was  
 Abd }

Adv:- Vit. B12 & D3 levels

DENTAL


O/E - Stains +

Adv - Scaling

**SAMPLE**  
 9763461253  
 Clinic  
 9121226368  
**AT HOME**

**PATHOLOGY COLLECTION**

Follow up date:



Julia  
 Doctor Signature



## Apollo Clinic

### CONSENT FORM

Patient Name: Yeshasree chinadoddi Age: 32

UHID Number: CNAL-0000057297 Company Name: .....

I Mr/Mrs/Ms Yeshasree chinadoddi Employee of .....

(Company) Want to inform you that I am not interested in getting PAP SMEAR (will be

Tests done which is a part of my routine health check package.

And I claim the above statement in my full consciousness.

done at the time of reports collecting)

Patient Signature: Yeshasree

Date: 14/9/24

GE MAC1200 ST CHINADODDI, YESHASREE 000057297, APOLLO CLINIC WANOWRIE  
Female, 32 Years (15.03.1992)

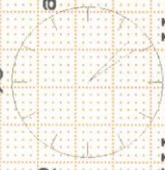
HR 98 bpm

WNL  
*[Signature]*

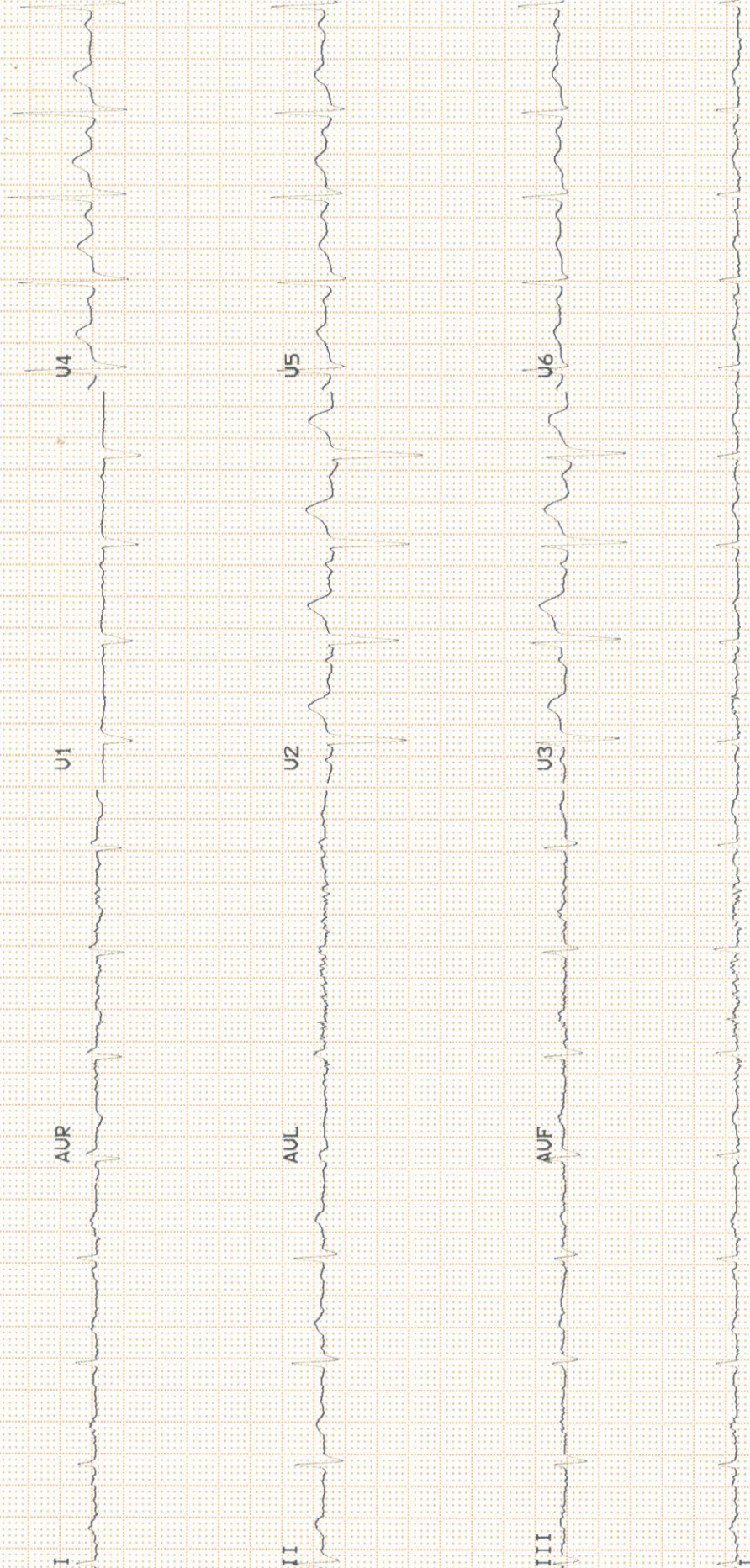
DR. MUSHFIYA BAHRAINWALA  
M.B.B.S  
Reg. No.: 47527  
Apollo Clinic Wanowarie  
XIBM Road, Kondi wa.

Measurement Results:

QRS	: 98 ms	< P
QT/QTcB	: 352 / 451 ms	< T
PR	: 130 ms	< QRS
P	: 84 ms	aUL
RR/PP	: 610 / 550 ms	O I
P/QRS/T	: 55/ 45/ 55 degrees	
QTD/QTcBD	: 36 / 46 ms	III +90 II
Sokolow	: 1.3 mV	aUF
NK	: 14	



Unconfirmed report.



I

II

III

U1

U2

U3

U5

U6

**The Apollo Clinic**

Wanowrie  
Pune-411048

PATIENT NAME :- Mrs. Yeshasree chinadoddi DATE :- 14/9/24

AGE/SEX :- 32/F UHID : 57297

EYE CHECK UP COMPLETE PREMEDICAL/OTHER

	RIGHT EYE	LEFT EYE
Far Vision	6/6 ✓	6/6 ✓
Near Vision	N/6 ✓	N/6 ✓
Anterior Segment Pupil	NORMAL ✓	NORMAL ✓
Fundus	NORMAL	NORMAL
Colour Vision	NORMAL ✓	NORMAL ✓
Iop	NORMAL ✓	NORMAL ✓
Family History/Medical History	NO	

IMPRESSION:- Both eyes normal vision

Advice :-

**Ophthalmologist**

**Apollo Health and Lifestyle Limited**

(CIN - U85110TG2000PLC115819)

Regd. Office: 1-10-60/62, Ashoka Raghupathi Chambers, 5th Floor, Begumpet, Hyderabad, Telangana - 500 016.


Ph No: 040-4904 7777, Fax No: 4904 7744 | Email ID: enquiry@apollohl.com | www.apollohl.com

APOLLO CLINICS NETWORK MAHARASHTRA

Pune (Aundh | Kharadi | Nigdi Pradhikaran | Viman Nagar | Wanowrie)

Online appointments: www.apolloclinic.com

TO BOOK AN APPOINTMENT

 **1860 500 7788**

---

Patient Name	: Mrs. YESHASREE CHINADODDI	Age	: 32Yrs 6Mths 1Days
UHID	: CNAL.0000057297	OP Visit No.	: CWANOPV239910
Printed On	: 16-09-2024 12:57 PM	Advised/Pres Doctor	: --
Department	: Radiology	Qualification	: --
Referred By	: Self	Registration No.	: --
Employer Id	: 22S33253		

---

**DEPARTMENT OF RADIOLOGY**

---

Both lung fields and hila are normal .

No obvious active pleuro-parenchymal lesion seen .

Both costophrenic and cardiophrenic angles are clear .

Cardiac shadow is normal.


Both diaphragms are normal in position and contour .

Thoracic wall and soft tissues appear normal.

**CONCLUSION :**

No obvious abnormality seen.

---End Of The Report---



Dr.SATINDER LAMBA  
MBBS, DMRE , MD ( USAIM )  
2004/02/386  
Radiology

---

## 2D ECHOCARDIOGRAPHY & COLOR DOPPLER STUDY

Name : Mrs. YESHASREE CHINADODDI      Age/Sex : 32/F      Date : 14/09/2024

### 2D Echo:-

Cardiac chamber dimensions –Normal

Wall motion abnormalities - no RWMA

LV systolic function - Normal, LVEF -60%

LV diastolic function – Diastolic flows are normal.

Cardiac valves -

Mitral valve –Normal, Minimal mitral regurgitation.

Aortic valve – Three thin leaflets, no aortic regurgitation, Aortic PG –9.2 mm Hg

Tricuspid valve – Mild tricuspid regurgitation, No PAH, PASP by TR jet -32mm Hg

Pulmonary valve - normal

Septae (IAS/IVS) – intact

Clot/vegetation/Pericardial effusion – No

Great Arteries (Aorta/pulmonary artery) - Normal

IVC - Normal

### Measurements -

Aorta	LA	IVS	PWD	LVIDd	LVIDs	LVEF
27	34	10	10	35	27	60%


### Conclusion:-

Normal chamber dimensions.

No RWMA, normal LV systolic function, LVEF – 60%

No LV Diastolic dysfunction.

Normal PA pressure.



Dr. Bhushan Bari  
DNB Medicine, DNB Cardiology  
Consultant and Interventional Cardiologist



**Saturday, September 14, 2024**

**NAME : MRS. YESHSHREE CHINADODDI**  
**AGE / SEX : 41 YEARS/FEMALE**  
**REF.BY : SELF**

**ULTRASOUND - ABDOMEN & PELVIS**

Liver appears normal in size, shape and echotexture. No focal lesion is noted.  
No e/o IHBR dilatation. Portal vein and CBD appear normal in dimensions at porta hepatis.

Gall bladder is distended with normal wall thickness.  
No echorefective calculus or soft tissue mass noted.

Spleen (10.6 cms) appears normal in size, shape and echotexture. No focal lesion is noted.

Visualized part of pancreas appears normal. No peripancreatic collection or mass lesion seen.

Both kidneys appear normal in size, shape, location with smooth outlines and normal echotexture. CM differentiation is maintained. No calculus, hydronephrosis or hydroureter noted on either side. **Right kidney shows a 14 x 14 mm simple cyst at mid pole cortex.**


No retroperitoneal lymphadenopathy is seen. No ascites or obvious bowel mass noted.

Urinary bladder is distended and appears normal. No echorefective calculus or soft tissue mass noted. Both U-V junctions appear normal.

Uterus appears normal in size. No obvious focal myometrial lesion is seen on TAS.  
Endometrial echo measures 6 mm. seen in midline & appears normal.  
Bilateral ovaries appear normal. No free fluid is detected in cul de sac.  
No solid or cystic adnexal mass is noted on either sides.

**IMPRESSION:**

- **Right simple renal cyst.**
- **No other significant abnormality detected.**  
**Suggest: clinical correlation.**

  
**Dr. Shaaz Khan (MBBS, DMRE)**  
**Consulting Radiologist**

The above findings represent radiographic observations and are not a final diagnoses in their own right, they need to be interpreted in the light of clinical/laboratory findings and relevant investigations if required.