

Name : Mrs. JANAKI S
PID No. : MED210162863
SID No. : 624023656
Age / Sex : 22 Year(s) / Female
Type : OP
Ref. Dr : MediWheel

Register On : 08/11/2024 10:07 AM
Collection On : 08/11/2024 10:22 AM
Report On : 08/11/2024 4:46 PM
Printed On : 11/11/2024 6:48 AM



<u>Investigation</u>	<u>Observed Value</u>	<u>Unit</u>	<u>Biological Reference Interval</u>
BLOOD GROUPING AND Rh TYPING (Blood/Agglutination)	'O' 'Positive'		
<u>Complete Blood Count With - ESR</u>			
Haemoglobin (Blood/Spectrophotometry)	11.5	g/dL	12.5 - 16.0
Packed Cell Volume(PCV)/Haematocrit (Blood/Derived from Impedance)	35.8	%	37 - 47
RBC Count (Blood/Impedance Variation)	4.30	mill/cu.mm	4.2 - 5.4
Mean Corpuscular Volume(MCV) (Blood/Derived from Impedance)	83.3	fL	78 - 100
Mean Corpuscular Haemoglobin(MCH) (Blood/Derived from Impedance)	26.6	pg	27 - 32
Mean Corpuscular Haemoglobin concentration(MCHC) (Blood/Derived from Impedance)	32.0	g/dL	32 - 36
RDW-CV (Derived from Impedance)	17.2	%	11.5 - 16.0
RDW-SD (Derived from Impedance)	50.15	fL	39 - 46
Total Leukocyte Count (TC) (Blood/Impedance Variation)	7940	cells/cu.mm	4000 - 11000
Neutrophils (Blood/Impedance Variation & Flow Cytometry)	61.8	%	40 - 75
Lymphocytes (Blood/Impedance Variation & Flow Cytometry)	28.8	%	20 - 45
Eosinophils (Blood/Impedance Variation & Flow Cytometry)	1.6	%	01 - 06
Monocytes (Blood/Impedance Variation & Flow Cytometry)	7.4	%	01 - 10



VERIFIED BY



Dr.R.Lavanya MD
Consultant - Pathologist
Reg No: 90632

APPROVED BY

The results pertain to sample tested.

Page 1 of 7

Name : Mrs. JANAKI S
PID No. : MED210162863
SID No. : 624023656
Age / Sex : 22 Year(s) / Female
Type : OP
Ref. Dr : MediWheel

Register On : 08/11/2024 10:07 AM
Collection On : 08/11/2024 10:22 AM
Report On : 08/11/2024 4:46 PM
Printed On : 11/11/2024 6:48 AM



<u>Investigation</u>	<u>Observed Value</u>	<u>Unit</u>	<u>Biological Reference Interval</u>
Basophils (Blood/Impedance Variation & Flow Cytometry)	0.4	%	00 - 02
INTERPRETATION: Tests done on Automated Five Part cell counter. All abnormal results are reviewed and confirmed microscopically.			
Absolute Neutrophil count (Blood/Impedance Variation & Flow Cytometry)	4.91	10 ³ / μ l	1.5 - 6.6
Absolute Lymphocyte Count (Blood/Impedance Variation & Flow Cytometry)	2.29	10 ³ / μ l	1.5 - 3.5
Absolute Eosinophil Count (AEC) (Blood/Impedance Variation & Flow Cytometry)	0.13	10 ³ / μ l	0.04 - 0.44
Absolute Monocyte Count (Blood/Impedance Variation & Flow Cytometry)	0.59	10 ³ / μ l	< 1.0
Absolute Basophil count (Blood/Impedance Variation & Flow Cytometry)	0.03	10 ³ / μ l	< 0.2
Platelet Count (Blood/Impedance Variation)	320	10 ³ / μ l	150 - 450
MPV (Blood/Derived from Impedance)	8.4	fL	8.0 - 13.3
PCT (Automated Blood cell Counter)	0.27	%	0.18 - 0.28
ESR (Erythrocyte Sedimentation Rate) (Blood/Automated ESR analyser)	23	mm/hr	< 20
BUN / Creatinine Ratio	13.09		
Glucose Fasting (FBS) (Plasma - F/GOD-PAP)	97.3	mg/dL	Normal: < 100 Pre Diabetic: 100 - 125 Diabetic: \geq 126

INTERPRETATION: Factors such as type, quantity and time of food intake, Physical activity, Psychological stress, and drugs can influence blood glucose level.

Glucose, Fasting (Urine) (Urine - F)	Negative		Negative
Glucose Postprandial (PPBS) (Plasma - PP/GOD-PAP)	105.5	mg/dL	70 - 140



VERIFIED BY



Dr. R. Lavanya MD
Consultant - Pathologist
Reg No: 90632

APPROVED BY

The results pertain to sample tested.

Page 2 of 7

Name : Mrs. JANAKI S
PID No. : MED210162863
SID No. : 624023656
Age / Sex : 22 Year(s) / Female
Type : OP
Ref. Dr : MediWheel

Register On : 08/11/2024 10:07 AM
Collection On : 08/11/2024 10:22 AM
Report On : 08/11/2024 4:46 PM
Printed On : 11/11/2024 6:48 AM



Investigation **Observed Value** **Unit** **Biological Reference Interval**

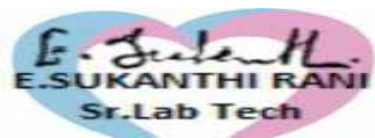INTERPRETATION:

Factors such as type, quantity and time of food intake, Physical activity, Psychological stress, and drugs can influence blood glucose level. Fasting blood glucose level may be higher than Postprandial glucose, because of physiological surge in Postprandial Insulin secretion, Insulin resistance, Exercise or Stress, Dawn Phenomenon, Somogyi Phenomenon, Anti- diabetic medication during treatment for Diabetes.

Blood Urea Nitrogen (BUN) (Serum/Urease UV / derived)	11.26	mg/dL	7.0 - 21
Creatinine (Serum/Modified Jaffe)	0.86	mg/dL	0.6 - 1.1
Uric Acid (Serum/Enzymatic)	4.1	mg/dL	2.6 - 6.0

Liver Function Test

Bilirubin(Total) (Serum)	1.10	mg/dL	0.1 - 1.2
Bilirubin(Direct) (Serum/Diazotized Sulfanilic Acid)	0.22	mg/dL	0.0 - 0.3
Bilirubin(Indirect) (Serum/Derived)	0.88	mg/dL	0.1 - 1.0
SGOT/AST (Aspartate Aminotransferase) (Serum/Modified IFCC)	21.2	U/L	5 - 40
SGPT/ALT (Alanine Aminotransferase) (Serum)	13.7	U/L	5 - 41
GGT(Gamma Glutamyl Transpeptidase) (Serum/IFCC / Kinetic)	14.0	U/L	< 38
Alkaline Phosphatase (SAP) (Serum/Modified IFCC)	55.8	U/L	42 - 98
Total Protein (Serum/Biuret)	7.77	gm/dl	6.0 - 8.0
Albumin (Serum/Bromocresol green)	4.50	gm/dl	3.5 - 5.2
Globulin (Serum/Derived)	3.27	gm/dL	2.3 - 3.6



VERIFIED BY



Dr.R.Lavanya MD
Consultant - Pathologist
Reg No: 90632

APPROVED BY

Name : Mrs. JANAKI S
PID No. : MED210162863
SID No. : 624023656
Age / Sex : 22 Year(s) / Female
Type : OP
Ref. Dr : MediWheel

Register On : 08/11/2024 10:07 AM
Collection On : 08/11/2024 10:22 AM
Report On : 08/11/2024 4:46 PM
Printed On : 11/11/2024 6:48 AM



<u>Investigation</u>	<u>Observed Value</u>	<u>Unit</u>	<u>Biological Reference Interval</u>
A : G RATIO (Serum/Derived)	1.38		1.1 - 2.2
<u>Lipid Profile</u>			
Cholesterol Total (Serum/CHOD-PAP with ATCS)	191.3	mg/dL	Optimal: < 200 Borderline: 200 - 239 High Risk: >= 240
Triglycerides (Serum/GPO-PAP with ATCS)	103.9	mg/dL	Optimal: < 150 Borderline: 150 - 199 High: 200 - 499 Very High: >= 500

INTERPRETATION: The reference ranges are based on fasting condition. Triglyceride levels change drastically in response to food, increasing as much as 5 to 10 times the fasting levels, just a few hours after eating. Fasting triglyceride levels show considerable diurnal variation too. There is evidence recommending triglycerides estimation in non-fasting condition for evaluating the risk of heart disease and screening for metabolic syndrome, as non-fasting sample is more representative of the "usual" circulating level of triglycerides during most part of the day.

HDL Cholesterol (Serum/Immunoinhibition)	52.6	mg/dL	Optimal(Negative Risk Factor): >= 60 Borderline: 50 - 59 High Risk: < 50
LDL Cholesterol (Serum/Calculated)	117.9	mg/dL	Optimal: < 100 Above Optimal: 100 - 129 Borderline: 130 - 159 High: 160 - 189 Very High: >= 190
VLDL Cholesterol (Serum/Calculated)	20.8	mg/dL	< 30
Non HDL Cholesterol (Serum/Calculated)	138.7	mg/dL	Optimal: < 130 Above Optimal: 130 - 159 Borderline High: 160 - 189 High: 190 - 219 Very High: >= 220



VERIFIED BY



Dr.R.Lavanya MD
Consultant - Pathologist
Reg No: 90632

APPROVED BY

Name : Mrs. JANAKI S
PID No. : MED210162863
SID No. : 624023656
Age / Sex : 22 Year(s) / Female
Type : OP
Ref. Dr : MediWheel

Register On : 08/11/2024 10:07 AM
Collection On : 08/11/2024 10:22 AM
Report On : 08/11/2024 4:46 PM
Printed On : 11/11/2024 6:48 AM



<u>Investigation</u>	<u>Observed Value</u>	<u>Unit</u>	<u>Biological Reference Interval</u>
----------------------	-----------------------	-------------	--------------------------------------

INTERPRETATION: 1.Non-HDL Cholesterol is now proven to be a better cardiovascular risk marker than LDL Cholesterol.
2.It is the sum of all potentially atherogenic proteins including LDL, IDL, VLDL and chylomicrons and it is the "new bad cholesterol" and is a co-primary target for cholesterol lowering therapy.

Total Cholesterol/HDL Cholesterol Ratio (Serum/Calculated)	3.6		Optimal: < 3.3 Low Risk: 3.4 - 4.4 Average Risk: 4.5 - 7.1 Moderate Risk: 7.2 - 11.0 High Risk: > 11.0
---	-----	--	--

Triglyceride/HDL Cholesterol Ratio (TG/HDL) (Serum/Calculated)	2		Optimal: < 2.5 Mild to moderate risk: 2.5 - 5.0 High Risk: > 5.0
---	---	--	--

LDL/HDL Cholesterol Ratio (Serum/Calculated)	2.2		Optimal: 0.5 - 3.0 Borderline: 3.1 - 6.0 High Risk: > 6.0
---	-----	--	---

Glycosylated Haemoglobin (HbA1c)

HbA1c (Whole Blood/Ion exchange HPLC by D10)	5.8	%	Normal: 4.5 - 5.6 Prediabetes: 5.7 - 6.4 Diabetic: >= 6.5
---	-----	---	---

INTERPRETATION: If Diabetes - Good control : 6.1 - 7.0 % , Fair control : 7.1 - 8.0 % , Poor control >= 8.1 %

Estimated Average Glucose (Whole Blood)	119.76	mg/dL
--	--------	-------

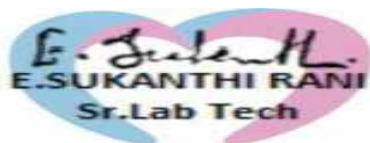INTERPRETATION: Comments

HbA1c provides an index of Average Blood Glucose levels over the past 8 - 12 weeks and is a much better indicator of long term glycemc control as compared to blood and urinary glucose determinations.

Conditions that prolong RBC life span like Iron deficiency anemia, Vitamin B12 & Folate deficiency, hypertriglyceridemia,hyperbilirubinemia,Drugs, Alcohol, Lead Poisoning, Asplenia can give falsely elevated HbA1C values.

Conditions that shorten RBC survival like acute or chronic blood loss, hemolytic anemia, Hemoglobinopathies, Splenomegaly,Vitamin E ingestion, Pregnancy, End stage Renal disease can cause falsely low HbA1c.

THYROID PROFILE / TFT



VERIFIED BY




Dr.R.Lavanya MD
Consultant - Pathologist
Reg No: 90632

APPROVED BY

Name : Mrs. JANAKI S
PID No. : MED210162863
SID No. : 624023656
Age / Sex : 22 Year(s) / Female
Type : OP
Ref. Dr : MediWheel

Register On : 08/11/2024 10:07 AM
Collection On : 08/11/2024 10:22 AM
Report On : 08/11/2024 4:46 PM
Printed On : 11/11/2024 6:48 AM



<u>Investigation</u>	<u>Observed Value</u>	<u>Unit</u>	<u>Biological Reference Interval</u>
T3 (Triiodothyronine) - Total (Serum/Chemiluminescent Immunometric Assay (CLIA))	1.48	ng/ml	0.7 - 2.04

INTERPRETATION:

Comment :

Total T3 variation can be seen in other condition like pregnancy, drugs, nephrosis etc. In such cases, Free T3 is recommended as it is Metabolically active.

T4 (Tyroxine) - Total (Serum/Chemiluminescent Immunometric Assay (CLIA))	10.36	µg/dL	4.2 - 12.0
---	-------	-------	------------

INTERPRETATION:

Comment :

Total T4 variation can be seen in other condition like pregnancy, drugs, nephrosis etc. In such cases, Free T4 is recommended as it is Metabolically active.

TSH (Thyroid Stimulating Hormone) (Serum/Chemiluminescent Immunometric Assay (CLIA))	1.55	µIU/mL	0.35 - 5.50
---	------	--------	-------------

INTERPRETATION:

Reference range for cord blood - upto 20

1 st trimester: 0.1-2.5

2 nd trimester 0.2-3.0

3 rd trimester : 0.3-3.0

(Indian Thyroid Society Guidelines)

Comment :

1.TSH reference range during pregnancy depends on Iodine intake, TPO status, Serum HCG concentration, race, Ethnicity and BMI.

2.TSH Levels are subject to circadian variation, reaching peak levels between 2-4am and at a minimum between 6-10PM.The variation can be of the order of 50%,hence time of the day has influence on the measured serum TSH concentrations.

3.Values&lt;0.03 µIU/mL need to be clinically correlated due to presence of rare TSH variant in some individuals.

Urine Analysis - Routine

Colour (Urine)	Pale Yellow	Yellow to Amber
Appearance (Urine)	Clear	Clear
Protein (Urine)	Negative	Negative



VERIFIED BY



Dr.R.Lavanya MD
Consultant - Pathologist
Reg No: 90632

APPROVED BY

Name : Mrs. JANAKI S
PID No. : MED210162863
SID No. : 624023656
Age / Sex : 22 Year(s) / Female
Type : OP
Ref. Dr : MediWheel

Register On : 08/11/2024 10:07 AM
Collection On : 08/11/2024 10:22 AM
Report On : 08/11/2024 4:46 PM
Printed On : 11/11/2024 6:48 AM



<u>Investigation</u>	<u>Observed Value</u>	<u>Unit</u>	<u>Biological Reference Interval</u>
Glucose (Urine)	Negative		Negative
Pus Cells (Urine)	2-3	/hpf	NIL
Epithelial Cells (Urine)	3-4	/hpf	NIL
RBCs (Urine)	Nil	/hpf	NIL



VERIFIED BY



Dr.R.Lavanya MD
Consultant - Pathologist
Reg No: 90632

APPROVED BY

-- End of Report --

Name	MRS.JANAKI S	ID	MED210162863
Age & Gender	22Y/FEMALE	Visit Date	08 Nov 2024
Ref Doctor Name	MediWheel		



Thanks for your reference

ECHOCARDIOGRAM WITH COLOUR DOPPLER:

LVID d ... 4.3cm
LVID s ... 2.5cm
EF ... 75%
IVS d ... 0.6 cm
IVS s ... 0.5cm
LVPW d ... 0.6cm
LVPW s ... 0.8cm
LA ... 2.6cm
AO ... 2.6cm
TAPSE ... 21mm
IVC ... 0.8cm

Left ventricle , Left atrium normal.

Right ventricle, Right atrium normal.

No regional wall motion abnormality present.

Mitral valve, Aortic valve, Tricuspid valve & Pulmonary valve normal.

Aorta normal.

Inter atrial septum intact.

Inter ventricular septum intact.

No pericardial effusion .

Doppler:

Mitral valve : E: 1.01m/s A: 0.73m/s

Name	MRS.JANAKI S	ID	MED210162863
Age & Gender	22Y/FEMALE	Visit Date	08 Nov 2024
Ref Doctor Name	MediWheel		



E/A Ratio: 1.39 E/E: 9.29

Aortic valve: AV Jet velocity: 1.09m/s

Tricuspid valve: TV Jet velocity: 1.35m/s

TRPG: 7.29

mmHg.

Pulmonary valve: PV Jet velocity: 1.22m/s

IMPRESSION:

1. **Normal chambers & Valves.**
2. **No regional wall motion abnormality present.**
3. **Normal LV systolic function.**
4. **Pericardial effusion - Nil.**
5. **No pulmonary artery hypertension.**

A handwritten signature in blue ink, appearing to read "Mani".

Dr. S. MANIKANDAN. MD.DM.(Cardio)

Cardiologist

Name	MRS.JANAKI S	ID	MED210162863
Age & Gender	22Y/FEMALE	Visit Date	08 Nov 2024
Ref Doctor Name	MediWheel		



Thanks for your reference

SONOGRAM REPORT

WHOLE ABDOMEN

Liver: The liver is normal in size and shows uniform echotexture with no focal abnormality. There is no intra or extra hepatic biliary ductal dilatation.

Gallbladder: The gall bladder is partially distended with no demonstrable calculus.

Pancreas: The pancreas head and visualized part of body appears normal. Rest of the body of pancreas and tail obscured by bowel gas.

Spleen: The spleen is normal.

Kidneys: The right kidney measures 8.9 x 3.4 cm. Normal architecture.

The collecting system is not dilated.

The left kidney measures 9.1 x 4.0 cm. Normal architecture.

The collecting system is not dilated.

Urinary

bladder: The urinary bladder is partially filled. No demonstrable internal echoes noted.

Uterus: The uterus is anteverted, and measures 6.1 x 4.1 cm.

Focal thickening noted in posterior myometrium.

The endometrium measures 9 mm in thickness.

Name	MRS.JANAKI S	ID	MED210162863
Age & Gender	22Y/FEMALE	Visit Date	08 Nov 2024
Ref Doctor Name	MediWheel		



**Few small nabothian follicles noted around the endo cervix.
Small amount of fluid noted in pouch of douglas.**

Ovaries: The right ovary measure 2.6 x 2.0 cm.
The left ovary measures 2.2 x 2.7 cm.
No significant mass or cyst is seen in the ovaries.
Parametria are free.

RIF: Iliac fossae are normal.
No mass is seen in the right iliac fossa.
The appendix is not visualized.
No para aortic lymphadenopathy is seen.

IMPRESSION :

- **Features suggestive of early uterine adenomyosis.**
- For follow up.

**DR.T.ANNIE STALIN MBBS.,F.USG.,
SONOLOGIST.**

Name	MRS.JANAKI S	ID	MED210162863
Age & Gender	22Y/FEMALE	Visit Date	08 Nov 2024
Ref Doctor Name	MediWheel		



Name	MRS.JANAKI S	ID	MED210162863
Age & Gender	22Y/FEMALE	Visit Date	08 Nov 2024
Ref Doctor Name	MediWheel		



Name	Mrs. JANAKI S	ID	MED210162863
Age & Gender	22Y/F	Visit Date	Nov 8 2024 10:07AM
Ref Doctor	MediWheel		


Thanks for your reference

DIGITAL X- RAY CHEST PA VIEW

Trachea appears normal.
Cardiothoracic ratio is within normal limits.
Bilateral lung fields appear normal.
Both costophrenic angles appear normal.
Visualised bony structures appear normal.
Extra thoracic soft tissues shadow grossly appears normal.

IMPRESSION:

- **NO SIGNIFICANT ABNORMALITY DEMONSTRATED.**



DR. DANIEL STANLEY PETER, M.D.R.D.,
Consultant Radiologist
Reg. No: 82342

MEDICAL EXAMINATION REPORT

Name Gender Date of Birth
Position Selected For Identification marks

A. HISTORY:

1. Do you have, or are you being treated for, any of the following conditions? (please tick all that apply)?

- | | | |
|---|--|---|
| <input type="checkbox"/> Anxiety | <input type="checkbox"/> Cancer | <input type="checkbox"/> High Blood Pressure |
| <input type="checkbox"/> Arthritis | <input type="checkbox"/> Depression/ bipolar disorder | <input type="checkbox"/> High Cholesterol |
| <input type="checkbox"/> Asthama, Bronchitis, Emphysema | <input type="checkbox"/> Diabetes | <input type="checkbox"/> Migraine Headaches |
| <input type="checkbox"/> Back or spinal problems | <input type="checkbox"/> Heart Disease | <input type="checkbox"/> Sinusitis or Allergic Rhinitis (Hay Fever) |
| <input type="checkbox"/> Epilepsy | <input type="checkbox"/> Any other serious problem for which you are receiving medical attention | |

2. List the medications taken Regularly.

3. List allergies to any known medications or chemicals

4. Alcohol : Yes No Occasional

5. Smoking : Yes No Quit(more than 3 years)

6. Respiratory Function :

- a. Do you become unusually short of breath while walking fast or taking stair - case? Yes No
- b. Do you usually cough a lot first thing in morning? Yes No
- c. Have you vomited or coughed out blood? Yes No

7. Cardiovascular Function & Physical Activity :

- a. Exercise Type: (Select 1)
- No Activity
 - Very Light Activity (Seated At Desk, Standing)
 - Light Activity (Walking on level surface, house cleaning)
 - Moderate Activity (Brisk walking, dancing, weeding)
 - Vigorous Activity (Soccer, Running)
- b. Exercise Frequency: Regular (less than 3 days/ week) / Irregular (more than 3 days/ Week)
- c. Do you feel pain in chest when engaging in physical activity? Yes No

8. Hearing :

- a. Do you have history of hearing troubles? Yes No
- b. Do you experiences ringing in your ears? Yes No
- c. Do you experience discharge from your ears? Yes No
- d. Have you ever been diagnosed with industrial deafness? Yes No

9. Musculo - Skeletal History

- a. Neck : Have you ever injured or experienced pain? Yes No
- b. Back : If Yes ; approximate date (MM/YYYY)
- c. Shoulder, Elbow, Wrists, Hands Consulted a medical professional ? Yes No
- d. Hips, Knees, Ankles, Legs Resulted in time of work? Yes No
- Surgery Required ? Yes No
- Ongoing Problems ? Yes No

10. Function History

- a. Do you have pain or discomfort when lifting or handling heavy objects? Yes No
- b. Do you have knee pain when squatting or kneeling? Yes No
- c. Do you have back pain when forwarding or twisting? Yes No
- d. Do you have pain or difficulty when lifting objects above your shoulder height? Yes No
- e. Do you have pain when doing any of the following for prolonged periods (Please circle appropriate response)
- | | | |
|---|---|--|
| •Walking : Yes <input type="checkbox"/> No <input checked="" type="checkbox"/> | •Kneeling : Yes <input type="checkbox"/> No <input checked="" type="checkbox"/> | •Squatting : Yes <input type="checkbox"/> No <input checked="" type="checkbox"/> |
| •Climbing : Yes <input type="checkbox"/> No <input checked="" type="checkbox"/> | •Sitting : Yes <input type="checkbox"/> No <input checked="" type="checkbox"/> | |
| •Standing : Yes <input type="checkbox"/> No <input checked="" type="checkbox"/> | •Bending : Yes <input type="checkbox"/> No <input checked="" type="checkbox"/> | |
- f. Do you have pain when working with hand tools? Yes No
- g. Do you experience any difficulty operating machinery? Yes No
- h. Do you have difficulty operating computer instrument? Yes No

MID - 35
chest - 32
Pulse - 83

B. CLINICAL EXAMINATION

a. Height <input type="text" value="146"/>	b. Weight <input type="text" value="51"/>	Blood Pressure <input type="text" value="91 / 66 mmhg"/>
Chest measurements: a. Normal <input type="text"/>	b. Expanded <input type="text"/>	
Waist Circumference <input type="text" value="Normal"/>	Ear, Nose & Throat <input type="text" value="Normal"/>	
Skin <input type="text" value="Normal"/>	Respiratory System <input type="text" value="Normal"/>	
Vision <input type="text" value="Normal"/>	Nervous System <input type="text" value="Normal"/>	
Circulatory System <input type="text" value="Normal"/>	Genito-urinary System <input type="text" value="Normal"/>	
Gastro-intestinal System <input type="text" value="Normal"/>	Colour Vision <input type="text" value="Normal"/>	

Discuss Particulars of Section B :-

C. REMARKS OF PATHOLOGICAL TESTS

Chest X-ray <input type="text" value="Normal"/>	ECG <input type="text" value="Normal"/>
Complete Blood Count <input type="text" value="11.5"/>	Urine routine <input type="text" value="Normal"/>
Serum cholesterol <input type="text" value="191.3"/>	Blood sugar <input type="text" value="F(IV), PP 105.5"/>
Blood Group <input type="text" value="O+ Positive"/>	S.Creatinine <input type="text" value="0.86"/>

D. CONCLUSION

Any further investigations required <input type="text"/>	Any precautions suggested <input type="text"/>
--	--

E. FITNESS CERTIFICATION

Certified that the above named recruit does not appear to be suffering from any disease communicable or otherwise, constitutional weakness or bodily infirmity except _____

_____ . I do not consider this as disqualification for employment in the Company. S

Candidate is free from Contagious/Communicable disease

Date : 9/11/2024



Signature of Medical Adviser

DR. S. MANIBANJAN, MD, DNB (Gen. Med.)

HR 74 bpm

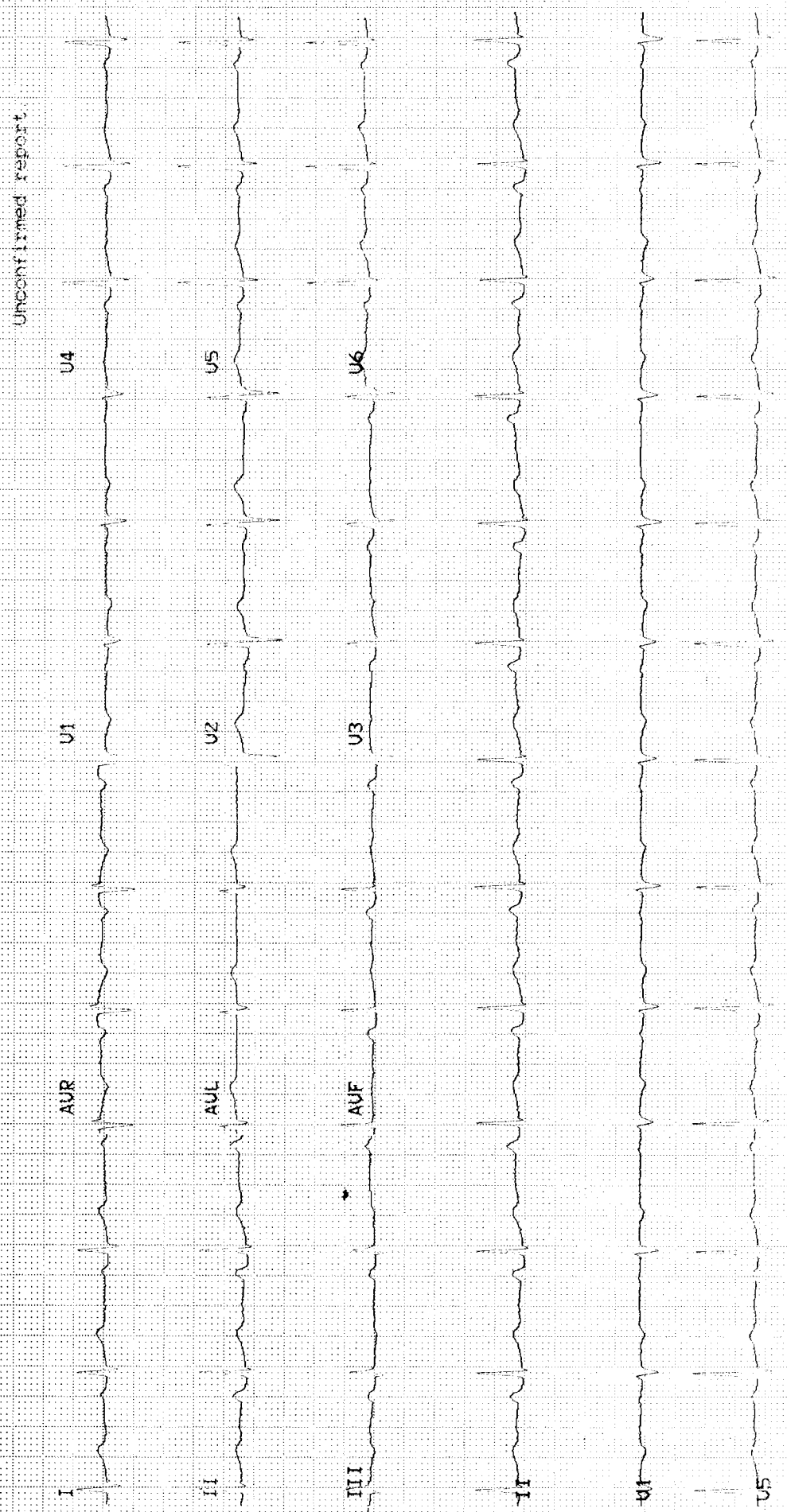
Interpretation:
12SL - Interpretation
Normal sinus rhythm
Normal ECG

Interpretation:
12SL - Interpretation
Normal sinus rhythm
Normal ECG

Measurement Results:

P 76 ms
TcB 368 / 408 ms
P 796 / 810 ms
S/T 64 / 58 / 35 degrees

aVR -90
aVL
aVF
I
II
III +90
aVR
aVL
aVF
I
II
III



14

MEDALL DIAGNOSTICS

Customer Name	MRS. JANAKI S	Customer ID	MED210162863
Age & Gender	22Y/FEMALE	Visit Date	08/11/2024
Ref Doctor	MEDIWHEEL		

Thanks for your reference

DIGITAL X- RAY CHEST PA VIEW

Trachea appears normal.

Cardiothoracic ratio is within normal limits.

Bilateral lung fields appear normal.

Both costophrenic angles appear normal.

Visualised bony structures appear normal.

Extra thoracic soft tissues shadow grossly appears normal.

IMPRESSION:

✓ **NO SIGNIFICANT ABNORMALITY DEMONSTRATED.**

DR. DANIEL STANLEY PETER, M.D.R.D.,
Consultant Radiologist.
Reg. No: 82342.



Customer Name	MRS.JANAKI S	Customer ID	MED210162863
Age & Gender	22Y/FEMALE	Visit Date	08/11/2024
Ref Doctor	MediWheel		

Thanks for your reference

ECHOCARDIOGRAM WITH COLOUR DOPPLER:

LVID d ... 4.3cm
 LVID s ... 2.5cm
 EF ... 75%
 IVS d ... 0.6 cm
 IVS s ... 0.5cm
 LVPW d ... 0.6cm
 LVPW s ... 0.8cm
 LA ... 2.6cm
 AO ... 2.6cm
 TAPSE ... 21mm
 IVC ... 0.8cm

Left ventricle , Left atrium normal.

Right ventricle, Right atrium normal.

No regional wall motion abnormality present.

Mitral valve, Aortic valve, Tricuspid valve & Pulmonary valve normal.

Aorta normal.

Inter atrial septum intact.

Inter ventricular septum intact.

No pericardial effusion .



Customer Name	MRS.JANAKI S	Customer ID	MED210162863
Age & Gender	22Y/FEMALE	Visit Date	08/11/2024
Ref Doctor	MediWheel		

Doppler:

Mitral valve : E: 1.01m/s A: 0.73m/s
 E/A Ratio: 1.39 E/E: 9.29

Aortic valve: AV Jet velocity: 1.09m/s

Tricuspid valve: TV Jet velocity: 1.35m/s

TRPG: 7.29 mmHg.

Pulmonary valve: PV Jet velocity: 1.22m/s

IMPRESSION:

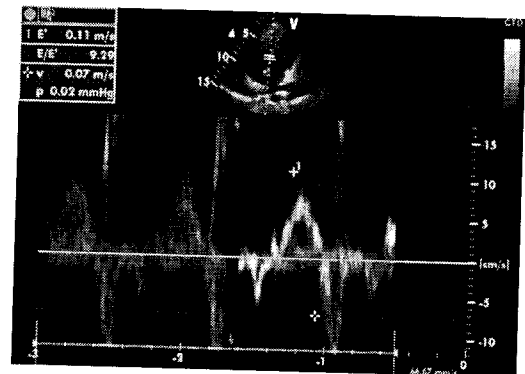
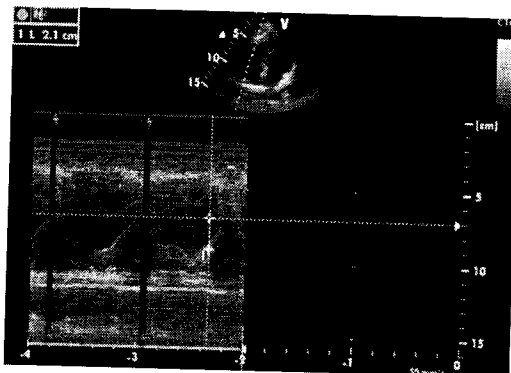
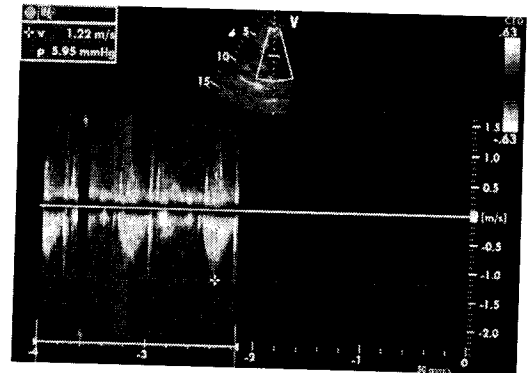
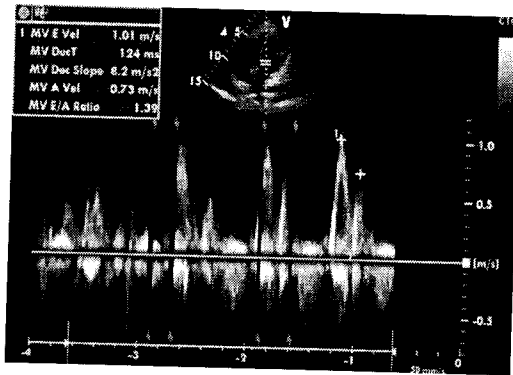
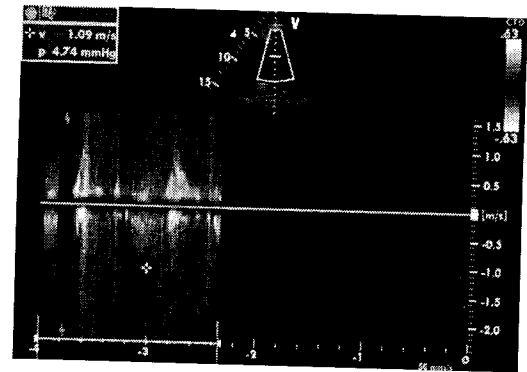
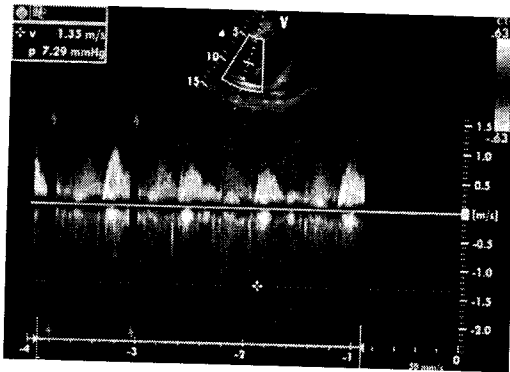
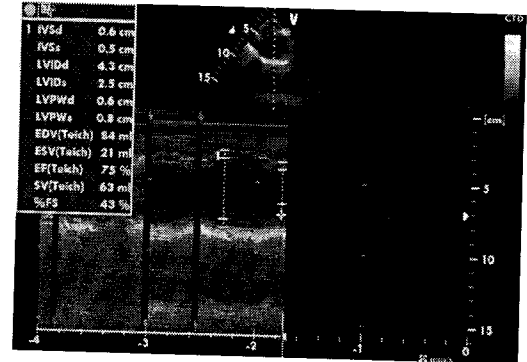
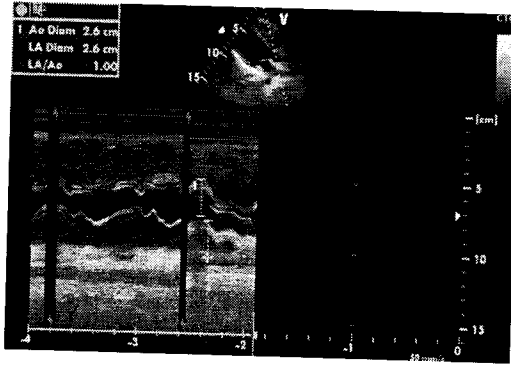
1. Normal chambers & Valves.
2. No regional wall motion abnormality present.
3. Normal LV systolic function.
4. Pericardial effusion - Nil.
5. No pulmonary artery hypertension.



Dr. S. MANIKANDAN. MD.DM.(Cardio)
Cardiologist



Customer Name	MRS.JANAKI S	Customer ID	MED210162863
Age & Gender	22Y/FEMALE	Visit Date	08/11/2024
Ref Doctor	MediWheel		



Customer Name	MRS.JANAKI S	Customer ID	MED210162863
Age & Gender	22Y/FEMALE	Visit Date	08/11/2024
Ref Doctor	MediWheel		

Thanks for your reference
SONOGRAM REPORT

WHOLE ABDOMEN

Liver: The liver is normal in size and shows uniform echotexture with no focal abnormality. There is no intra or extra hepatic biliary ductal dilatation.

Gallbladder: The gall bladder is partially distended with no demonstrable calculus.

Pancreas: The pancreas head and visualized part of body appears normal. Rest of the body of pancreas and tail obscured by bowel gas.

Spleen: The spleen is normal.

Kidneys: The right kidney measures 8.9 x 3.4 cm. Normal architecture. The collecting system is not dilated.

The left kidney measures 9.1 x 4.0 cm. Normal architecture. The collecting system is not dilated.

Urinary bladder: The urinary bladder is partially filled. No demonstrable internal echoes noted.



Customer Name	MRS.JANAKI S	Customer ID	MED210162863
Age & Gender	22Y/FEMALE	Visit Date	08/11/2024
Ref Doctor	MediWheel		

Uterus: The uterus is anteverted, and measures 6.1 x 4.1 cm.
Focal thickening noted in posterior myometrium.
 The endometrium measures 9 mm in thickness.
Few small nabothian follicles noted around the endo cervix.
Small amount of fluid noted in pouch of douglas.

Ovaries: The right ovary measure 2.6 x 2.0 cm.
 The left ovary measures 2.2 x 2.7 cm.
 No significant mass or cyst is seen in the ovaries.
 Parametria are free.

RIF: Iliac fossae are normal.
 No mass is seen in the right iliac fossa.
 The appendix is not visualized.
 No para aortic lymphadenopathy is seen.

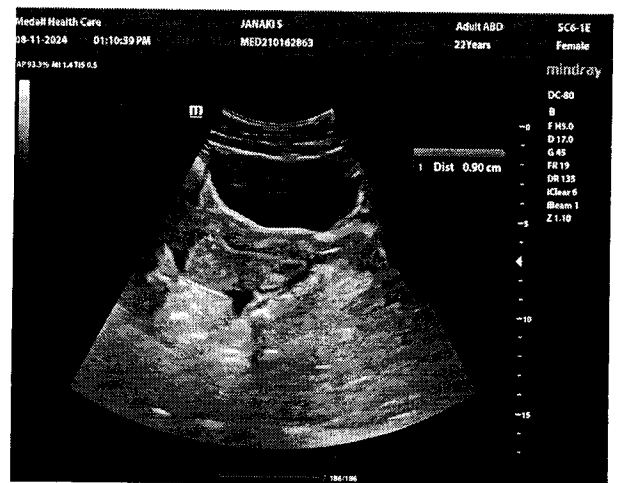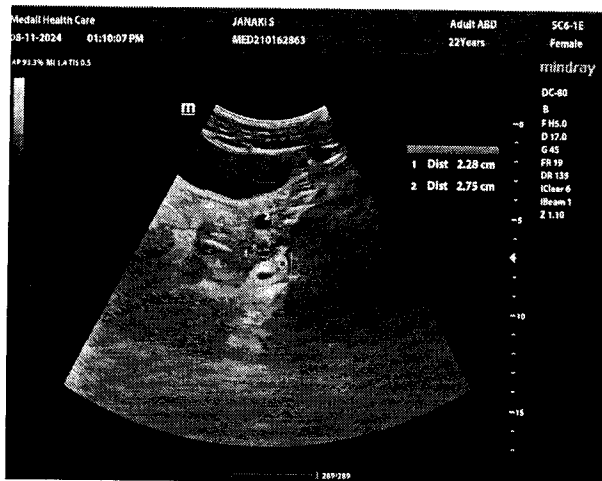
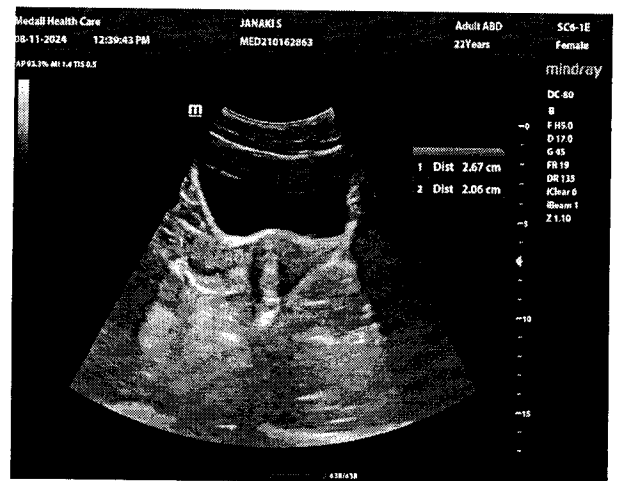
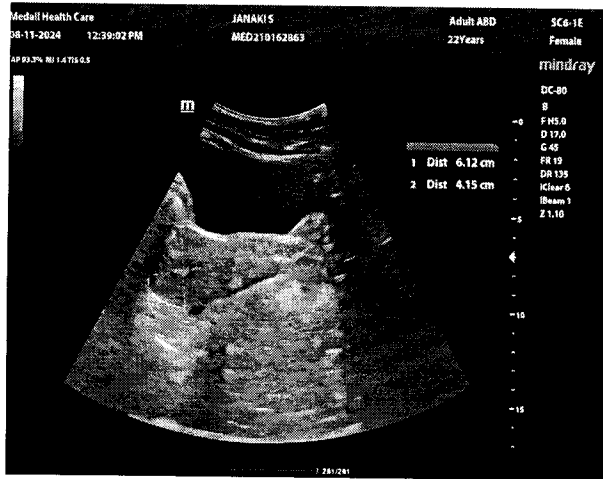
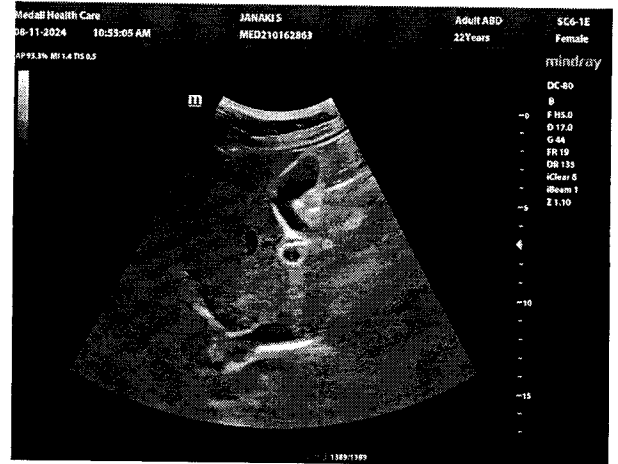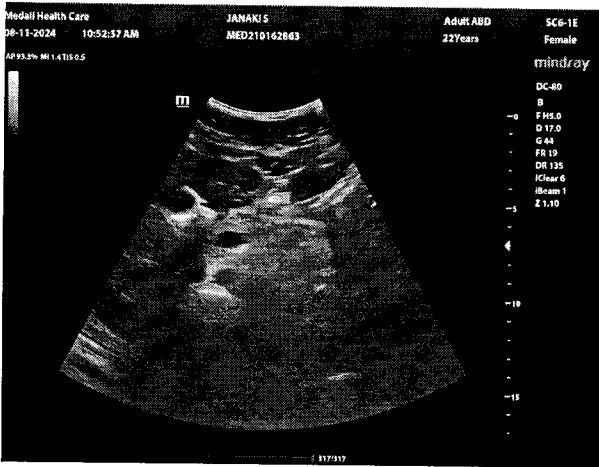
IMPRESSION :

- **Features suggestive of early uterine adenomyosis.**
- ***For follow up.***

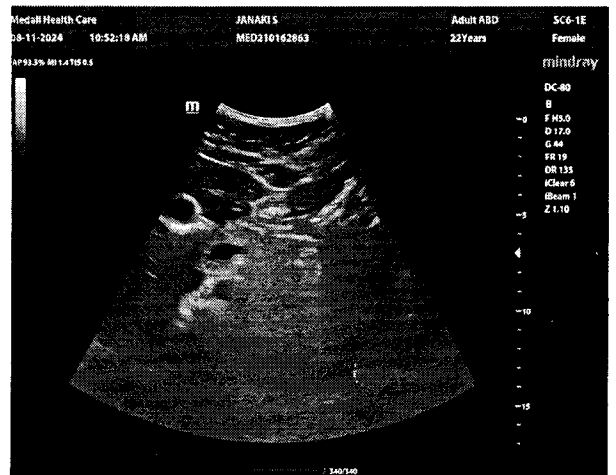
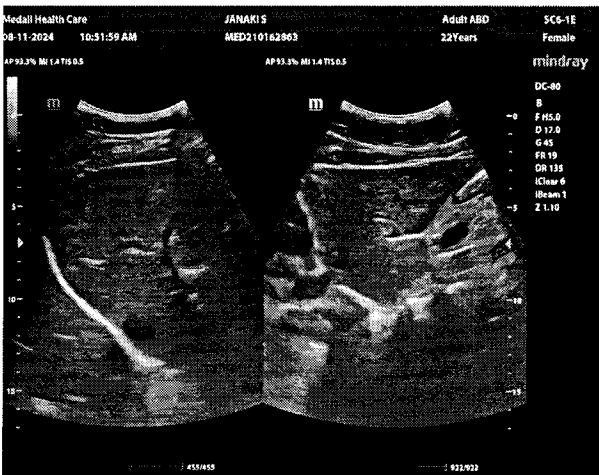
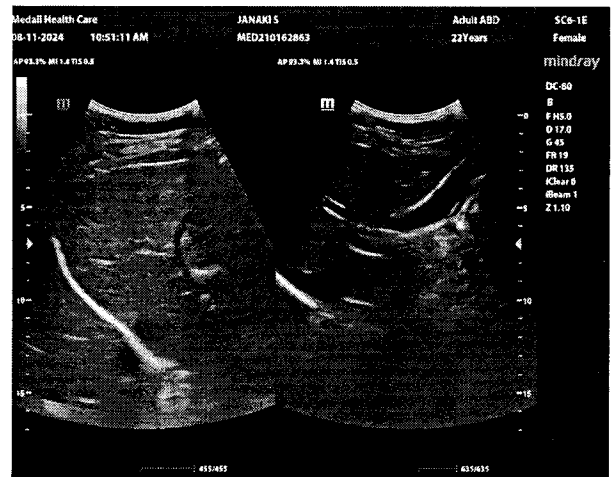
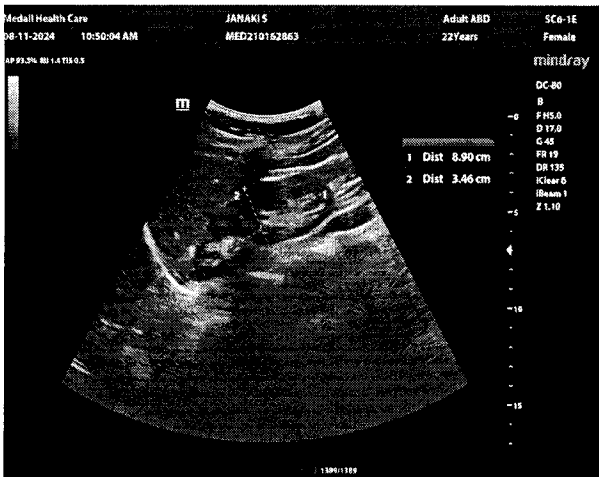
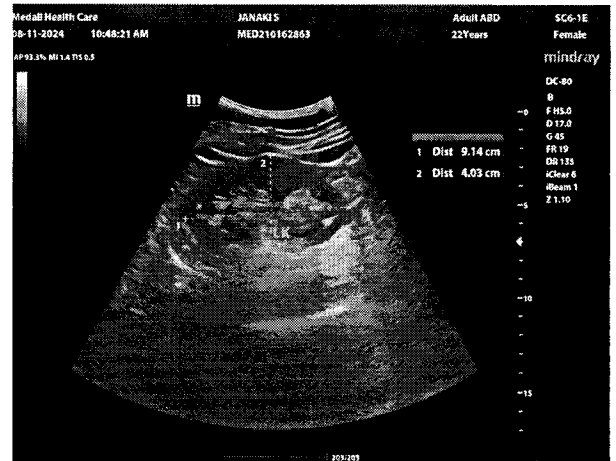
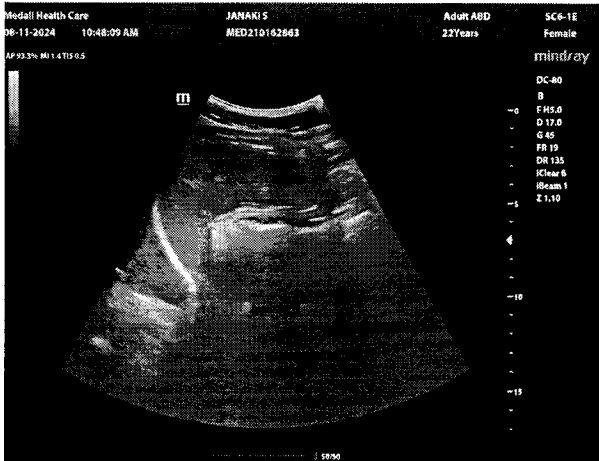

DR.T.ANNIE STALIN MBBS.,F.USG.,
SONOLOGIST.



Customer Name	MRS.JANAKI S	Customer ID	MED210162863
Age & Gender	22Y/FEMALE	Visit Date	08/11/2024
Ref Doctor	MediWheel		



Customer Name	MRS.JANAKI S	Customer ID	MED210162863
Age & Gender	22Y/FEMALE	Visit Date	08/11/2024
Ref Doctor	MediWheel		





Dr Agarwals

Patient :	MRS. JANAKI S	Doctor :	Dr. BHARATH K.A.
Age/Sex :	22 years 0 months /Female	Facility :	Dr Agarwals Eye Hospitals- Thirunelveli
Contact :	9894490146	Patient Type :	DRT
Appt. Dt :	08 Nov'24	MR No. :	TVL/350290/24
Address :	45 V.V.K.ST PETTAI, Tirunelveli Pettai S.O, TIRUNELVELI, Tamil Nadu 627004	Note Dt :	08 Nov'24

OPHTHALMIC REPORT

Integration - Drt New Drt Medall Health Care Vannarpettai (Fitness)

ON EXAMINATION

	Right Eye	Left Eye
UVA	UCVA - 6/9(P)	UCVA - 6/9
BCVA	PH- 6/6	PH- 6/6
IOP		

ANTERIOR SEGMENT EXAMINATION

R/OD	L/OS
Sclera: Normal	Sclera: Normal
Cornea: Size/Shape/Surface Normal	Cornea: Size/Shape/Surface Normal
Anterior Chamber: Within Normal Limits	Anterior Chamber: Within Normal Limits
Pupil: Within Normal Limits	Pupil: Within Normal Limits
Iris: Within Normal Limits	Iris: Within Normal Limits
Lens: Within Normal Limits	Lens: Within Normal Limits

FUNDUS EXAMINATION

Right Eye: Media-Clear(U/D), PVD-Absent, OptDiscSize-Medium, OpticDisc-healthy, Bloodvessel-normal Macula-Foveal Reflex, Foveal Reflex- Present
Left Eye: Media-Clear(U/D), PVD-Absent, OptDiscSize-Medium, OpticDisc-healthy, Bloodvessel-normal Macula-Foveal Reflex, Foveal Reflex- Present

IN CASE OF EMERGENCY (UNUSUAL PAIN, WATERING, REDNESS, OR DECREASE IN VISION) PLEASE

CONTACT: MOBILE NO:9840475661 / 8220013039

அவசரகாலநிலையில்(அசாதாரணவலி, கண்ணில்நீர்வடிதல், கண்சிவத்தல், பார்வைகுறைதல்)தொடர்புஎண்: அலைப்பேசி:

NO: 9840475661 / 8220013039

Branch Office : Dr. Agarwal's Health Care Ltd.

No. 15, South Bye Pass, Vannarpet, Tirunelveli - 627 003. Ph : 0462-2501818, 2501819

Mobile : 82200 13039 Email : tirunelveli@dragarwal.com Website : www.dragarwal.com

Regd. Office :



Dr Agarwals

DIAGNOSIS

1. Compound myopic astigmatism, bilateral

ADVICE

Advice & Precautions :

GP

Can issue certificate

For Followup : - Visit **Dr. BHARATH K.A.** after 6 Months

Dr. Bharath K.A.

Printed on: 08 Nov'2024, 04:13 PM

Dr. Agarwal's Eye Hospital
No. 10/1/1-5, Land Mark Towers,
South Bye Pass, Opp. to BSNL,
Vannarpet, Tirunelveli - 627 003.
Ph. 0462-2501818, Cell. 9446395952

IN CASE OF EMERGENCY (UNUSUAL PAIN, WATERING, REDNESS, OR DECREASE IN VISION) PLEASE

CONTACT: MOBILE NO:9840475661 / 8220013039

அவசரகாலநிலையில்(அசாதாரணவலி, கண்ணில்நீர்வடிதல், கண்சிவத்தல், பார்வைகுறைதல்)தொடர்புஎண்:அலைப்பேசி:

NO: 9840475661 / 8220013039

Branch Office : Dr. Agarwal's Health Care Ltd.

No. 15, South Bye Pass, Vannarpet, Tirunelveli - 627 003. Ph : 0462-2501818, 2501819

Mobile : 82200 13039 Email : tirunelveli@dragarwal.com Website : www.dragarwal.com

Regd. Office :

2nd Floor, Parkview Towers, No. 4, Main Road, South of C. P. Road, Madhavaram, Chennai - 600 030