

Subashlal@yahoo.com

Name : Mr. Subash Balasubramaanam

Age: 47 Y

UHID:CELE.0000129930

Sex: M



Address : ecity

OP Number:CELEOPV342302

Plan : ARCOFEMI MEDIWHEEL MALE AHC CREDIT PAN  
INDIA OP AGREEMENT

Bill No :CELE-OCR-55572

Date : 09.03.2024 08:08

Sno	Service Type/ServiceName	Department
1	ARCOFEMI - MEDIWHEEL - FULL BODY ANNUAL PLUS ABOVE 50Y MALE - 2D ECHO - PAN INDIA - FY2324	
1	GAMMA GLUTAMYL TRANSFERASE (GGT) - 12	
2	PROSTATIC SPECIFIC ANTIGEN (PSA TOTAL)	
3	2D ECHO - 11	
4	LIVER FUNCTION TEST (LFT)	
5	GLUCOSE, FASTING	
6	HEMOGRAM + PERIPHERAL SMEAR	
7	DIET CONSULTATION	
8	COMPLETE URINE EXAMINATION	
9	URINE GLUCOSE(POST PRANDIAL)	
10	PERIPHERAL SMEAR	
11	ECG - 13	
12	RENAL PROFILE/RENAL FUNCTION TEST (RFT/KFT)	
13	DENTAL CONSULTATION - 15/20	
14	GLUCOSE, POST PRANDIAL (PP), 2 HOURS (POST MEAL)	
15	URINE GLUCOSE(FASTING)	
16	HbA1c. GLYCATED HEMOGLOBIN	
17	X-RAY CHEST PA - 9	
18	ENT CONSULTATION - 6	
19	FITNESS BY GENERAL PHYSICIAN	
20	BLOOD GROUP ABO AND RH FACTOR	
21	LIPID PROFILE	
22	BODY MASS INDEX (BMI)	
23	OPTICAL BY GENERAL PHYSICIAN - 5	
24	ULTRASOUND - WHOLE ABDOMEN - 8 (8.45)	
25	THYROID PROFILE (TOTAL T3, TOTAL T4, TSH)	

physisio - 14      studio - 3      optical - 5

V<sub>R</sub> ← RE 6/36 NC      6/6 NB  
LE 6/36 PN<sub>6</sub>      6/6 PN<sub>6</sub>

WT - 74.5kg  
HT - 168cm

BMI - 26.3

Bp - 140/92

PR - 86

MEDICAL FITNESS CERTIFICATE

DATE: 09/03/2024

NAME: Mr. Subash

AGE/SEX: 47y

UHID: 129930

CHIEF COMPLAINTS:

PAST/FAMILY HISTORY:

ALLERGIES:

GENERAL EXAMINATION:

PULSE: 85	BP: 142/87	TEMP:	RR:
HT: 168cm	WT: 74.5	WAIST:	BMI:

Vision	Rt	Lt	With Correction
DISTANT			
NEAR			
COLOUR			

*Vision*

RG - 6/36 NG  
 LE - 6/36 PNB  
 PG - 6/6 NG  
 6/6 PNB

SYSTEMIC EXAMINATION

Chest:

Cvs:

P/A:

IMPRESSION:

FINAL RECOMMENDATION:

GENERAL PHYSICIAN

# Apollo Clinic

## Consent Form

Patient Name: Subash Balasubramaniam Age: 47

UHID Number: CELE 129930 Company Name: .....


I Mr/Mrs/Ms. Subash Balasubramaniam Employee of Dependant of Bank of Baroda  
(Company) want to inform you that I am not getting the Diet Consultation

test done which is a part of routine health check package.

Reason if any: Reports are not available at this point of time

.....

And I claim the above statement in my full consciousness.

Patient signature:  Date: 9/3/24

09/03/24.

Height :	Weight :	BMI :	Waist Circum :
Temp : 98.6°F	Pulse : 88/min	Resp : 22/min	B.P : 140/92 mm Hg

General Examination / Allergies  
History

CNS: }  
RS: }  
P/A: } NAD.

Clinical Diagnosis & Management Plan

- TBP -  
- not on any medications presently.  
- T. telmisartan 40mg 1-0-0.  
(After breakfast) x 3 days.  
- Follow up after 3 days.

Follow up date:

Doctor Signature

Mr. Subash Balasubramanian  
& Ty / m

9/3/24.

Dr. YASHASWI, MBBS, DLO  
FELLOW IN RHINOLOGY  
ALLERGY SPECIALIST  
REG. No.: 71613  
MOB.: 9448089291 / 9945126633

Height :	Weight :	BMI :	Waist Circum :
Temp :	Pulse :	Resp :	B.P :

General Examination / Allergies  
History

Clinical Diagnosis & Management Plan

came for regular ENT  
check-up

O/E (R) (L)  
EAC. cerumen (R) (L)

TM

Nose - spec (L) nasal cavity

Throat - NA (L)

Δ<sup>R</sup> :-

(R) cerumen

(L) solisax 3<sup>o</sup> eye drops  
1-1-1 x 5dy



Follow up date:

Doctor Signature

Personal Details

UHID: 00XHE1PU6TF0N51

PatentID: 129930

Name: Mr Subash Balasubramaniam

Age: 47

Gender: Male

Mobile: 9980470605

Pre-Existing Medical- Symptoms

Trials

Measurements

HR: 73 BPM

PR: 140 ms

PD: 119 ms

QRSD: 89 ms

QRS Axis: 71 deg

QT/QTc: 358/358 ms

Report ID: AHLIP\_00XHE1PU6TF0N51\_V6TF0N71

Interpretation

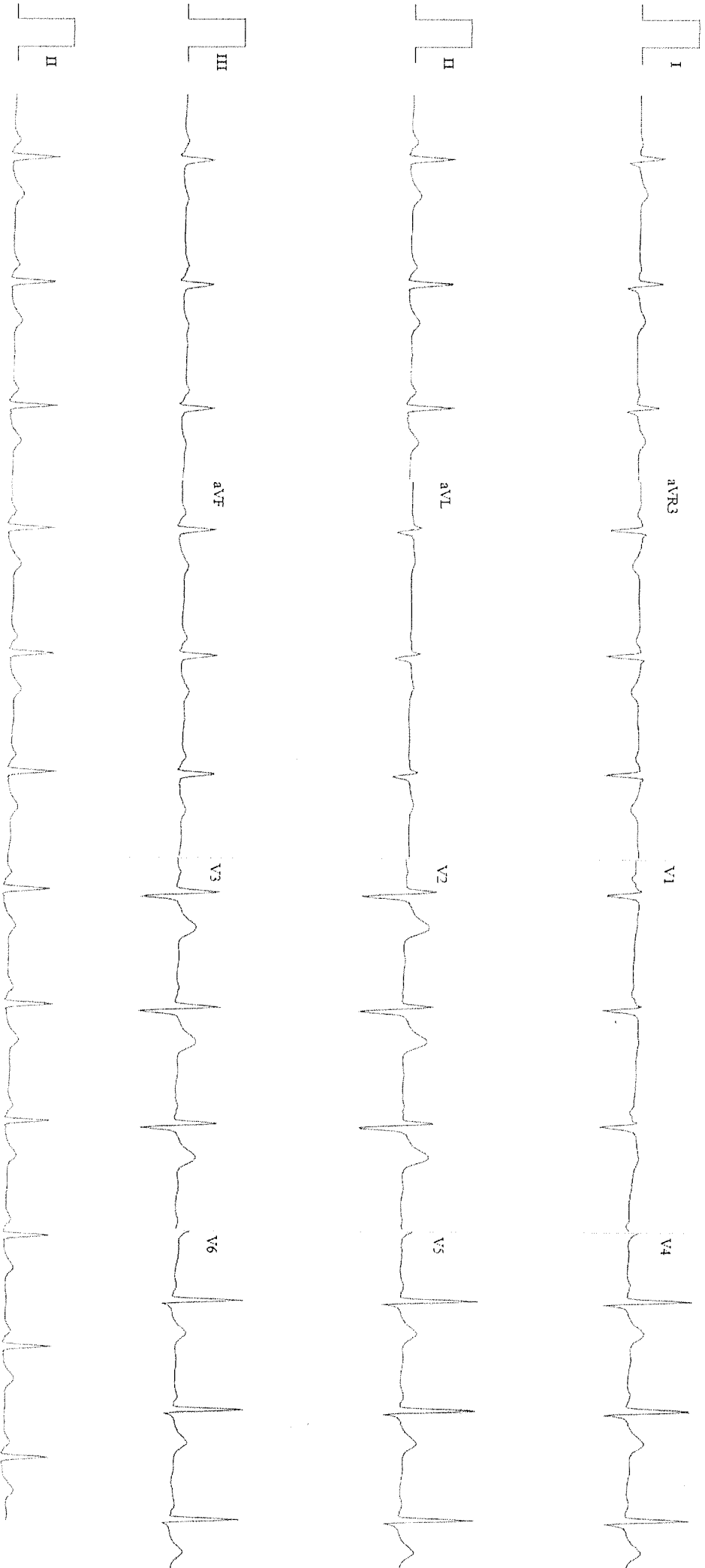
Sinus Rhythm: Regular  
Normal Axis

Apollo Hospitals  
Coimbatore

Authorized by

*Yogesh Kothari*

Dr. Yogesh Kothari  
M.D., DNB, FESC, FEP  
Reg. No. - KMC 44005



Speed: 25 mm/sec F: 0.05 - 40 Hz Limb: 10 mm mV Chest: 10 mm mV

As a patient, I authorize you to report a based on ECG findings and should be used as an additional tool in the diagnosis of cardiac symptoms and results of other investigations. I understand that this report is for informational purposes only and should not be used as a substitute for a medical consultation.

Patient Name : Mr. Subash Balasubramaanaam  
UHID : CELE.0000129930  
Reported on : 10-03-2024 09:01  
Adm/Consult Doctor :

Age : 47 Y M  
OP Visit No : CELEOPV342302  
Printed on : 10-03-2024 09:01  
Ref Doctor : SELF

---

**DEPARTMENT OF RADIOLOGY**

---

**X-RAY CHEST PA**

Both lung fields and hila are normal .

No obvious active pleuro-parenchymal lesion seen .

Both costophrenic and cardiophrenic angles are clear .

Both diaphragms are normal in position and contour .


Thoracic wall and soft tissues appear normal.

**CONCLUSION :**

No obvious abnormality seen

Printed on:10-03-2024 09:01

---End of the Report---

  
For **Dr. VIGNESH K**  
MBBS, MD Radio-Diagnosis  
Radiology

**2-D ECHO-CARDIOGRAPHY DOPPLER & COLOUR DOPPLER REPORT**

**NAME : MR SUBASH BALASUBRAMANAAM**

**DATE:09/03/2024**

**AGE/SEX: 47 Y/ M**

**REF : ARCOFEMI - MEDIWHEEL**

**UHID: 129930/03/46**

**\*\*\* MEASUREMENTS & FLOW VELOCITIES AS DEPICTED IN IMAGES OVERLEAF.**

1. NORMAL VALVES.
2. **M V : FLOW S/O DIASTOLIC DYSFUNCTION GRADE 1 ;** NORMAL FLOW ACROSS OTHER VALVES.
3. NO MR/ AR/ TR.
4. NORMAL GREAT VESSELS.
5. NORMAL SYSTEMIC VEINS & AT LEAST 3 PULMONARY VEINS SEEN DRAINING INTO LA.
6. NORMAL SIZED CHAMBERS.
7. NO REGIONAL WALL MOTION ABNORMALITIES.
8. INTACT SEPTAE ( IVS & IAS ).
9. GOOD LV & RV SYSTOLIC FUNCTION. **LVDD GRADE 1 ;**
10. PERICARDIUM : NORMAL
11. NO OBVIOUS VEGETATION / CLOTS.



**DR (CAPT.)S.V KRISHNA RAO**

**MD (PGI), DNB (Card)**

**Senior Consultant – Cardiologist**

**Reg No : ANP 19780000746KTK**

***To correlate with clinical findings & other relevant investigations .***

**Apollo Health and Lifestyle Limited**

(CIN - U85110TG2000PLC115819)

Regd. Office: 1-10-60/62, Ashoka Raghupathi Chambers, 5th Floor, Begumpet, Hyderabad, Telangana - 500 016.


Ph No: 040-4904 7777, Fax No: 4904 7744 | Email ID: enquiry@apollohl.com | www.apollohl.com

APOLLO CLINICS NETWORK KARNATAKA

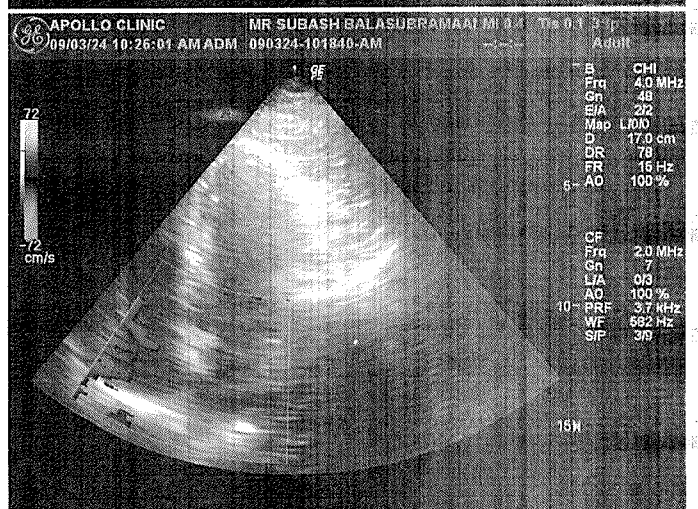
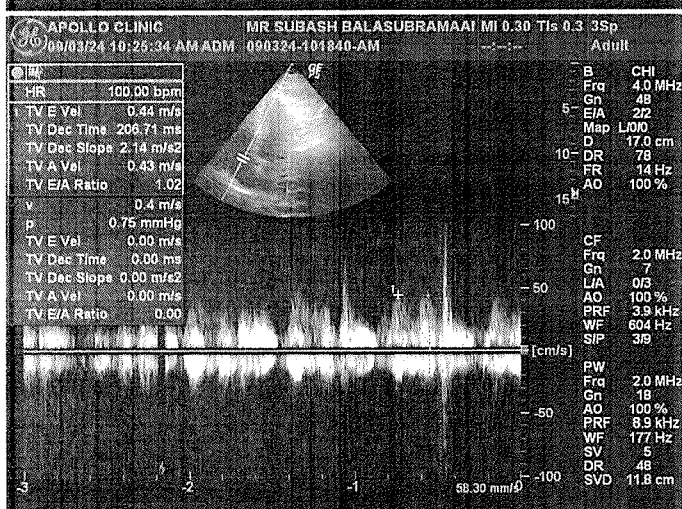
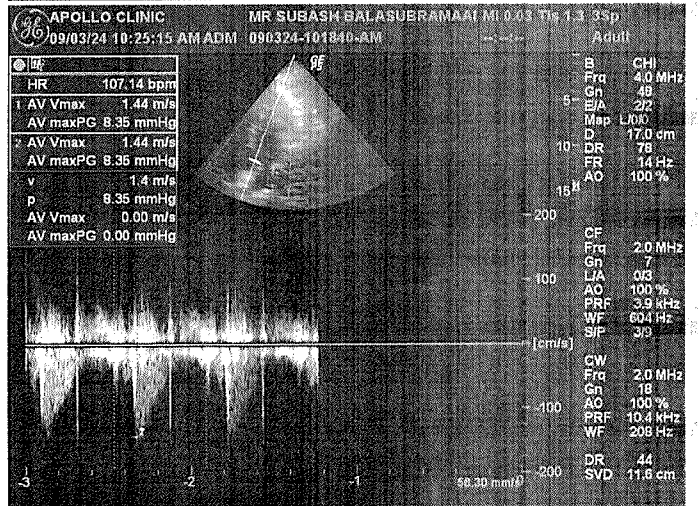
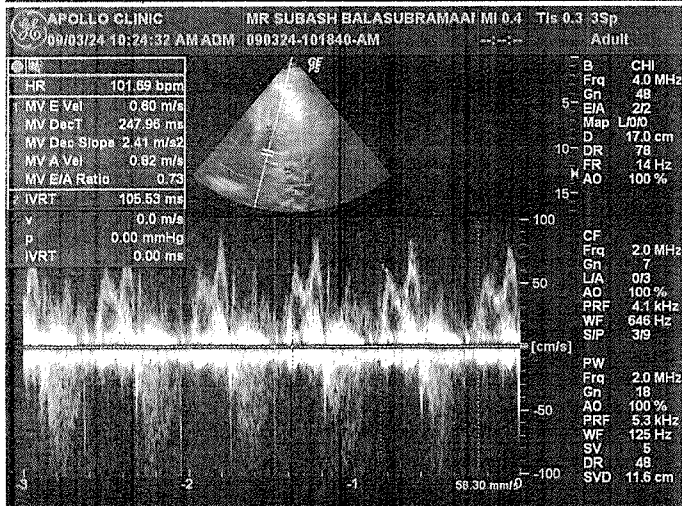
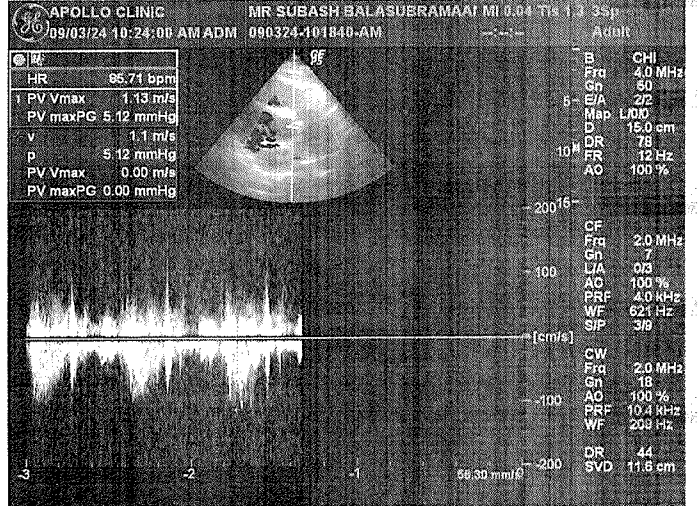
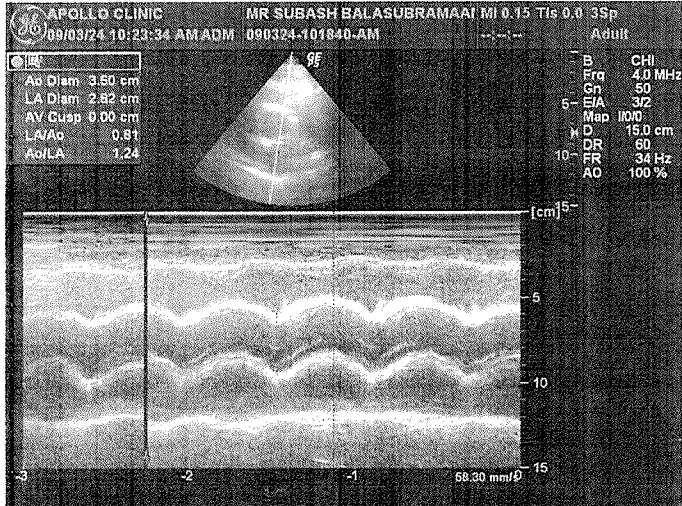
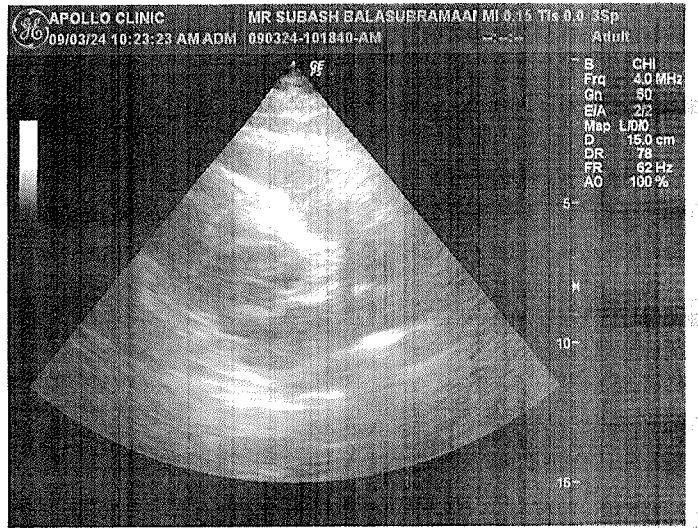
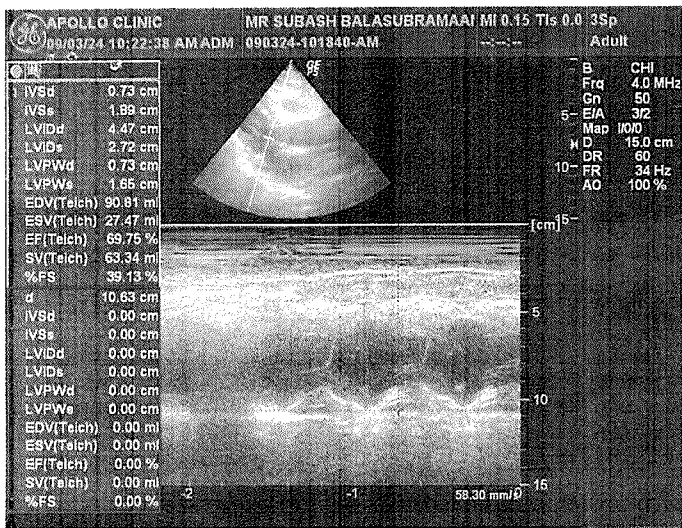
**Bangalore** (Basavanagudi | Bellandur | Electronic City | Fraser Town | HSR Layout | Indira Nagar | JP Nagar | Kundalahalli | Koramangala | Sarjapur Road) **Mysore** (VV Mohalla)

Online appointments: www.apolloclinic.com

TO BOOK AN APPOINTMENT

 **1860 500 7788**





<b>NAME:</b>	MR. SUBASH BALASUBRAMAANAAM
<b>AGE / SEX:</b>	47 YRS/ MALE
<b>DATE:</b>	09/03/2024
<b>REFERRED BY:</b>	ARCOFEMI

**ABDOMINAL ULTRASONOGRAPHY REPORT**

**LIVER:** appear normal in size and increased echogenicity. No focal lesion seen. The intra hepatic biliary and portal venous radicals are normal. Portal vein and CBD is normal

**GALL BLADDER:** moderately distended and appears normal. No abnormal wall thickening / pericholecystic fluid seen.

**PANCREAS:** Normal to the extent visualized.

**SPLEEN:** normal in size and echo texture. No focal lesion noted.

**KIDNEYS:** Both kidneys are normal in size and echo texture. Normal cortico-medullary differentiation is maintained. No calculus / hydronephrosis on both sides.

**PELVIC ORGANS:**

Urinary bladder is moderately distended and appears normal.

Prostate appear normal in size and echogenicity.

No free fluid in the abdomen and pelvis.

**IMPRESSION:**

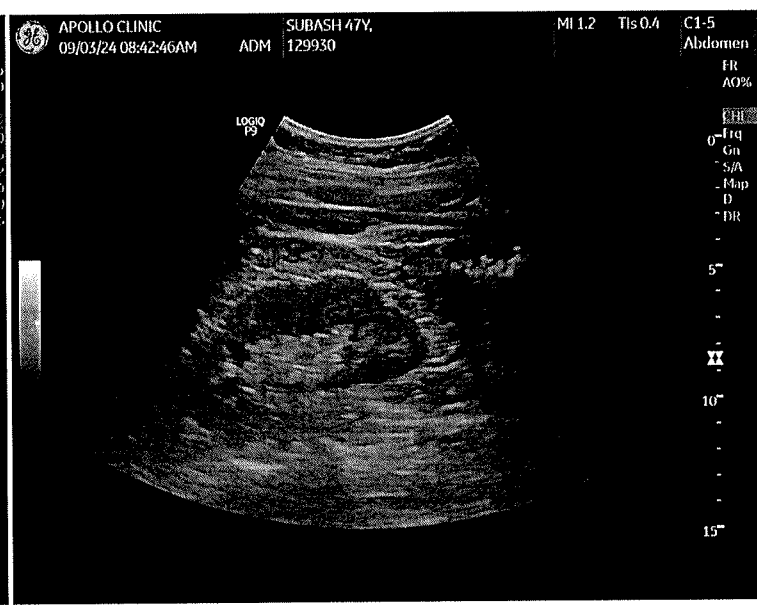
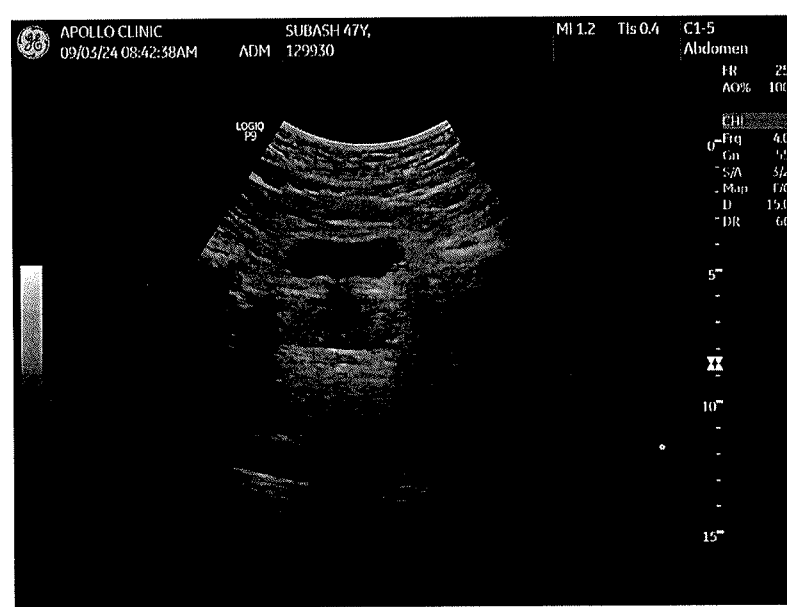
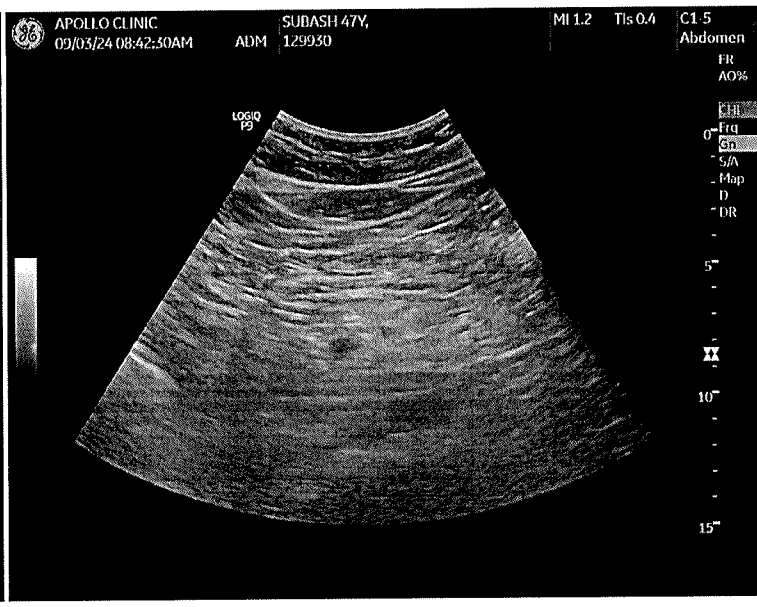
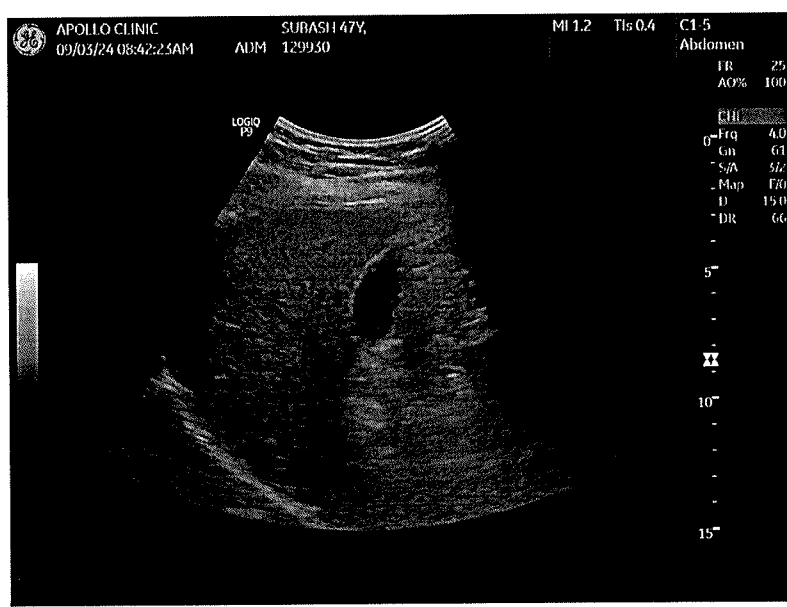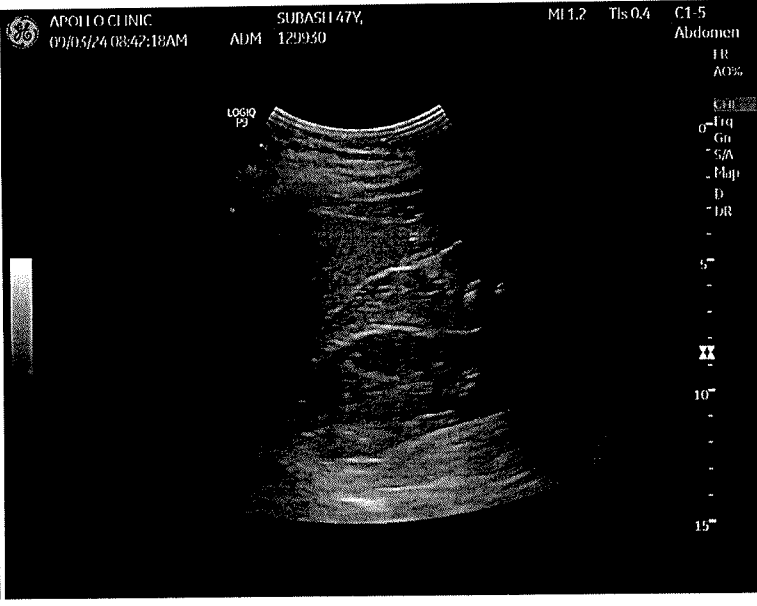
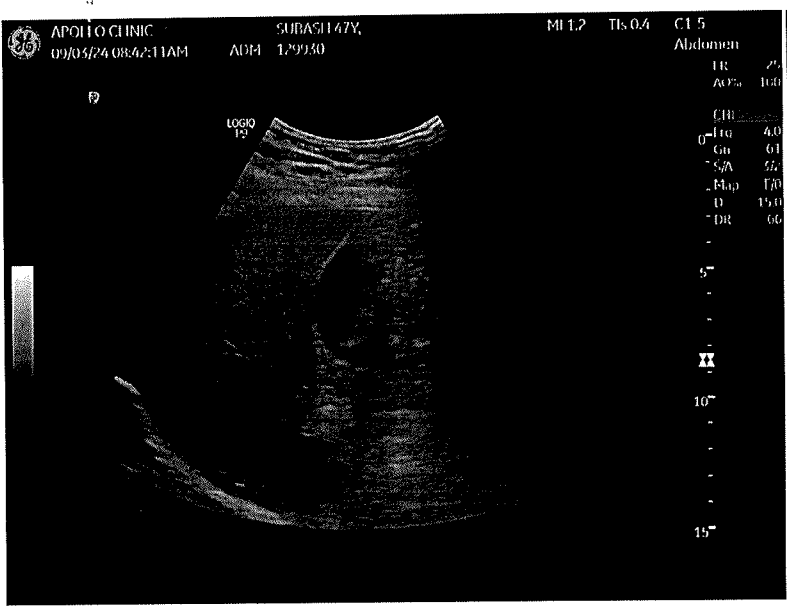
- **Grade I fatty liver.**

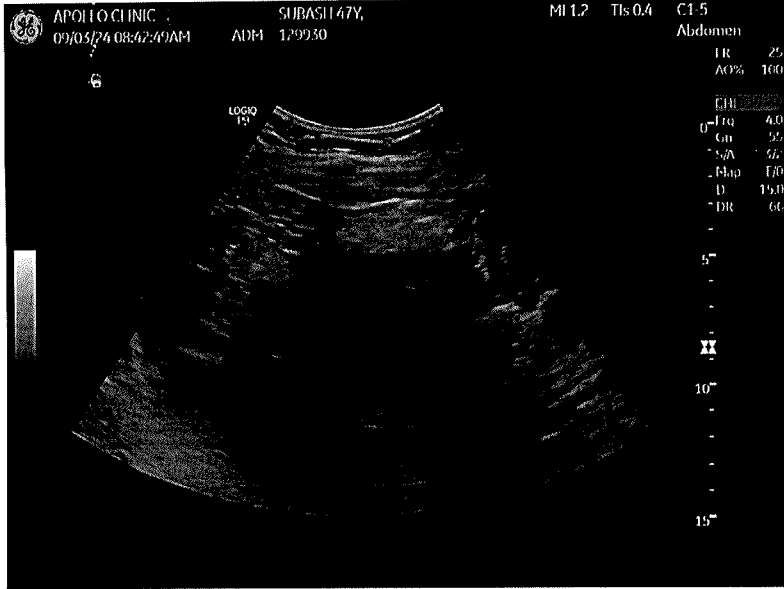*To correlate clinically & with other investigations.  
Not for medico-legal purpose*



**DR. VIGNESH K**

**CONSULTANT RADIOLOGIST**





DL No. : KA05 20120009633 DOI : 10/05/2012 FORM - 7  
NAME : SUBASH BALASUBRAMANIAM : [See Rule 16(2)]  
D.O.B : 01/10/1976 B.G. : O+  
VALID TILL : 30/09/2026(NT)




VALID THROUGHOUT INDIA  
COV : LMV 10/05/2012  
: MCWOG 24/02/2022

DDOI : 24.02.2022

S/o : BALASUBRAMANIAM K  
ADDRESS : FLAT NO B2-007 MAHENDRA AARNA  
KAMMASANDRA VILLAGE ROAD ANANTH  
NAGAR E CITY PHASE 2  
ANEKAL, BANGALORE 560100

Sign. Of Holder

  
Sign. Licencing Authority  
CHANDAPURA-KA59

**Fwd: Health Check up Booking Confirmed Request(bobS12671),Package Code-PKG10000367, Beneficiary Code-299338**

Sunitha P.P <sunithapp@gmail.com>

Sat 2024-03-09 7:55 AM

To: Electronic City <ecity@apolloclinic.com>

----- Forwarded message -----

From: **Mediwheel** <wellness@mediwheel.in>

Date: Sun, 3 Mar, 2024, 5:24 pm

Subject: Health Check up Booking Confirmed Request(bobS12671),Package Code-PKG10000367, Beneficiary Code-299338

To: <sunithapp@gmail.com>

Cc: <customercare@mediwheel.in>

**011-41195959**

Dear **Sunitha P P**,

We are pleased to confirm your health checkup booking request with the following details.

- Hospital Package Name** : Mediwheel Full Body Annual Plus Above 50 Male
- Patient Package Name** : Mediwheel Full Body Health Checkup Male Above 40
- Name of Diagnostic/Hospital** : Apollo Clinic - Electronic City
- Address of Diagnostic/Hospital-** Apollo Clinic, 323/100, Opp.Ajmera infinity Apartment, Neeladri Nagar, Electronic city Phase -1, Electronic city - 560100
- City** : Bangalore
- State** :
- Pincode** : 560100
- Appointment Date** : 09-03-2024
- Confirmation Status** : Booking Confirmed
- Preferred Time** : 8:30am
- Booking Status** : Booking Confirmed

Member Information		
Booked Member Name	Age	Gender
Subash Balasubramaanaam	47 year	Male

**Note - Please note to not pay any amount at the center.**

**Instructions to undergo Health Check:**