



Dr. Vivek Kumar
 MBBS, MS (RIMS, RANCHI)
 Specialist in PHACO & Medical Retina

ISO 9001 : 2015 Certified Hospital



Super Speciality Hospital
 (A Unit of Hazaribag Hope and Health Care Pvt. Ltd.)

OUT DOOR PATIENT SLIP

Date of Consultation :- 24/04/24

Full Name :- Goutam Ram

Age / Sex :- 38/M

| | | | | | |
|------------------------|--------|----------------|---------|-----------------|--|
| Current Medications :- | | | | Past History :- | |
| Height | Weight | Blood Pressure | Pulse | BMI | |
| | | 120/70 mmHg | 98b/min | SP02 100% | |

Chief complaints :-

Regular check-up

History & Examinations :-

VuK 6/6
 6/6
 N/A = 210

Ref:
 Cat - RE - NAD

- Ade
 17 2/2 Soften - (R/L)
 o o o

Prescription of glass for near work only

RE = + 1.50 D sph - NB





UHID : UNREGISTERED
Patient Name : GOUTAM RAM
Age/Gender : 38/Female
Cons. Doctor : MO. Arogam



Bill No. : ASH/B/23-24/12056
Sample Received : 24-02-2024 11:18:46
Report Released : 24-02-2024 02:43

| BLOOD GROUP | | | |
|-------------|----------|------|-----------------------|
| Test | Result | Unit | Biological Ref. Range |
| ABO | "A" | | |
| RH | POSITIVE | | |

-----End Of Report-----

Please Correlate Clinically



Dr. R.K Mahall
MBBS,MD(RIMS,Ranchi)

Doctor Signature



Dr. Anajana
MBBS,MD(Patho);RIMS

Doctor Signature



UHID : UNREGISTERED
Patient Name : GOUTAM RAM
Age/Gender : 38/Female
Cons. Doctor : MO. Arogam



Bill No. : ASH/B/23-24/12056
Sample Received : 24-02-2024 11:18:46
Report Released : 24-02-2024 12:54

CBC (COMPLETE BLOOD COUNT)

| Test | Result | Unit | Biological Ref. Range |
|--|--------|------------|-----------------------|
| Hb% (Haemoglobin) | 16.2 | gm/dl | 11.0-16.0 |
| Total Leucocytes Count | 6960 | cells/cumm | 4000 - 11000 |
| Neutrophils | 54 | % | 40-70% |
| lymphocytes | 36 | % | 18-40 % |
| Monocytes | 07 | % | 2-10% |
| Eosinophils | 03 | % | 1-6% |
| Basophils Percentage | 00 | % | 0-1 |
| Platelet Count | 1.94 | Lac/cmm | 1.5 - 4.5 |
| Total RBC | 5.0 | milli/cmm | 3.8-4.5 |
| PCV (Packed Cell Volume) | 50 | % | 37 - 47 |
| Mean Corpuscular Volume (MCV) | 105 | fl | 80-96 fL |
| Mean Corpuscular Hemoglobin (MCH) | 32 | pg | 27-32pg |
| Mean Corpuscular Hemoglobin Concentration (MCHC) | 34 | g/dl | 32.5-36 g/dL |

-----End Of Report-----

Please Correlate Clinically



Dr. R.K Mahali
MBBS,MD(RIMS,Ranchi)

Doctor Signature



Dr. Anajana
MBBS,MD(Pathol),RIMS

Doctor Signature

Address :- Zila Parisad Bhawan, District Board Chowk, Hazaribag - 825301 (Jharkhand)

☎ 06546-260500/501 ☎ 7319942219 ☎ hzbarogyam@gmail.com ☎ www.hzbarogyam.com



Super Speciality Hospital
(A Unit of Hazaribag Hope and Health Care Pvt. Ltd.)

UHID : CASH
Patient Name : GOUTAM RAM
Age/Gender : 38/Female
Cons. Doctor : MO. Arogyam

Bill No : ASH/B/23-24/12056
Sample Received : 2024-02-24 11:18:46
Report Released : 2024-02-24 07:01:26

| Test | Result | Units | Reference Range |
|-------------------------------------|--------|-------|-----------------|
| ESR(Erythrocyte Sedimentation Rate) | 10.0 | mm/hr | 0 - 20 |
| Blood Sugar (PP) | 136.0 | mg/dl | 70-140 |
| Blood Sugar (F) | 103.0 | mg/dl | 70-110 |
| GAMMA GT,Serum | 37.0 | U/L | 10-45 |

-----End Of Report-----

Please Correlate Clinically

Dr. R.K Mahali
MBBS,MD(RIMS,Ranchi)
Biochemist Signature



Dr. Anajana
MBBS,MD(Patho),RIMS
Pathologist Signature

Address :- Zila Parisad Bhawan, District Board Chowk, Hazaribag - 825301 (Jharkhand)

📞 06546-260500/501 📞 7319942219 📧 hzbarogyam@gmail.com 🌐 www.hzbarogyam.com



Super Speciality Hospital
(A Unit of Hazaribag Hope and Health Care Pvt. Ltd.)

UHID : UNREGISTERED
Patient Name : GOUTAM RAM
Age/Gender : 38/Female
Cons. Doctor : MO. Arogam



Bill No. : ASH/B/23-24/12056
Sample Received : 24-02-2024 11:18:46
Report Released : 24-02-2024 03:10

LIPID PROFILE

| Test | Result | Unit | Biological Ref. Range |
|-----------------|--------------|-------|-----------------------|
| Cholesterol | 224.0 | mg/dl | 140.0-250.0 |
| Triglycerides | 232.0 | mg/dl | 25-160 |
| HDL Cholesterol | 49.0 | mg/dl | 30-80 |
| LDL Cholesterol | 129.0 | mg/dl | 90-140 |
| VLDL | 46.0 | mg/dl | 15 - 32 |

-----End Of Report-----

Please Correlate Clinically



Dr. R.K Mahali
MBBS,MD(RIMS,Ranchi)

Doctor Signature



Dr. Anajana
MBBS,MD(Patho),RIMS

Doctor Signature

Address :- Zila Parisad Bhawan, District Board Chowk, Hazaribag - 825301 (Jharkhand)

📞 06546-260500/501 📞 7319942219 📧 hzbarogyam@gmail.com 🌐 www.hzbarogyam.com



UHID : UNREGISTERED
Patient Name : GOUTAM RAM
Age/Gender : 38/Female
Cons. Doctor : MO. Arogyam



Bill No. : ASH/B/23-24/12056
Sample Received : 24-02-2024 11:18:46
Report Released : 24-02-2024 03:11

LFT (LIVER FUNCTION TEST)

| Test | Result | Unit | Biological Ref. Range |
|-----------------------------------|--------------|-------|-----------------------|
| Bilirubin Total | 1.1 | gm/dl | 0.1 - 1.2 |
| S.Bilirubin (Direct) | 0.3 | mg/dl | 0-1.0 |
| S.Bilirubin (Indirect) | 0.8 | mg/dl | 0-0.55 |
| Alanine Transaminase(ALT/SGPT) | 70.0 | IU/L | 0-42 |
| Aspartate Transaminase (AST/SGOT) | 150.0 | IU/L | 0-42 |
| Alkaline Phosphatase | 158.0 | IU/L | 80-190 |
| Total Proteins | 8.0 | gm/dl | 6.6-8.3 |
| Albumin | 4.8 | g/dl | 3.4 - 4.8 |
| Globulin | 3.2 | g/dl | 2.3 - 4.6 |

-----End Of Report-----

Please Correlate Clinically



Dr. R.K Mahali
MBBS,MD(RIMS,Ranchi)

Doctor Signature



Dr. Anajana
MBBS,MD(Patho),RIMS

Doctor Signature

Address :- Zila Parisad Bhawan, District Board Chowk, Hazaribag - 825301 (Jharkhand)

📞 06546-260500/501 📞 7319942219 📧 hzbarogyam@gmail.com 🌐 www.hzbarogyam.com



UHID : UNREGISTERED
Patient Name : GOUTAM RAM
Age/Gender : 38/Female
Cons. Doctor : MO. Arogam



Bill No. : ASH/B/23-24/12056
Sample Received : 24-02-2024 11:18:46
Report Released : 24-02-2024 03:13

KFT (KIDENEY FUNCTION TEST)

| Test | Result | Unit | Biological Ref. Range |
|---------------------|--------|--------|-----------------------|
| Blood Urea | 18.0 | mg/dl | 15 - 45 |
| Serum Creatinine | 1.0 | mg/dl | 0.6-1.5 |
| SERUM URIC ACID | 4.9 | mg/dl | 3.5 - 7.0 |
| Serum Sodium[Na+] | 142.0 | mmol/L | 135-150 |
| Serum Potassium[K+] | 4.3 | mmol/L | 3.5-5.5 |
| Calcium | 10.0 | mg/dl | 8.7-11.0 |
| Blood Sugar (R) | 103.0 | mg/dl | 70-150 |

-----End Of Report-----

Please Correlate Clinically



Dr. R.K Mahall
MBBS,MD(RIMS,Ranchi)

Doctor Signature



Dr. Anajana
MBBS,MD(Patho),RIMS

Doctor Signature

Address :- Zila Parisad Bhawan, District Board Chowk, Hazaribag - 825301 (Jharkhand)

📞 06546-260500/501 📞 7319942219 📧 hzbarogyam@gmail.com 🌐 www.hzbarogyam.com



UHID : UNREGISTERED
Patient Name : GOUTAM RAM
Age/Gender : 38/Female
Cons. Doctor : MO. Arogam



Bill No. : ASH/B/23-24/12056
Sample Received : 24-02-2024 11:18:46
Report Released : 24-02-2024 03:14

URINE ROUTINE EXAMINATION

| Test | Result | Unit | Biological Ref. Range |
|----------------------------------|----------|------|-----------------------|
| PHYSICAL EXAMINATION | | | |
| Volume | 20ML | | |
| COLOUR | P.YELLOW | | |
| APPEREANCE | CLEAR | | |
| Specific Gravity | 1.010 | | |
| CHEMICAL EXAMINATION | | | |
| Ph | 6.0 | | |
| Sugar | NIL | | |
| Albumin | NIL | | |
| Ketone Bodies | NEGATIVE | | |
| Urine Bile Salt | NIL | | |
| Bile Pigment | NIL | | |
| MICROSCOPICAL EXAMINATION | | | |
| Pus Cell | 2-4/HPF | | |
| Epithelial Cell | A FEW | | |
| RBC | NIL | /HPF | |
| Bacteria | NIL | | |
| Casts | NIL | | |
| Others | NIL | | |

-----End Of Report-----

Please Correlate Clinically



Dr. R.K Mahali
MBBS,MD(RIMS,Ranchi)
Doctor Signature



Dr. Anajana
MBBS,MD(Patho),RIMS
Doctor Signature

Address :- Zila Parisad Bhawan, District Board Chowk, Hazaribag - 825301 (Jharkhand)
☎ 06546-260500/501 ☎ 7319942219 ✉ hzbarogyam@gmail.com 🌐 www.hzbarogyam.com



HZB12 240224

LAB ID : HZB12 Sample Collection : 24/02/2024 13:33:24
Name : MR. GOUTAM RAM Age/Sex : 38 Yrs. / M Sample Received : 24/02/2024 13:33:24
Sent By : M/O AROGYAM HOSPITAL Printed : 25/02/2024 13:24:31 Report Released : 25/02/2024 13:10:32
Ref. By : M/O AROGYAM

T3T4TSH (THYROID FUNCTION TEST)

| Test | Result | Unit | Biological Ref. Range |
|----------------------------|--------|-------|-----------------------|
| Total T3 | 1.32 | ng/ml | 0.69-2.15 ng/ml |
| <i>Serum, Method: CLIA</i> | | | |
| Total T4 | 8.43 | µg/dl | 4.5-14.5 µg/dl |
| <i>Serum, Method: CLIA</i> | | | |

| | | | |
|-----------------------------------|------|--------|------------------|
| TSH (Thyroid Stimulating Hormone) | 4.53 | µIU/ml | 0.30-4.50 µIU/ml |
| <i>Serum, Method: CLIA</i> | | | |

| | | | |
|------|---------------------|--|--|
| NOTE | MAGLUMI 800 (SNIBE) | | |
|------|---------------------|--|--|

| FOR PREGNANT WOMEN | T3 (ng/dl) | T4 (ng/dl) | TSH (uIU/ml) |
|--------------------|------------|------------|--------------|
| 1st TRIMESTER | 71-175 | 6.5-10.1 | 0.05-3.70 |
| 2st TRIMESTER | 91-195 | 7.5-10.3 | 0.31-4.35 |
| 3st TRIMESTER | 104-182 | 6.3-9.7 | 0.41-5.18 |

(Collected At: 24/02/2024 13:33:24, Received At: 24/02/2024 13:33:24, Reported At: 25/02/2024 13:10:32)



Anjana





HZB12 240224

Name : MR. GOUTAM RAM
Sent By : M/O AROGYAM HOSPITAL
Ref. By : M/O AROGYAM

LAB ID : HZB12
Age/Sex : 38 Yrs. / M
Printed : 25/02/2024 13:24:31

Sample Collection : 24/02/2024 13:33:24
Sample Received : 24/02/2024 13:33:24
Report Released : 25/02/2024 13:10:32

HbA1c

| Test | Result | Unit | Reference Range |
|--------------------------------|--------|------|---|
| HbA1C-Glycosylated Haemoglobin | 6.46 | % | Non-diabetic: 4-6 Excellent Control: 6-7 Fair to good control: 7-8 Unsatisfactory control: 8-10 Poor Control: >10 |

EDTA Whole Blood, Method: HPLC

| | | | |
|---------------------------------|--------|-------|--|
| Estimated Average Glucose (eAG) | 138.70 | mg/dl | 90-120 mg/dL : Good control 121-150 mg/dL : Fair control 151-180 mg/dL : Unsatisfactory control >180 mg/dL : Poor control |
|---------------------------------|--------|-------|--|

EDTA Whole Blood, Method: Calculated

Interpretation:

The term HbA1c refers to Glycated Haemoglobin. Measuring HbA1c gives an overall picture of what the average blood sugar levels have been over a period of weeks/month. Higher the HbA1c, the greater the risk of developing diabetes-related complications.

(Collected At: 24/02/2024 13:33:24, Received At: 24/02/2024 13:33:24, Reported At: 24/02/2024 14:10:14)

----- End Of Report -----



Anjana



ID: I2056

BPL 24-02-2024 13:46:15

GOUTAM RAM

Male 38Years

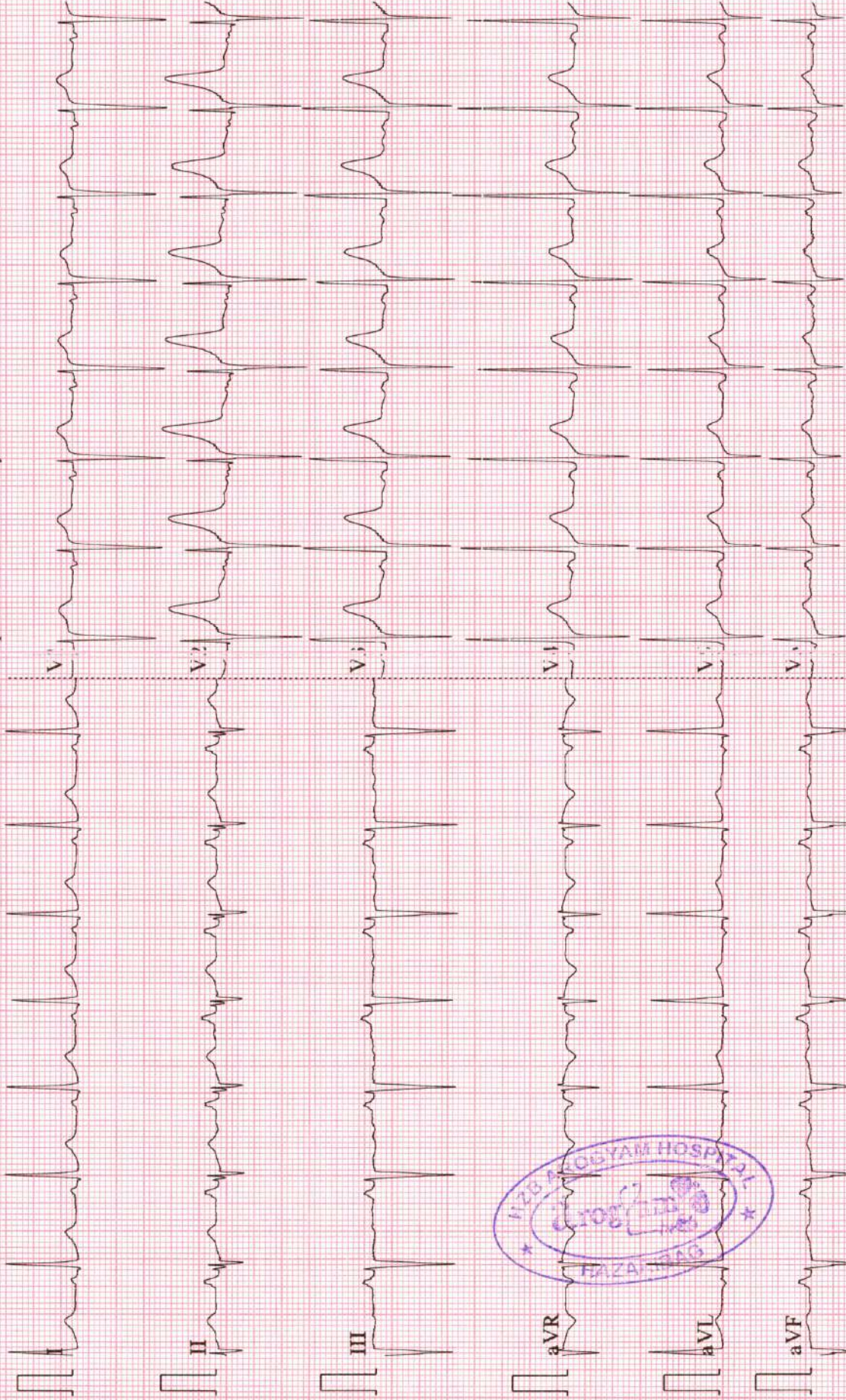
Req. No. :

HR : 91 bpm
 P : 98 ms
 PR : 134 ms
 QRS : 86 ms
 QT/QTcBz : 354/436 ms
 P/QRS/T : 69/-38/26 °
 RV5/SV1 : 1.505/1.587 mV

Diagnosis Information:

Sinus rhythm
 Lead(s) unsuitable for analysis: V6
 Possible left anterior fascicular block
 Borderline ECG

Report Confirmed by:





HAZARIBAG PATHOLOGYTM

NS-EN ISO 9001:2015 Certified

A FULLY COMPUTERISED DIAGNOSTIC LAB

Working hours : Monday to Saturday : 07:30 am to 08:00 pm : Sunday : 07:30 am to 5:00 pm.
Opp. Railway Booking Counter, Near Town Hall, NawabGanj, Hazaribag - 825301. Jharkhand.
Phone nos. : 9931817779 / 9471539321 : website : www.hzbpathology.com / email : hazaribagpathology1@gmail.com

Name of patient : Goutam Ram Age : 38 yrs Sex : M Date : 24/02/2024

Referred by : M/o Arogyam

Indication : Pain abd.

Technique : 3.5 MHz transabdominal transducer with color and multiherz options.

USG of : Whole abdomen.

This ultrasonographic study reveals,

LIVER : Normal in size (147.7 mm). **Parenchymal echotexture is increased.** No SOL or focal lesion seen in hepatic parenchyma. Intrahepatic biliary radicals is not dilated.

GALL BLADDER : Normal in shape and size. Wall appears normal. Lumen appears echofree.

CBD : Normal in course and caliber.

SPLEEN : **Mildly increased in size in bipolar length (130.7 mm).** It shows normal echogenicity of its parenchyma. The splenic vein is not dilated.

PANCREAS : Normal in shape, size and echotexture. No cystic or mass lesion seen. PD is not dilated.

UPPER RETROPERITONEUM : Aorto-mesentric angle and surrounding structure shows no lymphadenopathy.

UPPER GI TRACT : Gastro-esophageal junction, pyloro-duodenal region and jejunal loops appears normal.

RIGHT KIDNEY : Normal in size (RK - 99.2 mm). Cortical echotexture appears normal. Pelvi-calyceal system of right kidney is not dilated. Cortico medullary differentiation intact. Hilum is normal shows normal flow. Capsule appears regular margine. **An echogenic calculus of about 3.8 mm seen in upper calyx of right casting PAS.** No mass lesion seen in right kidney.

LEFT KIDNEY : Normal in size (LK - 108.2 mm). Cortical echotexture appears normal. Pelvi-calyceal system of left kidney is not dilated. Cortico medullary differentiation intact. Hilum is normal shows normal flow. Capsule appears regular margine. No calculus or mass lesion seen in left kidney.

URETERS : B/L ureter are not dilated. Hence not visualized.

UBL : Wall appears normal in thickness and smoothness. Lumen appears echofree.

PROSTATE : Prostate appears normal in volume measures 13.3 gram. Parenchymal echotexture appears normal. Capsules appears sonographically intact. No calcification seen.

OTHERS : **Faecal material filled dilated gut loop seen, having sluggish internal motion.** RIF normal. No ascites or pleural fusion is seen.

IMPRESSION : *This ultrasonographic study reveals, ---Grade - I fatty liver.

* Mild splenomegaly.

* Right nephrolithiasis.

* Faecal material filled dilated gut loop seen, having sluggish internal motion.

SUGGESTION :-Correlate clinically.

The reliability of ultrasound is about 80%. The opinion mention above should be correlate with clinical findings and other investigation modality for a final diagnosis. This is not valid for medical legal purpose.

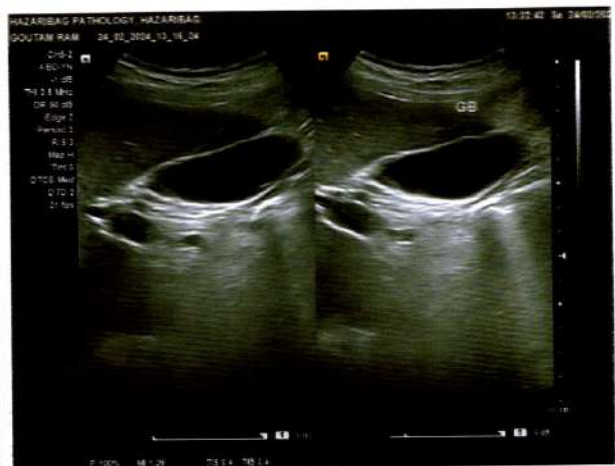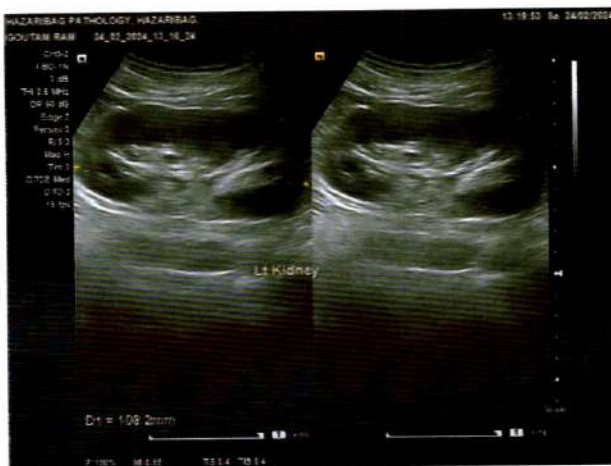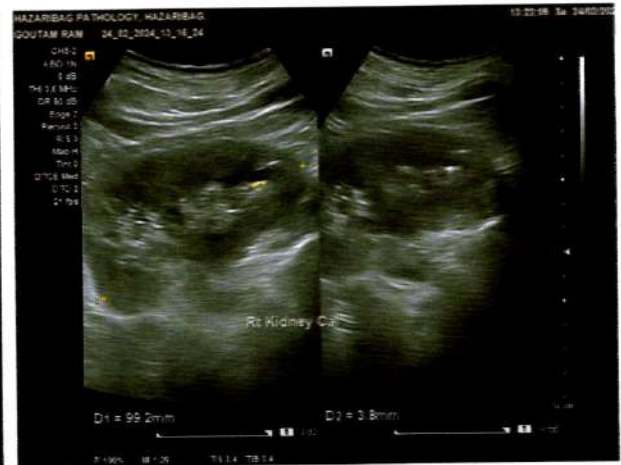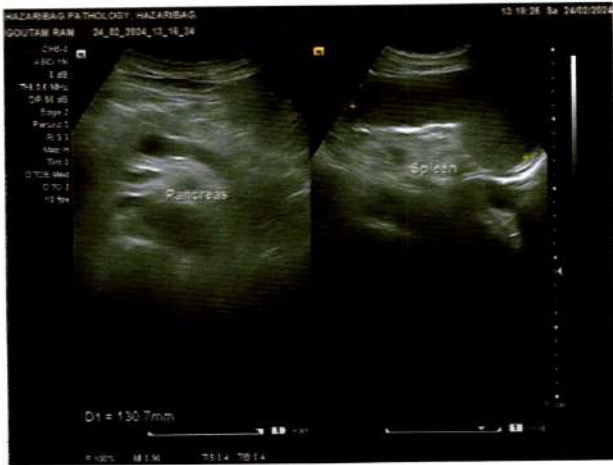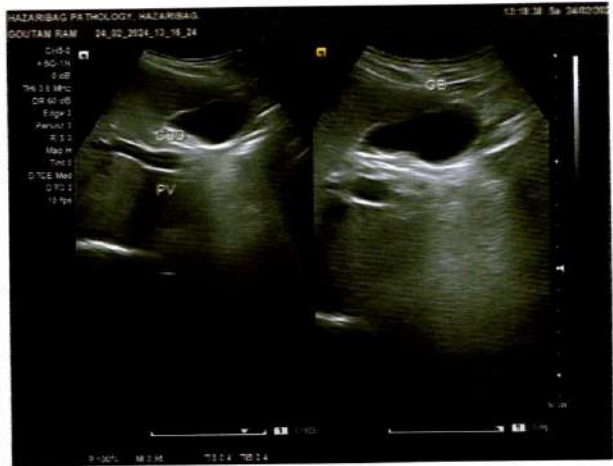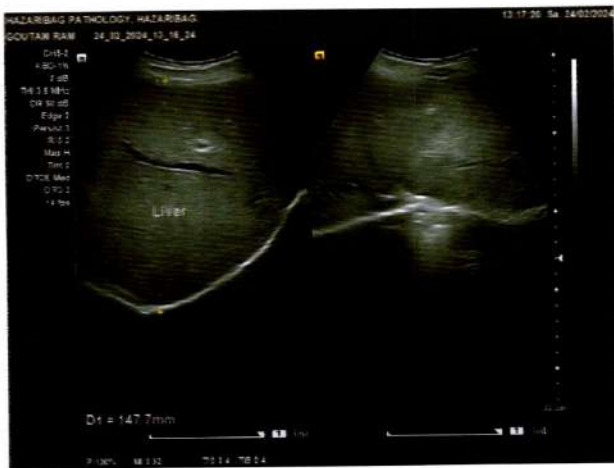Dr. A. K. Jain MBBS
Reg. No. JMC 73

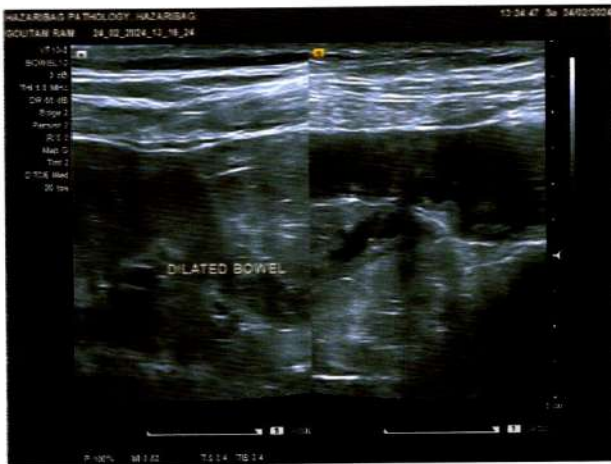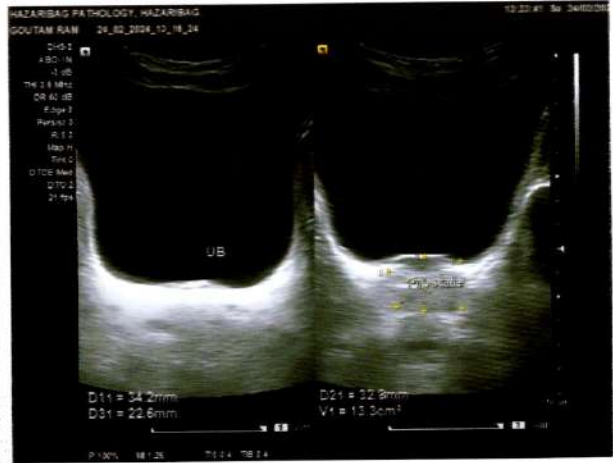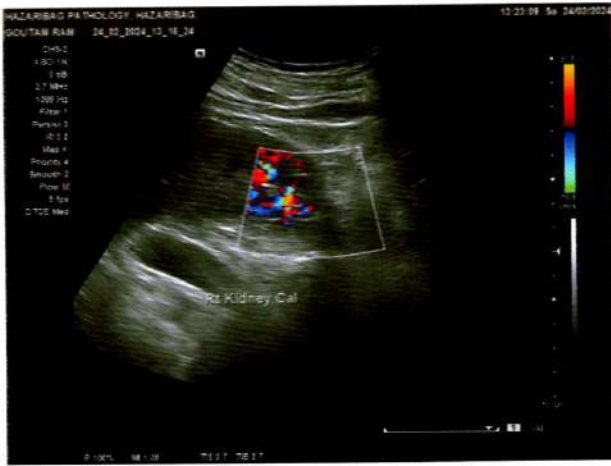Dr. Ravikant
MBBS (RIMS), DMRD (MMC, CHENNAI)
Reg. No -- 4270

Report is prepared by :- Nilofar



HAZARIBAG PATHOLOGY, HAZARIBAG.





NAME

24_FEB_2024 PM 12:43

NO. 0516

SN: 4783835

REF. DATA

VD: 12.00 CYL: MIX

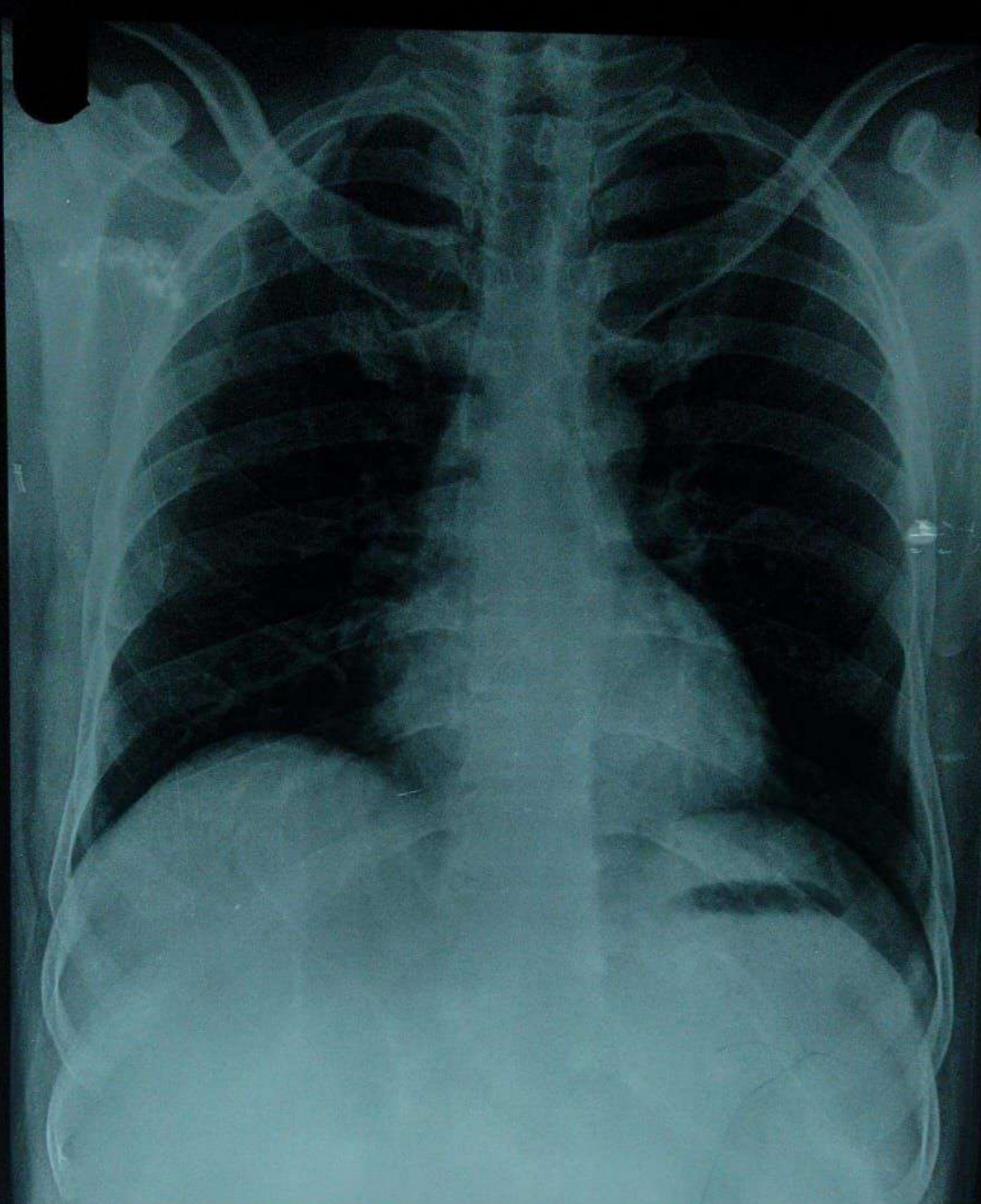
<R> S C A
+ 0.25 - 0.50 54
+ 0.25 - 0.50 53
+ 0.25 - 0.50 53
+ 0.25 - 0.50 53
S. E. - 0.00

<L> S C A
+ 0.25 + 0.25 55
+ 0.25 + 0.25 54
+ 0.25 + 0.25 54
+ 0.25 + 0.25 54
S. E. + 0.50

PD: 64.0

TOPCON

HZB AROGYAM HOSPITAL



GOUTAM RAM

38

Male

12056 24/02/2024 01:12:55 PM

Chest PA

62.7 %

Hazaribag Hope & Healthcare Pvt. Ltd. (AROGYAM)

AGFA