

ECHOCARDIOGRAPHY REPORT

Name	:	Mr. BALWANT SINGH DAHIYA		
Age/Sex	:	55 Years / Male	UHID	: 400215496
Referring Physician	:	SELF		
Indication	:	R/o CAD	Date	: 14/09/2024

M-Mode/2-D Description:

Doppler velocities (cm/sec)

Pulmonary valve		Aortic valve	
Max velocity	85	Max velocity	85
		Mean Velocity	
		Max PG	
		Mean PG	
Mitral valve		Tricuspid valve	
E	69	Max PG =	Max Velocity
A	56	Max Velocity =	TAPSE (> 1.5)
DT		Mean PG =	E/E' (< 6)
E/E'		Mean Velocity =	

Regurgitation

MR		TR	
Severity	Trace	Severity	Mild
Max Velocity		PASP	25 mmHg
AR		PR	
Severity	Nil	Severity	Nil

Measurements (mm):

	Observed Values		Normal Values
Aortic root diameter	28 mm		20-36 (22mm/M ²)
Aortic Valve Opening	mm		15-26
Left Atrium size	30 mm		19-40
	End Diastole	End Systole	Normal Values
Left Ventricle size	40 mm	24 mm	(ED= 37-56)
Interventricular Septum	10 mm		(ED= 6-12)
Posterior Wall Thickness	09 mm		(ED= 5-10)
LV Ejection Fraction (%)	55.00%		55%-80%

North East Health Care Pvt Ltd

Registered Address: Plot No 67/1, Opposite Panchamrut Bunglows, Near Shukan Mall, OFF Science City Road, Sola, Daskroi, Ahmedabad- 380060, Gujarat, India

Correspondence Address: Marengo Asia Hospitals, Golf Course Ext. Road, Sushant Lok-2, Sector 56, Gurugram, Haryana - 122011

☎ 1800 309 9999 ■ helpdesk@marengoasia.com

CIN No. U85110GJ2010PTC146108, PAN No. AACDN4016H, GST No. 06AACDN4016H1Z5



H-2019-0615


BALWANT SINGH DAHIYA, 400215496

Final Interpretation:-

Study done at HR of ~ 74 bpm

- No LV Regional wall motion abnormality, LVEF ~ 55%
- Normal RV systolic function.
- Normal Cardiac chamber dimensions.
- Trace MR, No MS, No AS/AR.
- Mild TR with (RVSP ~ 25 mmHg), No PS/PR.
- Normal mitral inflow pattern.
- No intra-cardiac clot/ Vegetation / Pericardial effusion seen.
- IVC normal in size with normal respiratory variation (RAP ~ 3 mmHg).

Dr. Anshul Goyal
MD, Medicine
Attending consultant- Cardiology


Dr. Yogendra Singh Rajput
MBBS, MD, DM FSCAI
Interventional Cardiologist
Associate Clinical Director-Cardiology

North East Health Care Pvt Ltd

Registered Address: Plot No 67/1, Opposite Panchamrut Bunglows, Near Shukan Mall, OFF Science City Road,
Sola, Daskroi, Ahmedabad- 380060, Gujarat, India

Correspondence Address: Marengo Asia Hospitals, Golf Course Ext. Road, Sushant Lok-2, Sector 56, Gurugram, Haryana - 122011
☎ 1800 309 9999 ■ helpdesk@marengoasia.com

CIN No. UB5110GJ2010PTC146108, PAN No. AADCN4016H, GST No. 06AADCN4016H1ZS





North East Health Care Private Limited
Golf Course Ext Rd, Sushant Lok II, Sector 56 Gurugram
Haryana
91-124-4131091
91-124-4131091



Visit Date	: 17/09/2024 1:01PM	UHID	: 400215496
Visit/IP No.	: 88610	Doctor Name	: Dr.M K Singh
Patient Name	: Mr. BALWANT SINGH DAHIYA	Visit Type	:
DOB	: 20/05/1969	Mobile	: 9891549116
Gender/Age	: 55 Years/Male	Department	: Internal Medicine
Sponsor	: Cash Paying	Address	: D 75 ASHOK VIHA R , Gurugram, Haryana, INDIA
State	: Haryana	City	: Gurugram

Vital Sign

Vital Date

T2DM

PHC

LDC 138

Ad
①

Diet diet.

PSA 12-1

• Urologer Ref.

BSF 130 / PD 249

• Conti sue alididile

HS Ac 7.2

M

Dr. Mohan Kumar Singh
MBBS, MD, FICP
Senior Consultant - Internal Medicine
North East Health Care Private Limited
Golf Course Extension Road, Sushant Lok-II
Sector-56, Gurugram
Regn. No. - HMC 4950

82 folly hi
P221



North East Health Care Pvt Ltd

Registered Address: Plot No 67/1, Opposite Pancharut Bunglows, Near Shukan Mall, OFF Science City Road, Sola, Daskroi, Ahmedabad- 380060, Gujarat, India **Dr.M K Singh**

Correspondence Address: Marengo Asia Hospitals, Golf Course Ext. Road, Sushant Lok-2, Sector 56, Gurugram, Haryana - 122011

© 1800 309 9999 helpdesk@marengoasia.com

CIN No. U85110GJ2010PTC146108, PAN No. AADCN4016H, GST No. 06AADCN4016H1ZS

Prepared By mk.singh

Printed at 17/09/2024 13:31

Page: 1 Of 1



Patient ID :	400215496	Paient Name :	BALWANT SHINGH DHAYIYA
Age :	55 YRS	Sex :	M
Ref Physician :		Modality/Study :	US
Study Date :	14-Sep-2024	Reported Date :	«ReportedDate»
Study :			

ULTRASOUND WHOLE ABDOMEN

LIVER is normal in size (14.8 cm) and **shows increased echotexture**. No evidence of any focal lesion or IHBR dilation is present.

GALL BLADDER is well distended and lumen is echofree. Wall thickness is normal. No pericholecystic fluid is seen.

SPLEEN is normal in size and echotexture. No focal lesion is seen.

PANCREAS is normal in size and echotexture. Peripancreatic fat planes are clear.

RIGHT KIDNEY: is normal in size (11.1 x 4.2 cm) and position and outline corticomedullary differentiation is maintained. There is no evidence of any focal lesion / calculus / backpressure changes.

LEFT KIDNEY: is normal in size (9.9 x 5.1 cm) and position and outline corticomedullary differentiation is maintained. There is no evidence of any focal lesion / calculus / backpressure changes.

URINARY BLADDER is *minimally distended*.

PROSTATE is enlarged in size and measures ~ 4.9 x 4.8 x 3.6 cm (vol: 46.6 cc).

No free fluid is seen in the abdomen

IMPRESSION:

- Grade I fatty liver.
- Prostatomegaly.

Please correlate clinically.

Dr. Shallini Mittal
Senior Consultant Radiologist
Dept. of Radiology
MT-SJ

North East Health Care Pvt Ltd

Registered Address: Plot No 67/1, Opposite Panchamrut Bunglows, Near Shukan Mall, OFF Science City Road, Sola, Daskroi, Ahmedabad- 380060, Gujarat, India

Correspondence Address: Marengo Asia Hospitals, Golf Course Ext. Road, Sushant Lok-2, Sector 56, Gurugram, Haryana - 122011

☎ 1800 309 9999 ■ helpdesk@marengoasia.com

CIN No. U85110GJ2010PTC146108, PAN No. AACDN4016H, GST No. 06AACDN4016H1ZS



H-2019-0615

4/9/24

Dentist

Mrs. Saira. 49/F

ofc

dentist
consultee.

Caries 56

Class I Caries 1/1

T/T

Adv. full
prophylaxis.

months out

Adv. restoration

1/1
56

[Handwritten signature]

North East Health Care Pvt Ltd

Registered Address: Plot No 67/1, Opposite Panchamrut Bunglows, Near Shukan Mall, OFF Science City Road, Sola, Daskroi, Ahmedabad- 380060, Gujarat, India

Correspondence Address: Marengo Asia Hospitals, Golf Course Ext. Road, Sushant Lok-2, Sector 56, Gurugram, Haryana - 122011

1800 309 9999 helpdesk@marengoasia.com

CIN No. U85110GJ2010PTC146108, PAN No. AACDN4016H, GST No. 06AACDN4016H1ZS



H-2019-0615

Dental

14/9/24

Balwant 55/M

O/E

Slav P
Cul P.

Adv. full Mouth oral
prophylax 1

↳

North East Health Care Pvt Ltd

Registered Address: Plot No 67/1, Opposite Panchamrut Bunglows, Near Shukan Mall, OFF Science City Road, Sola, Daskroi, Ahmedabad- 380060, Gujarat, India

Correspondence Address: Marengo Asia Hospitals, Golf Course Ext. Road, Sushant Lok-2, Sector 56, Gurugram, Haryana - 122011
☎ 1800 309 9999 📧 helpdesk@marengoasia.com

CIN No. U85110GJ2010PTC146108, PAN No. AADCN4016H, GST No. 06AADCN4016H1Z5



H-2019-0615

Dental

14/9/24

Balwant 56/M

O/E

slap
cut P.

Adv. full month
prophylax 1

↳

North East Health Care Pvt Ltd

Registered Address: Plot No 67/1, Opposite Panchamrut Bunglows, Near Shukan Mall, OFF Science City Road,
Sola, Daskroi, Ahmedabad- 380060, Gujarat, India

Correspondence Address: Marengo Asia Hospitals, Golf Course Ext. Road, Sushant Lok-2, Sector 56, Gurugram, Haryana - 122011
1800 309 9999 helpdesk@marengoasia.com

CIN No. U85110GJ2010PTC146108, PAN No. AACDN4016H, GST No. 06AADCN4016H1ZS



6/01
22/0

101778 Pra...
achar

RR-02M

1800

marengoasiahospitals.com



Name	Mr. Balwant Singh Dahiya	Date	17-09-24
Age/Gender	55 years / M	UHID	400215496

Presenting Complaints: NA

Past History: DM | HT | CAD

⊕ ⊖ ⊖

IOP: Right Eye: ^{4 yrs} 16 mmHg Left Eye: 16 mmHg POG RE:

LE:

Spectacles	Sphere	Cylinder	Axis	Vision	Near add	Vision
Right Eye	+0.75	-	-	6/6	+2.25	N6
Left Eye	+0.50	-	-	6/6	+2.25	N6

Clinical Features:

_____ hml -

Diagnosis: Refr error

Advice:

↳ for detailed refraction + follow up.

Dr Shibal Bhartiya

Clinical Director, Ophthalmology | Program Director, Community Outreach & Wellness
HN-15650

For Appointments: 8882638735 | For Clinical queries: +91 9818700269 | www.drshibalbhartiya.com

North East Health Care Pvt Ltd

Registered Address: Plot No 67/1, Opposite Panchamrut Bunglows, Near Shukan Mall, OFF Science City Road,
Sola, Daskroi, Ahmedabad- 380060, Gujarat, India

Correspondence Address: Marengo Asia Hospitals, Golf Course Ext. Road, Sushant Lok-2, Sector 56, Gurugram, Haryana - 122011
☎ 1800 309 9999 ■ helpdesk@marengoasia.com

CIN No. U85110GJ2010PTC146108, PAN No. AADCN4016H, GST No. 06AADCN4016H1Z5



400215496
55 Years

mr balwant singh
Male

14-Sep-24 11:24:04 AM

MARENGO ASIA HOSPITALS

EMERGENCY

Rate 71 . Sinus rhythm.....normal P axis, V-rate 50- 99
FR 142 . Consider right atrial enlargement.....P >0.24mV limb lead
QRSD 80 . Left ventricular hypertrophy.....multiple voltage criteria
QT 359 . Anterior Q waves, possibly due to LVH.....Q >30ms, V1 V2 & LVH
QTc 391 . Artifact in lead(s) V1 and baseline wander in lead(s) V1,V2

--AXIS--

P 65

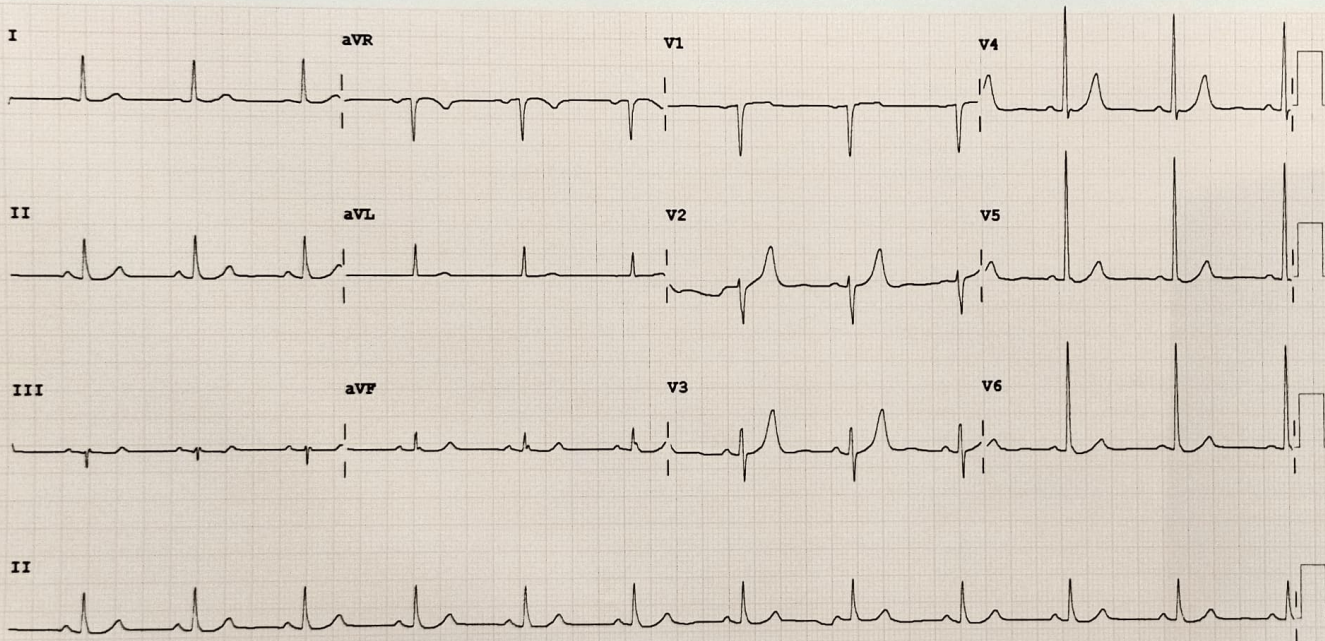
QRS 31

T 45

- ABNORMAL ECG -

12 Lead; Standard Placement

Unconfirmed Diagnosis



Device:

Speed: 25 mm/sec

Limb: 10 mm/mV

Chest: 10.0 mm/mV

F 50~ 0.50- 40 Hz W

100B CL

P?