

<i>Patient Name</i>	KUNDAN KUMARI 41Y/F	<i>Patient ID</i>	35008
<i>Age/D.O.B</i>	41	<i>Gender</i>	F
<i>Ref Doctor</i>	SELF	<i>Date</i>	28 Sep 24

XRAY RADIOGRAPH CHEST - PA


Observations

Prominent bronchovascular markings are noted in bilateral lung fields.
The cardiac silhouette is normal.
Both hila are normal.
No focal lung lesion is seen.
Soft tissues of the chest wall are normal.
No mediastinal abnormality is visible.
Cardiothoracic ratio is normal.

Impression

Prominent bronchovascular markings are noted in bilateral lung fields.

Reported By,

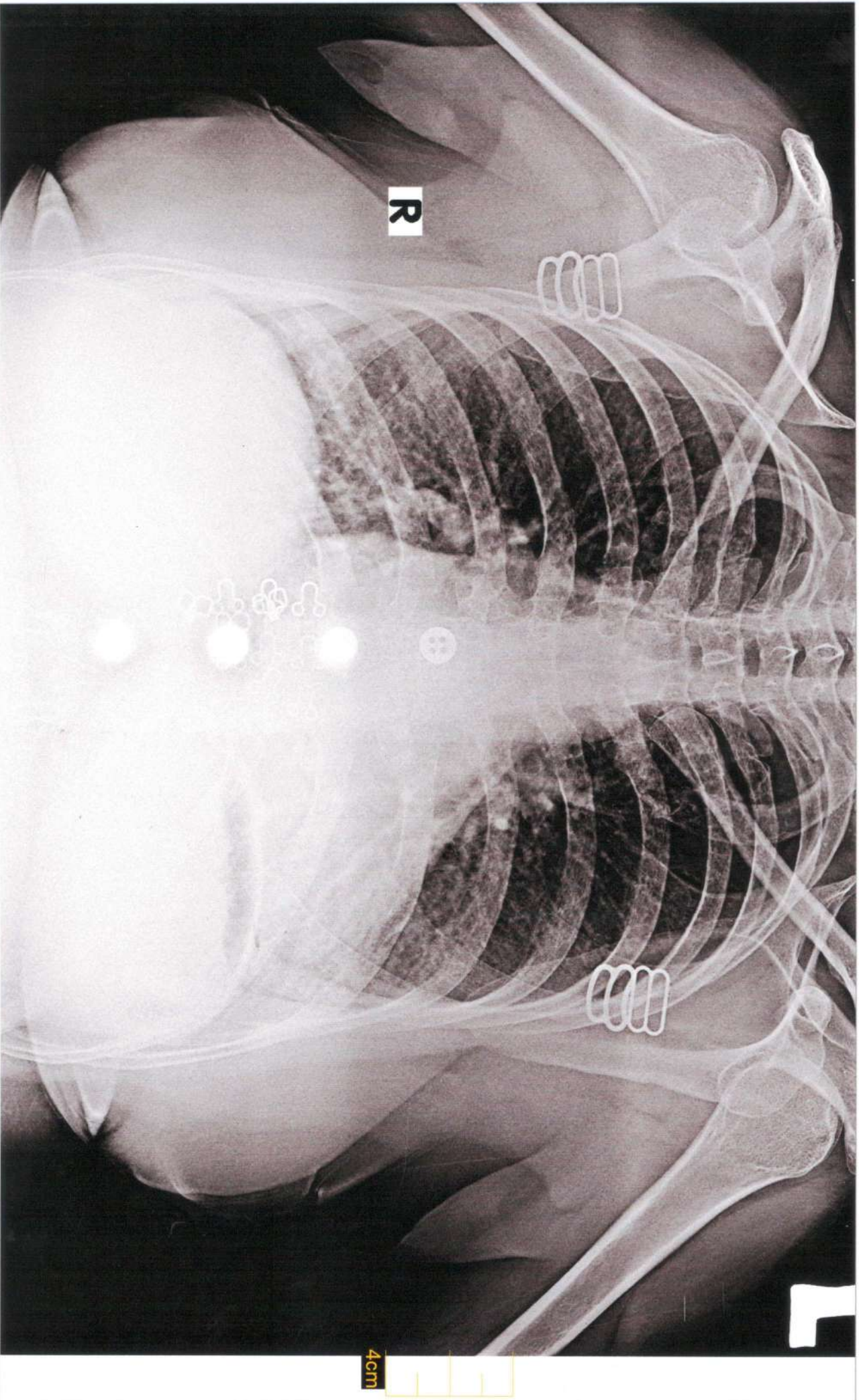


Dr. Aditi Agarwal

MBBS, MD

Consultant Radiologist

TSMC - TSMC/FMR/30641



<i>Patient Name</i>	RAVI SHANKAR 47Y/M	<i>Patient ID</i>	35007
<i>Age/D.O.B</i>	47	<i>Gender</i>	M
<i>Ref Doctor</i>	SELF	<i>Date</i>	28 Sep 24

XRAY RADIOGRAPH CHEST - PA

Observations

Bones and soft tissue shadows appear normal.
Visualised lung fields appear normal.
Cardia is normal in size.
Both Costophrenic Recesses are clear.
Hilar Shadows are within normal limits.
Domes of Diaphragm are smooth.
Pulmonary vasculature appears normal.

Impression

Essentially normal study.

Reported By,



Dr. Kale Balaji Baliram

MBBS, DMRD, DNB

Consultant Radiologist

MMC - 2015063398

RAVI, SHANKAR, 47Y, M, : CR From 28/09/2024

