



CID : 2408321575
Name : MS.MITALI ANILKUMAR AGARWAL
Age / Gender : 36 Years / Female
Consulting Dr. : -
Reg. Location : Bhayander East (Main Centre)

Collected : 23-Mar-2024 / 10:17
Reported : 23-Mar-2024 / 15:14

Use a QR Code Scanner
Application To Scan the Code

AERFOCAMI HEALTHCARE BELOW 40 MALE/FEMALE

CBC (Complete Blood Count), Blood

<u>PARAMETER</u>	<u>RESULTS</u>	<u>BIOLOGICAL REF RANGE</u>	<u>METHOD</u>
<u>RBC PARAMETERS</u>			
Haemoglobin	12.0	12.0-15.0 g/dL	Spectrophotometric
RBC	4.68	3.8-4.8 mil/cmm	Elect. Impedance
PCV	35.6	36-46 %	Measured
MCV	76	80-100 fl	Calculated
MCH	25.8	27-32 pg	Calculated
MCHC	33.9	31.5-34.5 g/dL	Calculated
RDW	15.8	11.6-14.0 %	Calculated
<u>WBC PARAMETERS</u>			
WBC Total Count	9170	4000-10000 /cmm	Elect. Impedance
<u>WBC DIFFERENTIAL AND ABSOLUTE COUNTS</u>			
Lymphocytes	29.8	20-40 %	
Absolute Lymphocytes	2732.7	1000-3000 /cmm	Calculated
Monocytes	5.1	2-10 %	
Absolute Monocytes	467.7	200-1000 /cmm	Calculated
Neutrophils	55.7	40-80 %	
Absolute Neutrophils	5107.7	2000-7000 /cmm	Calculated
Eosinophils	8.2	1-6 %	
Absolute Eosinophils	751.9	20-500 /cmm	Calculated
Basophils	1.2	0.1-2 %	
Absolute Basophils	110.0	20-100 /cmm	Calculated
Immature Leukocytes	-		

WBC Differential Count by Absorbance & Impedance method/Microscopy.

PLATELET PARAMETERS

Platelet Count	363000	150000-400000 /cmm	Elect. Impedance
MPV	8.7	6-11 fl	Calculated
PDW	15.2	11-18 %	Calculated

RBC MORPHOLOGY

Hypochromia	Mild
Microcytosis	Occasional



CID : 2408321575
Name : MS.MITALI ANILKUMAR AGARWAL
Age / Gender : 36 Years / Female
Consulting Dr. : -
Reg. Location : Bhayander East (Main Centre)

Collected : 23-Mar-2024 / 10:17
Reported : 23-Mar-2024 / 17:08

Use a QR Code Scanner
Application To Scan the Code

Macrocytosis	-
Anisocytosis	-
Poikilocytosis	-
Polychromasia	-
Target Cells	-
Basophilic Stippling	-
Normoblasts	-
Others	-
WBC MORPHOLOGY	-
PLATELET MORPHOLOGY	-
COMMENT	Eosinophilia

Specimen: EDTA Whole Blood

ESR, EDTA WB-ESR 21 2-20 mm at 1 hr. Sedimentation

Clinical Significance: The erythrocyte sedimentation rate (ESR), also called a sedimentation rate is the rate red blood cells sediment in a period of time.

Interpretation:

Factors that increase ESR: Old age, Pregnancy, Anemia

Factors that decrease ESR: Extreme leukocytosis, Polycythemia, Red cell abnormalities- Sickle cell disease

Limitations:

- It is a non-specific measure of inflammation.
- The use of the ESR as a screening test in asymptomatic persons is limited by its low sensitivity and specificity.

Reflex Test: C-Reactive Protein (CRP) is the recommended test in acute inflammatory conditions.

Reference:

- Pack Insert
- Brigden ML. Clinical utility of the erythrocyte sedimentation rate. American family physician. 1999 Oct 1;60(5):1443-50.

*Sample processed at SUBURBAN DIAGNOSTICS (INDIA) PVT. LTD Borivali Lab, Borivali West

*** End Of Report ***



Bmhasakar

Dr.KETAKI MHASKAR
M.D. (PATH)
Pathologist



CID : 2408321575
Name : MS.MITALI ANILKUMAR AGARWAL
Age / Gender : 36 Years / Female
Consulting Dr. : -
Reg. Location : Bhayander East (Main Centre)

Collected : 23-Mar-2024 / 10:17
Reported : 23-Mar-2024 / 15:18

Use a QR Code Scanner
Application To Scan the Code

AERFOCAMI HEALTHCARE BELOW 40 MALE/FEMALE

<u>PARAMETER</u>	<u>RESULTS</u>	<u>BIOLOGICAL REF RANGE</u>	<u>METHOD</u>
GLUCOSE (SUGAR) FASTING, Fluoride Plasma	225.0	Non-Diabetic: < 100 mg/dl Impaired Fasting Glucose: 100-125 mg/dl Diabetic: >/= 126 mg/dl	Hexokinase
GLUCOSE (SUGAR) PP, Fluoride Plasma PP/R	313.0	Non-Diabetic: < 140 mg/dl Impaired Glucose Tolerance: 140-199 mg/dl Diabetic: >/= 200 mg/dl	Hexokinase
BILIRUBIN (TOTAL), Serum	1.19	0.3-1.2 mg/dl	Vanadate oxidation
BILIRUBIN (DIRECT), Serum	0.38	0-0.3 mg/dl	Vanadate oxidation
BILIRUBIN (INDIRECT), Serum	0.81	<1.2 mg/dl	Calculated
TOTAL PROTEINS, Serum	7.1	5.7-8.2 g/dL	Biuret
ALBUMIN, Serum	4.3	3.2-4.8 g/dL	BCG
GLOBULIN, Serum	2.8	2.3-3.5 g/dL	Calculated
A/G RATIO, Serum	1.5	1 - 2	Calculated
SGOT (AST), Serum	21.1	<34 U/L	Modified IFCC
SGPT (ALT), Serum	23.8	10-49 U/L	Modified IFCC
GAMMA GT, Serum	29.3	<38 U/L	Modified IFCC
ALKALINE PHOSPHATASE, Serum	86.6	46-116 U/L	Modified IFCC
BLOOD UREA, Serum	15.8	19.29-49.28 mg/dl	Calculated
BUN, Serum	7.4	9.0-23.0 mg/dl	Urease with GLDH
CREATININE, Serum	0.49	0.55-1.02 mg/dl	Enzymatic

Note: Kindly note in change in reference range w.e.f. 07-09-2023



CID : 2408321575
Name : MS.MITALI ANILKUMAR AGARWAL
Age / Gender : 36 Years / Female
Consulting Dr. : -
Reg. Location : Bhayander East (Main Centre)

Collected : 23-Mar-2024 / 14:59
Reported : 23-Mar-2024 / 18:21

Use a QR Code Scanner
Application To Scan the Code

eGFR, Serum	125	(ml/min/1.73sqm)	Calculated
		Normal or High: Above 90	
		Mild decrease: 60-89	
		Mild to moderate decrease: 45-59	
		Moderate to severe decrease: 30-44	
		Severe decrease: 15-29	
		Kidney failure: <15	

Note: eGFR estimation is calculated using 2021 CKD-EPI GFR equation w.e.f 16-08-2023

URIC ACID, Serum	3.4	3.1-7.8 mg/dl	Uricase/ Peroxidase
Urine Sugar (Fasting)	Absent	Absent	
Urine Ketones (Fasting)	Absent	Absent	
Urine Sugar (PP)	+++	Absent	
Urine Ketones (PP)	Absent	Absent	

*Sample processed at SUBURBAN DIAGNOSTICS (INDIA) PVT. LTD Borivali Lab, Borivali West
*** End Of Report ***



Bmhasakar

Dr.KETAKI MHASKAR
M.D. (PATH)
Pathologist



CID : 2408321575
Name : MS.MITALI ANILKUMAR AGARWAL
Age / Gender : 36 Years / Female
Consulting Dr. : -
Reg. Location : Bhayander East (Main Centre)

Use a QR Code Scanner Application To Scan the Code
Collected : 23-Mar-2024 / 10:17
Reported : 23-Mar-2024 / 16:26

AERFOCAMI HEALTHCARE BELOW 40 MALE/FEMALE
GLYCOSYLATED HEMOGLOBIN (HbA1c)

PARAMETER	RESULTS	BIOLOGICAL REF RANGE	METHOD
Glycosylated Hemoglobin (HbA1c), EDTA WB - CC	10.7	Non-Diabetic Level: < 5.7 % Prediabetic Level: 5.7-6.4 % Diabetic Level: >/= 6.5 %	HPLC
Estimated Average Glucose (eAG), EDTA WB - CC	260.4	mg/dl	Calculated

Intended use:

- In patients who are meeting treatment goals, HbA1c test should be performed at least 2 times a year
- In patients whose therapy has changed or who are not meeting glycemic goals, it should be performed quarterly
- For microvascular disease prevention, the HbA1C goal for non pregnant adults in general is Less than 7%.

Clinical Significance:

- HbA1c, Glycosylated hemoglobin or glycated hemoglobin, is hemoglobin with glucose molecule attached to it.
- The HbA1c test evaluates the average amount of glucose in the blood over the last 2 to 3 months by measuring the percentage of glycosylated hemoglobin in the blood.

Test Interpretation:

- The HbA1c test evaluates the average amount of glucose in the blood over the last 2 to 3 months by measuring the percentage of Glycosylated hemoglobin in the blood.
- HbA1c test may be used to screen for and diagnose diabetes or risk of developing diabetes.
- To monitor compliance and long term blood glucose level control in patients with diabetes.
- Index of diabetic control, predicting development and progression of diabetic micro vascular complications.

Factors affecting HbA1c results:

Increased in: High fetal hemoglobin, Chronic renal failure, Iron deficiency anemia, Splenectomy, Increased serum triglycerides, Alcohol ingestion, Lead/opiate poisoning and Salicylate treatment.

Decreased in: Shortened RBC lifespan (Hemolytic anemia, blood loss), following transfusions, pregnancy, ingestion of large amount of Vitamin E or Vitamin C and Hemoglobinopathies

Reflex tests: Blood glucose levels, CGM (Continuous Glucose monitoring)

References: ADA recommendations, AACC, Wallach's interpretation of diagnostic tests 10th edition.

*Sample processed at SUBURBAN DIAGNOSTICS (INDIA) PVT. LTD Borivali Lab, Borivali West

*** End Of Report ***



Dr. Jageshwar Mandal

Dr. JAGESHWAR MANDAL
CHOUPAL
MBBS, DNB PATH
Pathologist



CID : 2408321575
Name : MS.MITALI ANILKUMAR AGARWAL
Age / Gender : 36 Years / Female
Consulting Dr. : -
Reg. Location : Bhayander East (Main Centre)

Use a QR Code Scanner Application To Scan the Code
Collected : 23-Mar-2024 / 10:17
Reported : 23-Mar-2024 / 19:26

AERFOCAMI HEALTHCARE BELOW 40 MALE/FEMALE
URINE EXAMINATION REPORT

PARAMETER	RESULTS	BIOLOGICAL REF RANGE	METHOD
PHYSICAL EXAMINATION			
Color	Pale yellow	Pale Yellow	-
Reaction (pH)	5.0	4.5 - 8.0	Chemical Indicator
Specific Gravity	1.005	1.001-1.030	Chemical Indicator
Transparency	Clear	Clear	-
Volume (ml)	40	-	-
CHEMICAL EXAMINATION			
Proteins	Absent	Absent	pH Indicator
Glucose	Absent	Absent	GOD-POD
Ketones	Absent	Absent	Legals Test
Blood	Absent	Absent	Peroxidase
Bilirubin	Absent	Absent	Diazonium Salt
Urobilinogen	Normal	Normal	Diazonium Salt
Nitrite	Absent	Absent	Griess Test
MICROSCOPIC EXAMINATION			
Leukocytes(Pus cells)/hpf	2-3	0-5/hpf	
Red Blood Cells / hpf	Absent	0-2/hpf	
Epithelial Cells / hpf	1-2		
Casts	Absent	Absent	
Crystals	Absent	Absent	
Amorphous debris	Absent	Absent	
Bacteria / hpf	+(>20/hpf)	Less than 20/hpf	
Others	-		

Interpretation: The concentration values of Chemical analytes corresponding to the grading given in the report are as follows:

- Protein (1+ = 25 mg/dl , 2+ =75 mg/dl , 3+ = 150 mg/dl , 4+ = 500 mg/dl)
- Glucose(1+ = 50 mg/dl , 2+ =100 mg/dl , 3+ =300 mg/dl ,4+ =1000 mg/dl)
- Ketone (1+ =5 mg/dl , 2+ = 15 mg/dl , 3+= 50 mg/dl , 4+ = 150 mg/dl)

Reference: Pack inert

*Sample processed at SUBURBAN DIAGNOSTICS (INDIA) PVT. LTD Borivali Lab, Borivali West
*** End Of Report ***



Signature

Dr.JAGESHWAR MANDAL
CHOUPAL
MBBS, DNB PATH
Pathologist



CID : 2408321575
Name : MS.MITALI ANILKUMAR AGARWAL
Age / Gender : 36 Years / Female
Consulting Dr. : -
Reg. Location : Bhayander East (Main Centre)

Use a QR Code Scanner Application To Scan the Code
Collected : 23-Mar-2024 / 10:17
Reported : 23-Mar-2024 / 18:06

AERFOCAMI HEALTHCARE BELOW 40 MALE/FEMALE
BLOOD GROUPING & Rh TYPING

<u>PARAMETER</u>	<u>RESULTS</u>
ABO GROUP	B
Rh TYPING	Positive

NOTE: Test performed by automated Erythrocytes magnetized technology (EMT) which is more sensitive than conventional methods.

Specimen: EDTA Whole Blood and/or serum

Clinical significance:
ABO system is most important of all blood group in transfusion medicine


Limitations:

- ABO blood group of new born is performed only by cell (forward) grouping because allo antibodies in cord blood are of maternal origin.
- Since A & B antigens are not fully developed at birth, both Anti-A & Anti-B antibodies appear after the first 4 to 6 months of life. As a result, weaker reactions may occur with red cells of newborns than of adults.
- Confirmation of newborn's blood group is indicated when A & B antigen expression and the isoagglutinins are fully developed at 2 to 4 years of age & remains constant throughout life.
- Cord blood is contaminated with Wharton's jelly that causes red cell aggregation leading to false positive result
- The Hh blood group also known as Oh or Bombay blood group is rare blood group type. The term Bombay is used to refer the phenotype that lacks normal expression of ABH antigens because of inheritance of hh genotype.

References:

1. Denise M Harmening, Modern Blood Banking and Transfusion Practices- 6th Edition 2012. F.A. Davis company. Philadelphia
2. AABB technical manual

*Sample processed at SUBURBAN DIAGNOSTICS (INDIA) PVT. LTD SDRL, Vidyavihar Lab
*** End Of Report ***



Anupa

Dr. ANUPA DIXIT
M.D.(PATH)
Consultant Pathologist & Lab Director



CID : 2408321575
Name : MS.MITALI ANILKUMAR AGARWAL
Age / Gender : 36 Years / Female
Consulting Dr. : -
Reg. Location : Bhayander East (Main Centre)

Use a QR Code Scanner Application To Scan the Code
Collected : 23-Mar-2024 / 10:17
Reported : 23-Mar-2024 / 15:22

AERFOCAMI HEALTHCARE BELOW 40 MALE/FEMALE
LIPID PROFILE

PARAMETER	RESULTS	BIOLOGICAL REF RANGE	METHOD
CHOLESTEROL, Serum	188.5	Desirable: <200 mg/dl Borderline High: 200-239mg/dl High: >/=240 mg/dl	CHOD-POD
TRIGLYCERIDES, Serum	67.0	Normal: <150 mg/dl Borderline-high: 150 - 199 mg/dl High: 200 - 499 mg/dl Very high:>/=500 mg/dl	Enzymatic colorimetric
HDL CHOLESTEROL, Serum	42.4	Desirable: >60 mg/dl Borderline: 40 - 60 mg/dl Low (High risk): <40 mg/dl	Elimination/ Catalase
NON HDL CHOLESTEROL, Serum	146.1	Desirable: <130 mg/dl Borderline-high:130 - 159 mg/dl High:160 - 189 mg/dl Very high: >/=190 mg/dl	Calculated
LDL CHOLESTEROL, Serum	132.7	Optimal: <100 mg/dl Near Optimal: 100 - 129 mg/dl Borderline High: 130 - 159 mg/dl High: 160 - 189 mg/dl Very High: >/= 190 mg/dl	Calculated
VLDL CHOLESTEROL, Serum	13.4	< /= 30 mg/dl	Calculated
CHOL / HDL CHOL RATIO, Serum	4.4	0-4.5 Ratio	Calculated
LDL CHOL / HDL CHOL RATIO, Serum	3.1	0-3.5 Ratio	Calculated

*Sample processed at SUBURBAN DIAGNOSTICS (INDIA) PVT. LTD SDRL, Vidyavihar Lab
*** End Of Report ***



Dr. Vrushi Shroff

Dr.VRUSHALI SHROFF
M.D.(PATH)
Pathologist



CID : 2408321575
 Name : MS.MITALI ANILKUMAR AGARWAL
 Age / Gender : 36 Years / Female
 Consulting Dr. : -
 Reg. Location : Bhayander East (Main Centre)

Use a QR Code Scanner Application To Scan the Code
 Collected : 23-Mar-2024 / 10:17
 Reported : 23-Mar-2024 / 15:08

AERFOCAMI HEALTHCARE BELOW 40 MALE/FEMALE
THYROID FUNCTION TESTS

<u>PARAMETER</u>	<u>RESULTS</u>	<u>BIOLOGICAL REF RANGE</u>	<u>METHOD</u>
Free T3, Serum	3.9	3.5-6.5 pmol/L	CLIA
Free T4, Serum	13.8	11.5-22.7 pmol/L	CLIA
sensitiveTSH, Serum	5.310	0.55-4.78 microIU/ml First Trimester:0.1-2.5 Second Trimester:0.2-3.0 Third Trimester:0.3-3.0	CLIA



CID : 2408321575
Name : MS.MITALI ANILKUMAR AGARWAL
Age / Gender : 36 Years / Female
Consulting Dr. : -
Reg. Location : Bhayander East (Main Centre)

Collected : 23-Mar-2024 / 10:17
Reported : 23-Mar-2024 / 15:08

Use a QR Code Scanner
Application To Scan the Code

Interpretation:

A thyroid panel is used to evaluate thyroid function and/or help diagnose various thyroid disorders.

Clinical Significance:

- 1)TSH Values between high abnormal upto15 microIU/ml should be correlated clinically or repeat the test with new sample as physiological factors can give falsely high TSH.
- 2)TSH values may be trasiently altered becuae of non thyroidal illness like severe infections,liver disease, renal and heart severe burns, trauma and surgery etc.

TSH	FT4 / T4	FT3 / T3	Interpretation
High	Normal	Normal	Subclinical hypothyroidism, poor compliance with thyroxine, drugs like amiodarone, Recovery phase of non-thyroidal illness, TSH Resistance.
High	Low	Low	Hypothyroidism, Autoimmune thyroiditis, post radio iodine Rx, post thyroidectomy, Anti thyroid drugs, tyrosine kinase inhibitors & amiodarone, amyloid deposits in thyroid, thyroid tumors & congenital hypothyroidism.
Low	High	High	Hyperthyroidism, Graves disease, toxic multinodular goiter, toxic adenoma, excess iodine or thyroxine intake, pregnancy related (hyperemesis gravidarum, hydatiform mole)
Low	Normal	Normal	Subclinical Hyperthyroidism, recent Rx for Hyperthyroidism, drugs like steroids & dopamine), Non thyroidal illness.
Low	Low	Low	Central Hypothyroidism, Non Thyroidal Illness, Recent Rx for Hyperthyroidism.
High	High	High	Interfering anti TPO antibodies, Drug interference: Amiodarone, Heparin, Beta Blockers, steroids & anti epileptics.

Diurnal Variation:TSH follows a diurnal rhythm and is at maximum between 2 am and 4 am , and is at a minimum between 6 pm and 10 pm. The variation is on the order of 50 to 206%. Biological variation:19.7%(with in subject variation)

Reflex Tests:Anti thyroid Antibodies,USG Thyroid ,TSH receptor Antibody. Thyroglobulin, Calcitonin

Limitations:

1. Samples should not be taken from patients receiving therapy with high biotin doses (i.e. >5 mg/day) until atleast 8 hours following the last biotin administration.
2. Patient samples may contain heterophilic antibodies that could react in immunoassays to give falsely elevated or depressed results. this assay is designed to minimize interference from heterophilic antibodies.

Reference:

- 1.O.koulouri et al. / Best Practice and Research clinical Endocrinology and Metabolism 27(2013)
- 2.Interpretation of the thyroid function tests, Dayan et al. THE LANCET . Vol 357
- 3.Tietz ,Text Book of Clinical Chemistry and Molecular Biology -5th Edition
- 4.Biological Variation:From principles to Practice-Callum G Fraser (AACC Press)

*Sample processed at SUBURBAN DIAGNOSTICS (INDIA) PVT. LTD SDRL, Vidyavihar Lab

*** End Of Report ***



Anupa

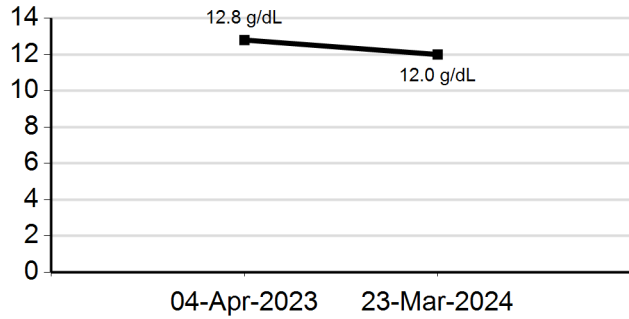
Dr.ANUPA DIXIT
M.D.(PATH)
Consultant Pathologist & Lab Director



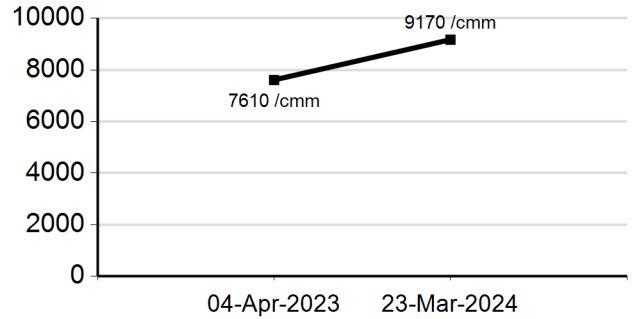
Use a QR Code Scanner Application To Scan the Code

CID : 2408321575
 Name : MS.MITALI ANILKUMAR AGARWAL
 Age / Gender : 36 Years / Female
 Consulting Dr. : -
 Reg. Location : Bhayander East (Main Centre)

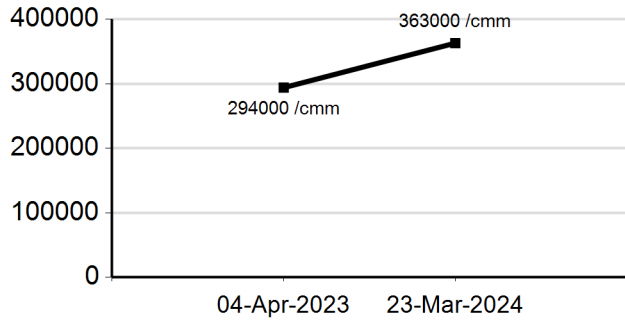
Haemoglobin



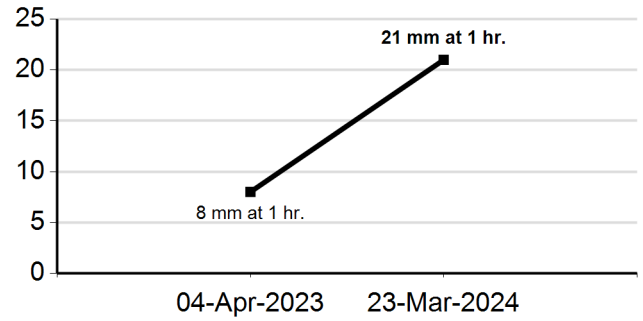
WBC Total Count



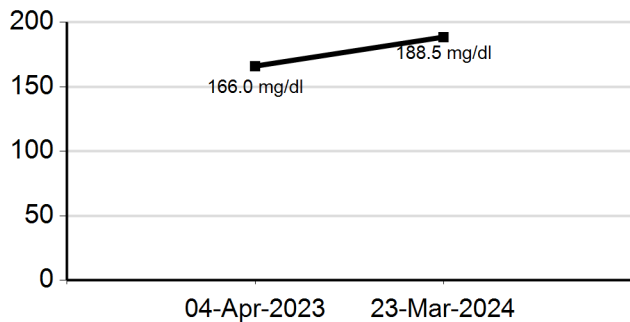
Platelet Count



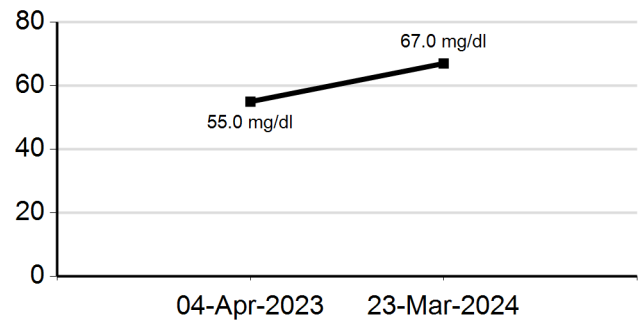
ESR



CHOLESTEROL



TRIGLYCERIDES

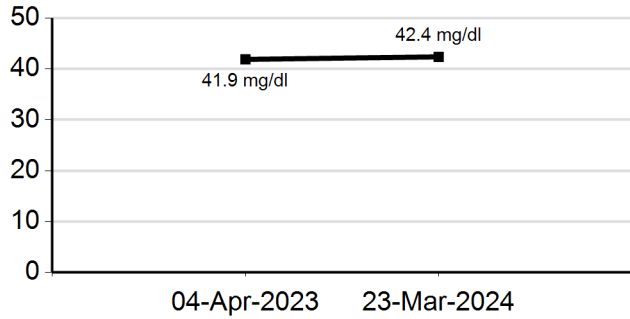




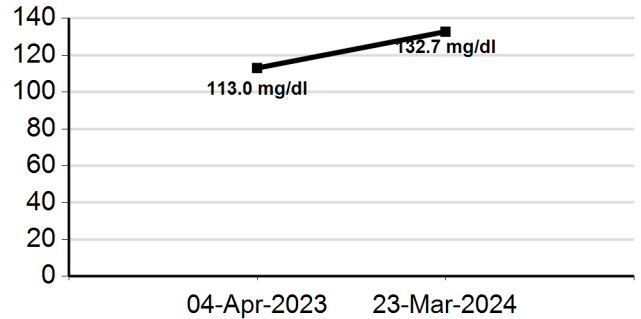
CID : 2408321575
 Name : MS.MITALI ANILKUMAR AGARWAL
 Age / Gender : 36 Years / Female
 Consulting Dr. : -
 Reg. Location : Bhayander East (Main Centre)

Use a QR Code Scanner
 Application To Scan the Code

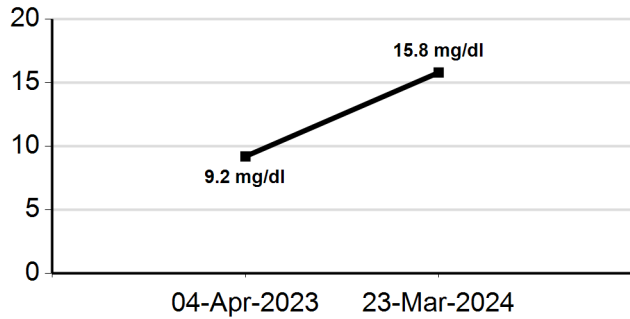
HDL CHOLESTEROL



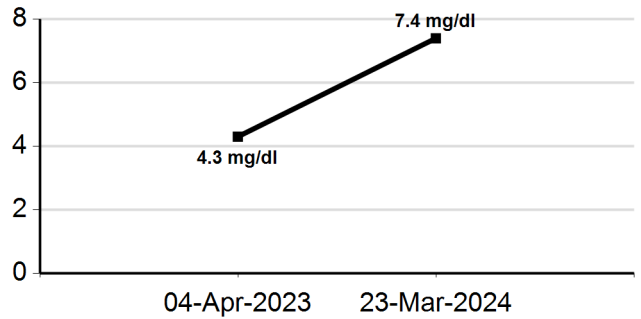
LDL CHOLESTEROL



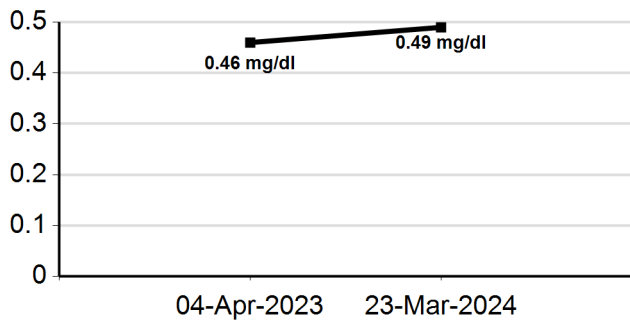
BLOOD UREA



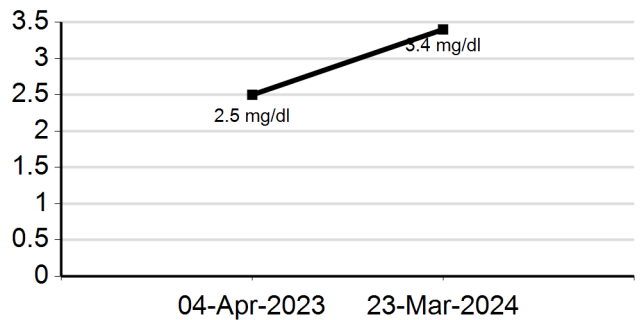
BUN



CREATININE



URIC ACID

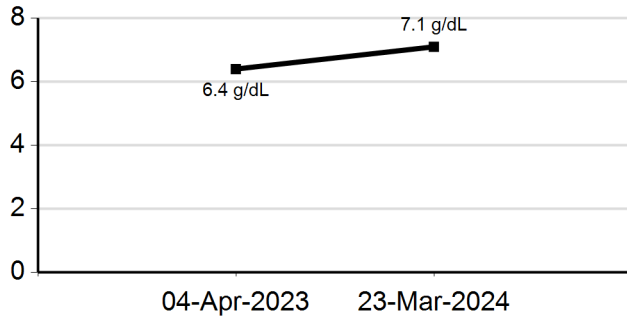




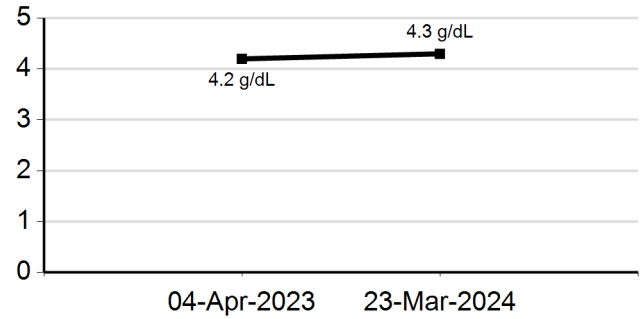
Use a QR Code Scanner
 Application To Scan the Code

CID : 2408321575
 Name : MS.MITALI ANILKUMAR AGARWAL
 Age / Gender : 36 Years / Female
 Consulting Dr. : -
 Reg. Location : Bhayander East (Main Centre)

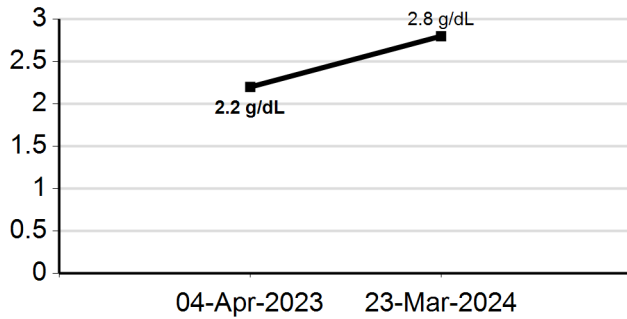
TOTAL PROTEINS



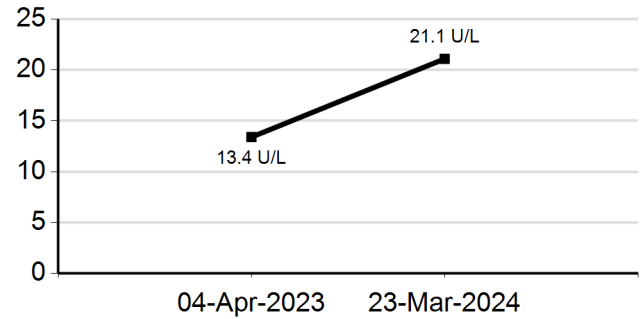
ALBUMIN



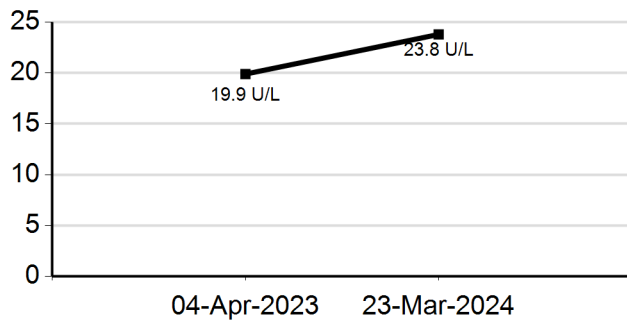
GLOBULIN



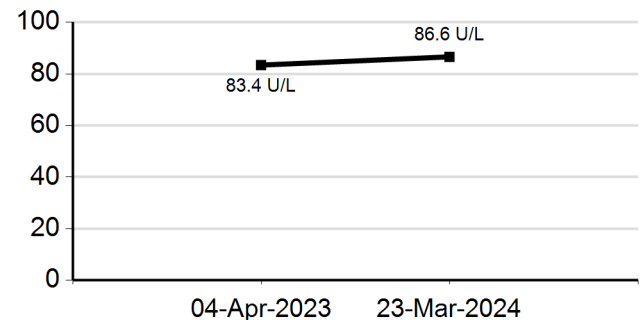
SGOT (AST)



SGPT (ALT)



ALKALINE PHOSPHATASE

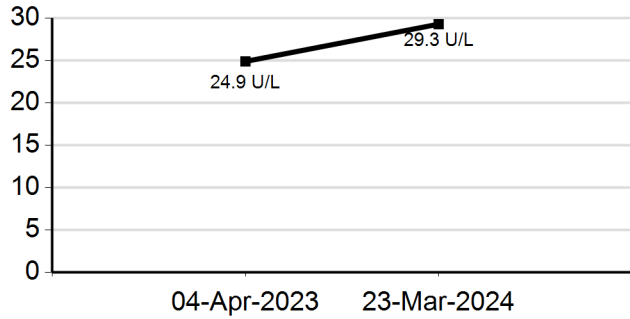




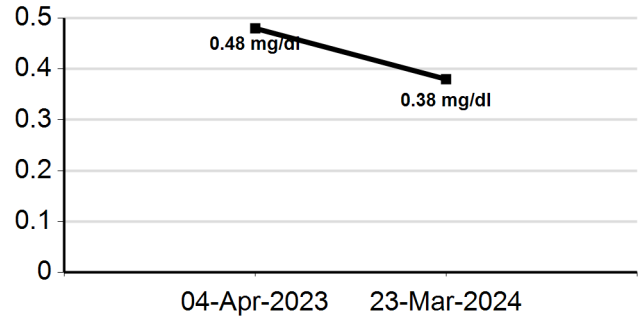
Use a QR Code Scanner Application To Scan the Code

CID : 2408321575
 Name : MS.MITALI ANILKUMAR AGARWAL
 Age / Gender : 36 Years / Female
 Consulting Dr. : -
 Reg. Location : Bhayander East (Main Centre)

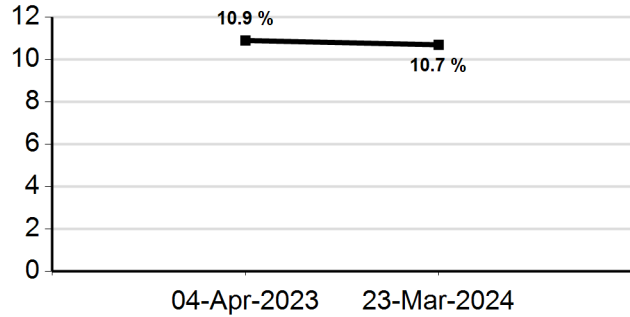
GAMMA GT



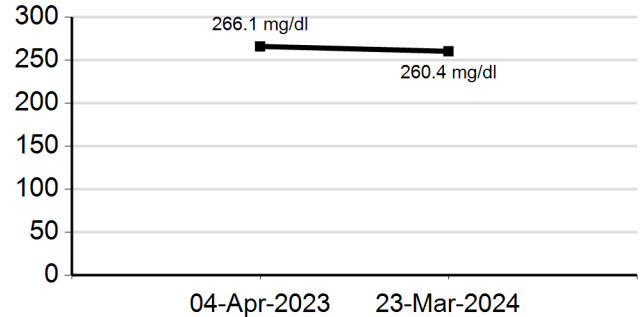
BILIRUBIN (DIRECT)



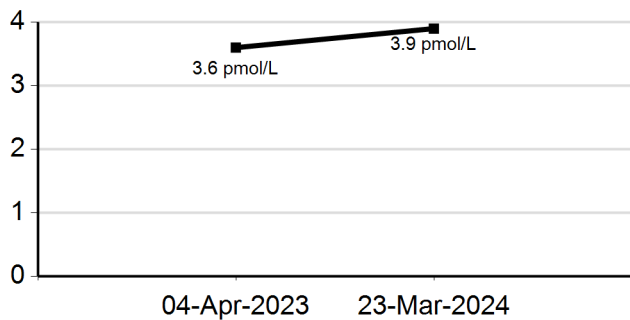
Glycosylated Hemoglobin (HbA1c)



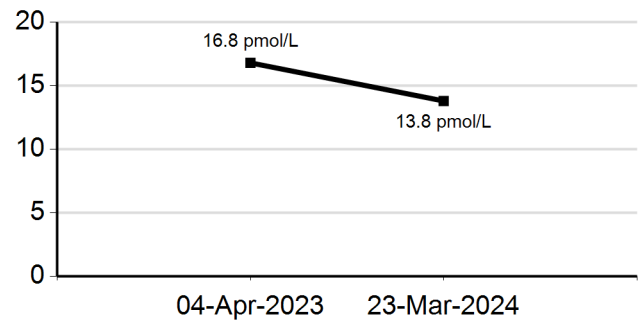
Estimated Average Glucose (eAG)



Free T3



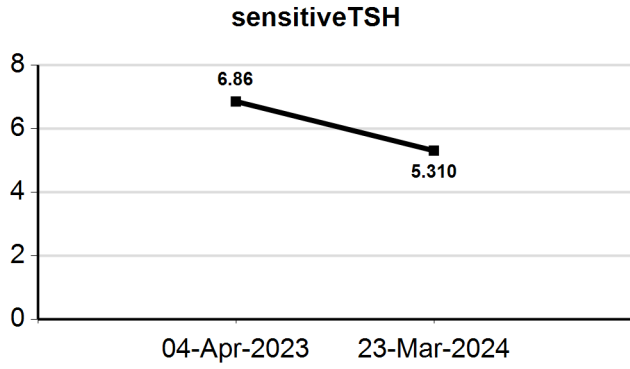
Free T4

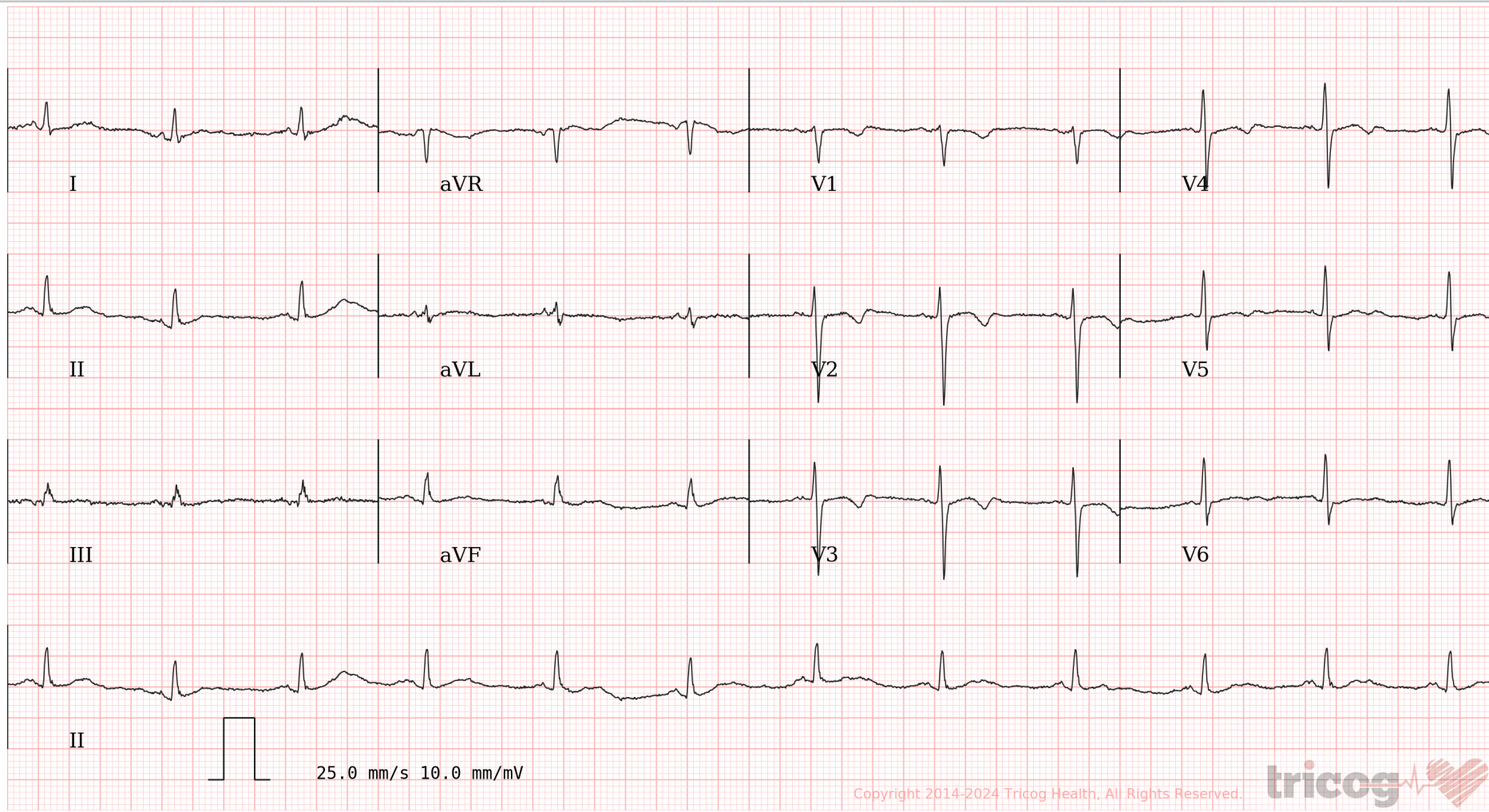




Use a QR Code Scanner
Application To Scan the Code

CID : 2408321575
Name : MS.MITALI ANILKUMAR AGARWAL
Age / Gender : 36 Years / Female
Consulting Dr. : -
Reg. Location : Bhayander East (Main Centre)





Age **36** NA NA
years months days

Gender **Female**

Heart Rate **73bpm**

Patient Vitals

BP: 110/80 mmHg
Weight: 66 kg
Height: 163 cm
Pulse: NA
Spo2: NA
Resp: NA
Others: _____

Measurements

QRSD: 76ms
QT: 426ms
QTcB: 469ms
PR: 114ms
P-R-T: 26° 56° 46°

Sinus Rhythm, Normal axis. T wave inversion in V1-V5. Please correlate clinically.

Disclaimer: 1) Analysis in this report is based on ECG alone and should be used as an adjunct to clinical history, symptoms, and results of other invasive and non-invasive tests and must be interpreted by a qualified physician. 2) Patient vitals are as entered by the clinician and not derived from the ECG.

REPORTED BY
Smita Valani
Dr. Smita Valani
MBBS, D. Cardiology
2011/03/0587



Name : MS.MITALI ANILKUMAR AGARWAL

Age / Gender : 36 Years/Female

Consulting Dr. :

Collected : 23-Mar-2024 / 09:46

Reg.Location : Bhayander East (Main Centre)

Reported : 23-Mar-2024 / 17:50

PHYSICAL EXAMINATION REPORT

History and Complaints:

EXAMINATION FINDINGS:

Height (cms):	163	Weight (kg):	66
Temp (0c):	Afebrile	Skin:	NAD
Blood Pressure (mm/hg):	110/80	Nails:	NAD
Pulse:	86/min	Lymph Node:	Not Palpable

Systems

Cardiovascular: S1S2-Normal
Respiratory: Chest-Clear
Genitourinary: NAD
GI System: NAD
CNS: NAD

IMPRESSION:

*USG with G-I fatty liver.
Right renal cortical cyst,
Post. wall uterine fibroid.*

ADVICE:

↳ Expector consultation.

CHIEF COMPLAINTS:

- 1) Hypertension: No
- 2) IHD: No
- 3) Arrhythmia: No
- 4) Diabetes Mellitus: Yes , 1yr
- 5) Tuberculosis: No
- 6) Asthama: No

Name : MS.MITALI ANILKUMAR AGARWAL

Age / Gender : 36 Years/Female

Consulting Dr. :

Collected : 23-Mar-2024 / 09:46

Reg.Location : Bhayander East (Main Centre)

Reported : 23-Mar-2024 / 17:50

- 7) Pulmonary Disease No
- 8) Thyroid/ Endocrine disorders Yes , 1 yr .
- 9) Nervous disorders No
- 10) GI system No
- 11) Genital urinary disorder No
- 12) Rheumatic joint diseases or symptoms No
- 13) Blood disease or disorder No
- 14) Cancer/lump growth/cyst No
- 15) Congenital disease No
- 16) Surgeries Yes
- 17) Musculoskeletal System No

collective Sp for
shortening of Rt. Limbs
- 18 yrs back.

PERSONAL HISTORY:

- 1) Alcohol No
- 2) Smoking No
- 3) Diet Vegetarian
- 4) Medication Yes

glimepiride - 400mg
gliclazide -
Eltroxin - 75mcg.

*** End Of Report ***

SUBURBAN DIAGNOSTICS (I) PVT. LTD.
Shop No. 101-A, 1st Floor,
Kshitij Building, Above Raymond,
Near Thunga Hospital, Mira-Bhay. Road,
Mira Road (East), Dist. Thane - 401 105
Phone . 022 - 61700000

Anita

DR. ANITA CHOUDHARY
M.B.B.S.
CONSULTANT PHYSICIAN
Reg. No. 2017/12/5553

• PATIENT NAME : MS.MITALI ANILKUMAR AGARWAL	• SEX : FEMALE ✓
• REFERRED BY. : DR-----	• AGE : 36 YEARS
• CID NO : 2408321575	• DATE : 23/03/2024

USG WHOLE ABDOMEN

LIVER:

The liver is normal in size (12.1 cm), normal in shape and shows smooth margins. **It shows raised parenchymal echotexture.** No obvious cystic or solid lesion made out in the parenchyma. The intra hepatic biliary and portal radicals appear normal. The main portal vein appears normal. (PV - 9.0 mm)

GALL BLADDER:

The gall bladder is folded and physiologically distended. Neck region is not well visualised. Gall bladder wall appears normal. No evidence of calculus, mass lesion or sludge seen in the visualised lumen.

COMMON BILE DUCT:

The visualized common bile duct is normal in calibre. Terminal common bile duct is obscured due to bowel gas artefacts.

PANCREAS:

The pancreas appears normal. No evidence of solid or cystic mass lesion made out.

KIDNEYS:

Right kidney measures 10.7 x 3.7 cm. Left kidney measures 9.9 x 4.9 cm. Both the kidneys are normal in size, shape, position and echotexture. Corticomedullary differentiation is well maintained. Pelvicalyceal system is normal. **A 1.6 x 1.2 cm cortical cyst seen in the mid pole of right kidney.** No evidence of any calculus, hydronephrosis or mass lesion seen on both sides.

SPLEEN:

The spleen is normal in size (8.6 cm). Parenchyma appears normal. No evidence of focal lesion is noted.

URINARY BLADDER:

The urinary bladder is well distended and reveals no intraluminal abnormality. Bladder wall appears normal. No obvious calculus or mass lesion made out in the lumen.

There is no evidence of any lymphadenopathy or ascites

UTERUS:

The uterus is anteverted and appears normal. It measures 5.5 x 3.5 cms in size. Myometrium appears normal. The endometrium measures 9.3 mm and appears normal.

An intramural posterior wall uterine fibroid measuring ~ 10.1 x 10.9 mm -FIGO-3

OVARIES:

Right ovary : 2.7 x 1.7 cm.

Left ovary : 2.6 x 1.2 cm.

Both the ovaries are well visualised and appear normal in size, shape, position and echotexture.

There is no evidence of any ovarian or adnexal mass seen.

No free fluid is seen in the pouch of douglas.

IMPRESSION

- **Grade I fatty infiltration of liver.**
- **Right renal cortical cyst.**
- **Posterior wall uterine fibroid.**

Kindly correlate clinically.

Investigations have their limitation. Solitary pathological/Radiological & other investigations never confirm the final diagnosis. They only help in diagnosing the disease in correlation to clinical symptoms & other related tests. Please interpret accordingly.

-----End of Report-----

Aishalakhani

DR AISHA LAKHANI
MBBS, MD (Radio-Diagnosis)
PDCC (Abdominal Radiology)
Reg. No. 2016/ 07/1521
CONSULTANT RADIOLOGIST

Date:- 23/3/24
 Name:- mitali Agarwal
 CID: 240832575
 Sex / Age: 36/F

EYE CHECK UP

Chief complaints:

Systemic Diseases:

Past history:

} NO

Unaided Vision:

RE LE

Aided Vision:

6/6 6/6

Refraction:

1/6 1/6

(Right Eye)

(Left Eye)

	Sph	Cyl	Axis	Vn	Sph	Cyl	Axis	Vn
Distance								
Near								

Colour Vision: Normal / Abnormal

Remark:


SUBURBAN DIAGNOSTICS (I) PVT. LTD.
 Shop No. 101-A, 1st Floor,
 Kshiti Building, Above Raymond,
 Near Thunga Hospital, Mira-Bhy. Road,
 Mira Road (East), Dist. Thane - 401 105
 Phone : 022 - 61700000

भारत सरकार
GOVERNMENT OF INDIA

मिताली अनिलकुमार अग्रवाल
Mitali Anilkumar Agarwal
जन्म वर्ष/YoB: 1987
महिला Female

6071 6607 2402

आधार - सामान्य माणसाचा अधिकार



M. Agarwal

SUBURBAN DIAGNOSTICS (I) PVT. LTD.
Shop No. 102A, 1st Floor,
Kshitya 2000, Near Thane Bypass Road,
Mira Road (East), Dist. Thane - 401 105.
Phone : 022 - 61700000

• PATIENT NAME :MS.MITALI ANILKUMAR AGARWAL	• SEX : FEMALE
• REFERRED BY. : DR. ----	• AGE : 36 YEARS
• CID NO :- 2408321575	• DATE : 23/03/2024

X-RAY CHEST PA VIEW

Positional rotation seen.

Increased bronchovascular markings are seen in the left lower lung zone.

Both lung fields are otherwise clear with no obvious active parenchymal lesions made out.

The cardiothoracic ratio is maintained and the cardiac outline is normal.

The domes of the diaphragm and hila are normal.

The cardio and costophrenic angles are clear.

Bony thorax is normal.

IMPRESSION:

NO SIGNIFICANT ABNORMALITY IS DETECTED.

-----End of Report-----



DR AISHA LAKHANI
MBBS, MD (Radio-Diagnosis)
Fellow in Abdominal Radiology
Reg. No. 2016/ 07/1521
CONSULTANT RADIOLOGIST