

2024-03-23 10:16:54 AM

223 166 05

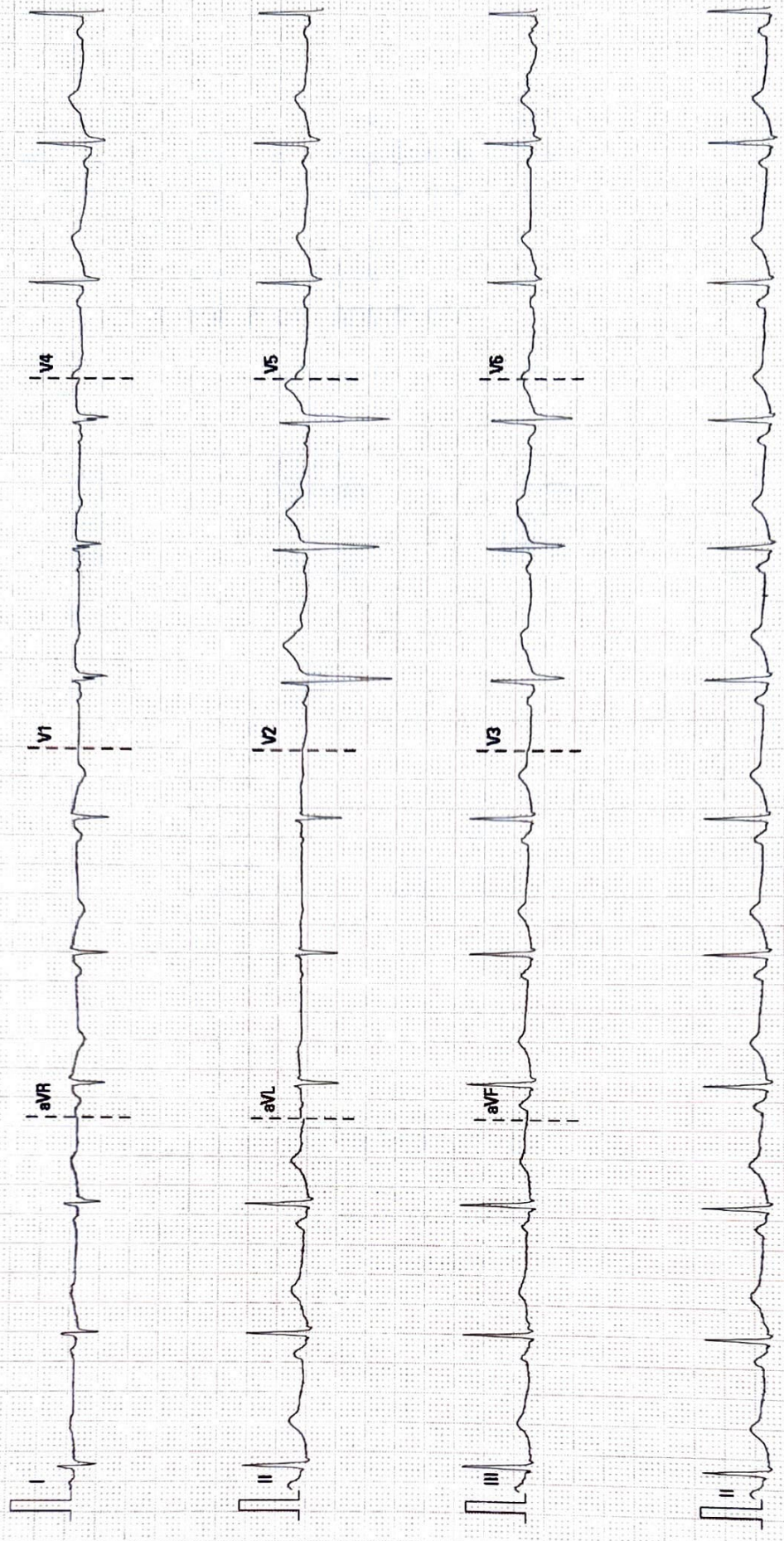
ID: 910062086
Name: MRS EVELYN SNEHA
Age: 34 Years
Gender: Female
Race:

Vent. Rate	67 bpm	Sinus rhythm
PR Interval	144 ms	Rightward axis
QRS Duration	88 ms	Borderline ECG
QT/QTc Interval	414/426 ms	
P/QRS/T Axes	68/95/67 deg	

QTc: Hodges

Unconfirmed Diagnosis

SP
① am
N





PRASHANTH HOSPITALS

Name	: EVELYN SNEHA S	UHID	: 910062086
Sex / Age	: F / 34Y	Accession NO	: 9121184775
Study Date	: 23/3/2024, 10:59:08 am	Report Date	: 23/3/2024, 11:05:14 am
Ref Dr.	: DR. GOPALASWAMY G		

DEPARTMENT OF CARDIOLOGY

INVESTIGATION: ECHO

LV MEASUREMENTS

AO	23 mm	IVS d/s	08/10mm
LA	28 mm	LVPW d/s	07/09mm
LVID (ED)	48 mm	EF	68%
LVID (ES)	30 mm	FS	38%

MORPHOLOGICAL DATA

MITRAL VALVE :

AML	:	NORMAL
PML	:	NORMAL
CHORDAE	:	NORMAL
AORTIC VALVE	:	NORMAL
TRICUSPID VALVE	:	NORMAL
PULMONARY VALVE	:	NORMAL
ATRIA	:	NORMAL
RIGHT VENTRICLE	:	NORMAL FUNCTION (TAPSE : 2.0 cm)
INTER ATRIAL SEPTUM	:	INTACT
INTER VENTRICULAR SEPTUM	:	INTACT
AORTA	:	NORMAL
PULMONARY ARTERY	:	NORMAL
PERICARDIUM	:	NORMAL

DOPPLER DATA :

MITRAL VALVE	:	NORMAL E/A RATIO AT MITRAL INFLOW TRIVIAL MR E : 90 cm/s, A : 51cm/s E/E' : 6.9, S' : 9.9cm/s
AORTIC VALVE	:	NO AR, NO AS, VEL : 115 cm/s
PULMONARY VALVE	:	NO PR, NO PS, VEL : 88 cm/s
TRICUSPID VALVE	:	TRIVIAL TR / NO PAH / TRPG: 18 mmHg

A Unit of PRASHANTH FERTILITY RESEARCH CENTRE PVT. LTD.

No. 36 & 36A, Velachery Main Road, Velachery, Chennai - 600 042. ☎ +91 93 8099 8099

☎ +91 44 4680 5544 / 2243 9494 ✉ info@prashanthhospitals.org 🌐 www.prashanthhospitals.org



PRASHANTH HOSPITALS

Name	: EVELYN SNEHA S	UHID	: 910062086
Sex / Age	: F / 34Y	Accession NO	: 9121184775
Study Date	: 23/3/2024, 10:59:08 am	Report Date	: 23/3/2024, 11:05:14 am
Ref Dr.	: DR. GOPALASWAMY G		

IMPRESSION

- ◆ NO REGIONAL WALL MOTION ABNORMALITY
- ◆ NORMAL LV SYSTOLIC AND DIASTOLIC FUNCTION (LVEF: 68%)
- ◆ NORMAL RIGHT VENTRICLE FUNCTION (TAPSE: 2.0 cm)
- ◆ NO PERICARDIAL EFFUSION
- ◆ NO EVIDENCE OF CLOT OR VEGETATION

DONE BY :KALPANA.M
SR.ECHO TECHNOLOGIST

Dr. Sivakumar
MBBS.MD.,DNB.,FNB
Sr. Consultant Interventional Cardiologist
Reg. No: 68984

A Unit of PRASHANTH FERTILITY RESEARCH CENTRE PVT. LTD.

No. 36 & 36A, Velachery Main Road, Velachery, Chennai - 600 042. ☎ +91 93 8099 8099

☎ +91 44 4680 5544 / 2243 9494 ✉ info@prashanthhospitals.org 🌐 www.prashanthhospitals.org



PRASHANTH HOSPITALS

Patient Name	Mrs. Evelyn Sneha S	Age / Sex	34 Y/F
Patient ID	910062086	Visit No.	1
Ref. By	Dr. Gopalaswamy .G	Visit Date	23.03.2024

USG ABDOMEN AND PELVIS

Real time B-mode Ultrasonography of Upper Abdomen, KUB and Pelvis done

UPPER ABDOMEN:

Liver is normal in size (13.9 cm) and shows uniform echo texture. No abscess or mass lesion in the liver. Intrahepatic biliary radicals not dilated. Portal and Hepatic veins appear normal.

Gall bladder: Fundus, body and neck imaged. Walls and lumen appeared normal. No calculi seen.

Pancreas: Head, body and tail appeared normal. Duct is not dilated.

Spleen appeared normal in size (10.6 cm) and shows homogenous echoes.

Retroperitoneum: Aorta and IVC appears normal. No obvious para aortic lymphadenopathy.

KUB:

RT. Kidney measures 11.8 x 4.6 cm. Cortex appears normal

Cortico medullary differentiation is maintained.

Pelvicalyceal system is not dilated. No calculus is seen.

Right ureter is not dilated.

LT. Kidney measures 11.4 x 4.3 cm. Cortex appears normal

Cortico medullary differentiation is maintained.

Pelvicalyceal system is not dilated. No calculus is seen.

Left ureter is not dilated.

Bladder : is normal in contour. No calculus, mass or diverticulum is seen.

PELVIS :

Uterus measures 8.6 x 3.9 x 5.2 cm. Anteverted.

Shows homogenous myometrial echoes.

E/o two subserosal fibroids measuring 12 x 13 mm in anterior myometrium and 11 x 10 mm in fundus.

Endometrial thickness 10.5 mm, cavity appears normal.

Cervix: Appear normal in size. No focal lesion.

A Unit of PRASHANTH FERTILITY RESEARCH CENTRE PVT. LTD.

No. 36 & 36A, Velachery Main Road, Velachery, Chennai - 600 042. ☎ +91 93 8099 8099

☎ +91 44 4680 5544 / 2243 9494 ☎ info@prashanthhospitals.org ☎ www.prashanthhospitals.org



PRASHANTH HOSPITALS

Patient Name	Mrs. Evelyn Sneha S	Age / Sex	34 Y/F
Patient ID	910062086	Visit No.	1
Ref. By	Dr. Gopalaswamy .G	Visit Date	23.03.2024

Ovaries:

Right ovary measures 5.3 x 4.1 x 4.2 cm, Vol: 48.1 cc. AFC = 0

E/o two cysts with internal echoes and peripheral echogenic foci in right ovary measuring 28 x 27 mm and 18 x 12 mm— Features suggestive of Endometriotic cysts.

E/o a cyst with internal echoes (honey comb pattern) with posterior enhancement in right ovary measured 3.5 x 2.4 cm - S/o Acute Hemorrhagic cyst.

Left ovary measures 3.3 x 1.6 x 2.7 cm, Vol: 7.7 cc. AFC = 2

Left ovary appear normal in size and echotexture

P.O.D: is free. No adnexal mass lesion seen.

No free fluid in peritoneal cavity.

Both iliac fossas appear normal. Appendix is suboptimal. No focal lesion.

Impression:

- Subserosal Uterine fibroids
- Suggestive of Endometriotic cysts in right ovary
- Features of acute hemorrhagic cyst in right ovary
—Suggested review scan on 5th day of next menstrual cycle
- Rest of the visualized organs appears normal

Dr. Kathiresan
Consultant Sonologist

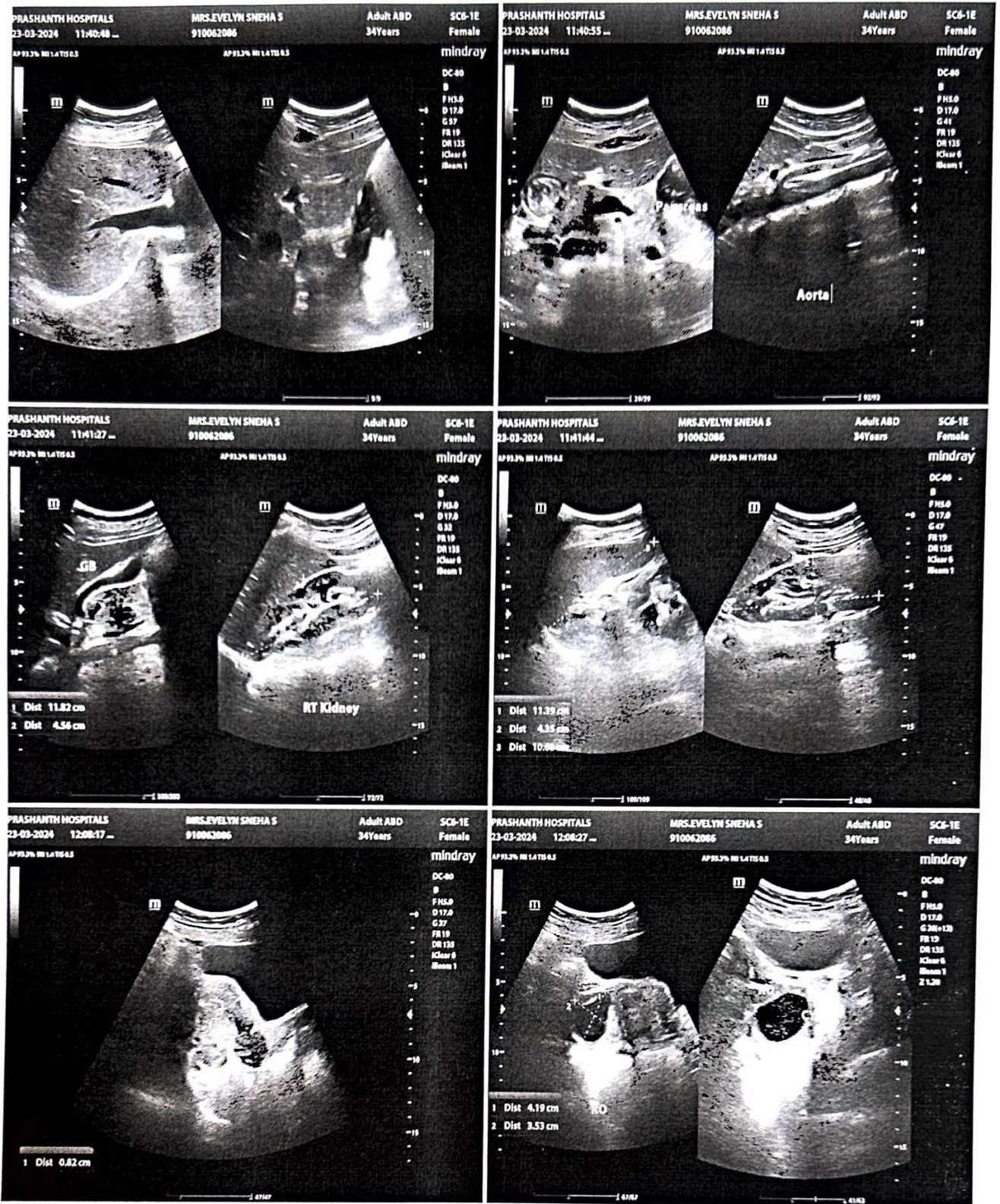
Note: This investigation has its own limitation. Hence sonographic findings should be correlated with clinical features and with further investigations. Not for medico legal purpose.

A Unit of PRASHANTH FERTILITY RESEARCH CENTRE PVT. LTD.

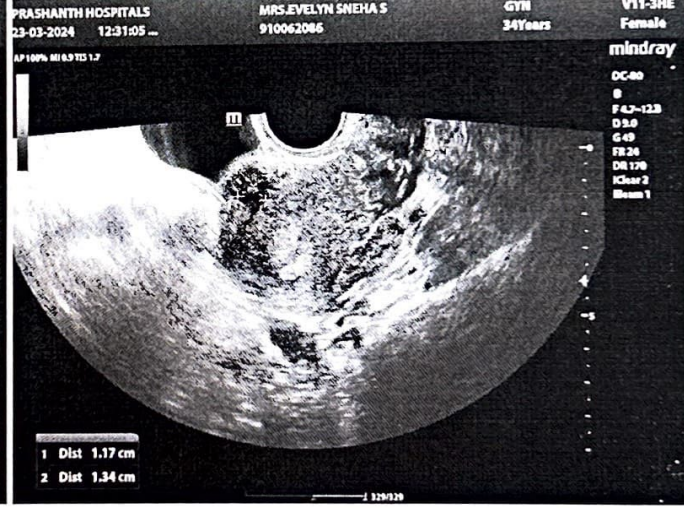
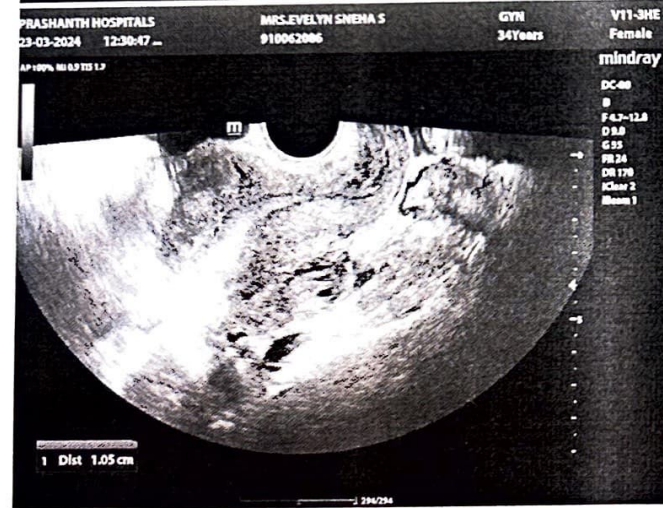
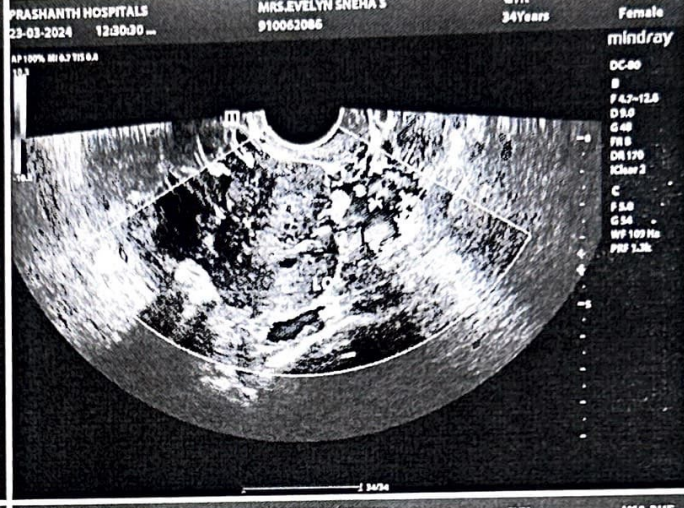
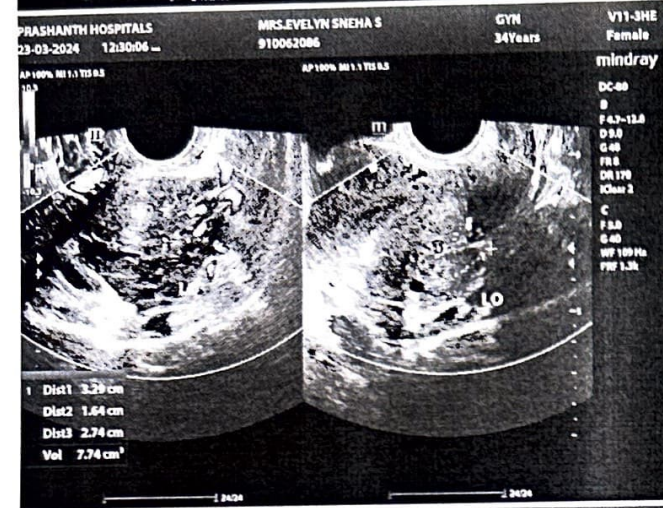
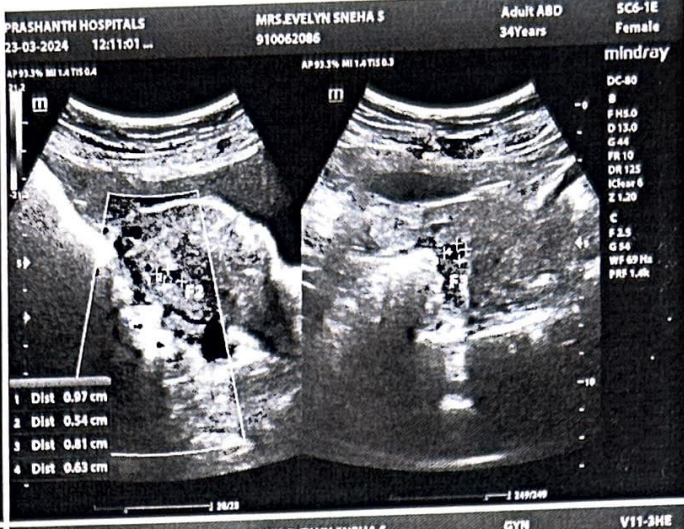
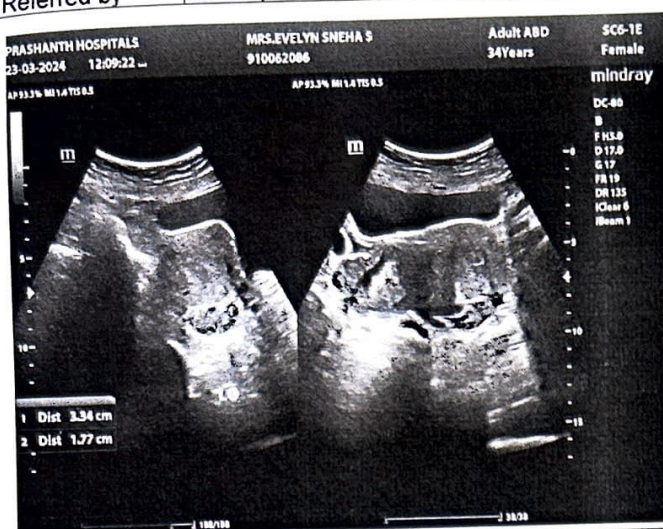
No. 36 & 36A, Velachery Main Road, Velachery, Chennai - 600 042. ☎ +91 93 8099 8099

☎ +91 44 4680 5544 / 2243 9494 ✉ info@prashanthhospitals.org 🌐 www.prashanthhospitals.org

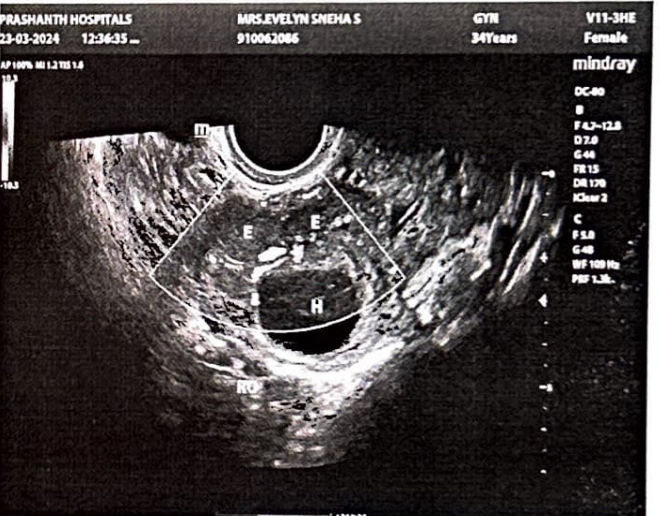
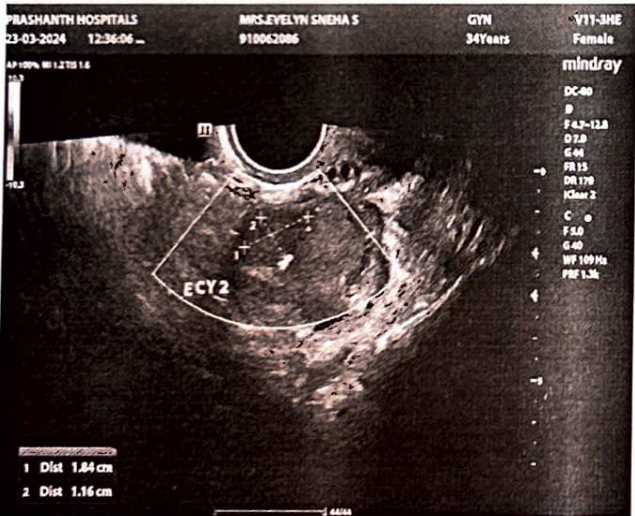
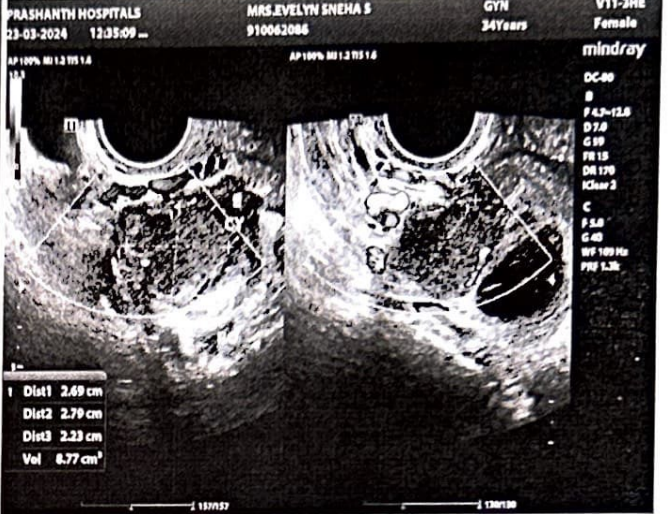
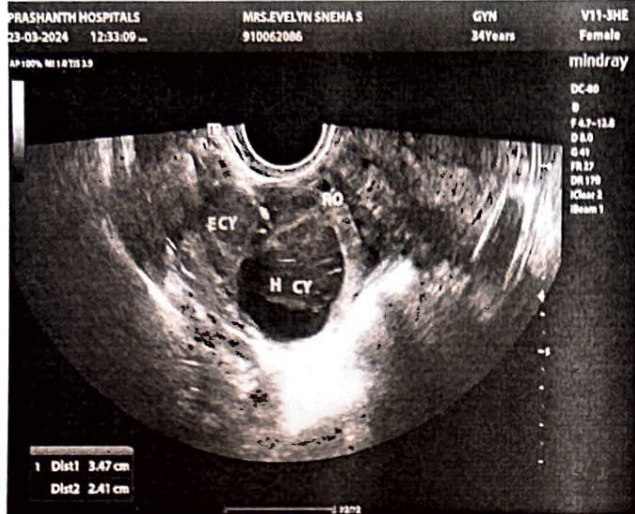
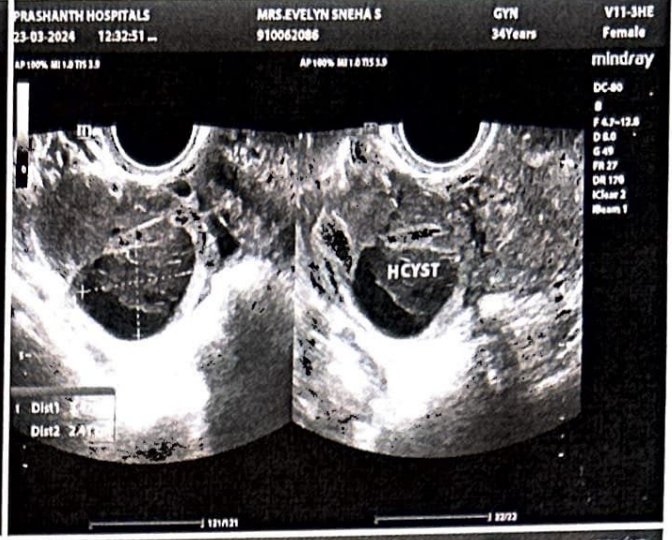
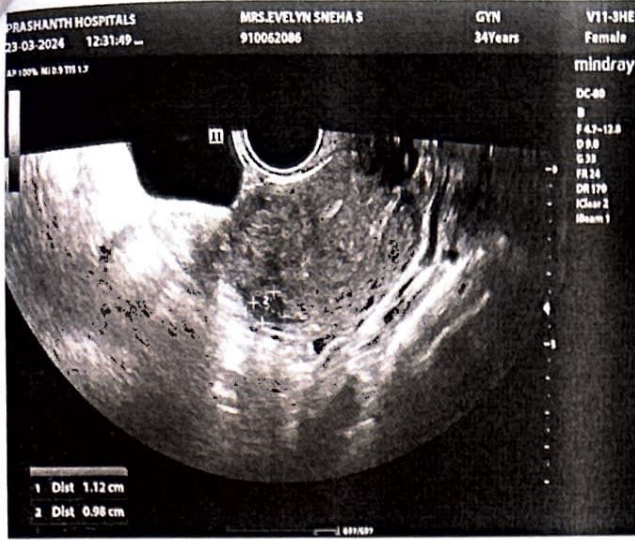
Patient name	Mrs. EVELYN SNEHA S	Age/Sex	34 Years / Female
Patient ID	910062086	Visit no	2
Referred by	Dr. Gopaldaswamy G	Visit date	23/03/2024



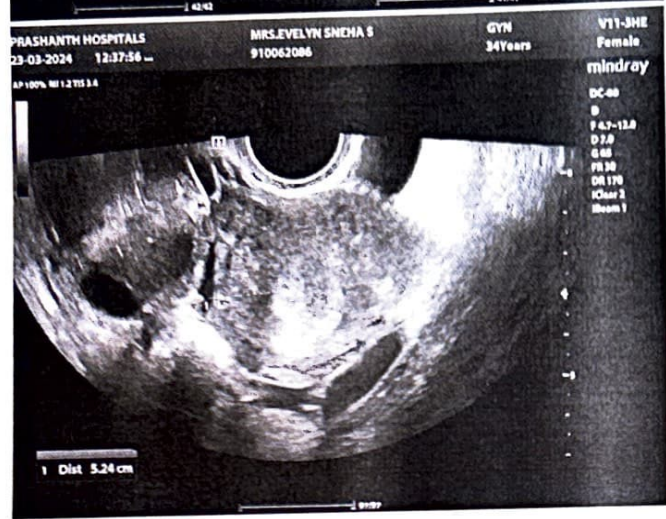
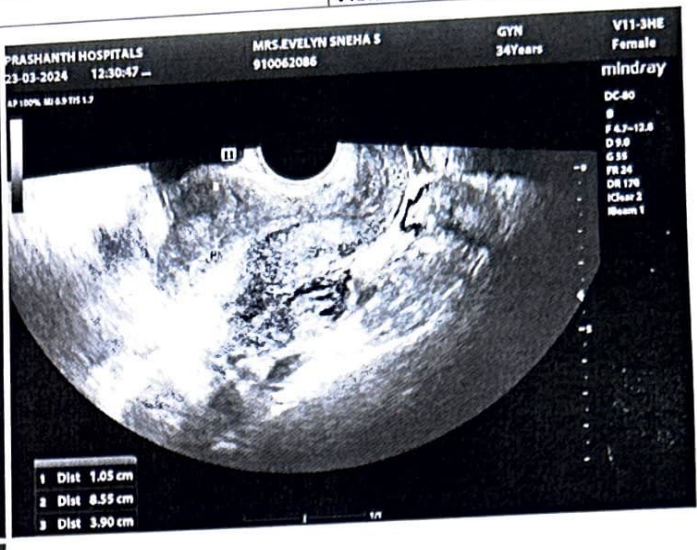
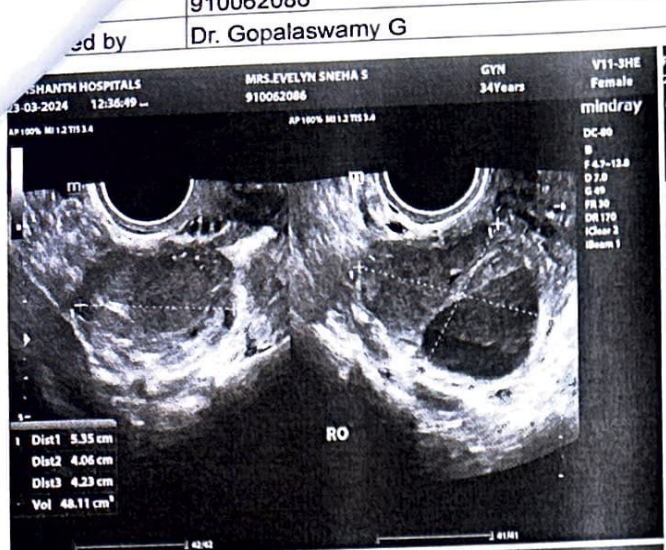
Patient name	Mrs. EVELYN SNEHA S	Age/Sex	34 Years / Female
Patient ID	910062086	Visit no	2
Referred by	Dr. Gopalswamy G	Visit date	23/03/2024



name	Mrs. EVELYN SNEHA S	Age/Sex	34 Years / Female
nt ID	910062086	Visit no	2
ferred by	Dr. Gopalaswamy G	Visit date	23/03/2024



Mrs. EVELYN SNEHA S 910062086 Dr. Gopalaswamy G	Age/Sex	34 Years / Female
	Visit no	2
	Visit date	23/03/2024





PRASHANTH HOSPITALS

EYE CHECK-UP REPORT

NAME : Mrs. Evelyn Sneha

DATE : 23/03/24

AGE / SEX : 34/F

UHID NUM : 910062086

Chief complaints : Regular eye check up

Past history : —

Systemic Diseases : —

DISTANCE VISION :

WITH OUT GLASS : 6/60, N6 6/60, N6

WITH GLASS : 6/6, N6 6/6, N6

COLOR VISION : NORMAL / ABNORMAL

GLASS PRESCRIPTION :

EYE	SPH	CYL	AXIS	V/A	SPH	CYL	AXIS	V/A
DISTANCE	—	—	—	—	—	—	—	—
	3.00	0.75	40°	6/6	3.50	0.75	150°	6/6
ADD	—	—	—	N6	—	—	—	N6

ANTERIOR SEGMENT :

CORNEA & LENS :

BE WNT

REMARK : CONTINUE WITH SAME GLASSE ✓

ROUTINE CHECK UP AFTER 6/12 MONTH ✓

FUNDUSCOPY ONCE A YEAR

→ Refresh Tears Eye drops 1-1-1 x BEX
3 months.


OPTOMETRIST

A Unit of PRASHANTH FERTILITY RESEARCH CENTRE PVT. LTD.

No. 36 & 36A, Velachery Main Road, Velachery, Chennai - 600 042. ☎ +91 93 8099 8099

☎ +91 44 4680 5544 / 2243 9494 ✉ info@prashanthhospitals.org 🌐 www.prashanthhospitals.org