

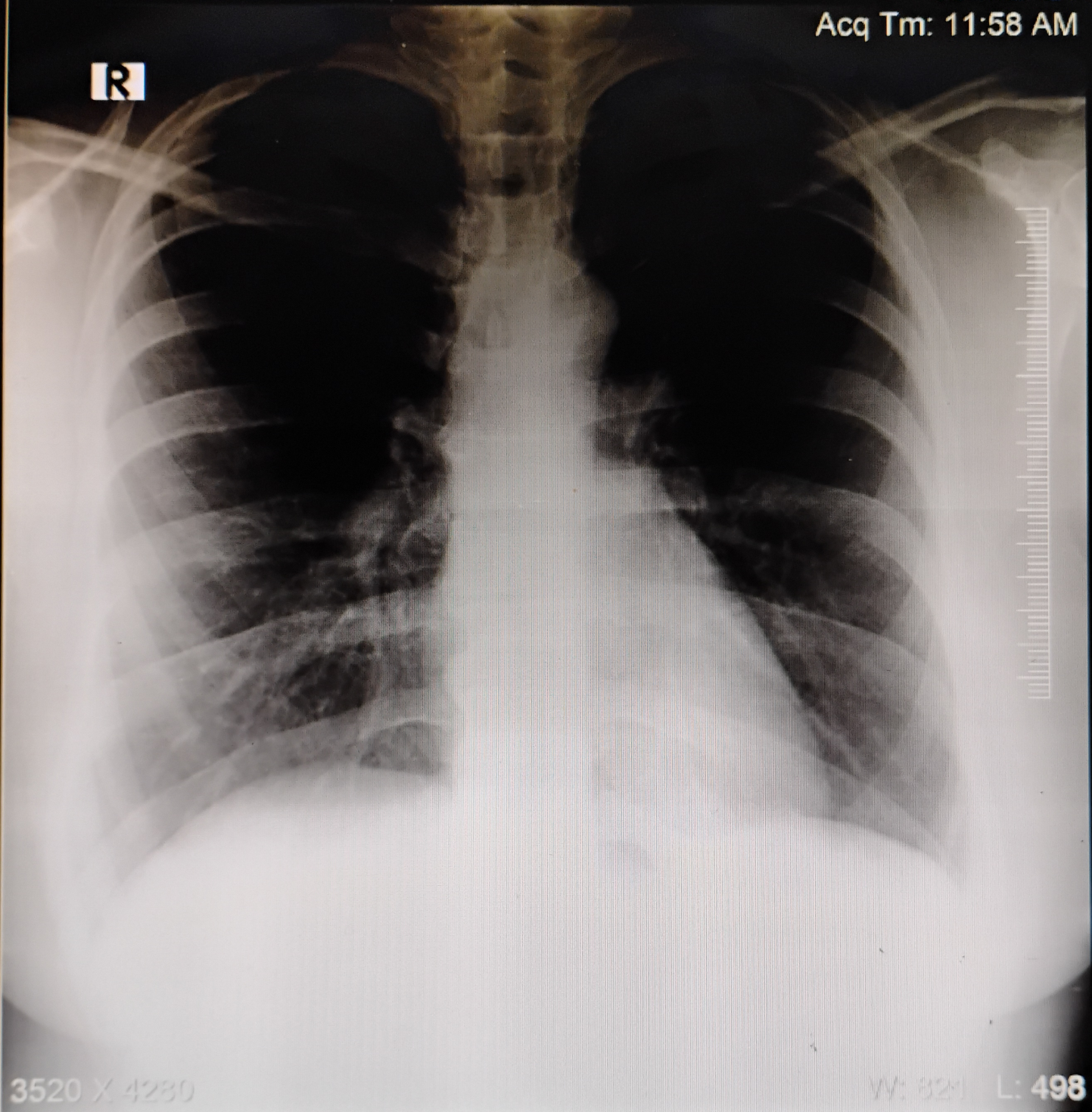
ru0 DDRC AGILUS DIAGNOSTIC (P) LTD, KADAPPAKADA, KOLLAM
CHEST-PA JYOTHI GEORGE 35 YRS

4071/2052

09-Mar-24

Acq Tm: 11:58 AM

R

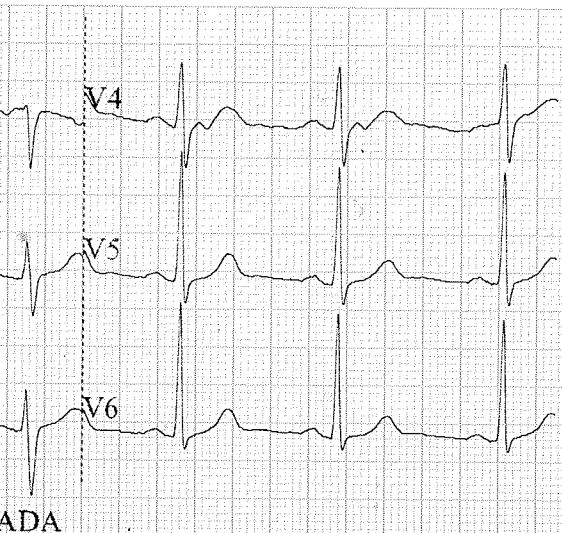


3520 X 4280

W: 829 L: 498

JYOTHI GEORGE 35 YRS 4071/2052 F CHEST-PA 09-Mar-24 11:55 AM

DDRC AGILUS DIAGNOSTIC (P) LTD, KADAPPAKADA, KOLLAM



ID: 9322

Diagnosis Information:

Female
35 Years
cm


mmHg

kg

Syothi George

35/F

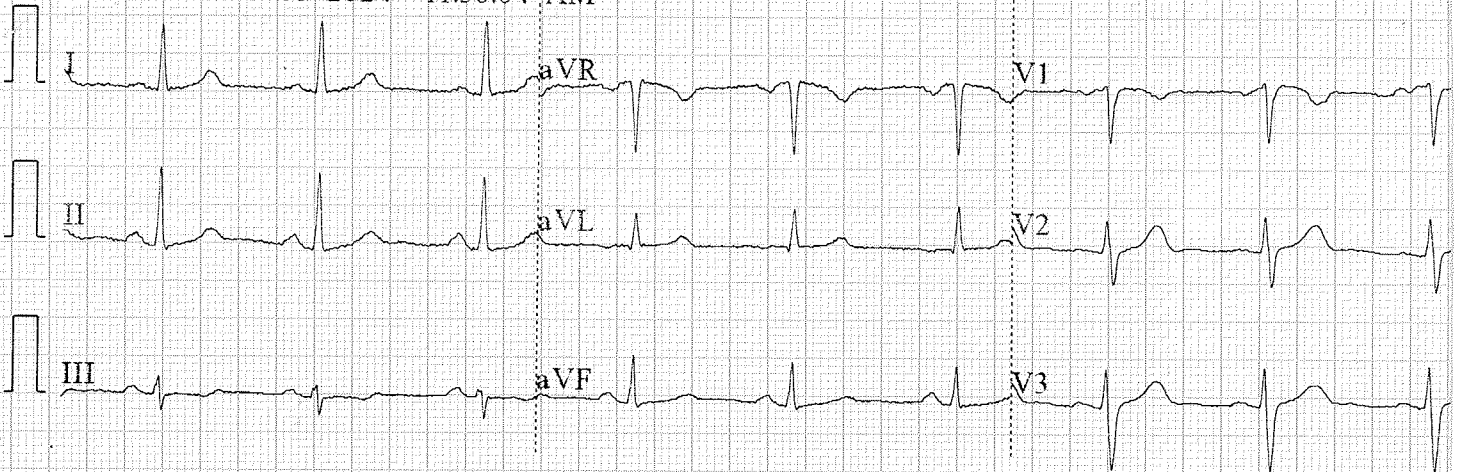
HR : 74 bpm
P : 122 ms
PR : 158 ms
QRS : 79 ms
QT/QTc : 387/431 ms
P:QRS/T : 66/31/37 °
RV5/SV1 : 1.612/0.712 mV



Report Confirmed by:

ARROW CE

ID: 9322 09-03-2024 11:56:04 AM



0.67~35Hz AC50 25mm/s 10mm/mV ♥72 V1.0 SEMIP V1.7 DDRC_AGILUS_KADAPPAKKAD

If the examinee is suffering from an acute life threatening situation, you may be obliged to disclose the result of the medical examination to the examinee.

1. Name of the examinee	: Mr./Mrs./Ms. JYOTHI GEORGE
2. Mark of Identification	: (Mole/Scar/any other (specify location)): Mole on right palm
3. Age/Date of Birth	: 30-05-1988 Gender: F/M
4. Photo ID Checked	: (Passport/Election Card/PAN Card/Driving Licence/Company ID)

PHYSICAL DETAILS:

a. Height 162 (cms)	b. Weight 76 (Kgs)	c. Girth of Abdomen 98 (cms)
d. Pulse Rate 88 (/Min)	e. Blood Pressure: 110/70	Systolic Diastolic
	1 st Reading 110	70
	2 nd Reading	

FAMILY HISTORY:

Relation	Age if Living	Health Status	If deceased, age at the time and cause
Father	75	Good	
Mother	65	Good	
Brother(s)			
Sister(s)	37	Good	

HABITS & ADDICTIONS: Does the examinee consume any of the following?

Tobacco in any form	Sedative	Alcohol
N	N	N

PERSONAL HISTORY

- | | |
|---|---|
| a. Are you presently in good health and entirely free from any mental or Physical impairment or deformity. If No, please attach details. Y/N | c. During the last 5 years have you been medically examined, received any advice or treatment or admitted to any hospital? Y/N |
| b. Have you undergone/been advised any surgical procedure? Y/N | d. Have you lost or gained weight in past 12 months? Y/N |

Have you ever suffered from any of the following?

- | | |
|--|---|
| • Psychological Disorders or any kind of disorders of the Nervous System? Y/N | • Any disorder of Gastrointestinal System? Y/N |
| • Any disorders of Respiratory system? Y/N | • Unexplained recurrent or persistent fever, and/or weight loss Y/N |
| • Any Cardiac or Circulatory Disorders? Y/N | • Have you been tested for HIV/HBsAg / HCV before? If yes attach reports Y/N |
| • Enlarged glands or any form of Cancer/Tumour? Y/N | • Are you presently taking medication of any kind? Y/N |
| • Any Musculoskeletal disorder? Y/N | |

DDRC agilus Pathlabs Limited

Corp. Office : Express House, Second Floor, Opp. Pothys Silks, Banerjee Road, Kaloor -682017

Contact :- 93334 93334, Web :- www.ddrcagilus.com Email :- info.ddrc@agilus.in

• Any disorders of Urinary System?

Y/N

• Any disorder of the Eyes, Ears, Mouth & Skin

FOR FEMALE CANDIDATES ONLY

a. Is there any history of diseases of breast/genital organs?

Y/N

d. Do you have any history of miscarriage/abortion or MTP

b. Is there any history of abnormal PAP Smear/Mammogram/USG of Pelvis or any other tests? (If yes attach reports)

Y/N

e. For Parous Women, were there any complications during pregnancy such as gestational diabetes, hypertension etc

Y

c. Do you suspect any disease of Uterus, Cervix or Ovaries?

Y/N

f. Are you now pregnant? If yes, how many months?

No

Y/N

CONFIDENTIAL COMMENTS FROM MEDICAL EXAMINER

➤ Was the examinee co-operative?

Y/N

➤ Is there anything about the examinee's health, lifestyle that might affect him/her in the near future with regard to his/her job?

Y/N

➤ Are there any points on which you suggest further information be obtained?

Y/N

➤ Based on your clinical impression, please provide your suggestions and recommendations below:

.....
.....

➤ Do you think he/she is **MEDICALLY FIT** or **UNFIT** for employment.

MEDICAL EXAMINER'S DECLARATION

I hereby confirm that I have examined the above individual after verification of his/her identity and the findings stated above are true and correct to the best of my knowledge.

Name & Signature of the Medical Examiner :


Dr. Akhila Sekhar *Akhila*

Seal of Medical Examiner :

Dr. Akhila Sekhar MBBS.MD
Consultant Pathologist
Reg.No. 55174

Name & Seal of DDRC SRL Branch :

Date & Time



DDRC agilus Pathlabs Limited.

Corp. Office : Express House, Second Floor, Opp. Pothys Silks, Banerjee Road, Kaloor -682017

Contact :- 93334 93334, Web :- www.ddrcagilus.com Email :- info.ddrc@agilus.in

Name : Mrs. Jyothi George	Age : 35 yrs	Sex: F	RADIOLOGY DIVISION Date : 09.03.2024
Ref. from. Mediwheel Arcofemi			

USG OF ABDOMEN (TAS & TVS)

(Technical consideration : Poor sonological window)

LIVER: Is normal in size (15.0 cms) and echotexture. No focal lesions are seen. No dilatation of intra-hepatic biliary radicles present. Portal vein is normal. Common bile duct is normal.

GALL BLADDER: Is distended. Normal in wall thickness. No calculus or mass.

PANCREAS: Visualized head and body appears normal. Rest obscured by bowel gas

SPLEEN: Is normal in size (8.4 cms) and echotexture.

RIGHT KIDNEY: Measures 9.8 x 3.9 cms. Normal in size and echotexture. Cortico medullary differentiation is well maintained. No calculus, hydronephrosis or mass.

LEFT KIDNEY: Measures 10.4 x 5.0 cms. Normal in size and echotexture. Cortico medullary differentiation is well maintained. No calculus, hydronephrosis or mass.

URINARY BLADDER: Is distended. Normal wall thickness. No obvious calculus or mass. No vesical diverticulum present.

UTERUS: Measures 9.8 x 4.7 x 5.1 cms. Normal in size. Myometrial echoes normal. No focal lesions noted. Endometrial thickness measures 9.6 mm.

Right ovary measures - 37.6 x 18.8 x 35.1 mm , volume- 13 cc

Left ovary measures - 36.2 x 15.6 x 34.1 mm , volume- 10.1 cc

Both ovaries are slightly bulky in size and shows mild increase in stromal echoes with multiple small follicles of size 3-5mm. No dominant follicle noted in either side.


No adnexal mass lesion seen. No free fluid in POD.

Both iliac fossae appear normal and there is no obvious evidence of bowel mass or bowel wall thickening present.

IMPRESSION:

❖ **Polycystic appearance in both ovaries.**

- Suggested follow up & clinical correlation
- Images overleaf.



Dr. AISALUTH THULASEEDHARAN
MBBS, DMRD

(Note: Diagnosis should not be made solely on one investigation. Advised further / repeat investigation and clinical correlation in suspected cases and in case of unexpected results, ultrasound is not 100% accurate and this report is not valid for medico legal purpose)

DDRC agilus Pathlabs Limited.

Corp. Office : Express House, Second Floor, Opp. Pothys Silks, Banerjee Road, Kaloore -682017
Contact :- 93334 93334, Web :- www.ddrcagilus.com Email :- info.ddrc@agilus.in

Mrs. Jyothi George, 25 yrs old female
with Best corrected visual acuity
 $6/6$, N_6 in both eyes. Anterior
segment examination fo and
undilated fundus examination
found to be normal.

Thanking You

Yours faithfully



9/3/24

Dr. HARIPRIYA.H
MBBS, MS - OPHTHALMOLOGY
TCMC Reg. No: 44880
Chaithanya Eye Hospital & Research Institute
Prathibha Junction, Kadappakkada, Kollam - 691005

NAME	AGE/ SEX	DATE
JYOTHI GEORGE	35/F	09.03.2024

X-RAY- CHEST WITH REPORT

CHEST X RAY : NORMAL

Impression : Within radiological limits

Dr. Akhila Sekhar MBBS.MD
Consultant Pathologist
Reg.No. 55174


DR AKHILA SEKHAR

MBBS, MD

CONSULTANT PATHOLOGIST

NAME : JYOTHI GEORGE	AGE/ SEX : 35/F	09.03.2024
----------------------	-----------------	------------

ELECTRO CARDIOGRAM REPORT

ELECTRO CARDIOGRAM

: NSR - 74./minute. No evidence of ischaemia or chamber hypertrophy.

Impression

: ECG with in normal limits.

Dr. Akhila Sekhar MBBS, MD
Consultant Pathologist
Reg.No. 55174



DR AKHILA SEKHAR

MBBS, MD

CONSULTANT PATHOLOGIST

From

Jyothi George
Kadathanathu
Venmony

To

Mediwheel

Sir,

I am not willing to test stool examinations


JG

Name : Mrs. Jyothi George	Age : 35 yrs	Sex: F	RADIOLOGY DIVISION Date : 09.03.2024
Ref. from. Mediwheel Arcofemi			

USG OF ABDOMEN (TAS & TVS)

(Technical consideration : Poor sonological window)

LIVER: Is normal in size (15.0 cms) and echotexture. No focal lesions are seen. No dilatation of intra-hepatic biliary radicles present. Portal vein is normal. Common bile duct is normal.

GALL BLADDER: Is distended. Normal in wall thickness. No calculus or mass.

PANCREAS: Visualized head and body appears normal. Rest obscured by bowel gas

SPLEEN: Is normal in size (8.4 cms) and echotexture.

RIGHT KIDNEY: Measures 9.8 x 3.9 cms. Normal in size and echotexture. Cortico medullary differentiation is well maintained. No calculus, hydronephrosis or mass.

LEFT KIDNEY: Measures 10.4 x 5.0 cms. Normal in size and echotexture. Cortico medullary differentiation is well maintained. No calculus, hydronephrosis or mass.

URINARY BLADDER: Is distended. Normal wall thickness. No obvious calculus or mass. No vesical diverticulum present.

UTERUS: Measures 9.8 x 4.7 x 5.1 cms. Normal in size. Myometrial echoes normal. No focal lesions noted. Endometrial thickness measures 9.6 mm.

Right ovary measures - 37.6 x 18.8 x 35.1 mm , volume- 13 cc

Left ovary measures - 36.2 x 15.6 x 34.1 mm , volume- 10.1 cc

Both ovaries are slightly bulky in size and shows mild increase in stromal echoes with multiple small follicles of size 3-5mm. No dominant follicle noted in either side.


No adnexal mass lesion seen. No free fluid in POD.

Both iliac fossae appear normal and there is no obvious evidence of bowel mass or bowel wall thickening present.

IMPRESSION:

❖ **Polycystic appearance in both ovaries.**

- Suggested follow up & clinical correlation
- Images overleaf.



Dr. AISALUTH THULASEEDHARAN
MBBS, DMRD

(Note: Diagnosis should not be made solely on one investigation. Advised further / repeat investigation and clinical correlation in suspected cases and in case of unexpected results, ultrasound is not 100% accurate and this report is not valid for medico legal purpose)

DDRC agilus Pathlabs Limited.

Corp. Office : Express House, Second Floor, Opp. Pothys Silks, Banerjee Road, Kaloor -682017
Contact :- 93334 93334, Web :- www.ddrcagilus.com Email :- info.ddrc@agilus.in



CHAITHANYA EYE
HOSPITAL & RESEARCH INSTITUTE



Mrs. Jyothi George, 25 yrs old female
with Best corrected visual acuity
 $6/6$, N_6 in both eyes. Anterior
segment examination fo and
undilated fundus examination
found to be normal.

Thanking You

Yours faithfully

Haripriya

9/3/24

Dr. HARIPRIYA.H
MBBS, MS - OPHTHALMOLOGY
TCMC Reg. No: 44880
Chaithanya Eye Hospital & Research Institute
Prathibha Junction, Kadappakkada, Kollam - 691005



+91 47427 35500
+91 90727 72221



info.klm@chaithanya.org
www.chaithanya.org



Chaithanya Eye Hospital and Research Institute
Prathibha Junction, Kadappakkada, Kollam 691 005

NAME	AGE/ SEX	DATE
JYOTHI GEORGE	35/F	09.03.2024

X-RAY- CHEST WITH REPORT

CHEST X RAY : NORMAL

Impression : Within radiological limits

Dr. Akhila Sekhar MBBS.MD
Consultant Pathologist
Reg.No. 55174


DR AKHILA SEKHAR**MBBS, MD****CONSULTANT PATHOLOGIST**

NAME : JYOTHI GEORGE	AGE/ SEX : 35/F	09.03.2024
----------------------	-----------------	------------

ELECTRO CARDIOGRAM REPORT

ELECTRO CARDIOGRAM

: NSR - 74./minute. No evidence of ischaemia or chamber hypertrophy.

Impression

: ECG with in normal limits.

Dr. Akhila Sekhar MBBS, MD
Consultant Pathologist
Reg.No. 55174


DR AKHILA SEKHAR

MBBS, MD

CONSULTANT PATHOLOGIST

From

Jyothi George
Kaduthanathu
Venmony

To

Mediwheel

Sir,

I am not willing to test stool examinations


JG

Name : Mrs. Jyothi George	Age : 35 yrs	Sex: F	RADIOLOGY DIVISION
Ref. from. Mediwheel Arcofemi			Date : 09.03.2024

USG OF ABDOMEN (TAS & TVS)

(Technical consideration : Poor sonological window)

LIVER: Is normal in size (15.0 cms) and echotexture. No focal lesions are seen. No dilatation of intra-hepatic biliary radicles present. Portal vein is normal. Common bile duct is normal.

GALL BLADDER: Is distended. Normal in wall thickness. No calculus or mass.

PANCREAS: Visualized head and body appears normal. Rest obscured by bowel gas

SPLEEN: Is normal in size (8.4 cms) and echotexture.

RIGHT KIDNEY: Measures 9.8 x 3.9 cms. Normal in size and echotexture. Cortico medullary differentiation is well maintained. No calculus, hydronephrosis or mass.

LEFT KIDNEY: Measures 10.4 x 5.0 cms. Normal in size and echotexture. Cortico medullary differentiation is well maintained. No calculus, hydronephrosis or mass.

URINARY BLADDER: Is distended. Normal wall thickness. No obvious calculus or mass. No vesical diverticulum present.

UTERUS: Measures 9.8 x 4.7 x 5.1 cms. Normal in size. Myometrial echoes normal. No focal lesions noted. Endometrial thickness measures 9.6 mm.

Right ovary measures - 37.6 x 18.8 x 35.1 mm , volume- 13 cc

Left ovary measures - 36.2 x 15.6 x 34.1 mm , volume- 10.1 cc

Both ovaries are slightly bulky in size and shows mild increase in stromal echoes with multiple small follicles of size 3-5mm. No dominant follicle noted in either side.


No adnexal mass lesion seen. No free fluid in POD.

Both iliac fossae appear normal and there is no obvious evidence of bowel mass or bowel wall thickening present.

IMPRESSION:

❖ *Polycystic appearance in both ovaries.*

- Suggested follow up & clinical correlation
- Images overleaf.



Dr. AISALUTH THULASEEDHARAN
MBBS, DMRD

(Note: Diagnosis should not be made solely on one investigation. Advised further / repeat investigation and clinical correlation in suspected cases and in case of unexpected results, ultrasound is not 100% accurate and this report is not valid for medico legal purpose)

DDRC agilus Pathlabs Limited.

Corp. Office : Express House, Second Floor, Opp. Pothys Silks, Banerjee Road, Kaloore -682017
Contact :- 93334 93334, Web :- www.ddrcagilus.com Email :- info.ddrc@agilus.in

Gynecology Report

Patient ID : 09_03_2024_14_04_00

Sex : F

Age :

Patient Name : jyothi

Study Date : 09/03/2024

Referring MD :

Performing MD :

Sonographer :

Indication :

Exam Type : GYN

Height :

Weight :

Gravida :

Para :

AB :

Ectopic :

LMP :

2D Mode Measurements

Rt Ovary

Length : 37.6 mm

Width : 35.1 mm

Depth : 18.8 mm

Volume : 13.0 cc

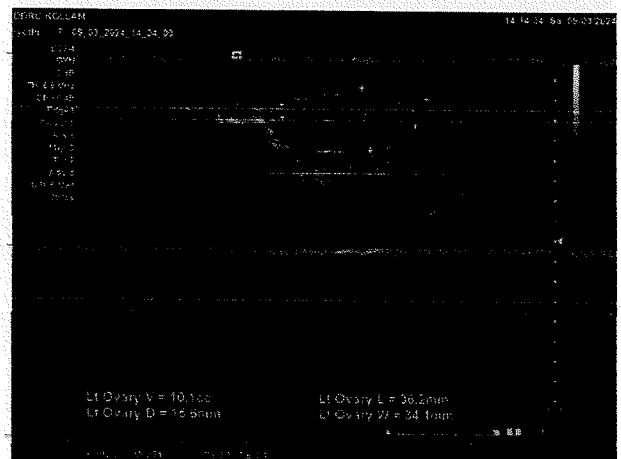
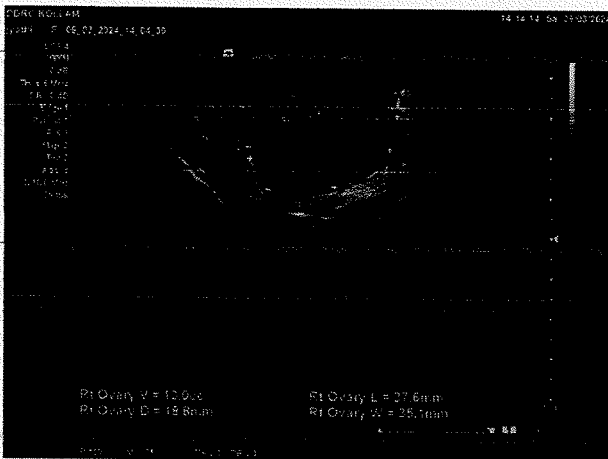
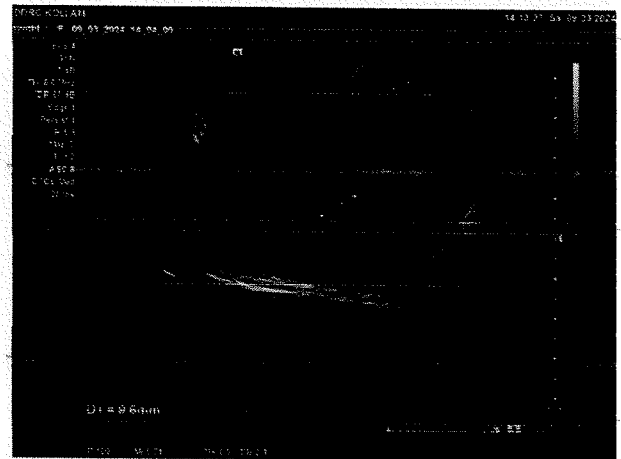
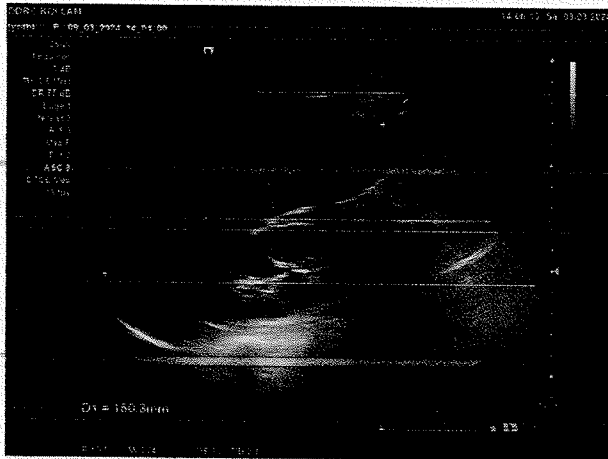
Lt Ovary

Length : 36.2 mm

Width : 34.1 mm

Depth : 15.6 mm

Volume : 10.1 cc



Signature _____