

DAKSH HOSPITAL

396 - 397, Gandhi Nagar, Scheme No. 8, ALWAR -301001

Ref. No.

Date.....

MEDICAL EXAMINATION REPORT

Mediwheel (BOB)

Name: Mr. Mehendra Prasad Sharma Age: 33yrs Sex: Male Date: 23-03-2024

General Physical Examination

Height : 169 cm
Pulse : 86 mt
Respiration : 18/mt

Weight : 76 kg
BP : 120/80 mm/hg
BMI : 26.6 kg/m²

Systemic Exam:-

NORMAL

Dental Check up:-

NORMAL

Eye check-up:-

NORMAL

Skin Check up:-

NORMAL

ENT Check up:-

NORMAL

Impression:-

↑ OHP, Mild
TBM 5.9
Fully Lived

Recommendation:-

Reduced Feat/Carbonyl/urate
exclus/walk

Dr. Mukesh Kumar Gupta
MD Gen. Medicine
Reg. No 5423/16262

डॉ० मुकेश गुप्ता
M.D.F.C.C.S.
फिजिशियन एवं मधुमेह रोग विशेषज्ञ
दक्ष हॉस्पिटल, अलवर
रजि० नं०-5423/16262

Results

Run Date 23/03/2024 09:34:37 AM

Operator DAKSH

Last Name

Sample ID 9

First Name MR. MAHENDRA

Department

Gender Male

Age

Physician DR. MUKESH GUPTA M.D

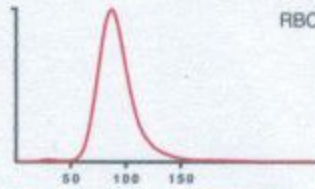
Patient ID AUTO_PID20438

Type Man

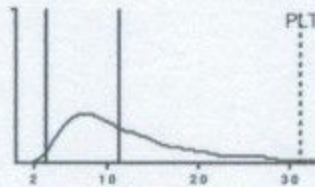
Date of birth

Sample comments

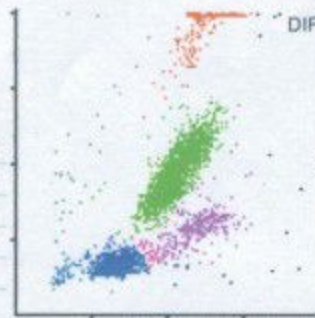
			Range
RBC	4.81	10 ⁶ /μL	3.80 - 5.50
HGB	14.5	g/dL	13.0 - 17.0
HCT	44.3	%	39.0 - 52.0
MCV	92.0	μm ³	76.0 - 100.0
MCH	30.1	pg	26.0 - 34.0
MCHC	32.7	g/dL	32.0 - 35.0
RDW-CV	16.1	%	11.0 - 16.0
RDW-SD	58.3	μm ³	37.0 - 49.0



			Range
PLT	218	10 ³ /μL	150 - 450
PCT	0.25	%	0.15 - 0.40
MPV	11.4	μm ³	8.0 - 11.0
PDW	20.4	μm ³	11.0 - 22.0
P-LCC	92	10 ³ /μL	44 - 140
P-LCR	42.2	%	18.0 - 50.0



			Range		Range
WBC	6.99	10 ³ /μL	3.50 - 10.00		
	#			%	
NEU	3.27		1.60 - 7.00	47.0	40.0 - 75.0
LYM	3.12	h	1.00 - 3.00	44.8	20.0 - 45.0
MON	0.16	l	0.20 - 0.80	2.3	2.0 - 10.0
EOS	0.34		0.00 - 0.50	4.9	1.0 - 6.0
BAS	0.07		0.00 - 0.15	1.0	0.0 - 1.0
LIC	0.03		0.00 - 0.10	0.4	0.0 - 1.0



Dr. R.S. Gupta

Dr. R.S. GUPTA
MD (Pathology) (MAHE)
RMC No. 7924/19778


Date :-23/03/2024

Name :- MR. MAHENDRA

Age & Sex :- Yrs/ male

Refd. :- Dr Mukesh Gupta M.D.

	TEST NAME	RESULT	REFERENCE RANGE	
	ESR	15	00 -20 mm/hrs	
	Blood Group & Rh Factor	A* POSITIVE		
	HbA1C	4.81	4 - 5.6%	
	Blood Sugar (F)	86.1	< 70 - 100 mg/dl	
	Blood Sugar (PP)	-	< 140 mg/dl	
	Urine Sugar (F)	-	-	
	Urine Sugar (PP)	-	-	
LIVER	S.Bilirubin Total	1.0	0.30 - 1.20 mg/dl	
	S.Bilirubin Direct	0.3	0.10 - 0.30 mg/dl	
	S.Bilirubin Indirect	0.7	0.30 - 0.90 mg/dl	
	S.G.O.T.	43	> 37 u/l	
	S.G.P.T.	52	> 40 u/l	
	S.Alk. Phosp.	180	80 - 306 u/l	
	G.G.T.	22.1	5 - 40 u/l	
	Total Protein	6.5	6.5 - 8.5 gm/dl	
	Albumin	3.5	3.8 - 5.4 gm/dl	
	Globulin	3.0	2.3 - 3.5 gm/dl	
	A/G Ratio	1.2	-	
	AST/ALT Ratio	0.82	-	
	KIDNEY	Blood Urea	30.1	15 -45 mg/dl
S.Creatinine		1.1	0.60 - 1.30 mg/dl	
BUN		23.1	6 -24 mg/dl	
S.Uric Acid		5.4	M 3.1 - 7.0, F 2.5 - 5.6 mg/dl	
BUN/Creatinine Ratio		23.1	-	
LIPID PROFILE	Total Cholesterol	165.1	Up to 200 mg/dl	
	S.HDL	44.1	30 - 70 mg/dl	
	S.LDL	91.1	Up to 170 mg/dl	
	S.VLDL	30.1	5.0 - 40 mg/dl	
	S. Triglycerides	150.1	Up to 170 mg/dl	
	LDL/HDL Ratio	2.0	-	
	Total Cholesterol/ HDL Ratio	3.6	-	
THYROID	T3	108.1	40 - 181 ng/dl	
	T4	8.1	4.6 - 10.5 µg/dl	
	TSH	5.9	0.30 - 5.0 mlu/l	
	URINE EXAMINATION		<i>Microscopic Examination:</i>	
General/Chemical Examination:	Colour	Pale Yellow	RBC	Absent
	Reaction	Acidic	WBC	0 - 1
	Specific Gravity	QNS	Epithelial Cells	Absent
	Appearance	Clear	Cast	Absent
	Albumin	Nil	Spermatozoa	Absent
	Sugar	Nil	Amorphous Sediments	Absent
			Other	Absent
X-RAY CHEST	NORMAL STUDY			
	STOOL EXAMINATION		<i>Microscopic Examination:</i>	
General/Chemical Examination:	Colour	BRONISH	RBC	NIL
	Consistency	SOLID	WBC	NIL
			Ova & Parasites	NIL


Dr. R.S. GUPTA
 MD (Pathology) (MAHE)
 Director
 RMC No. 7924/19778

TECHNOLOGIST

All investigations have their own limitations regarding the sensitivity & specificity of individual assay procedures. Isolated laboratory investigations never confirm the final diagnosis of the disease. They only help in arriving at a diagnosis in conjunction with clinical presentation and other related investigations. Report is not valid for medico-legal purpose subject to ALWAR jurisdiction only.



दक्ष हॉस्पिटल

396, गाँधी नगर स्कीम नं.8, अलवर (राज०) ☎ 0144-2703340

Sonography / 2D Echo Cardiography / Doppler Report

2D/ ECHO REPORT

Name: - Mr Mahendra Prasad Age: - 33 Yrs Date: - 23-Mar-24

Reg. No.:- Alw/2009/04
BOB health checkup

PROCEDURES: M-MODE/2D/DOPPLER/COLOR/CONTRASTB.A.S. M²

MEASUREMENT:			DOPPLER:				
AOD	26	NORMAL (20- 37mm)	MV	0.6	NORMAL (0.8- 1.3)	MR	No
LA	226	(19- 40mm)	AV	1.4	(1.2- 1.8)	AR	No
AVO	19	(12- 25mm)	TV	0.6	(0.3- 0.8)	TR	No
RVDd.	14.9	(03- 09mm)	PV	0.8	(0.7- 1.1)	PR	No
LVDd	47.9	(37- 56mm)	MITRAL VALVE-				
LVDs	26.5	(22- 40mm)			AML	Normal	
IVS d	7.8	(06- 12mm)			PML	Normal	
IVS s	12		AORTIC VALVE				
PWd	5	(05- 10mm)				Normal	
LV FUNCTION			TV & PV are normal.				
M- E- S Separation		<0.9cm					
Minor		24.42%					
LV Ejection Fraction	76%	65 +/- 12%					

LV WALL MOTION: NO RWMA
ALL CARDIAC CHAMBERS ARE NORMAL
ALL VALVES ARE NORMAL
NO CLOT, VEGETATION, PERICARDIAL EFFUSION

FINAL DIAGNOSIS: NORMAL STUDY

Adv: - Follow up/ review at higher center for confirmation

Note:- Please Correlate clinically. Due to technical limitations as well as inaccuracies inherent in the laboratory and statistical analysis of biological process. Diagnostic accuracy of ECHO is up to 95% only.
Report is not valid for medico-legal purpose.


Dr. Mukesh Kumar Gupta
DR. MUKESH GUPTA
Physician & Sonologist
RM 5423/16262



"भ्रूण लिंग परीक्षण की शिकायत
104 टोल फ्री सेवा पर भी की
जा सकती है"

भ्रूण लिंग परीक्षण की शिकायत 104 टोल फ्री सेवा पर भी की जा सकती है।



दक्ष हॉस्पिटल

396, गाँधी नगर स्कीम नं.8, अलवर (राज०) ☎ 0144-2703340

Sonography / 2D Echo Cardiography / Doppler Report

Name: MR. MAHENDRA PRASAD /M/33 YRS

Date: 23-Mar-24

BOB HEALTH CHECK UP

U.S.G. OF ABDOMEN & PELVIS

LIVER

Liver is **15.5 cm at vertically with mild increase echogenicity**. Intra hepatic biliary radicals are not dilated.
No evidence of focal or diffuse lesion.

GALL BLADDER

Gall bladder is well distended, visualized lumen appear clear. Wall thickness normal. CBD normal

PANCREAS

Pancreas is normal in size, shape & echo-texture.

SPLEEN

8.9 cm in size with normal shape & echo- texture.

BOTH KIDNEY

Both kidney normal shape, size & echo texture. CMD maintained

PROSTATE is normal shape, size & echo texture..

URINARY BLADDER is normal shape, size & echo texture..

Impression:- Grade I fatty liver.

Please correlate clinically. USG accuracy is 95 % due to technical limitations as well as inaccuracies inherent in the laboratory and statistical analysis biological process.

This report is not valid for medico-legal cases.


DR. MUKESH GUPTA
Dr. Mukesh Kumar Gupta
Physician & Sonologist
RM 5423/16262



"भ्रूण लिंग परीक्षण की शिकायत
104 टोल फ्री सेवा पर भी की
जा सकती है"

भ्रूण लिंग परीक्षण की शिकायत 104 टोल फ्री सेवा पर भी की जा सकती है।

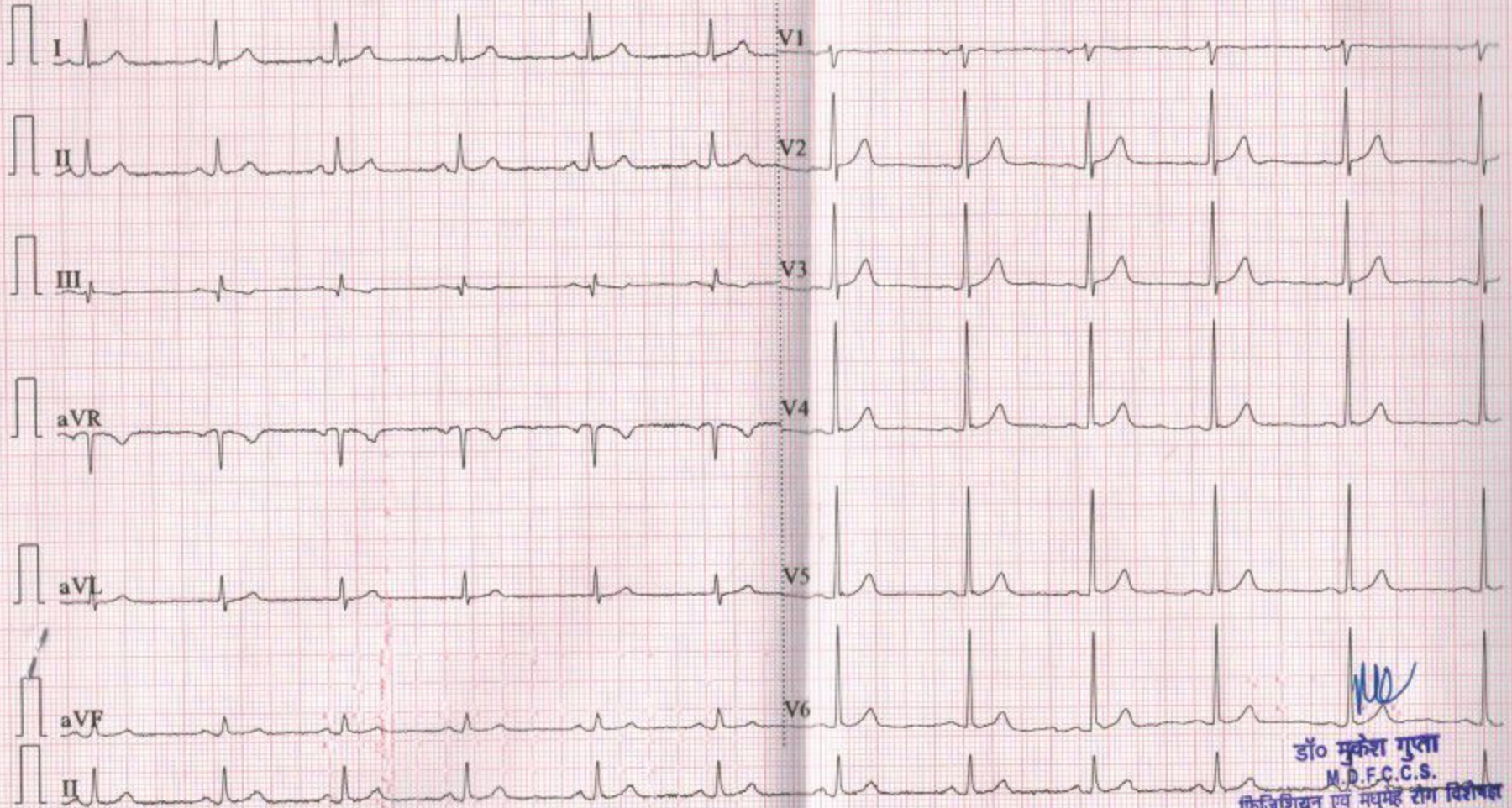
ID: 5

male Years

HR : 68 bpm
 P : 113 ms
 PR : 156 ms
 QRS : 82 ms
 QT/QTc : 337/361 ms
 P/QRS/T : 54/38/26 °
 RV5/SV1 : 1.853/0.269 mV

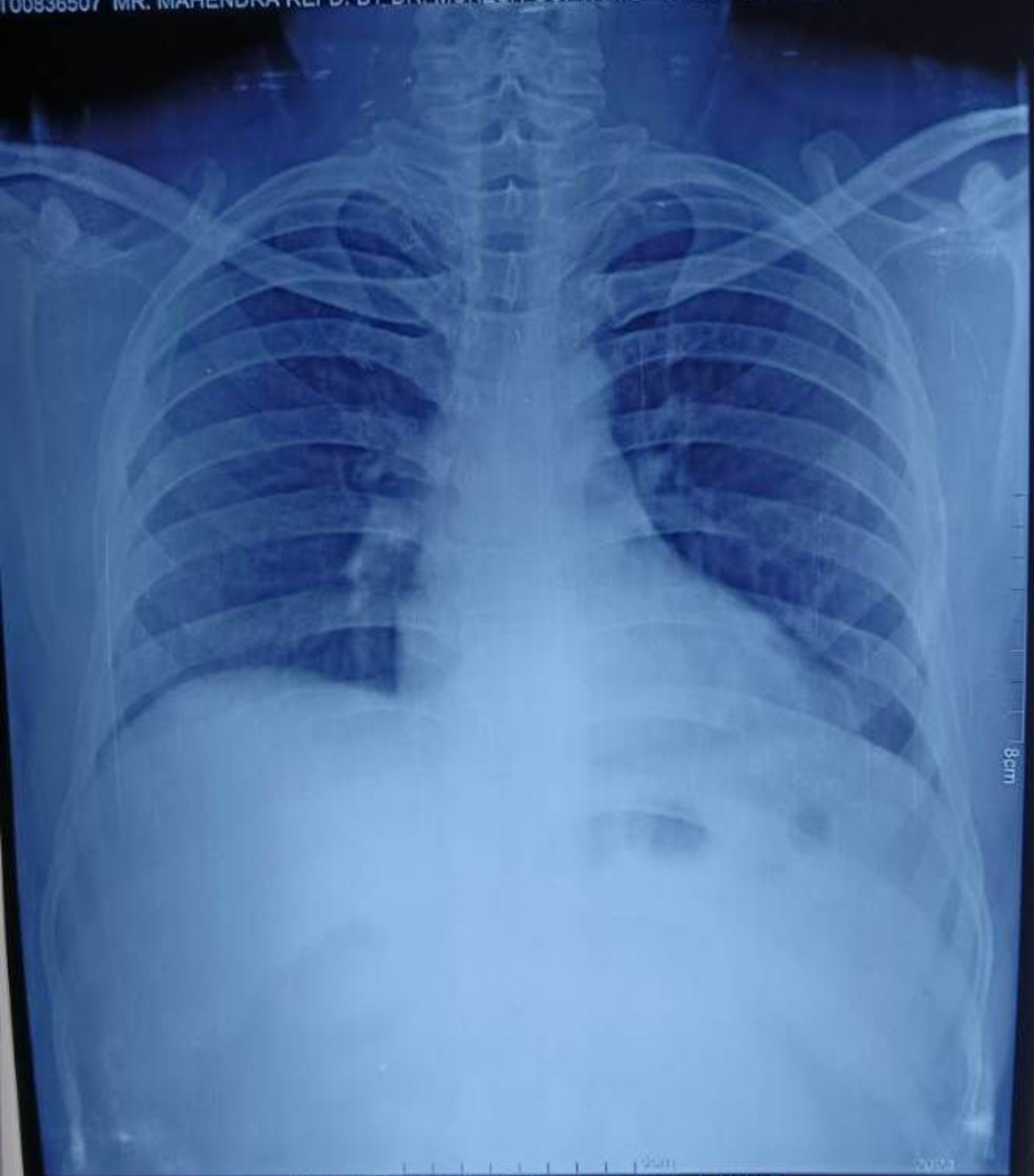
Diagnosis Information:
 Sinus Rhythm
 Normal ECG

Report Confirmed by:



डॉ० मुकेश गुप्ता
 M.D.F.C.C.S.
 फिजिशियन एवं मधुमेह रोग विशेषज्ञ
 दक्ष हॉस्पिटल, अलवर
 रजि० नं०-5423/16262

T00836507 MR. MAHENDRA REFD. BY DR. MUKESH GUPTA MD CHEST 23.03.2024



8cm