

**DAKSH HOSPITAL**

396 - 397, Gandhi Nagar, Scheme No. 8, ALWAR -301001

Ref. No.

Date.....

MEDICAL EXAMINATION REPORT

Mediwheel (BOB)

Name: Mr. Harshit Mittal

Age: 30 yrs

Sex: Male

Date: 22-03-2024

General Physical Examination

Height : 170 cm  
Pulse : 78 mt  
Respiration : 18/mt

Weight : 75.60 kg  
BP : 118/80 mm/hg  
BMI : 26.2 kg/m<sup>2</sup>

Systemic Exam:-

NORMAL

Dental Check up:-

NORMAL

Eve check-up:-

NORMAL

Skin Check up:-

NORMAL

ENT Check up:-


NORMAL

Impression:-

NORMAL

Recommendation:-

NO

  
Dr. Mukesh Kumar Gupta  
MD Gen. Medicine  
Reg. No 5423/16262

डॉ० मुकुंश गुप्ता  
M.D F.C.C.S.  
फिजिशियन एवं मधुमेह रोग विशेषज्ञ  
दक्ष हॉस्पिटल, अलवर  
रजि० नं०-5423/16262

## Results

Run Date 22/03/2024 09:33:09 AM

Operator DAKSH

Last Name

Sample ID 3

First Name MR HARSHIT MITTAL

Department

Gender Male Age

Physician DR. MUKESH GUPTA M.D

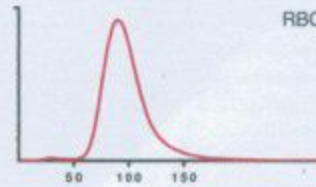
Patient ID AUTO\_PID20410

Type Man

Date of birth

Sample comments

			Range
RBC	4.41	10 <sup>6</sup> /μL	3.80 - 5.50
HGB	13.9	g/dL	13.0 - 17.0
HCT	42.8	%	39.0 - 52.0
MCV	97.0	μm <sup>3</sup>	76.0 - 100.0
MCH	31.4	pg	26.0 - 34.0
MCHC	32.3	g/dL	32.0 - 35.0
RDW-CV	17.8	H %	11.0 - 16.0
RDW-SD	66.7	H μm <sup>3</sup>	37.0 - 49.0



### Recommended actions


Slide review

### Susp. Pathologies

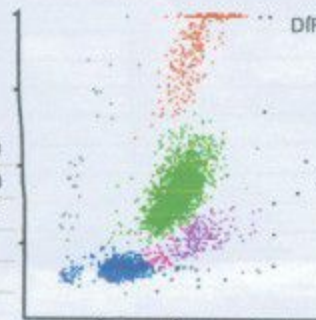
Anisocytosis

Macroplatelets

			Range
PLT	186	* 10 <sup>3</sup> /μL	150 - 450
PCT	0.24	* %	0.15 - 0.40
MPV	12.9	H* μm <sup>3</sup>	8.0 - 11.0
PDW	25.5	H* μm <sup>3</sup>	11.0 - 22.0
P-LCC	94	10 <sup>3</sup> /μL	44 - 140
P-LCR	50.7	h %	18.0 - 50.0



			Range		Range
WBC	6.84	10 <sup>3</sup> /μL	3.50 - 10.00		
	#	Range	%	Range	
NEU	3.50	1.60 - 7.00	51.3	40.0 - 75.0	
LYM	2.73	1.00 - 3.00	40.1	20.0 - 45.0	
MON	0.09	0.20 - 0.80	1.3	2.0 - 10.0	l
EOS	0.43	0.00 - 0.50	6.3	1.0 - 6.0	h
BAS	0.07	0.00 - 0.15	1.0	0.0 - 1.0	
LIC	0.02	0.00 - 0.10	0.3	0.0 - 1.0	



*[Signature]*

Dr. R.S. GUPTA  
MD (Pathology) (MAHE)  
RMC No. 7924/19778


Date :-22/03/2023

Name :- MR. HARSHIT MITTAL

Age &amp; Sex :- 30Yrs/ male

Refd. :- Dr Mukesh Gupta M.D.

	TEST NAME	RESULT	REFERENCE RANGE	
	ESR	12	00 -20 mm/hrs	
	Blood Group & Rh Factor	B " POSITIVE		
	HbA1C	4.2	4 - 5.6%	
	Blood Sugar (F)	118.1	< 70 - 100 mg/dl	
	Blood Sugar (PP)	131.7	< 140 mg/dl	
	Urine Sugar (F)	NIL	-	
	Urine Sugar (PP)	NIL	-	
LIVER	S.Bilirubin Total	0.90	0.30 - 1.20 mg/dl	
	S.Bilirubin Direct	0.20	0.10 - 0.30 mg/dl	
	S.Bilirubin Indirect	0.70	0.30 - 0.90 mg/dl	
	S.G.O.T.	36	> 37 u/l	
	S.G.P.T.	48	> 40 u/l	
	S.Alk. Phosp.	199	80 - 306 u/l	
	G.G.T.	18.1	5 -40 u/l	
	Total Protein	6.9	6.5 - 8.5 gm/dl	
	Albumin	3.7	3.8 - 5.4 gm/dl	
	Globulin	3.2	2.3 - 3.5 gm/dl	
	A/G Ratio	1.2	-	
	AST/ALT Ratio	0.8	-	
KIDNEY	Blood Urea	29.1	15 -45 mg/dl	
	S.Creatinine	0.9	0.60 - 1.30 mg/dl	
	BUN	20.1	6 -24 mg/dl	
	S.Uric Acid	5.1	M 3.1 - 7.0, F 2.5 - 5.6 mg/dl	
	BUN/Creatinine Ratio	20.1	-	
LIPID PROFILE	Total Cholesterol	140.1	Up to 200 mg/dl	
	S.HDL	42.1	30 - 70 mg/dl	
	S.LDL	74.1	Up to 170 mg/dl	
	S.VLDL	27.1	5.0 - 40 mg/dl	
	S. Triglycerides	135.1	Up to 170 mg/dl	
	LDL/HDL Ratio	1.7	-	
Total Cholesterol/ HDL Ratio	3.3	-		
THYROID	T3	89.1	40 - 181 ng/dL	
	T4	2.9	4.6 - 10.5 µg/dL	
	TSH	3.85	0.30 - 5.0 mIU/L	
<b>URINE EXAMINATION</b>			<i>Microscopic Examination :</i>	
General/Chemical Examination:	Colour	Pale Yellow	RBC	Absent
	Reaction	Acidic	WBC	1 -2
	Specific Gravity	QNS	Epithelial Cells	0- 1
	Appearance	Clear	Cast	Absent
	Albumin	Nil	Crystal	Absent
	Sugar	Nil	Spermatozoa	Absent
			Amorphous Sediments	Absent
		Other	Absent	
X-RAY CHLST	NORMAL STUDY			
<b>STOOL EXAMINATION</b>			<i>Microscopic Examination :</i>	
General/ Chemical Examination:	Colour	-	RBC	-
	Consistency	-	WBC	-
	PH	-	Ova & Parasites	-
	Reducing Substances	-		

  
**Dr. R.S. GUPTA**  
 MD (Pathology) (MAHE)  
 Doctor. 792419778

**TECHNOLOGIST**

All investigation have their own limitations regarding the sensitivity & specificity of individual assay procedures, Isolated laboratory investigations never confirm the final diagnosis of the disease. They only help in arriving at a diagnosis in conjunction with clinical presentation and other related investigations. Report is not valid for medico-legal purpose subject to ALWAR jurisdiction only.



# दक्ष हॉस्पिटल

396, गाँधी नगर स्कीम नं.8, अलवर (राज०) ☎ 0144-2703340

## Sonography / 2D Echo Cardiography / Doppler Report

### 2D/ ECHO REPORT

Name: - Mrs HARSHIT MITTAL

Age: - 30 Yrs

Date: - 22-Mar-24

Reg. No.: - Alw/2009/04

BOB health checkup

PROCEDURES:

M-MODE/2D/DOPPLER/COLOR/CONTRASTB.A.S. M<sup>2</sup>

MEASUREMENT:		DOPPLER:	
AOD	18	NORMAL	NORMAL (cm/sec.)
LA	25	(20- 37mm)	MV 0.8 (0.8- 1.3) MR No
AVO	16	(19- 40mm)	AV 1.3 (1.2- 1.8) AR No
RVDd.	15.5	(12- 25mm)	TV 0.6 (0.3- 0.8) TR No
		(03- 09mm)	PV 0.8 (0.7- 1.1) PR No
LVDd	50	(37- 56mm)	MITRAL VALVE-
LVDs	32	(22- 40mm)	AML Normal
IVS d	5	(06- 12mm)	PML Normal
IVS s	11		
PWd	4.5	(05- 10mm)	AORTIC VALVE Normal
LV FUNCTION		TV & PV are normal.	
M- E- S Separation	<0.9cm		
Minor	24.42%		
LV Ejection Fraction	65%	65 +/- 12%	

MITRAL E>A

LV WALL MOTION: NO RWMA

ALL CARDIAC CHAMBERS ARE NORMAL

ALL VALVES ARE NORMAL

NO CLOT, VEGETATION, PERICARDIAL EFFUSION

Adv: - Follow up/ review at higher center for confirmation

Note:- Please Correlate clinically. Due to technical limitations as well as inaccuracies inherent in the laboratory and statistical analysis of biological process. Diagnostic accuracy of ECHO is up to 95% only. Report is not valid for medico-legal purpose.

DR. MUKESH GUPTA  
Dr. Mukesh Gupta  
PHYSICIAN

Physician & Sonologist

RM 5423/16262



"भ्रूण लिंग परीक्षण की शिकायत  
104 टोल फ्री सेवा पर भी की

भ्रूण लिंग परीक्षण की शिकायत 104 टोल फ्री सेवा पर भी की जा सकती है।



# दक्ष हॉस्पिटल

396, गाँधी नगर स्कीम नं.8, अलवर (राज०) ☎ 0144-2703340

## Sonography / 2D Echo Cardiography / Doppler Report

Name: MR. HARSHIT MITTAL /M/30 YRS

Date: 22-Mar-24

BOB HEALTH CHECK UP

### U.S.G. OF ABDOMEN & PELVIS

#### LIVER

Liver is 13.1 cm with normal echo-texture. Intra hepatic biliary radicals are not dilated.  
No evidence of focal or diffuse lesion.

#### GALL BLADDER

Gall bladder is normal dilated. Lumen clear. Wall thickness normal. CBD normal

#### PANCREAS

Pancreas is normal in size, shape & echo-texture.

#### SPLEEN

8.2 cm in size with normal shape & echo- texture.

#### BOTH KIDNEY

Both kidney normal shape, size & echo texture. CMD maintained

PROSTATE is normal shape, size & echo texture..

URINARY BLADDER is well distended.

Advice- X Ray KUB / URINE EXAM

Please correlate clinically. USG accuracy is 95 % due to technical limitations as well as inaccuracies inherent in the laboratory and statistical analysis biological process.

This report is not valid for medico-legal cases.



DR. MUKESH GUPTA  
SONOLOGIST

Dr. Mukesh Kumar Gupta

Physician & Sonologist

RM 5423/16262



"भ्रूण लिंग परीक्षण की शिकायत  
104 टोल फ्री सेवा पर भी की  
जा सकती है"

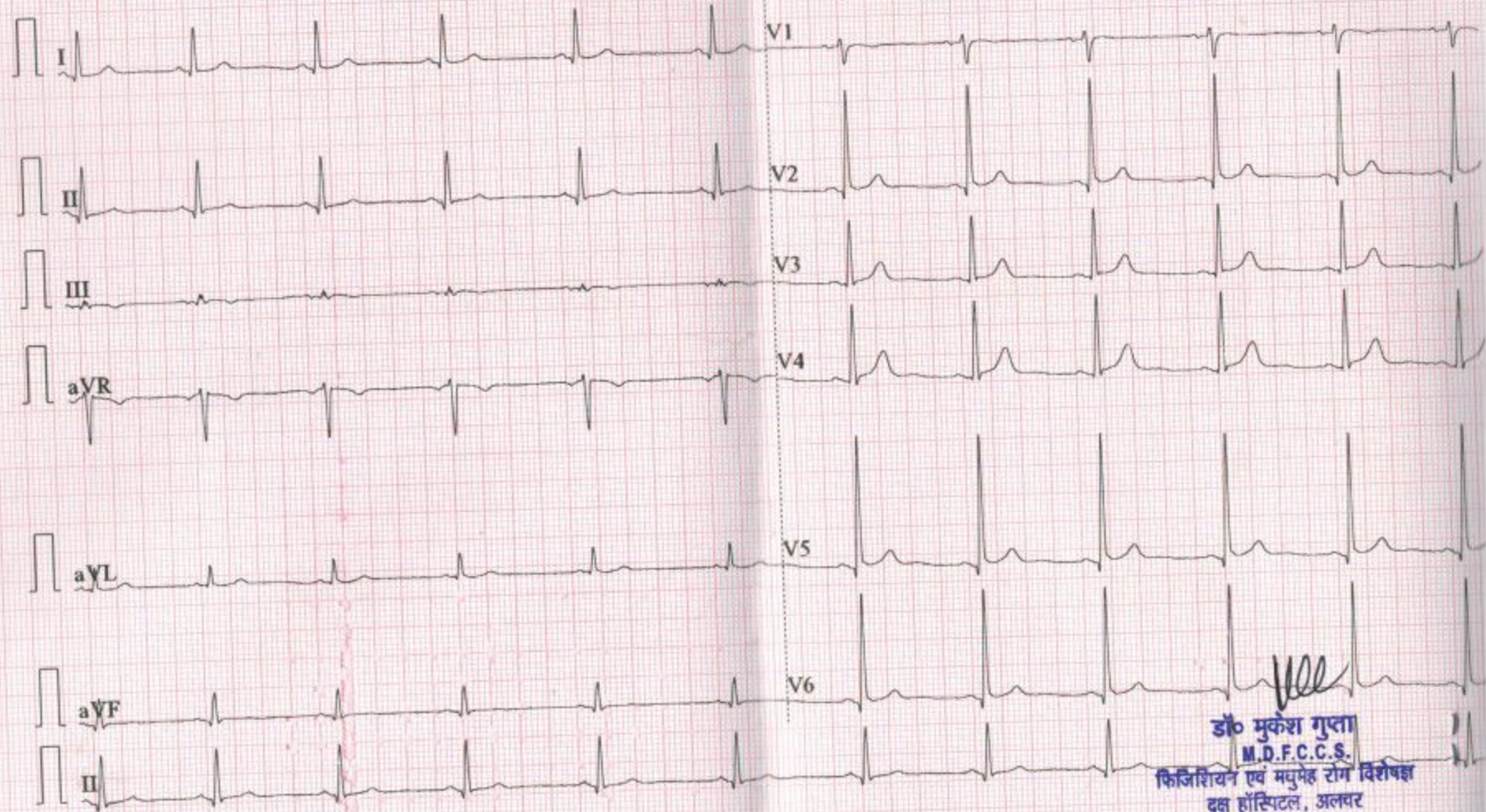भ्रूण लिंग परीक्षण की शिकायत 104 टोल फ्री सेवा पर भी की जा सकती है।

Female      Years

HR : 67 bpm  
P : 93 ms  
PR : 117 ms  
QRS : 78 ms  
QT/QTc : 341/362 ms  
P/QRS/T : 36/31/23 °  
RV5/SV1 : 2.16/0.362 mV

Diagnosis Information:  
Sinus Rhythm  
Short PR Interval

Report Confirmed by:



*[Signature]*  
डॉ० मुकेश गुप्ता  
M.D.F.C.C.S.

फिजिशियन एवं मधुमेह रोग विशेषज्ञ  
दक्ष हॉस्पिटल, अलवर  
रजि० नं०-5423/16262

R

