

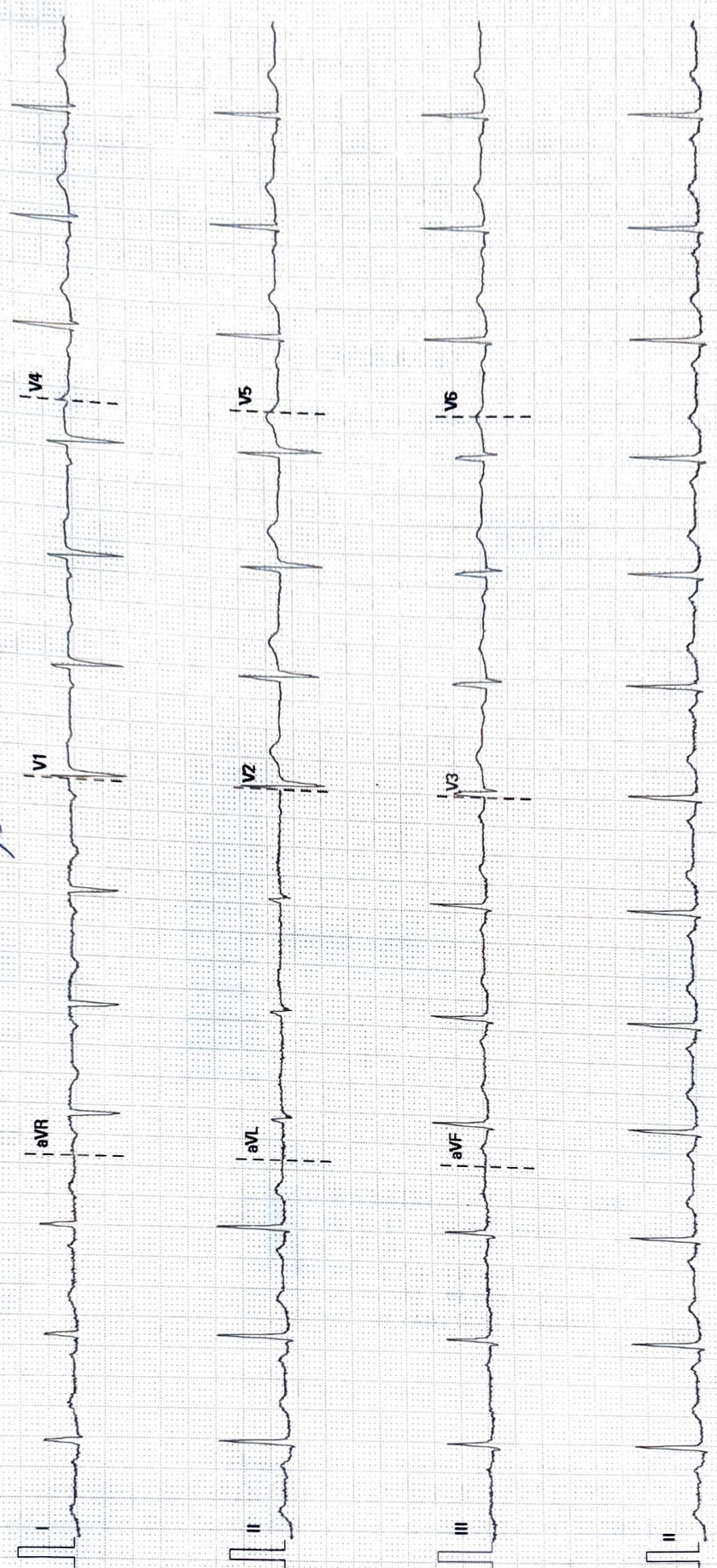
ID: 910063342
Name: MRS KEERTHANA S
Age: 31 Years
Gender: Female
Race:

2024-04-09 09:30:30 AM

Vent. Rate 82 bpm
PR Interval 172 ms
QRS Duration 76 ms
QT/QTc Interval 366/405 ms
P/ORS/T Axes 59/62/39 deg
QTc: Hodges

Sinus rhythm
Normal ECG

Keerthana S





PRASHANTH HOSPITALS

Name	: KEERTHANA, S	UHID	: 910063342
Sex / Age	: F / 31Y	Accession NO	: 9121185172
Study Date	: 9/4/2024, 11:03:29 am	Report Date	: 9/4/2024, 10:40:48 am
Ref Dr.	: DR. GOPALASWAMY G		

DEPARTMENT OF CARDIOLOGY

INVESTIGATION: ECHO

LV MEASUREMENTS

AO	24 mm	IVS d/s	09/11 mm
LA	33 mm	LVPW d/s	08/09 mm
LVID (ED)	35 mm	EF	67 %
LVID (ES)	24 mm	FS	36 %

MORPHOLOGICAL DATA

MITRAL VALVE :		
AML	:	NORMAL
PML	:	NORMAL
CHORDAE	:	NORMAL
AORTIC VALVE	:	NORMAL
TRICUSPID VALVE	:	NORMAL
PULMONARY VALVE	:	NORMAL
ATRIA	:	NORMAL
RIGHT VENTRICLE	:	NORMAL FUNCTION (TAPSE : 2.2 cm)
INTER ATRIAL SEPTUM	:	INTACT
INTER VENTRICULAR SEPTUM	:	INTACT
AORTA	:	NORMAL
PULMONARY ARTERY	:	NORMAL
PERICARDIUM	:	NORMAL

DOPPLER DATA :

MITRAL VALVE	:	NORMAL E/A RATIO AT MITRAL INFLOW
	:	TRIVIAL MR E : 83 cm/s, A : 72 cm/s
	:	E/E' : 9, S' : 7.6 cm/s
AORTIC VALVE	:	NO AR, NO AS, VEL : 136 cm/s
PULMONARY VALVE	:	NO PR, NO PS, VEL : 99 cm/s
TRICUSPID VALVE	:	TRIVIAL TR / NO PAH / TRPG: 19 mmHg

A Unit of PRASHANTH FERTILITY RESEARCH CENTRE PVT. LTD.

No. 36 & 36A, Velachery Main Road, Velachery, Chennai - 600 042. ☎ +91 93 8099 8099

☎ +91 44 4680 5544 / 2243 9494 ✉ info@prashanthhospitals.org 🌐 www.prashanthhospitals.org



PRASHANTH HOSPITALS

Name	: KEERTHANA, S	UHID	: 910063342
Sex / Age	: F / 31Y	Accession NO	: 9121185172
Study Date	: 9/4/2024, 11:03:29 am	Report Date	: 9/4/2024, 10:40:48 am
Ref Dr.	: DR. GOPALASWAMY G		

IMPRESSION

- ◆ NO REGIONAL WALL MOTION ABNORMALITY
- ◆ NORMAL LV SYSTOLIC AND DIASTOLIC FUNCTION (LVEF: 67 %)
- ◆ NORMAL RIGHT VENTRICLE FUNCTION (TAPSE: 2.2 cm)
- ◆ NO PERICARDIAL EFFUSION
- ◆ NO EVIDENCE OF CLOT OR VEGETATION

DONE BY :KARTHIKA. V
SR.ECHO TECHNOLOGIST

Dr. Sivakumar
MBBS.MD.,DNB.,FNB
Sr. Consultant Interventional Cardiologist
Reg. No: 68984

A Unit of PRASHANTH FERTILITY RESEARCH CENTRE PVT. LTD.

No. 36 & 36A, Velachery Main Road, Velachery, Chennai - 600 042. ☎ +91 93 8099 8099

☎ +91 44 4680 5544 / 2243 9494 ✉ info@prashanthhospitals.org 🌐 www.prashanthhospitals.org



PRASHANTH HOSPITALS

Name	: KEERTHANA S 31 YRS	UHID	: 910063342
Sex / Age	: F / ---	Accession NO	: 180053775
Study Date	: 9/4/2024, 12:35:46 pm	Report Date	: 9/4/2024, 3:37:19 pm
Ref Dr.	: DR. G . GOPALASWAMY		

CHEST X-RAY

Trachea and both main bronchi are normal.

Cardiac silhouette and cardiothoracic ratio are normal

Bilateral lung fields are clear. No focal lesion seen.


The cardiophrenic and costophrenic angles are free.

Both hemi diaphragms appear normal.

Bony thorax appears normal.

IMPRESSION:

No significant abnormality detected.


Dr. NARMADHA, MBBS., DMRD
CONSULTANT RADIOLOGIST
REG NO: 93293



PRASHANTH HOSPITALS

Patient Name	Mrs. Keerthana S	Age / Sex	31 Y/F
Patient ID	910063342	Visit No.	1
Ref. By	Dr. Gopaldaswamy.G	Visit Date	09.04.2024

USG ABDOMEN AND PELVIS

Upper Abdomen:

Liver normal in size measures (11.2 cm) and filled with homogeneous parenchymal echoes. No abscess or mass lesion in the liver. No dilatation of intrahepatic biliary radicals seen. Gall bladder walls and lumen appeared normal. No calculi seen. Common duct appeared normal. No calculi seen. Portal vein and Pancreas appeared normal. Spleen measures 10.6 cm and appears normal.

Kidneys:

RT. Kidney measures 10.5 x 4.5 cm. Cortex appears normal. Cortico medullary differentiation is maintained. Pelvicalyceal system is not dilated. No calculus is seen. Right ureter is not dilated.

LT. Kidney measures 11.5 x 4.5 cm. Cortex appears normal. Cortico medullary differentiation is maintained. Pelvicalyceal system is not dilated. No calculus is seen. Left ureter is not dilated.

Bladder:

Is normal in contour. No intra luminal echoes are seen. No calculus or diverticulum is seen.

Uterus:

Uterus measures 11.1 x 2.8 x 4.1 cm. Anteverted. Shows homogenous myometrial echoes. No focal lesion. Endometrium measures 4.3 mm. Cavity appears normal. Cervix: Appears normal. No focal lesion.

A Unit of PRASHANTH FERTILITY RESEARCH CENTRE PVT. LTD.

No. 36 & 36A, Velachery Main Road, Velachery, Chennai - 600 042. ☎ +91 93 8099 8099

☎ +91 44 4680 5544 / 2243 9494 ✉ info@prashanthhospitals.org 🌐 www.prashanthhospitals.org

Patient Name	Mrs. Keerthana S	Age / Sex	31 Y/F
Patient ID	910063342	Visit No.	1
Ref. By	Dr. Gopalswamy.G	Visit Date	09.04.2024

Ovaries:

Right ovary measures 2.4 x 1.5 cm.

Left ovary measures 3.7 x 1.6 cm.

Appear normal in size and echotexture.

P.O.D: No free fluid in POD. No adnexal mass lesion noted.


Retroperitoneum:

Aorta and IVC appears normal. No obvious para aortic lymphadenopathy.

No free fluid in peritoneal cavity. Pleural spaces appeared normal.

Impression:

- **No significant abnormality detected in the visualized organs.**


Dr. Narmadha, DMRD
Consultant Radiologist
Reg no : 93293

Note: This investigation has its own limitation. Hence sonographic findings should be correlated with clinical features and with further investigations. Not for medico legal purpose.



PRASHANTH HOSPITALS

EYE CHECK-UP REPORT

NAME : Mrs. Keerthana. S

DATE : 09/11/24

AGE / SEX : 31/F

UHID NUM : 910063342

Chief complaints : Regular eye check up

Past history : —

Systemic Diseases : —

DISTANCE VISION :

WITH OUT GLASS : 6/6, N6 6/6, N6

WITH GLASS : — —

COLOR VISION : NORMAL / ABNORMAL

GLASS PRESCRIPTION :

EYE	SPH	CYL	AXIS	V/A	SPH	CYL	AXIS	V/A
DISTANCE	± Plano	—	—	6/6	± Plano	—	—	6/6
ADD	—	—	—	N6	—	—	—	N6

ANTERIOR SEGMENT :

CORNEA & LENS : BE WNL

REMARK : CONTINUE WITH SAME GLASSE

ROUTINE CHECK UP AFTER 6/12 MONTH ✓

FUNDUSCOPY ONCE A YEAR


OPTOMETRIST

A Unit of PRASHANTH FERTILITY RESEARCH CENTRE PVT. LTD.

No. 36 & 36A, Velachery Main Road, Velachery, Chennai - 600 042. ☎ +91 93 8099 8099

© +91 44 4680 5544 / 2243 9494 ✉ info@prashanthhospitals.org 🌐 www.prashanthhospitals.org