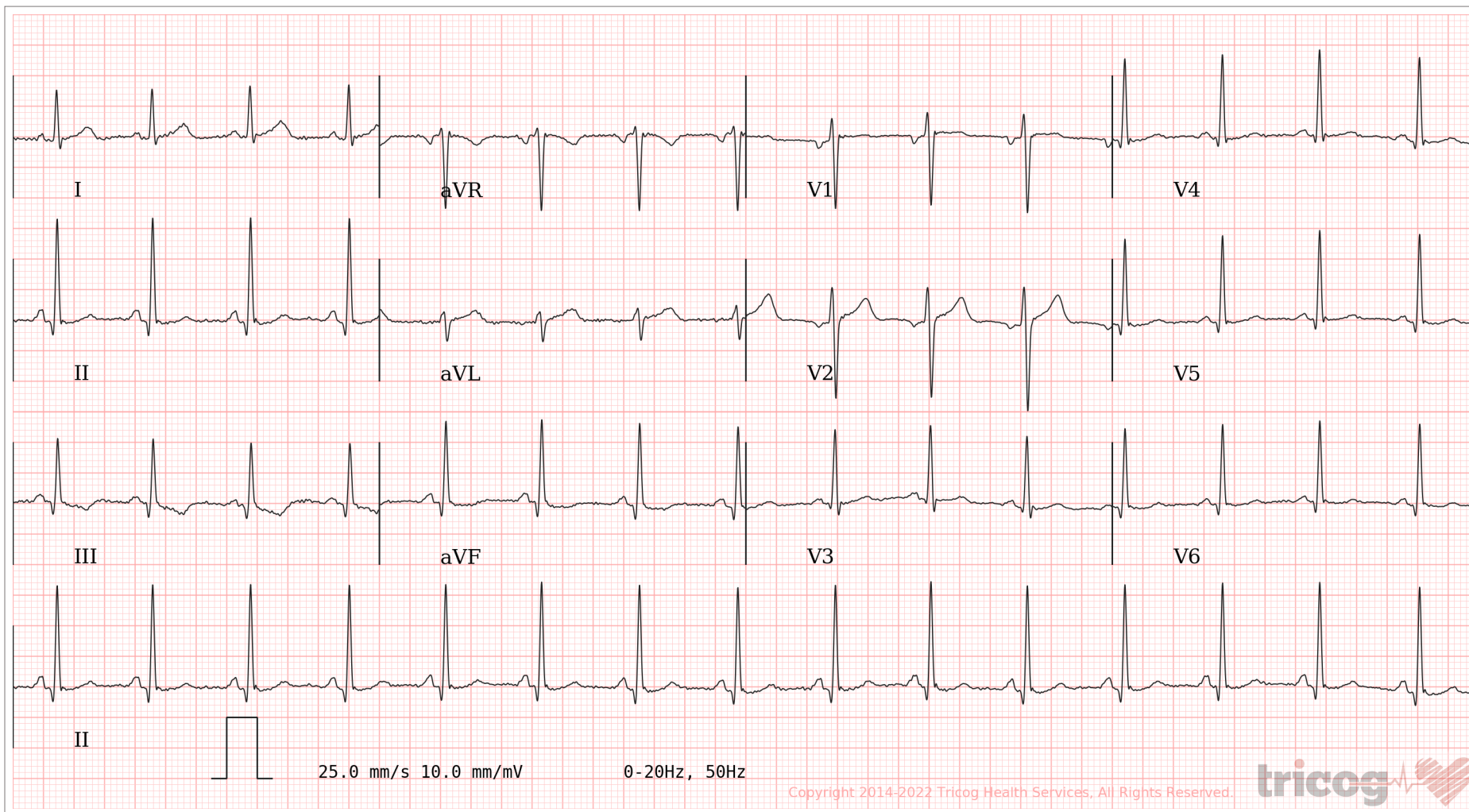


Chandan Diagnostic



Age / Gender: 32/Male
Patient ID: CVAR0048272223
Patient Name: Mr.GAURI SHANKAR KUMAR

Date and Time: 25th Sep 22 11:18 AM



AR: 94bpm VR: 94bpm QRSD: 84ms QT: 332ms QTcB: 415ms PRI: 114ms P-R-T: 64° 63° -4°

Sinus Rhythm, Normal Axis, Nonspecific ST and T wave Abnormality. Please correlate clinically.

AUTHORIZED BY

Dr. Charit
MD, DM: Cardiology

REPORTED BY

Dr Nethra

Disclaimer: Analysis in this report is based on ECG alone and should only be used as an adjunct to clinical history, symptoms and results of other invasive and non-invasive tests and must be interpreted by a qualified physician.

63382