

Name : Mrs. SHASHIKALA

Age: 44 Y

Sex: F

UHID:CMYS.0000060177



OP Number:CMYSOPV123751

Bill No :CMYS-OCR-22773

Date : 23.03.2024 08:04

 Address : SRIRANGAPATNA
 : ARCOFEMI MEDIWHEEL FEMALE AHC CREDIT PAN
 Plan INDIA OP AGREEMENT

Sl no	Service Type/ServiceName	Department
1	ARCOFEMI - MEDIWHEEL - FULL BODY ANNUAL PLUS CHECK ADVANCED - FEMALE - 2D ECHO - PAN INDIA - FY2324	
1	GAMMA GLUTAMYL TRANSFERASE (GGT)	
2	2D ECHO	
3	LIVER FUNCTION TEST (LFT)	
4	GLUCOSE, FASTING	
5	HEMOGRAM + PERIPHERAL SMEAR	
6	GYNACOLOGY CONSULTATION → P	
7	DIET CONSULTATION → P	
8	COMPLETE URINE EXAMINATION	HG → 152
9	URINE GLUCOSE(POST PRANDIAL)	WG → 56.4
10	PERIPHERAL SMEAR	Bp → 110/80
11	ECG	
12	LBC PAP TEST- PAPSURE	
13	RENAL PROFILE/RENAL FUNCTION TEST (RFT/KFT)	
14	DENTAL CONSULTATION	
15	GLUCOSE, POST PRANDIAL (PP), 2 HOURS (POST MEAL) 10.30 AM	
16	URINE GLUCOSE(FASTING)	
17	SONO MAMOGRAPHY - SCREENING	
18	HbA1c, GLYCATED HEMOGLOBIN	
19	X-RAY CHEST PA	
20	DENT CONSULTATION → P	
21	FITNESS BY GENERAL PHYSICIAN → P	
22	BLOOD GROUP ABO AND RH FACTOR	
23	LIPID PROFILE	
24	BODY MASS INDEX (BMI)	
25	OPHTHAL BY GENERAL PHYSICIAN	
26	ULTRASOUND - WHOLE ABDOMEN	
27	THYROID PROFILE (TOTAL T3, TOTAL T4, TSH)	

CERTIFICATE OF MEDICAL FITNESS

This is to certify that I have conducted the clinical examination

of Shashikala on 25/3/2024

After reviewing the medical history and on clinical examination it has been found that he/she is

	Tick
<ul style="list-style-type: none"> Medically Fit 	✓
<ul style="list-style-type: none"> Fit with restrictions/recommendations <p>Though following restrictions have been revealed, in my opinion, these are not impediments to the job.</p> <p>1.....</p> <p>2.....</p> <p>3.....</p> <p>However the employee should follow the advice/medication that has been communicated to him/her.</p> <p>Review after _____</p>	
<ul style="list-style-type: none"> Currently Unfit. Review after _____ recommended 	
<ul style="list-style-type: none"> Unfit 	

[Signature]
Dr. Radhachethan Kumar A.
 M.D. (General Medicine)
 Medical Officer
 Apollo Clinic, Mysore.

Apollo Health and Lifestyle Limited

CPIN: UAS110TG2000PLC115819
 Kingd Office: 1, 1D, 6D, 62, Ashoka Raghupathi Chambers, 5th Floor, Begumpet, Hyderabad, Telangana, India
 Ph: No. (044) 4904 7777 Fax: No. 4904 7744 | Email ID: enquiry@apollohl.com | www.apollohl.com

APOLLO CLINICS NETWORK KARNATAKA

Bangalore | Basavanagudi | Bellandur | Electronic City | Fraser Town | HSR Layout | Indira Nagar | JP Nagar | Kundalahalli |
 Kowmanigala | Sarjapur Road | Mysore (VV Mohalla)

Online appointments: www.apolloclinic.com

TO BOOK AN APPOINTMENT

1860 500 7788

This certificate is not meant for medico-legal purposes

Dental.

Da
Date : 23-03-2024
MR NO : CMYS.0000060177
Name : Mrs. SHASHIKALA
Age/ Gender : 44 Y / Female

Department : GENERAL
Doctor :
Registration No :
Qualification :

Consultation Timing: 08:04

Height : 152	Weight : 56.4	BMI :	Waist Circum :
Temp :	Pulse :	Resp :	B.P : 110/80

General Examination /
Allergies History

Clinical Diagnosis & Management Plan
CL by Dr. Sashikala

O/E

Cu-H, SFT +

ASU:- oral prophylaxis

Follow up date :

Sashikala
Doctor Signature
Apollo Clinic
23, 1st Floor,
Kalidasa Road, Mysore - 02
Ph : 0821-4006040/41

Date

MR No Date : 23-03-2024

Department : GENERAL

MR NO : CMYS.0000060177

Doctor :

Name

Age/ Name : Mrs. SHASHIKALA

Registration No :

Age/ Gender : 44 Y / Female

Qualification :

Const

Consultation Timing: 08:04

Height : 152	Weight : 56.4	BMI :	Waist Circum :
Temp :	Pulse :	Resp :	B.P : 110/80

General Examination / Allergies History

Hb 8.6 Hct 29.50 MCV 64
 HCT 29.50

Clinical Diagnosis & Management Plan

alo Compl

9: Sc

ag

h
r

Che Cu Su.

A de

1. Tab. orofar-xT (60)

2. B- protaripow (T)

3. Tab Bonds phy (DSE)

Doctor Signature

Follow up date :

Dr. Ravi Chethan Kumar
 M.B.B.S., MD (General Medicine)
 KMC Reg. No. B2089
 Apollo Clinic, K.D. Road, Mysore.

Date : 23-03-2024

Department : GENERAL

Ophthalm

MR NO : CMYS.0000060177

Doctor :

Name : Mrs. SHASHIKALA

Registration No :

Age/ Gender : 44 Y / Female

Qualification :

Consultation Timing: 08:04

Height: 152	Weight: 56.4	BMI:	Waist Circum:
Temp: 37	Pulse: 90/min	Resp: 20/min	B.P: 110/80

General Examination / Allergies History

- NO -

Clinical Diagnosis & Management Plan

Wearing corrected Spectacle.
Not wearing regularly.

NO H/O T2DM / HTN.

vision	(R)	(L)
Far	6/6	6/6
Near	N6	N6
colour	Not affected	

Follow up date :

Doctor Signature

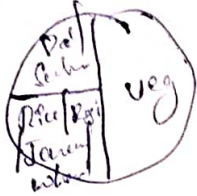
Apollo Clinic

23, 1st Floor,

Kalidasa Road, Mysore - 02

Ph: 0821-4006040/41

- Regular eye check up



Date : 23-03-2024
 MR NO : CMYS.0000060177
 Name : Mrs. SHASHIKALA
 Age/ Gender : 44 Y / Female

Department : GENERAL Dietetics
 Doctor : Madhura. B.P
 Registration No :
 Qualification : M.Sc Nutrition & Dietetics
 Ph.D

Consultation Timing: 08:04

Height: 152	Weight: 56.4	BMI: 24.6	Waist Circum: 80
Temp:	Pulse:	Resp:	B.P: 110/80

General Examination /
 Allergies History

HB - 8.6
 FBS - 109
 PPBS - 165

Clinical Diagnosis & Management Plan

- Advise low calorie, high protein diet with fiber rich foods.
- Dietary guidelines chart to be given.
- Include Iron rich foods like dark green leafy vegetable and other vegetables.

Follow up date :

Doctor Signature
 23/2/2024
Apollo Clinic
 # 23, 1st Floor,
 Kalidasa Road, Mysore - 02
 Ph : 0821-4006040/41


Department- Dietetics

Name- Madhura B P

Qualification- M.Sc Nutrition & Dietetic
PhD*

- Do not skip any of the meals, take small frequent meals.
- Include all variety of seasonal fruits, vegetables and green leafy vegetables on regular basis.
- Include nuts like Almond, Walnuts and dry-fruits like dried dates and raisins regularly.
- Include seeds like Flax seeds, Pumpkin seeds, Sunflower seeds, Sesame seeds and watermelon seeds- 1 teaspoon each and dry roasted.
- Avoid 5 white slow poisons like Sugar, Salt, Maida, Baking soda and creams.
- Cooking oil- ½ litre/person/month.
- Use combination of oils like Rice bran oil, Groundnut oil, Sesame oil, Mustard oil/ Coconut oil and Ghee. Change the oil every month or 2 months. But do not mix the oils.
- Drink at least 2-3 liters of water in a day.
- Skimmed or toned milk can be used on regular basis. Since it's a rich source of protein and low in calories.
- Avoid Butter, Vanaspati and Dalda.
- Avoid deep-fried foods, Biscuits, Cookies, Bakery products, Pastries, Papad, packed and processed foods, chocolates, Alcohol, caffeine and carbonated beverages.
- Avoid junk foods like Pizza and Burger.

Dietician signature


23/3/2024

Apollo Clinic
23, 1st Floor,
Kalidasa Road, Mysore - 02
Ph : 0821-2006040/41

Date : 23-03-2024
MR NO : CMYS.0000060177
Name : Mrs. SHASHIKALA
Age/ Gender : 44 Y / Female

Department : GENERAL
Doctor :
Registration No :
Qualification :

Consultation Timing: 08:04

Height : 152	Weight : 56.4	BMI :	Waist Circum :
Temp :	Pulse :	Resp :	B.P : 110/80

General Examination /
Allergies History

Clinical Diagnosis & Management Plan

Ear - normal, drums
Nose - normal, drums
throat - normal

Adv.

1.) Mupirocin ointment twice

Adv.

Follow up date :

Doctor's Signature
Apollo Clinic
23, 1st Floor,
Kalidasa Road, Mysore - 02
Ph : 0821-4006040/41

ID: 60177

23-03-2024 09:31:08 AM

MRS SHASHIKALA

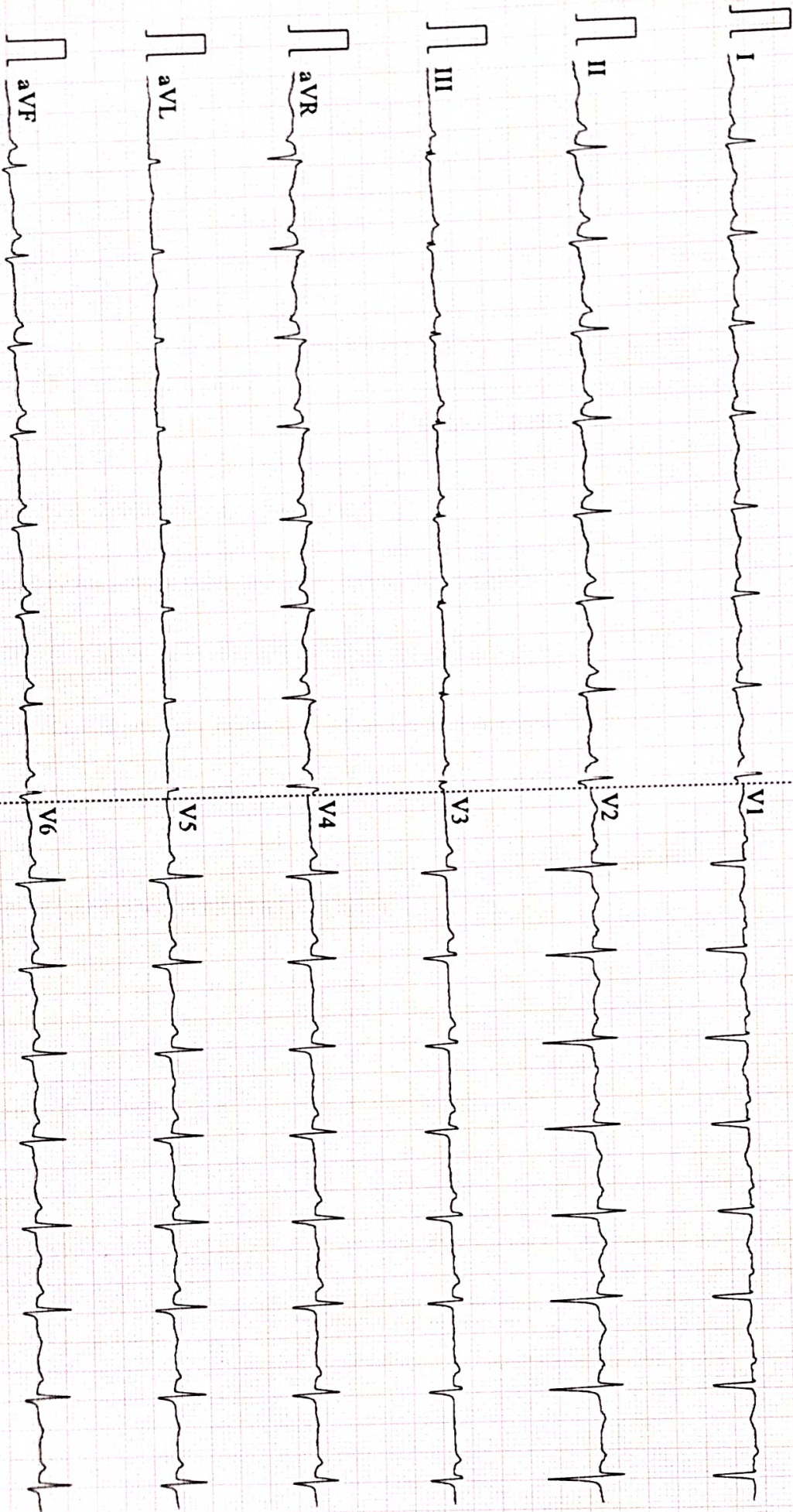
Female 44Years

152cm 56kg 110/80 mmHg

Diagnosis Information:

Unconfirmed Report.

Apollo Clinic
23, 1st Floor,
Kalidasa Road, Mysore - 01
Ph : 0821-4006040/41



0.5-45Hz AC50 25mm/s 10mm/mV 2*5.0s 97 CARDIART 3 D V1.43 Glasgow V28.6.0 APOLLO CLINIC MYSURU

Patient Name : Mrs. SHASHIKALA
UHID : CMYS.0000060177
Reported on : 23-03-2024 15:05
Adm/Consult Doctor :

Age : 44 Y F
OP Visit No : CMYSOPV123751
Printed on : 23-03-2024 15:05
Ref Doctor : SELF

DEPARTMENT OF RADIOLOGY

X-RAY CHEST PA

Both lung fields and hila are normal .

No obvious active pleuro-parenchymal lesion seen .

Both costophrenic and cardiophrenic angles are clear .


Both diaphragms are normal in position and contour .

Thoracic wall and soft tissues appear normal.

IMPRESSION :NORMAL STUDY .

Printed on:23-03-2024 15:05

---End of the Report---


Dr. CHETAN HOLEPPAGOL
MBBS, DNB(RADIO DIAGNOSIS)
Radiology

Apollo Health and Lifestyle Limited

CIN: U85110TG2000PLC115819

Regd Office: 110/60/62, Ashoka Raghupathi Chambers, 5th Floor, Begumpet, Hyderabad, Telangana - 500 016

Ph No: (04) 4904 7777 | Fax No: 4904 7744 | Email ID: enquiry@apollohl.com | www.apollohl.com

APOLLO CLINICS NETWORK KARNATAKA

Bangalore | Basavanagudi | Bellandur | Electronic City | Frazer Town | MSR Layout | Indira Nagar | JP Nagar | Kundalahalli |
Koramangala | Sarjapur Road | Mysore (VV Mohalla)

Online appointments: www.apolloclinic.com

TO BOOK AN APPOINTMENT

 **1860 500 7788**

Patient's Name : Mrs. SHASHIKALA	Age & Sex; 44Yrs /Female
Date : 23.03.2024	UHID No:060177

2D ECHOCARDIOGRAPHY STUDY

Impression:

- Normal chambers and valves
- No regional wall motion abnormality
- Normal left ventricular systolic function. EF 68 %
- No clots. No pericardial effusion

Findings

Left Ventricle:	No RWMA
Right Ventricle	Normal
Left Atrium	Normal
Right Atrium	Normal
Aorta	Normal
Pulmonary Artery	Normal
IAS	Intact
IVS	Intact
Valves	Normal
Pericardium	Normal
Doppler	Normal

Apollo Health and Lifestyle Limited

(CIN: UAS1107G2000PLC115819)

Regd Office: 1-10-60-62, Ashoka Raghupathi Chambers, 5th Floor, Begumpet, Hyderabad, Telangana - 500 016

Ph: No: (04) 4964 7777 Fax No: 4964 7744 | Email ID: enquiry@apollohl.com | www.apollohl.com

APOLLO CLINICS NETWORK KARNATAKA

Bangalore: Basavanagudi | Bellandur | Electronic City | Fraser Town | HSR Layout | Indira Nagar | JP Nagar | Kundalahalli |

Koramangala | Sarjapur Road | Mysore (VV Mohalla)

Online appointments: www.apolloclinic.com

TO BOOK AN APPOINTMENT

 **1860 500 7788**

Patient's Name : Mrs. SHASHIKALA	Age & Sex; 44Yrs /Female
Date : 23.03.2024	UHID No:060177

Measurements

AO : 2.4 cm
 LA : 2.3 cm

RV : 2.0 cm
 LVIDd 3.81 cm
 LVIDs : 2.38 cm
 IVSd : 0.73 cm
 IVSs : 1.02 cm
 PWd : 0.95 cm
 PWs : 1.21 cm
 EF : 68.0 %
 FS : 37.0 %

Doppler

	MV		TV		AV		PV			
E	0.97	m/s	E ---	m/s	V max	1.39	m/s	V max	1.01	m/s
A:	0.85	m/s	A ---	m/s						

Dr. GURU PRASAD. B. V
 MBBS, PGDCC (CARDIO)
 CCMH, CRFC (ICCP), PGCC, CCEBDM
 Consultant- Non Invasive Cardiology
 KMC No 69949

Dr. GURU PRASAD. B. V, MBBS, PGDCC
CONSULTANT – NON-INVASIVE CARDIOLOGY

Apollo Health and Lifestyle Limited

(CIN: U85110TG2000PLC115819)
 Regd. Office: 1-10-610-62, Ashoka Raghupathi Chambers, 5th Floor, Begumpet, Hyderabad, Telangana - 500 016
 Ph. No: (04) 4904 7777 Fax No: 4904 7744 | E-mail ID: enquiry@apollohl.com | www.apollohl.com

APOLLO CLINICS NETWORK KARNATAKA

Bangalore (Basavanagudi | Brindavanur | Electronic City | Fraser Town | HSR Layout | Indira Nagar | JP Nagar | Kundalahalli |
 Reshma Nagar | Sarjapur Road) Mysore (VV Mohalla)

Online appointments: www.apolloclinic.com

TO BOOK AN APPOINTMENT

1860 500 7788

Date : 23-03-2024
 MR NO : CMYS.0000060177
 Name : Mrs. SHASHIKALA
 Age/ Gender : 44 Y / Female

Department : GENERAL
 Doctor :
 Registration No :
 Qualification :

Consultation Timing: 08:04

Height: 152	Weight: 56.4	BMI:	Waist Circum:
Temp:	Pulse:	Resp:	B.P: 110/80

General Examination /
 Allergies History

PH - NS
 2H - NS

Hb - 1. ↓

Adv:

Hb 1.
 2BS
 6PBS
 8m unrlated Hb 1.

June 2024

Empty stomach -
 8:30am

Clinical Diagnosis & Management Plan

mH - regular ylls.
 mod flow.
 Imp - 12/12/24.

m - 2 yrs. Palp -
 Both FTNDs
 not to be touched

mammogram -
 breasts - normal slides
 ush - normal slides

IAB. BANDY PLUS (1) ✓
23/3/24

Follow up date :

[Signature]
 Doctor Signature

Apollo Clinic
 # 23, 1st Floor,
 Kalidasa Road, Mysore - 02
 Ph : 0821-4006040/41

Patient Name: Mrs. SHASHIKALA	Date : 23.03.2024	Referring Doctor: DR Self
Age / Sex: 44Yrs/Female	UHID No : 0060177	Location : OP
ULTRASONOGRAPHY- ABDOMEN & PELVIS		

LIVER: It is normal in size and echotexture. No focal lesions seen. IHBR are not dilated. CBD and Portal vein are normal.

GALL BLADDER: It is well distended and normal. No calculi seen.

SPLEEN: It is normal in size, outline and echopattern. No e/o focal lesions.

PANCREAS: It is normal.

RIGHT KIDNEY: It measures 9.3x3.8 cm with parenchymal thickness of 1.2 cm. It is normal in size, outline and echotexture. No e/o calculus or hydronephrosis seen.

LEFT KIDNEY: It measures 8.9x4.0 cm with parenchymal thickness of 1.2 cm. It is normal in size, outline and echotexture. No e/o calculus or hydronephrosis seen.

URINARY BLADDER: It is well distended. The UB wall is normal. No calculi seen.

UTERUS: It is anteverted and measures 9.1x5.0x5.8 cm with ET= 14mm. It is normal in size, outline and echotexture. No mass lesion.

Rt. OVARY: It measures 3.7x1.9 cm. It is normal. No mass lesion seen.

Lt. OVARY: It measures 3.2x1.5cm. It is normal. No mass lesion seen.

OTHERS: No e/o free fluid in the abdomen. No e/o lymphadenopathy. No e/o gut wall thickening. No mass lesion seen in the abdomen.

IMPRESSION: NORMAL STUDY.


Dr. Chetan H, DNB
Consultant Radiologist.

Apollo Health and Lifestyle Limited

REGD. OFFICE (UIN: UB5110102000PLC115819)

Regd. Office: 110/10/02, Ashoka Raghupathi Chambers, 5th Floor, Begumpet, Hyderabad, Telangana - 500 016

Ph. No: 044 4904 7777 | Fax No: 4904 7744 | Email ID: enquiry@apollohl.com | www.apollohl.com

APOLLO CLINICS NETWORK KARNATAKA

Bangalore: Basavanagudi | Bellandur | Electronic City | Fraser Town | MSR Layout | Indra Nagar | JP Nagar | Kundalahalli |

Koramangala | Sarjapur Road | Mysore (VV Mohalla)

Online appointments: www.apolloclinic.com

TO BOOK AN APPOINTMENT

1860 500 7788

Patient Name: Mrs. SHASHIKALA	Date : 23.03.2024	Referring Doctor: Dr. Self
Age / Sex: 44Yrs/Female	UHID No : 0060177	Location : OP
ULTRASONOGRAPHY- BREAST		

RIGHT BREAST: It is normal in echopattern. No e/o focal nodular or mass lesions seen. No e/o calcifications. The skin over the breast is normal. Nipple and areola are normal. The subcutaneous, mammary and retro mammary zones are normal.

LEFT BREAST: It is normal in echopattern. No e/o focal nodular or mass lesions seen. No e/o calcifications. The skin over the breast is normal. Nipple and areola are normal. The subcutaneous, mammary and retro mammary zones are normal.

No e/o axillary lymphadenopathy.

IMPRESSION: NORMAL STUDY.

Dr. Chetan S H. DMRD DNB
Consultant Radiologist.

Apollo Health and Lifestyle Limited

ICIN : URS1101G2000PLC1158191

Regd Office: 110 RD 62, Ashoka Raghupathi Chambers, 5th Floor, Begumpet, Hyderabad, Telangana - 500 016

Ph No: (91) 4904 7777 Fax No: 4904 7744 | E-mail: enquiry@apollohcl.com | www.apollohcl.com

APOLLO CLINICS NETWORK KARNATAKA

Bangalore: Basavanagudi | Bellandur | Electronic City | Frasier Town | HSR Layout | Indra Nagar | JP Nagar | Kundalahalli | Koramangala | Sarjapur Road. **Mysore:** VV Mahalla

Online appointments: www.apollohcl.com

TO BOOK AN APPOINTMENT

1860 500 7788