

Name : Mr. NAVA CHAITANYA

Age: 33 Y

UHID:CMYS.0000060188

Sex: M



Address : MYSORE

OP Number:CMYSOPV123773

Plan : ARCOFEMI MEDIWHEEL MALE AHC CREDIT PAN
INDIA OP AGREEMENT

Bill No :CMYS-OCR-22791

Date : 23.03.2024 08:57

| Sno | Service Type/ServiceName | Department |
|-----|--|------------|
| 1 | ARCOFEMI - MEDIWHEEL - FULL BODY ANNUAL PLUS MALE - 2D ECHO - PAN INDIA - FY2324 | |
| 1 | GAMMA GLUTAMYL TRANSFERASE (GGT) | |
| 2 | 2 D ECHO → P | |
| 3 | LIVER FUNCTION TEST (LFT) | |
| 4 | GLUCOSE, FASTING | |
| 5 | HEMOGRAM + PERIPHERAL SMEAR | |
| 6 | DIET CONSULTATION → P | |
| 7 | COMPLETE URINE EXAMINATION | |
| 8 | URINE GLUCOSE(POST PRANDIAL) | |
| 9 | PERIPHERAL SMEAR | |
| 10 | ECG | |
| 11 | RENAL PROFILE/RENAL FUNCTION TEST (RFT/KFT) | del H 88 |
| 12 | DENTAL CONSULTATION | H/F 169 |
| 13 | GLUCOSE, POST PRANDIAL (PP), 2 HOURS (POST MEAL) * | |
| 14 | URINE GLUCOSE(FASTING) | 110/80 |
| 15 | HbA1c, GLYCATED HEMOGLOBIN | |
| 16 | X-RAY CHEST PA | |
| 17 | ENT CONSULTATION → P | |
| 18 | FITNESS BY GENERAL PHYSICIAN → P | |
| 19 | BLOOD GROUP ABO AND RH FACTOR | |
| 20 | LIPID PROFILE | |
| 21 | BODY MASS INDEX (BMI) | |
| 22 | OPHTHAL BY GENERAL PHYSICIAN | |
| 23 | ULTRASOUND - WHOLE ABDOMEN → P | |
| 24 | THYROID PROFILE (TOTAL T3, TOTAL T4, TSH) | |

CERTIFICATE OF MEDICAL FITNESS

This is to certify that I have conducted the clinical examination

of NARA CHAITANYA on 23/03/2024

After reviewing the medical history and on clinical examination it has been found that he/she is

| | Tick |
|--|------|
| <ul style="list-style-type: none"> Medically Fit | ✓ |
| <ul style="list-style-type: none"> Fit with restrictions/recommendations <p>Though following restrictions have been revealed, in my opinion, these are not impediments to the job.</p> <p>1.....</p> <p>2.....</p> <p>3.....</p> <p>However the employee should follow the advice/medication that has been communicated to him/her.</p> <p>Review after _____</p> | |
| <ul style="list-style-type: none"> Currently Unfit. Review after _____ recommended | |
| <ul style="list-style-type: none"> Unfit | |

Dr. Ravichandran
M.B.B.S., MD (D)
KMC Reg. No. 82081
Apollo Clinic, K.D. Road, Mysore.
Apollo Clinic # 23, 1st Floor,
Kalidasa Road, Mysore - 02
Medical Officer: 0821-4066040/11
The Apollo Clinic, Mysore.

Apollo Health and Lifestyle Limited

This certificate is not meant for medico-legal purposes

APOLLO CLINICS NETWORK KARNATAKA
Bangalore | Hebbal | Bellandur | Electronic City | Fraser Town | HSR Layout | Indira Nagar | JP Nagar | Kundalahalli |
Kumarajala | Sarjapur Road | Mysore (VV Mohalla)
Online appointments: www.apolloclinic.com

TO BOOK AN APPOINTMENT

1860 500 7788

Date : 23-03-2024
MR NO : CMYS.0000060188

Department : GENERAL
Doctor :

Name : Mr. NAVA CHAITANYA

Registration No :

Age/ Gender : 33 Y / Male

Qualification :

Consultation Timing: 08:56

| | | | |
|--------------|-------------|--------|----------------|
| Height : 169 | Weight : 88 | BMI : | Waist Circum : |
| Temp : | Pulse : | Resp : | B.P : 110/80 |

General Examination /
Allergies History

Clinical Diagnosis & Management Plan

Ax

no Com

up

9

6

2

Ax

life style modify

R/A 3 months
TFT



Dr. Ravi Chethan Kumar
M.B.B.S., MD (General Medicine)
KMC Reg. No. 82089
Apollo Clinic, K.D. Road, Mysore.

Follow up date :

Doctor Signature

Apollo Clinic
23, 1st Floor,
Kalidasa Road, Mysore - 02
Ph : 0821-4006040/41

Date : 23-03-2024
MR NO : CMYS.0000060188

Department : GENERAL [dental]
Doctor :

Name : Mr. NAVA CHAITANYA

Registration No :

Age/ Gender : 33 Y / Male

Qualification :

Consultation Timing: 08:56

| | | | |
|-------------|------------|-------|----------------------|
| Height: 169 | Weight: 88 | BMI: | Waist Circum: 110/80 |
| Temp: | Pulse: | Resp: | B.P: |

General Examination /
Allergies History

Clinical Diagnosis & Management Plan

O/E

CA+1, St-1-1

Adv - oral prophylaxis

$$\frac{211}{765} \quad 12$$

PRM Bridge present
Asymptomatic

Follow up date :

[Signature]

Doctor Signature

Apollo Clinic
23, 1st Floor,
Kalidasa Road, Mysore - 02
Ph : 0821-4006040/41

Date : 23-03-2024
MR NO : CMYS.0000060188

Department : GENERAL
Doctor : ENT

Name : Mr. NAVA CHAITANYA

Registration No :
Qualification :

Age/ Gender : 33 Y / Male

Consultation Timing: 08:56

| | | | |
|--------------|-------------|--------|-----------------------|
| Height : 169 | Weight : 88 | BMI : | Waist Circum : 110/80 |
| Temp : | Pulse : | Resp : | |

General Examination /
Allergies History

Clinical Diagnosis & Management Plan

ENT Examination

(L) Impacted wax

dx

1) Wax impaled
2° - 3 times x 1 week

meeth

Follow up date :

Doctor Signature

Apollo Clinic
23, 1st Floor,
Kalidasa Road, Mysore - 02
Ph : 0821-4006040/41

Date : 23-03-2024
MR NO : CMYS.0000060188

Department : GENERAL (Ophthalm)
Doctor :

Name : Mr. NAVA CHAITANYA
Age/ Gender : 33 Y / Male

Registration No :
Qualification :

Consultation Timing: 08:56

| | | | |
|--------------|----------------|-----------|----------------|
| Height : 169 | Weight : 88 | BMI : | Waist Circum : |
| Temp : (9) | Pulse : 76/min | Resp : 20 | B.P : 110/80 |

General Examination /
Allergies History

NO

Clinical Diagnosis & Management Plan

Not wearing Spectacle,
No fresh complaints
No H/O T2DM / HTN
Not on Rx.

| | | |
|--------|---------------|-----|
| vision | (R) | (L) |
| Far | 6/6 | 6/6 |
| Near | N6 | N6 |
| colour | Not affected. | |

Follow up date :

Regular follow up.

Doctor Signature
Apollo Clinic
23, 1st Floor,
Kaldasa Road, Mysore - 02
Ph : 0821-4006040/41

ID: 60188

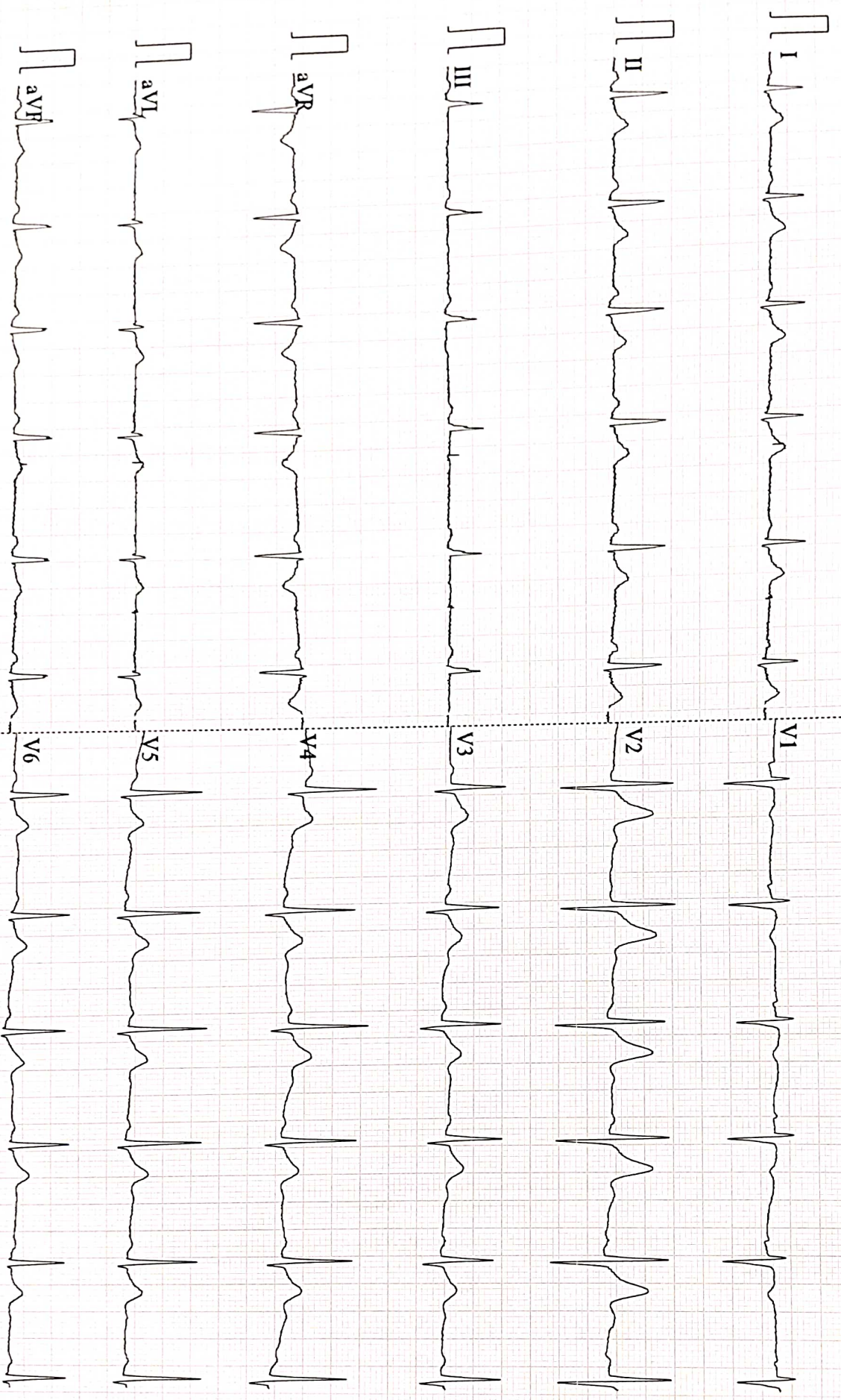
23-03-2024 12:32:05 PM

Diagnosis Information:

MR VUPPATI NAVYA CHAITANYA
Male 33Years
169cm 88kg 110/80 mmHg

Apollo Clinic
23, 1st Floor,
Kalladasa Road, Mysore - 02
Ph : 0821-4006040/41

Unconfirmed Report.



| | | | |
|--------------------|----------------------|-------------|--------------------|
| Patient Name | : Mr. NAVA CHAITANYA | Age | : 33 Y M |
| UHID | : CMYS.0000060188 | OP Visit No | : CMYSOPV123773 |
| Reported on | : 23-03-2024 15:20 | Printed on | : 23-03-2024 15:21 |
| Adm/Consult Doctor | : | Ref Doctor | : SELF |

DEPARTMENT OF RADIOLOGY

X-RAY CHEST PA

Both lung fields and hila are normal .
No obvious active pleuro-parenchymal lesion seen .
Both costophrenic and cardiophrenic angles are clear .
Both diaphragms are normal in position and contour .
Thoracic wall and soft tissues appear normal.

IMPRESSION :NORMAL STUDY .

Printed on:23-03-2024 15:20

---End of the Report---


Dr. CHETAN HOLEPPAGOL
MBBS, DNB(RADIO DIAGNOSIS)
Radiology

Apollo Health and Lifestyle Limited

(CIN : U85110TG2000PLC115819)
Regd. Office: 1-10-6/0 B2, Ashoka Raghupathi Chambers, 5th Floor, Begumpet, Hyderabad, Telangana - 500 016
Ph.No: 040-4904 7777 Fax No: 4904 7744 | Email ID: enquiry@apollohl.com | www.apollohl.com

APOLLO CLINICS NETWORK KARNATAKA

Bangalore: Basavanagudi | Bellandur | Electronic City | Fraser Town | HSR Layout | Indira Nagar | JP Nagar | Kundalahalli |
Kumaracarya | Sarjapur Road | Mysore (VV Mohalla)

Online appointments: www.apolloclinic.com

TO BOOK AN APPOINTMENT

 **1860 500 7788**

Scanned with CamScanner

| | | | |
|---|--|------------------|------------------------|
| Patient Name: Mr. NAVA CHAITANYA | | Date: 23.03.2024 | Referring Doctor: Self |
| Age / Sex : 33yrs / Male | | UHID : 0060188 | |
| ULTRASONOGRAPHY – ABDOMEN & PELVIS | | | |

LIVER: It is normal in size, outline and echotexture. No focal lesions seen. IHBR are not dilated. CBD and Portal vein are normal.

GALL BLADDER: It is partially distended and normal. No evidence of calculi.

SPLEEN: It is normal in size, outline and echopattern. No e/o focal lesions.

PANCREAS: It is normal in size, outline and echopattern.


RIGHT KIDNEY: It measures 10.4x3.8 cm with parenchymal thickness of 1.6 cm. It is normal in size, outline and echotexture. No e/o calculus or hydronephrosis seen.

LEFT KIDNEY: It measures 9.5x4.0 cm with parenchymal thickness of 1.6 cm. It is normal in size, outline and echotexture. No e/o calculus or hydronephrosis seen.

URINARY BLADDER: It is well distended. The UB wall is normal. No e/o calculi.

PROSTATE: It is normal in size, outline and echotexture.
No e/o free fluid in the abdomen.

IMPRESSION: NORMAL STUDY.


Dr. Chetan H, DNB
Consultant Radiologist.

| | |
|-------------------------------------|------------------------|
| Patient's Name : Mr. NAVA CHAITANYA | Age & Sex; 33Yrs /Male |
| Date : 23.03.2024 | UHID No:060188 |

2D ECHOCARDIOGRAPHY STUDY

Impression:

- Normal chambers and valves
- No regional wall motion abnormality
- Normal left ventricular systolic function. EF 67 %
- No clots. No pericardial effusion

Findings

| | |
|------------------|---------|
| Left Ventricle: | No RWMA |
| Right Ventricle | Normal |
| Left Atrium | Normal |
| Right Atrium | Normal |
| Aorta | Normal |
| Pulmonary Artery | Normal |
| IAS | Intact |
| IVS | Intact |
| Valves | Normal |
| Pericardium | Normal |
| Doppler | Normal |

Apollo Health and Lifestyle Limited

(CIN: U85110TG2000PLC115819)
 Head Office: 1, 1D to 62, Ashoka Raghupathi Chambers, 5th Floor, Begumpet, Hyderabad, Telangana - 500 016
 Ph. No: (04) 4904 7777 Fax No: 4904 7744 | Email ID: enquiry@apollohi.com | www.apollohi.com

APOLLO CLINICS NETWORK KARNATAKA

Bangalore: Basavanagudi | Bellandur | Electronic City | Fraser Town | HSR Layout | Indira Nagar | JP Nagar | Kundalahalli |
 Karamangala | Sarjapur Road | Mysore (VV Mohalla)

Online appointments: www.apolloclinic.com

TO BOOK AN APPOINTMENT

1860 500 7788

| | |
|-------------------------------------|------------------------|
| Patient's Name : Mr. NAVA CHAITANYA | Age & Sex; 33Yrs /Male |
| Date : 23.03.2024 | UHID No:060188 |

Measurements

AO : 2.6 cm
 LA : 2.9 cm

 RV : 2.5 cm
 LVIDd 4.86 cm
 LVIDs : 3.05 cm
 IVSd : 1.02 cm
 IVSs : 1.43 cm
 PWd : 1.05 cm
 PWs : 1.14 cm
 EF : 67.0 %
 FS : 37.0 %

Doppler

| | | | |
|------------|-----------|----------------|----------------|
| MV | TV | AV | PV |
| E 0.85 m/s | E --- m/s | V max 1.26 m/s | V max 1.26 m/s |

A: 0.42 m/s A --- m/s

Dr. GURU PRASAD. B. V, MBBS, PGDCC
CONSULTANT – NON-INVASIVE CARDIOLOGY

Dr. GURU PRASAD. B. V
MBBS, PGDCC (CARDIO)
CCMH, CRFC (ICCP), PGCC, CCEBDM
Consultant- Non Invasive Cardiology
KMC No 69949

Apollo Health and Lifestyle Limited

CIN: U85110TG2000PLC115819
 Regd Office: 110-6D-02, Ashoka Raghupathi Chambers, 5th Floor, Begumpet, Hyderabad, Telangana - 500 016
 Ph: No: 040 4934 7777 | Fax: No: 4934 7744 | Email ID: enquiry@apollohl.com | www.apollohl.com

APOLLO CLINICS NETWORK KARNATAKA

Bangalore | Hebbal | Jayadev | Bellandur | Electronic City | Fraser Town | MSR Layout | Indira Nagar | JP Nagar | Kundalahalli |
 Kuvempu | Sarjapur Road | Mysore (VV Mohalla)

Online appointments: www.apolloclinic.com

TO BOOK AN APPOINTMENT

1860/500 7788