



॥ ॐ गणेशाय नमः ॥

GANESH DIAGNOSTIC

DR. LOKESH GOYAL

MBBS (KEMC), MD (RADIOLOGY)
CONSULTANT INTERVENTIONAL RADIOLOGIST
FORMER SR. REGISTRAR - APOLLO HOSPITAL, NEW DELHI
LIFE MEMBER OF IMA

Timings : 9:00 am to 9:00 pm, Sunday 9.00 am to 3.00 pm ☎ 8392957683, 6395228718

MR. SACHIN SINGH 40/M
DR. NITIN AGARWAL, DM

23-03-2024

EXAMINATION PERFORMED ULTRASOUND WHOLE ABDOMEN

The Liver is normal in size and outline. It shows uniform echopattern. No obvious focal pathology is seen. The intra and extra hepatic biliary passages are not dilated.

The Gall Bladder is normal in size. Wall is thin. There is e/o single calculus 14 mm with distal acoustic shadowing seen within the lumen. No wall edema or pericholecystic fluid is seen. Sonographic Murphy's sign is negative. CBD is clear.

The Pancreas is normal in size and echogenicity. Its outlines are distinct. No obvious focal lesion, calcification or ductal dilatation is seen.

Spleen is normal in size and echogenicity. There is no evidence of collaterals.

Right Kidney is normal in position, outline and echogenicity. No evidence of calculi or calyceal dilatation is seen. Renal mobility is not impaired. Perinephric space is clear.

Left Kidney is normal in position, outline and echogenicity. No evidence of calculi or calyceal dilatation is seen. Renal mobility is not impaired. Perinephric space is clear.

No ascitis or pleural effusion. No retroperitoneal adenopathy.

The Urinary Bladder is normal in size and outline. Walls are thin & smooth. There is no evidence of any obvious intraluminal or perivesical pathology.

The Prostate is normal in size and volume. Homogenous parenchyma. Median lobe is not projecting. The Seminal Vesicles are normally visualized.

Bowel loops are non- dilated; gas filled & show normal peristaltic activity.

IMPRESSION:- CHOLELITHIASIS (SINGLE CALCULUS 14 MM), CBD CLEAR

DR LOKESH GOYAL
MD
RADIODIAGNOSIS

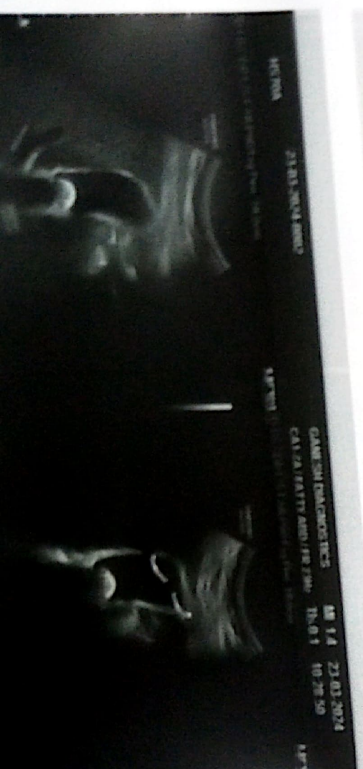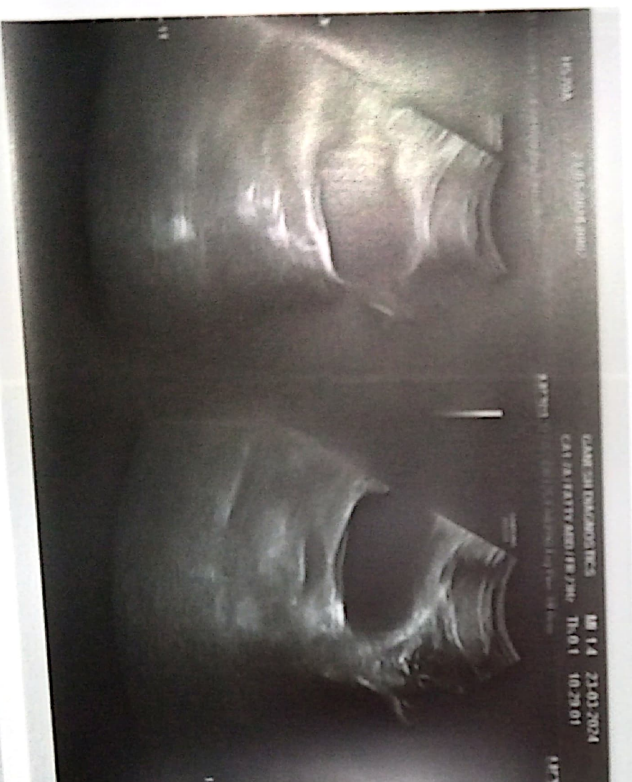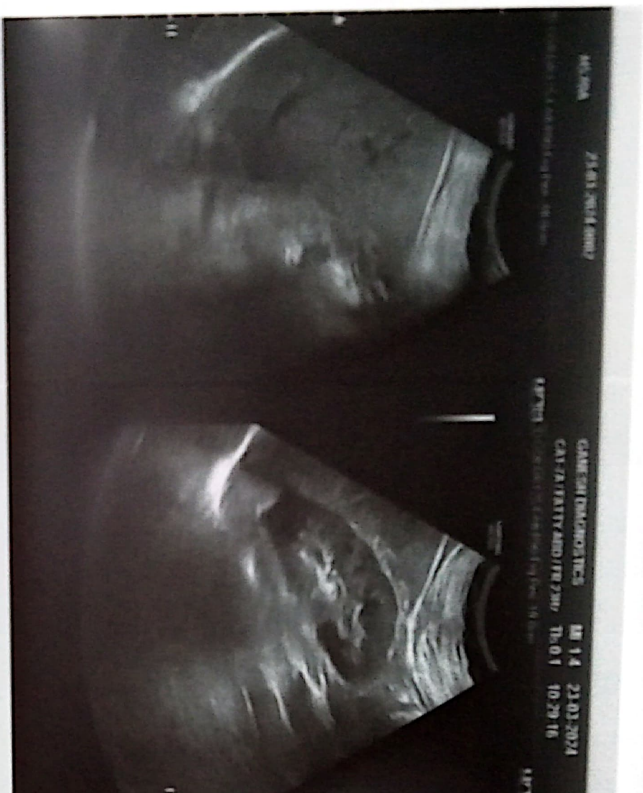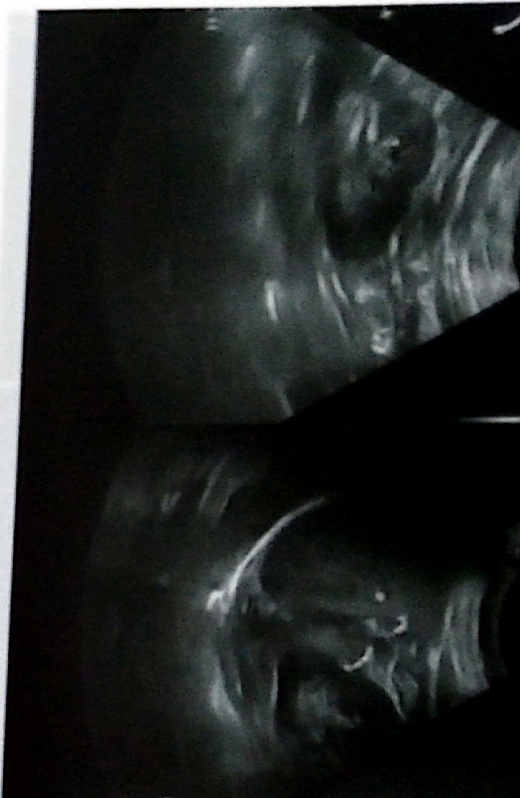Every imaging has its limitations. This is a professional opinion, not a final diagnosis. For further confirmation of diagnosis, clinical-pathological correlation & relevant next line investigation (TVS for gynecological disorders) (endoscopy / CT scan for bowel pathologies) are required. In case of clinical discrepancy with the report or confusion, reexamination / reevaluation are suggested. Esp. for the surgical cases 2nd opinion is must. Your positive as well as negative feedbacks are most welcome for better results

Counter sign



डिजिटल एक्स-रे, मल्टी स्लाइस
सी. टी. स्कैन सुविधा उपलब्ध है।

NOT VALID FOR
MEDICO LEGAL PURPOSE





॥ ॐ गणेशाय नमः ॥

GANESH DIAGNOSTIC

DR. LOKESH GOYAL
MBBS (KGMU), MD (RADIOLOGY)
CONSULTANT INTERVENTIONAL RADIOLOGIST
FORMER SR. REGISTRAR - APOLLO HOSPITAL, NEW DELHI
LIFE MEMBER OF IRIA

Timings : 9:00 am to 9:00 pm, Sunday 9.00 am to 3.00 pm

8392957683, 6395228718

MR. SACHIN SINGH 40/M
DR. NITIN AGARWAL, DM

23-03-2024

REPORT

EXAMINATION PERFORMED: X-RAY CHEST

B/L lung fields are clear

Both of the CP angles are clear.

Both hila show a normal pattern .

Cardiac and mediastinal borders appear normal.

Visualized bony thorax and soft tissue of the chest wall appear normal.

IMPRESSION ---NO SIGNIFICANT ABNORMALITY IS SEEN

Not for medico-legal purpose

DR LOKESH GOYAL
MD
RADIOLOGIST

डिजिटल एक्स-रे, मल्टी स्लाइस
सी. टी. स्कैन सुविधा उपलब्ध है।



NOT VALID FOR
MEDICO LEGAL PURPOSE

m/mv 25mm/sec 32Hz

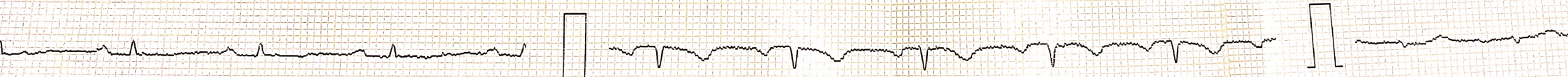
BPL

BPL CARDIART 6108T

10mm/mv 25mm/sec

aVR

aVL



... ID

Pat. ID .

CARDIART

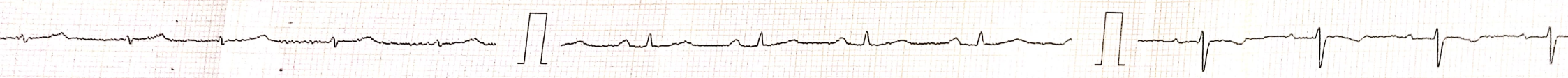
CARDIART

BPL CARDIART 6108T

10mm/mv 25mm/sec 32Hz

aVF

V1



Pat.ID

CARDIART

CARDIART

BPL

BPL CARDIART 6108T

BPL

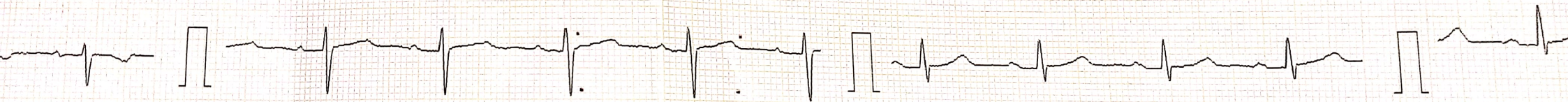
10mm/mv 25mm/sec 32Hz

BPL CARDIART

V2

V3

V4



Pat. ID

CARDIART

CARDIART

CARDIART 6108T

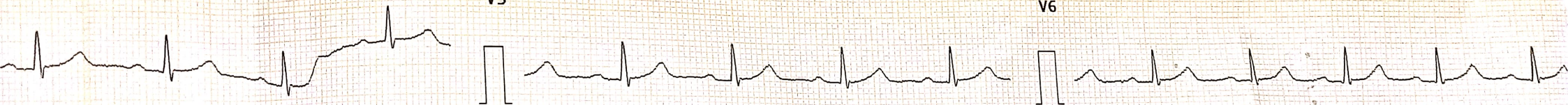
BPL

10mm/mv 25mm/sec 32Hz

BPL CARDIART 6108T

V5

V6



Pat.ID

BPL 10mm/mv 25mm/sec @ \approx 32Hz

BPL CARDIART 6108T



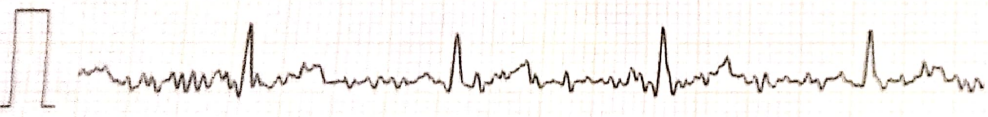
BPL

10mm

I

II

III



Pat. ID

Sachin

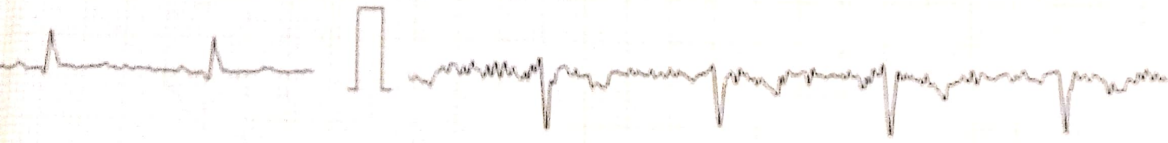23/03/24

CARDIART

112

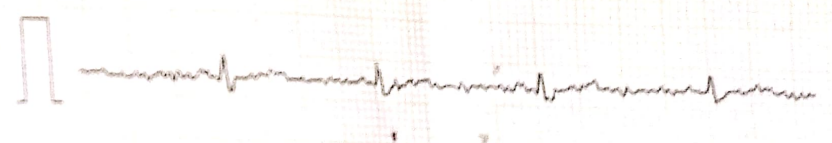
aVR

BPL CARDIART 6108T




aVL

10mm/mv 25mm/sec @ 32Hz



aVF

BPL CAR



Pat. ID

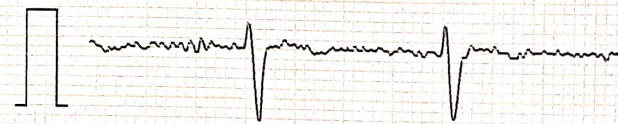
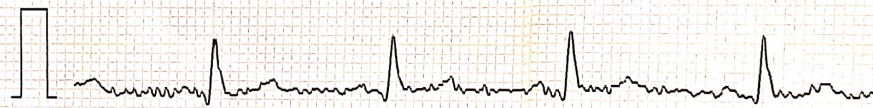
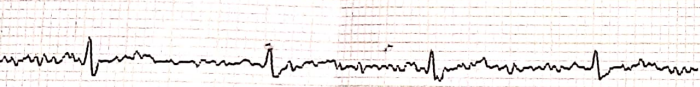
10mm/mv 25mm/sec @ 32Hz

BPL CARDIART 6108T

BPL 10mm/mv 25mm/sec @ 32Hz

aVF

V1



Pat.ID

Pat.ID

BPL CARDIART 6108T

BPL

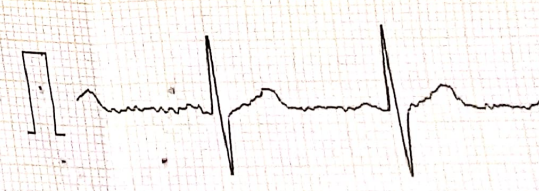
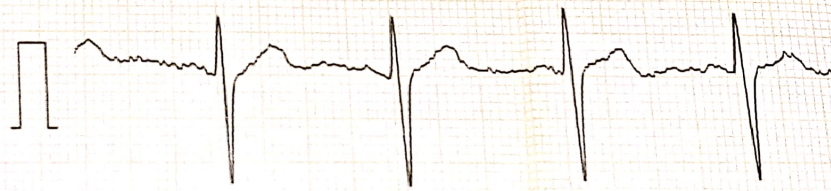
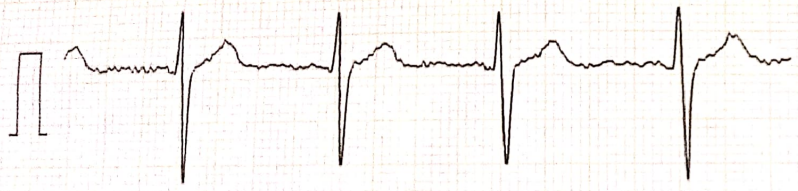
10mm/mv 25mm/sec @ ≈ 32Hz

BPL CARDIART 6108T

V2

V3

V4



Pat.ID

CARDIART

V3

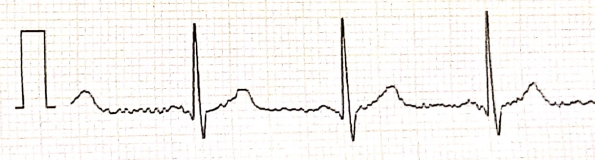
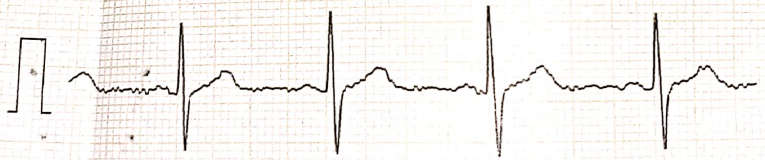
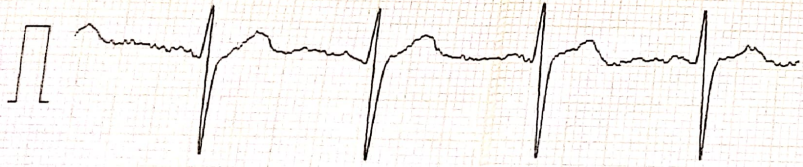
10mm/mv 25mm/sec @ ≈ 32Hz

BPL CARDIART 6108T

V5

10mm/mv 25mm/sec @ ≈ 32Hz

V4



Pat.ID

CARDIART

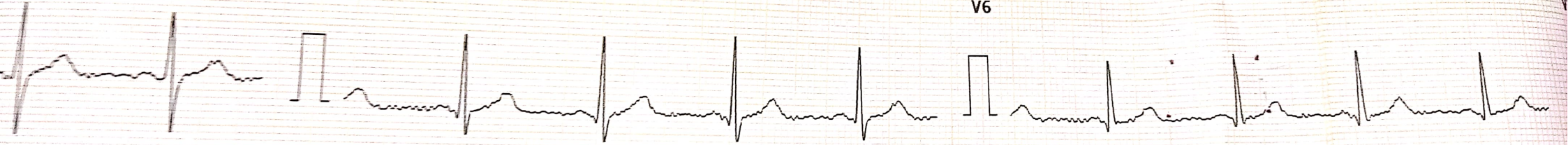
Pat.ID

V5

10mm/mv 25mm/sec @ \approx 32Hz ^{BPL}

BPL CARDIART 6108T

V6



Pat.ID

CARDIART

CARDIART