


8, 9, 12

<b>Name</b> : Mrs. ANIMA BORO  <b>Address</b> : MYSORE  <b>Plan</b> : ARCOFEMI MEDIWHEEL FEMALE AHC CREDIT PAN INDIA OP AGREEMENT	<b>Age</b> : 36 Y  <b>Sex</b> : F	<b>UHID</b> : CMYS 0000060155  <small>CMYS.0000060155</small> <b>OP Number</b> : CMYSOPV123706 <b>Bill No</b> : CMYS-OCR-22752 <b>Date</b> : 22.03.2024 09.08
---	---	--

Sno	Service Type/ServiceName	Department
1	ARCOFEMI - MEDIWHEEL - FULL BODY HEALTH ANNUAL PLUS CHECK - FEMALE - 2D ECHO - PAN INDIA - FY2324	
<input checked="" type="checkbox"/>	1 GAMMA GLUTAMYL TRANSFERASE (GGT)	
2	2 D ECHO	
<input checked="" type="checkbox"/>	3 LIVER FUNCTION TEST (LFT)	
<input checked="" type="checkbox"/>	4 GLUCOSE, FASTING	
5	5 HEMOGRAM + PERIPHERAL SMEAR	
6	6 GYNAECOLOGY CONSULTATION P	
7	7 DIET CONSULTATION P	
<input checked="" type="checkbox"/>	8 COMPLETE URINE EXAMINATION	IS 2
9	9 URINE GLUCOSE (POST PRANDIAL)	53.6
<input checked="" type="checkbox"/>	10 PERIPHERAL SMEAR	
<input checked="" type="checkbox"/>	11 ECG	Bps 96/60
12	12 LBC PAP TEST- PAPSURE <i>reorder</i>	
<input checked="" type="checkbox"/>	13 RENAL PROFILE/RENAL FUNCTION TEST (RFT/KFT)	
14	14 DENTAL CONSULTATION	
15	15 GLUCOSE, POST PRANDIAL (PP), 2 HOURS (POST MEAL)	
<input checked="" type="checkbox"/>	16 URINE GLUCOSE (FASTING)	
<input checked="" type="checkbox"/>	17 HbA1c, GLYCATED HEMOGLOBIN	
18	18 X-RAY CHEST PA	
19	19 ENT CONSULTATION P	
20	20 FITNESS BY GENERAL PHYSICIAN P	
<input checked="" type="checkbox"/>	21 BLOOD GROUP ABO AND RH FACTOR	
22	22 LIPID PROFILE	
<input checked="" type="checkbox"/>	23 BODY MASS INDEX (BMI)	
24	24 OPHTHAL BY GENERAL PHYSICIAN	
25	25 ULTRASOUND - WHOLE ABDOMEN	
<input checked="" type="checkbox"/>	26 THYROID PROFILE (TOTAL T3, TOTAL T4, TSH)	

Date : 22-03-2024  
MR NO : CMYS.0000060155

Department : GENERAL  
Doctor :

Name : Mrs. ANIMA BORO

Registration No :

Age/ Gender : 36 Y / Female

Qualification :

Consultation Timing: 09:08

Height : 152	Weight : 53.6	BMI :	Waist Circum :
Temp :	Pulse : 77/mt	Resp : 20/m	B.P : 90/60

General Examination /  
Allergies History

Clinical Diagnosis & Management Plan

AK  
RS  
PA / WAZ


Adh

R Nerval 510 - (30)

F Limea 520 810 - (20)

Regular Encesum

Follow up date :

  
Doctor Signature

Apollo Clinic  
# 23, 1st Floor,  
Kallidasa Road, Mysore - 02  
Ph : 0821-4006040/41

Date : 22-03-2024  
 MR NO : CMYS.0000060155  
 Name : Mrs. ANIMA BORO  
 Age/ Gender : 36 Y / Female

Department : GENERAL  
 Doctor :  
 Registration No :  
 Qualification :

Consultation Timing: 09:08

Height : 152	Weight : 53.6	BMI :	Waist Circum :
Temp :	Pulse :	Resp :	B.P : 90/60

General Examination /  
 Allergies History

Clinical Diagnosis & Management Plan

of Cough -  
 since months.

o/c - Acute - Angina

10L - Karyogithi

Adh

- 1.) T. Montair LC 500 x 7d.
- 2.) T. Cepodem 100 x 5d.  
 dosing
- 3.) Salt water gargle.
- 4.) T. Pantakid 100 x 7d.  
 DSR

Follow up date :

after 5 day.

Doctor Signature

**Apollo Clinic**  
 # 23, 1st Floor,  
 Kalidasa Road, Mysore - 02  
 Ph : 0821-4006040/41

Date : 22-03-2024  
 MR NO : CMYS.0000060155  
 Name : Mrs. ANIMA BORO  
 Age/ Gender : 36 Y / Female

Department : GENERAL  
 Doctor :  
 Registration No :  
 Qualification :

Consultation Timing: 09:08

Height : 152	Weight : 53.6	BMI :	Waist Circum :
Temp :	Pulse :	Resp :	B.P : 90/60

General Examination /  
 Allergies History

Clinical Diagnosis & Management Plan

FH - thalassemia  
 minor + .

FH - Dent .

mlt 7 hrs .

Pt I-Us  
 - boy - 7y  
 A.H.

ole breasts @

us h → small rt wall  
 fibroid 1.4x1cm

adv: - regular walk / yoga .

- low fat / low fat diet

- avoid sunbath .

- reassurance

- follow up .

Follow up date :

*B. Anandani*  
 Doctor Signature

**Apollo Clinic**  
 # 23, 1st Floor,  
 Kallidasa Road, Mysore - 02  
 Ph : 0821-4006040/41

Date : 22-03-2024  
MR NO : CMYS.0000060155

Department : GENERAL Dietetics  
Doctor : Archana. P.

Name : Mrs. ANIMA BORO  
Age/ Gender : 36 Y / Female

Registration No :  
Qualification : M.Sc Nutrition & Dietetics  
PhD

Consultation Timing: 09:08

Height: 152	Weight: 53.6	BMI: 22.8 <sup>Iron - 50ug</sup>	Waist Circum:
Temp:	Pulse:	Resp:	B.P: 90/60

General Examination /  
Allergies History  
Hb - 10.3

Clinical Diagnosis & Management Plan

- Advised Balanced diet with fiber & Iron rich foods.
- \*Include Iron rich foods like dark green leafy vegetables [Amarnath, drumstick leaves, palak, beetroot, pomegranate and other vegetables with vitamin - c rich foods [for better absorption of Iron].
- Cooling oil - 1/2 liter/person/month. Use combination of oil like mustard oil, ground nut oil, Sesame oil, coconut oil, Olive & Rice bran oil. But do not mix the oils.
- Avoid bakery products, chate, deep fried foods.

Follow up date :

Doctor Signature

- Regular physical activity. Exercise is must.
- Drink 12 - 14 big glasses of water/day.

**Apollo Clinic**  
# 23, 1st Floor,  
Kalidasa Road, Mysore - 02  
Ph : 0821-4006040/41

Date : 22-03-2024  
MR NO : CMYS.0000060155  
Name : Mrs. ANIMA BORO  
Age/ Gender : 36 Y / Female

Department : GENERAL  
Doctor :  
Registration No :  
Qualification :

Consultation Timing: 09:08

Height: 152	Weight: 53.6	BMI:	Waist Circum:
Temp: 98	Pulse: 90/min	Resp: 20/min	B.P: 90/60

General Examination /  
Allergies History

NO -

Clinical Diagnosis & Management Plan

Wearing. corrected Spectacle.

No fresh complaints.

Not on regular Rx

No H/O T2DM / HTN.

vision

(R)

(L)

Far

NG

NG

Near

corrected spectacle.

colour

Not affected

Follow up date :

Doctor Signature

**Apollo Clinic**  
# 23, 1st Floor,  
Kalidasa Road, Mysore - 02  
Ph : 0821-4006040/41

- Laser correction

- Regular check-up-

Date : 22-03-2024 Department : GENERAL Dental  
 MR NO : CMYS.0000060155 Doctor :  
 Name : Mrs. ANIMA BORO Registration No :  
 Age/ Gender : 36 Y / Female Qualification :

Consultation Timing: 09:08

Height : 152	Weight : 53.6	BMI :	Waist Circum :
Temp :	Pulse :	Resp :	B.P : 90/60

General Examination /  
Allergies History

Clinical Diagnosis & Management Plan

O/E

6/6 missing

Adv. - Replacement

Catt, Sttt

Adv. - oral prophylaxis

7 Restoration

Adv. - X-ray Fluorby Treatment

*[Signature]*

Follow up date :

Doctor *[Signature]*  
**Apollo Clinic**  
 # 23, 1st Floor,  
 Kalidasa Road, Mysore - 02  
 Ph : 0821-4006040/41

**Informed Consent/Declaration For Test Exclusion**

Patient Name: Alina Boro Age: 36 F

UHID Number: 60155

Please tick and sign the relevant part

I certify that I will skip view (ppb) Test from my own.

No refund is provided for the above excluded test and i have been informed about the same.

Patient signature Alina Boro Date 22-03-2024

Witness signature: [Signature] Date: 22-03-2024

Apollo Clinic  
# 23, 1st Floor,  
Kasturba Road, Mysore - 02  
Ph : 0821-4006040/41



**Informed Consent/Declaration For Test Exclusion**

Patient Name: Mrs. Arima Boro Age: 36yrs

UHID Number: 60155

Please tick and sign the relevant part

I certify that I will skip LBC after 10 days Test from my own.

No refund is provided for the above excluded test and i have been informed about the same.

Patient signature *Arima Boro* Date 22/3/24

Witness signature: *Sree* Date: 22/3/24

**Apollo Clinic**  
# 23, 1st Floor,  
Kalidasa Road, Mysore - 02  
Ph : 0821-4006040/41

Patient Name	: Mrs. ANIMA BORO	Age	: 36 Y F
UHID	: CMYS.0000060155	OP Visit No	: CMYSOPV123706
Reported on	: 22-03-2024 16:51	Printed on	: 22-03-2024 16:52
Adm/Consult Doctor	:	Ref Doctor	: SELF

**DEPARTMENT OF RADIOLOGY**

**X-RAY CHEST PA**

Both lung fields and hila are normal .  
No obvious active pleuro-parenchymal lesion seen .  
Both costophrenic and cardiophrenic angles are clear .  
Both diaphragms are normal in position and contour .  
Thoracic wall and soft tissues appear normal.

**IMPRESSION :NORMAL STUDY .**

Printed on:22-03-2024 16:51

---End of the Report---

  
**Dr. CHETAN HOLEPPAGOL**  
**MBBS, DNB(RADIO DIAGNOSIS)**

Radiology

**Apollo Health and Lifestyle Limited**

(CIN : U85110TG2000PLC115819)

Regd Office : 110-63/62, Ashoka Raghupathi Chambers, 5th Floor, Begumpet, Hyderabad, Telangana - 500 016

Ph. No: 040 4904 7777 Fax No: 4904 7744 | Email ID: enquiry@apollohl.com | www.apollohl.com

APOLLO CLINICS NETWORK KARNATAKA

Bangalore (Basavanagudi) | Bellandur | Electronic City | Fraser Town | HSR Layout | Indira Nagar | JP Nagar | Kundalahalli |  
Koramangala (Banjara Road) | Mysore (VV Mohalla)

Online appointments: www.apolloclinic.com

TO BOOK AN APPOINTMENT

 **1860 500 7788**

Patient Name: Mrs. Anima Boro	Date : 22.03.2024	Referring Doctor: DR Self
Age / Sex: 36Yrs/Female	UHID No : 60155	Location : OP
<b>ULTRASONOGRAPHY- ABDOMEN &amp; PELVIS</b>		

**LIVER:** It is normal in size and echotexture. No focal lesions seen. IHBR are not dilated. CBD and Portal vein are normal.

**GALL BLADDER:** It is contracted.

**SPLEEN:** It is normal in size, outline and echopattern. No e/o focal lesions.

**PANCREAS:** It is normal.

**RIGHT KIDNEY:** It measures 9.7x4.1 cm with parenchymal thickness of 1.4 cm. It is normal in size, outline and echotexture. No e/o calculus or hydronephrosis seen.

**LEFT KIDNEY:** It measures 11.9x4.3cm with parenchymal thickness of 1.6 cm. It is normal in size, outline and echotexture. No e/o calculus or hydronephrosis seen.

**URINARY BLADDER:** It is well distended. The UB wall is normal. No calculi seen.

**UTERUS:** It is anteverted and measures 9.3x3.4x4.4 cm with ET=4 mm. It is normal in size, outline and echotexture. **Small posterior wall intramural fibroid measuring 1.4x1.0cm is seen.**


**Rt. OVARY:** It measures 3.2x1.6cm. It is normal. No mass lesion seen.

**Lt. OVARY:** It measures 3.1x1.6cm. It is normal. No mass lesion seen.

**OTHERS:** No e/o free fluid in the abdomen. No e/o lymphadenopathy. No e/o gut wall thickening. No mass lesion seen in the abdomen.

**IMPRESSION:**

**SMALL POSTERIOR WALL INTRAMURAL UTERINE FIBROID.**

  
Dr. Chetan H, DNB  
Consultant Radiologist.

**Apollo Health and Lifestyle Limited**

(CIN: U85110TG2000PLC115819)

Regd. Office: 1-10-60-62, Ashoka Raghupathi Chambers, 5th Floor, Begumpet, Hyderabad, Telangana - 500 016

Ph. No: (040) 4904 7777 Fax No: 4904 7744 | Email ID: enquiry@apollohi.com | www.apollohi.com

**APOLLO CLINICS NETWORK KARNATAKA**

Bangalore: Basavanagudi | Brindavanur | Electronic City | Fraser Town | MSR Layout | Indira Nagar | JP Nagar | Kundalahalli |  
Koramangala | Sarjapur Road | Mysore (VV Mohalla)

Online appointments: www.apolloclinic.com

TO BOOK AN APPOINTMENT

 **1860 500 7788**



Patient's Name : Mrs. Anima Bore

Date : 22.03.2024

Age & sex : 36 Yrs /Female

UHID No : 60155

Measurements

AO : 2.20 cm  
LA : 2.58 cm

RV : 1.68 cm  
LVIDd : 4.10 cm  
LVIDs : 2.73 cm  
IVSd : 0.92 cm  
IVSs : 1.20 cm  
PWd : 0.98 cm  
PWs : 1.29 cm  
EF : 62.0 %  
FS : 33.0 %

Doppler

MV	TV	AV	PV
E: 0.93 m/s	E 0.58 m/s	V max 1.30 m/s	V max 0.91 m/s
A: 0.46 m/s	A 0.32 m/s		
MR Nil	TR Nil	AR Nil	PR Nil

**Dr. C. B. MESHAVAMURTHY MD, DM, DNB**

ICPV: U85110TG2000PLC115819  
**CONSULTANT CARDIOLOGIST** | Apollo Clinic, Begumpet, Hyderabad, Telangana - 500 014  
Ph. No: 041 4934 7777 | Fax No: 4904 7744 | Email ID: enquiry@apollohospitals.com | www.apollohospitals.com

APOLLO CLINICS NETWORK KARNATAKA

Bangalore | Basavanagudi | Bellandur | Electronic City | Frayser Town | HSR Layout | Indira Nagar | JP Nagar | Kundalahalli |  
Koramangala | Marjapur Road | Mysore | VV Mohalla

Online appointments: www.apolloclinic.com

TO BOOK AN APPOINTMENT

**1860 500 7788**

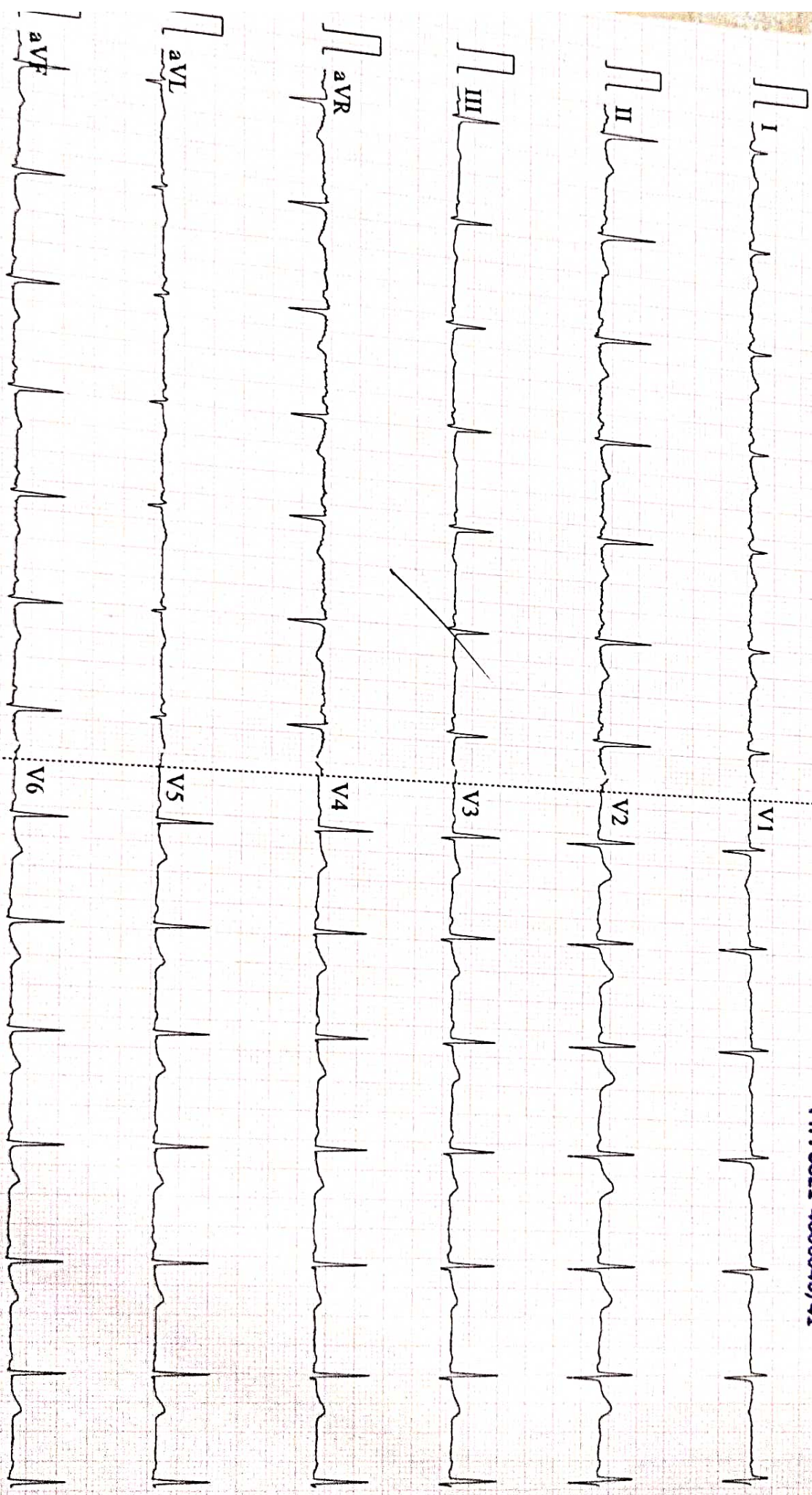
ID: 60155  
MRS ANIMA BORO  
Female 36Years  
152cm 53kg 90/60 mmHg

22-03-2024 11:01:55 AM

Diagnosis Information:

Unconfirmed Report.

**Apollo Clinic**  
# 23, 1st Floor,  
Kallidasa Road, Mysore - 02  
Ph : 0821-4006040/41



45Hz AC50 25mm/s 10mm/mV 2\*5.0s 80 CARDIART 8 D V1.43 Glasgow V28.6.0 APOLLO CLINIC MYSURU