



CID : 2408912785  
Name : MRS.MONA RANE  
Age / Gender : 49 Years / Female  
Consulting Dr. : -  
Reg. Location : Kandivali East (Main Centre)

Collected : 29-Mar-2024 / 08:34  
Reported : 29-Mar-2024 / 10:46

Use a QR Code Scanner  
Application To Scan the Code

**MEDIWHEEL FULL BODY HEALTH CHECKUP FEMALE ABOVE 40/2D ECHO**

**CBC (Complete Blood Count), Blood**

PARAMETER	RESULTS	BIOLOGICAL REF RANGE	METHOD
<b><u>RBC PARAMETERS</u></b>			
Haemoglobin	13.8	12.0-15.0 g/dL	Spectrophotometric
RBC	5.41	3.8-4.8 mil/cmm	Elect. Impedance
PCV	41.6	36-46 %	Measured
MCV	77	80-100 fl	Calculated
MCH	25.4	27-32 pg	Calculated
MCHC	33.1	31.5-34.5 g/dL	Calculated
RDW	15.4	11.6-14.0 %	Calculated
<b><u>WBC PARAMETERS</u></b>			
WBC Total Count	4690	4000-10000 /cmm	Elect. Impedance
<b><u>WBC DIFFERENTIAL AND ABSOLUTE COUNTS</u></b>			
Lymphocytes	33.0	20-40 %	
Absolute Lymphocytes	1547.7	1000-3000 /cmm	Calculated
Monocytes	6.7	2-10 %	
Absolute Monocytes	314.2	200-1000 /cmm	Calculated
Neutrophils	57.9	40-80 %	
Absolute Neutrophils	2715.5	2000-7000 /cmm	Calculated
Eosinophils	2.0	1-6 %	
Absolute Eosinophils	93.8	20-500 /cmm	Calculated
Basophils	0.4	0.1-2 %	
Absolute Basophils	18.8	20-100 /cmm	Calculated
Immature Leukocytes	-		
WBC Differential Count by Absorbance & Impedance method/Microscopy.			
<b><u>PLATELET PARAMETERS</u></b>			
Platelet Count	314000	150000-400000 /cmm	Elect. Impedance
MPV	7.8	6-11 fl	Calculated
PDW	13.0	11-18 %	Calculated
<b><u>RBC MORPHOLOGY</u></b>			
Hypochromia	Mild		
Microcytosis	Occasional		



Use a QR Code Scanner  
Application To Scan the Code

**CID** : 2408912785  
**Name** : MRS.MONA RANE  
**Age / Gender** : 49 Years / Female  
**Consulting Dr.** : -  
**Reg. Location** : Kandivali East (Main Centre)

**Collected** : 29-Mar-2024 / 08:34  
**Reported** : 29-Mar-2024 / 10:52

Macrocytosis -  
Anisocytosis -  
Poikilocytosis -  
Polychromasia -  
Target Cells -  
Basophilic Stippling -  
Normoblasts -  
Others -  
WBC MORPHOLOGY -  
PLATELET MORPHOLOGY -  
COMMENT -

Specimen: EDTA Whole Blood

ESR, EDTA WB-ESR                      18                      2-20 mm at 1 hr.                      Sedimentation

**Clinical Significance:** The erythrocyte sedimentation rate (ESR), also called a sedimentation rate is the rate red blood cells sediment in a period of time.

**Interpretation:**

Factors that increase ESR: Old age, Pregnancy, Anemia

Factors that decrease ESR: Extreme leukocytosis, Polycythemia, Red cell abnormalities- Sickle cell disease

**Limitations:**

- It is a non-specific measure of inflammation.
- The use of the ESR as a screening test in asymptomatic persons is limited by its low sensitivity and specificity.

**Reflex Test:** C-Reactive Protein (CRP) is the recommended test in acute inflammatory conditions.

**Reference:**

- Pack Insert
- Brigden ML. Clinical utility of the erythrocyte sedimentation rate. American family physician. 1999 Oct 1;60(5):1443-50.

\*Sample processed at SUBURBAN DIAGNOSTICS (INDIA) PVT. LTD Borivali Lab, Borivali West

\*\*\* End Of Report \*\*\*



*J Thakker*

**Dr. JYOT THAKKER**  
**M.D. (PATH), DPB**  
**Pathologist & AVP( Medical Services)**



CID : 2408912785  
Name : MRS.MONA RANE  
Age / Gender : 49 Years / Female  
Consulting Dr. : -  
Reg. Location : Kandivali East (Main Centre)

Collected : 29-Mar-2024 / 08:34  
Reported : 29-Mar-2024 / 20:51

Use a QR Code Scanner  
Application To Scan the Code

**MEDIWHEEL FULL BODY HEALTH CHECKUP FEMALE ABOVE 40/2D ECHO**

PARAMETER	RESULTS	BIOLOGICAL REF RANGE	METHOD
GLUCOSE (SUGAR) FASTING, Fluoride Plasma	99.4	Non-Diabetic: < 100 mg/dl Impaired Fasting Glucose: 100-125 mg/dl Diabetic: >/= 126 mg/dl	Hexokinase
GLUCOSE (SUGAR) PP, Fluoride Plasma PP/R	111.7	Non-Diabetic: < 140 mg/dl Impaired Glucose Tolerance: 140-199 mg/dl Diabetic: >/= 200 mg/dl	Hexokinase
Urine Sugar (Fasting)	+	Absent	
Urine Ketones (Fasting)	Absent	Absent	

\*Sample processed at SUBURBAN DIAGNOSTICS (INDIA) PVT. LTD Borivali Lab, Borivali West  
\*\*\* End Of Report \*\*\*



*Bmhasakar*

**Dr.KETAKI MHASKAR**  
M.D. (PATH)  
Pathologist



CID : 2408912785  
Name : MRS.MONA RANE  
Age / Gender : 49 Years / Female  
Consulting Dr. : -  
Reg. Location : Kandivali East (Main Centre)

Use a QR Code Scanner  
Application To Scan the Code  
Collected : 29-Mar-2024 / 08:34  
Reported : 29-Mar-2024 / 12:21

**MEDIWHEEL FULL BODY HEALTH CHECKUP FEMALE ABOVE 40/2D ECHO  
KIDNEY FUNCTION TESTS**

PARAMETER	RESULTS	BIOLOGICAL REF RANGE	METHOD
BLOOD UREA, Serum	21.5	12.8-42.8 mg/dl	Kinetic
BUN, Serum	10.0	6-20 mg/dl	Calculated
CREATININE, Serum	0.78	0.51-0.95 mg/dl	Enzymatic
eGFR, Serum	93	(ml/min/1.73sqm) Normal or High: Above 90 Mild decrease: 60-89 Mild to moderate decrease: 45-59 Moderate to severe decrease: 30-44 Severe decrease: 15-29 Kidney failure: <15	Calculated

Note: eGFR estimation is calculated using 2021 CKD-EPI GFR equation w.e.f 16-08-2023

TOTAL PROTEINS, Serum	7.8	6.4-8.3 g/dL	Biuret
ALBUMIN, Serum	4.6	3.5-5.2 g/dL	BCG
GLOBULIN, Serum	3.2	2.3-3.5 g/dL	Calculated
A/G RATIO, Serum	1.4	1 - 2	Calculated
URIC ACID, Serum	4.2	2.4-5.7 mg/dl	Enzymatic
PHOSPHORUS, Serum	4.1	2.7-4.5 mg/dl	Molybdate UV
CALCIUM, Serum	9.8	8.6-10.0 mg/dl	N-BAPTA
SODIUM, Serum	141	135-148 mmol/l	ISE
POTASSIUM, Serum	5.1	3.5-5.3 mmol/l	ISE
CHLORIDE, Serum	106	98-107 mmol/l	ISE

\*Sample processed at SUBURBAN DIAGNOSTICS (INDIA) PVT. LTD Borivali Lab, Borivali West  
\*\*\* End Of Report \*\*\*



*Bmhasakar*

**Dr.KETAKI MHASKAR**  
M.D. (PATH)  
Pathologist



CID : 2408912785  
Name : MRS.MONA RANE  
Age / Gender : 49 Years / Female  
Consulting Dr. : -  
Reg. Location : Kandivali East (Main Centre)

Use a QR Code Scanner Application To Scan the Code  
Collected : 29-Mar-2024 / 08:34  
Reported : 29-Mar-2024 / 11:45

**MEDIWHEEL FULL BODY HEALTH CHECKUP FEMALE ABOVE 40/2D ECHO**  
**GLYCOSYLATED HEMOGLOBIN (HbA1c)**

PARAMETER	RESULTS	BIOLOGICAL REF RANGE	METHOD
Glycosylated Hemoglobin (HbA1c), EDTA WB - CC	6.1	Non-Diabetic Level: < 5.7 % Prediabetic Level: 5.7-6.4 % Diabetic Level: >= 6.5 %	HPLC
Estimated Average Glucose (eAG), EDTA WB - CC	128.4	mg/dl	Calculated

**Intended use:**

- In patients who are meeting treatment goals, HbA1c test should be performed at least 2 times a year
- In patients whose therapy has changed or who are not meeting glycemic goals, it should be performed quarterly
- For microvascular disease prevention, the HbA1C goal for non pregnant adults in general is Less than 7%.

**Clinical Significance:**

- HbA1c, Glycosylated hemoglobin or glycated hemoglobin, is hemoglobin with glucose molecule attached to it.
- The HbA1c test evaluates the average amount of glucose in the blood over the last 2 to 3 months by measuring the percentage of glycosylated hemoglobin in the blood.

**Test Interpretation:**

- The HbA1c test evaluates the average amount of glucose in the blood over the last 2 to 3 months by measuring the percentage of Glycosylated hemoglobin in the blood.
- HbA1c test may be used to screen for and diagnose diabetes or risk of developing diabetes.
- To monitor compliance and long term blood glucose level control in patients with diabetes.
- Index of diabetic control, predicting development and progression of diabetic micro vascular complications.

**Factors affecting HbA1c results:**

**Increased in:** High fetal hemoglobin, Chronic renal failure, Iron deficiency anemia, Splenectomy, Increased serum triglycerides, Alcohol ingestion, Lead/opiate poisoning and Salicylate treatment.

**Decreased in:** Shortened RBC lifespan (Hemolytic anemia, blood loss), following transfusions, pregnancy, ingestion of large amount of Vitamin E or Vitamin C and Hemoglobinopathies

**Reflex tests:** Blood glucose levels, CGM (Continuous Glucose monitoring)

**References:** ADA recommendations, AACC, Wallach's interpretation of diagnostic tests 10th edition.

\*Sample processed at SUBURBAN DIAGNOSTICS (INDIA) PVT. LTD Borivali Lab, Borivali West

\*\*\* End Of Report \*\*\*



*J Thakker*

**Dr. JYOT THAKKER**  
M.D. (PATH), DPB  
Pathologist & AVP( Medical Services)



CID : 2408912785  
Name : MRS.MONA RANE  
Age / Gender : 49 Years / Female  
Consulting Dr. : -  
Reg. Location : Kandivali East (Main Centre)

Collected : 29-Mar-2024 / 08:34  
Reported : 29-Mar-2024 / 20:02

Use a QR Code Scanner  
Application To Scan the Code

**MEDIWHEEL FULL BODY HEALTH CHECKUP FEMALE ABOVE 40/2D ECHO**  
**URINE EXAMINATION REPORT**

<u>PARAMETER</u>	<u>RESULTS</u>	<u>BIOLOGICAL REF RANGE</u>	<u>METHOD</u>
<b><u>PHYSICAL EXAMINATION</u></b>			
Color	Pale yellow	Pale Yellow	-
Reaction (pH)	6.5	4.5 - 8.0	Chemical Indicator
Specific Gravity	1.005	1.001-1.030	Chemical Indicator
Transparency	Clear	Clear	-
Volume (ml)	30	-	-
<b><u>CHEMICAL EXAMINATION</u></b>			
Proteins	Absent	Absent	pH Indicator
Glucose	1+	Absent	GOD-POD
Ketones	Absent	Absent	Legals Test
Blood	Absent	Absent	Peroxidase
Bilirubin	Absent	Absent	Diazonium Salt
Urobilinogen	Normal	Normal	Diazonium Salt
Nitrite	Absent	Absent	Griess Test
<b><u>MICROSCOPIC EXAMINATION</u></b>			
Leukocytes(Pus cells)/hpf	2-3	0-5/hpf	
Red Blood Cells / hpf	Absent	0-2/hpf	
Epithelial Cells / hpf	1-2		
Casts	Absent	Absent	
Crystals	Absent	Absent	
Amorphous debris	Absent	Absent	
Bacteria / hpf	6-8	Less than 20/hpf	
Others	-		

Result rechecked  
Kindly correlate clinically.



Use a QR Code Scanner  
Application To Scan the Code

CID : 2408912785  
Name : MRS.MONA RANE  
Age / Gender : 49 Years / Female  
Consulting Dr. : -  
Reg. Location : Kandivali East (Main Centre)

Collected : 29-Mar-2024 / 08:34  
Reported : 29-Mar-2024 / 20:02

**Interpretation:** The concentration values of Chemical analytes corresponding to the grading given in the report are as follows:

- Protein ( 1+ = 25 mg/dl , 2+ =75 mg/dl , 3+ = 150 mg/dl , 4+ = 500 mg/dl )
- Glucose(1+ = 50 mg/dl , 2+ =100 mg/dl , 3+ =300 mg/dl ,4+ =1000 mg/dl )
- Ketone (1+ =5 mg/dl , 2+ = 15 mg/dl , 3+= 50 mg/dl , 4+ = 150 mg/dl )

Reference: Pack inert

\*Sample processed at SUBURBAN DIAGNOSTICS (INDIA) PVT. LTD Borivali Lab, Borivali West  
\*\*\* End Of Report \*\*\*



*Bmhasakar*

**Dr.KETAKI MHASKAR**  
**M.D. (PATH)**  
**Pathologist**



CID : 2408912785  
Name : MRS.MONA RANE  
Age / Gender : 49 Years / Female  
Consulting Dr. : -  
Reg. Location : Kandivali East (Main Centre)

Collected : 29-Mar-2024 / 08:34  
Reported : 29-Mar-2024 / 14:46

Use a QR Code Scanner  
Application To Scan the Code

**MEDIWHEEL FULL BODY HEALTH CHECKUP FEMALE ABOVE 40/2D ECHO**  
**BLOOD GROUPING & Rh TYPING**

<u>PARAMETER</u>	<u>RESULTS</u>
ABO GROUP	A
Rh TYPING	Positive

NOTE: Test performed by automated Erythrocytes magnetized technology (EMT) which is more sensitive than conventional methods.

Specimen: EDTA Whole Blood and/or serum

**Clinical significance:**

ABO system is most important of all blood group in transfusion medicine

**Limitations:**

- ABO blood group of new born is performed only by cell (forward) grouping because allo antibodies in cord blood are of maternal origin.
- Since A & B antigens are not fully developed at birth, both Anti-A & Anti-B antibodies appear after the first 4 to 6 months of life. As a result, weaker reactions may occur with red cells of newborns than of adults.
- Confirmation of newborn's blood group is indicated when A & B antigen expression and the isoagglutinins are fully developed at 2 to 4 years of age & remains constant throughout life.
- Cord blood is contaminated with Wharton's jelly that causes red cell aggregation leading to false positive result
- The Hh blood group also known as Oh or Bombay blood group is rare blood group type. The term Bombay is used to refer the phenotype that lacks normal expression of ABH antigens because of inheritance of hh genotype.

**References:**

1. Denise M Harmening, Modern Blood Banking and Transfusion Practices- 6th Edition 2012. F.A. Davis company. Philadelphia
2. AABB technical manual

\*Sample processed at SUBURBAN DIAGNOSTICS (INDIA) PVT. LTD SDRL, Vidyavihar Lab

\*\*\* End Of Report \*\*\*



*Dr. Vrushi Shroff*

**Dr.VRUSHALI SHROFF**  
**M.D.(PATH)**  
**Pathologist**





CID : 2408912785  
Name : MRS.MONA RANE  
Age / Gender : 49 Years / Female  
Consulting Dr. : -  
Reg. Location : Kandivali East (Main Centre)

Use a QR Code Scanner Application To Scan the Code  
Collected : 29-Mar-2024 / 08:34  
Reported : 29-Mar-2024 / 12:21

**MEDIWHEEL FULL BODY HEALTH CHECKUP FEMALE ABOVE 40/2D ECHO**  
**LIPID PROFILE**

PARAMETER	RESULTS	BIOLOGICAL REF RANGE	METHOD
CHOLESTEROL, Serum	198.9	Desirable: <200 mg/dl Borderline High: 200-239mg/dl High: >/=240 mg/dl	CHOD-POD
TRIGLYCERIDES, Serum	76.9	Normal: <150 mg/dl Borderline-high: 150 - 199 mg/dl High: 200 - 499 mg/dl Very high:>/=500 mg/dl	GPO-POD
HDL CHOLESTEROL, Serum	45.4	Desirable: >60 mg/dl Borderline: 40 - 60 mg/dl Low (High risk): <40 mg/dl	Homogeneous enzymatic colorimetric assay
NON HDL CHOLESTEROL, Serum	153.5	Desirable: <130 mg/dl Borderline-high:130 - 159 mg/dl High:160 - 189 mg/dl Very high: >/=190 mg/dl	Calculated
LDL CHOLESTEROL, Serum	139.0	Optimal: <100 mg/dl Near Optimal: 100 - 129 mg/dl Borderline High: 130 - 159 mg/dl High: 160 - 189 mg/dl Very High: >/= 190 mg/dl	Calculated
VLDL CHOLESTEROL, Serum	14.5	< /= 30 mg/dl	Calculated
CHOL / HDL CHOL RATIO, Serum	4.4	0-4.5 Ratio	Calculated
LDL CHOL / HDL CHOL RATIO, Serum	3.1	0-3.5 Ratio	Calculated

\*Sample processed at SUBURBAN DIAGNOSTICS (INDIA) PVT. LTD Borivali Lab, Borivali West  
\*\*\* End Of Report \*\*\*



*Bmhasakar*

**Dr.KETAKI MHASKAR**  
M.D. (PATH)  
Pathologist



CID : 2408912785  
Name : MRS.MONA RANE  
Age / Gender : 49 Years / Female  
Consulting Dr. : -  
Reg. Location : Kandivali East (Main Centre)

Use a QR Code Scanner Application To Scan the Code  
Collected : 29-Mar-2024 / 08:34  
Reported : 29-Mar-2024 / 11:02

**MEDIWHEEL FULL BODY HEALTH CHECKUP FEMALE ABOVE 40/2D ECHO**  
**THYROID FUNCTION TESTS**

<u>PARAMETER</u>	<u>RESULTS</u>	<u>BIOLOGICAL REF RANGE</u>	<u>METHOD</u>
Free T3, Serum	4.4	3.5-6.5 pmol/L	ECLIA
Free T4, Serum	15.9	11.5-22.7 pmol/L First Trimester:9.0-24.7 Second Trimester:6.4-20.59 Third Trimester:6.4-20.59	ECLIA
sensitiveTSH, Serum	3.38	0.35-5.5 microIU/ml First Trimester:0.1-2.5 Second Trimester:0.2-3.0 Third Trimester:0.3-3.0	ECLIA



CID : 2408912785  
Name : MRS.MONA RANE  
Age / Gender : 49 Years / Female  
Consulting Dr. : -  
Reg. Location : Kandivali East (Main Centre)

Use a QR Code Scanner  
Application To Scan the Code  
Collected : 29-Mar-2024 / 08:34  
Reported : 29-Mar-2024 / 11:02

**Interpretation:**

A thyroid panel is used to evaluate thyroid function and/or help diagnose various thyroid disorders.

**Clinical Significance:**

- 1)TSH Values between high abnormal upto15 microIU/ml should be correlated clinically or repeat the test with new sample as physiological factors can give falsely high TSH.
- 2)TSH values may be trasiently altered becuae of non thyroidal illness like severe infections,liver disease, renal and heart severe burns, trauma and surgery etc.

TSH	FT4 / T4	FT3 / T3	Interpretation
High	Normal	Normal	Subclinical hypothyroidism, poor compliance with thyroxine, drugs like amiodarone, Recovery phase of non-thyroidal illness, TSH Resistance.
High	Low	Low	Hypothyroidism, Autoimmune thyroiditis, post radio iodine Rx, post thyroidectomy, Anti thyroid drugs, tyrosine kinase inhibitors & amiodarone, amyloid deposits in thyroid, thyroid tumors & congenital hypothyroidism.
Low	High	High	Hyperthyroidism, Graves disease, toxic multinodular goiter, toxic adenoma, excess iodine or thyroxine intake, pregnancy related (hyperemesis gravidarum, hydatiform mole)
Low	Normal	Normal	Subclinical Hyperthyroidism, recent Rx for Hyperthyroidism, drugs like steroids & dopamine), Non thyroidal illness.
Low	Low	Low	Central Hypothyroidism, Non Thyroidal Illness, Recent Rx for Hyperthyroidism.
High	High	High	Interfering anti TPO antibodies, Drug interference: Amiodarone, Heparin, Beta Blockers, steroids & anti epileptics.

**Diurnal Variation:**TSH follows a diurnal rhythm and is at maximum between 2 am and 4 am , and is at a minimum between 6 pm and 10 pm. The variation is on the order of 50 to 206%. Biological variation:19.7%(with in subject variation)

**Reflex Tests:**Anti thyroid Antibodies,USG Thyroid ,TSH receptor Antibody. Thyroglobulin, Calcitonin

**Limitations:**

1. Samples should not be taken from patients receiving therapy with high biotin doses (i.e. >5 mg/day) until atleast 8 hours following the last biotin administration.
2. Patient samples may contain heterophilic antibodies that could react in immunoassays to give falsely elevated or depressed results. this assay is designed to minimize interference from heterophilic antibodies.

**Reference:**

- 1.O.koulouri et al. / Best Practice and Research clinical Endocrinology and Metabolism 27(2013)
- 2.Interpretation of the thyroid function tests, Dayan et al. THE LANCET . Vol 357
- 3.Tietz ,Text Book of Clinical Chemistry and Molecular Biology -5th Edition
- 4.Biological Variation:From principles to Practice-Callum G Fraser (AACC Press)

\*Sample processed at SUBURBAN DIAGNOSTICS (INDIA) PVT. LTD Borivali Lab, Borivali West

\*\*\* End Of Report \*\*\*



*Bmhasakar*

**Dr.KETAKI MHASKAR**  
**M.D. (PATH)**  
**Pathologist**



CID : 2408912785  
Name : MRS.MONA RANE  
Age / Gender : 49 Years / Female  
Consulting Dr. : -  
Reg. Location : Kandivali East (Main Centre)

Collected : 29-Mar-2024 / 08:34  
Reported : 29-Mar-2024 / 11:58

Use a QR Code Scanner  
Application To Scan the Code

**MEDIWHEEL FULL BODY HEALTH CHECKUP FEMALE ABOVE 40/2D ECHO**  
**LIVER FUNCTION TESTS**

<u>PARAMETER</u>	<u>RESULTS</u>	<u>BIOLOGICAL REF RANGE</u>	<u>METHOD</u>
BILIRUBIN (TOTAL), Serum	0.34	0.1-1.2 mg/dl	Colorimetric
BILIRUBIN (DIRECT), Serum	0.13	0-0.3 mg/dl	Diazo
BILIRUBIN (INDIRECT), Serum	0.21	0.1-1.0 mg/dl	Calculated
TOTAL PROTEINS, Serum	7.8	6.4-8.3 g/dL	Biuret
ALBUMIN, Serum	4.6	3.5-5.2 g/dL	BCG
GLOBULIN, Serum	3.2	2.3-3.5 g/dL	Calculated
A/G RATIO, Serum	1.4	1 - 2	Calculated
SGOT (AST), Serum	21.2	5-32 U/L	NADH (w/o P-5-P)
SGPT (ALT), Serum	13.0	5-33 U/L	NADH (w/o P-5-P)
GAMMA GT, Serum	15.5	3-40 U/L	Enzymatic
ALKALINE PHOSPHATASE, Serum	85.3	35-105 U/L	Colorimetric

\*Sample processed at SUBURBAN DIAGNOSTICS (INDIA) PVT. LTD Borivali Lab, Borivali West  
\*\*\* End Of Report \*\*\*



*Bmhasakar*


**Dr.KETAKI MHASKAR**  
**M.D. (PATH)**  
**Pathologist**



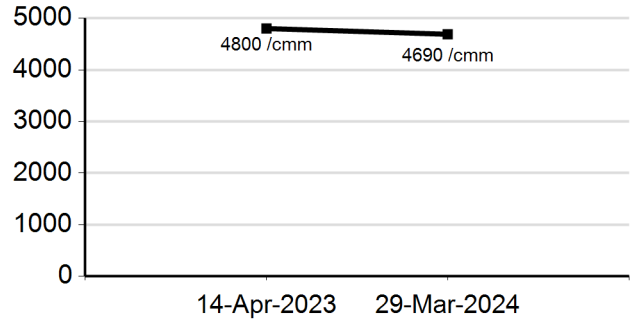
Use a QR Code Scanner Application To Scan the Code

CID : 2408912785  
Name : MRS.MONA RANE  
Age / Gender : 49 Years / Female  
Consulting Dr. : -  
Reg. Location : Kandivali East (Main Centre)

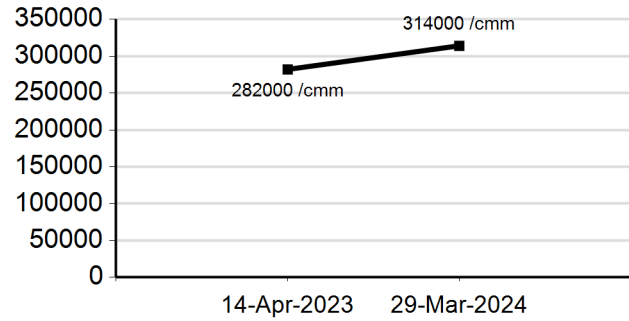
**Haemoglobin**



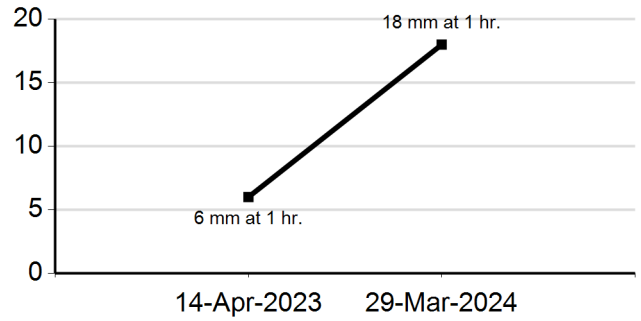
**WBC Total Count**



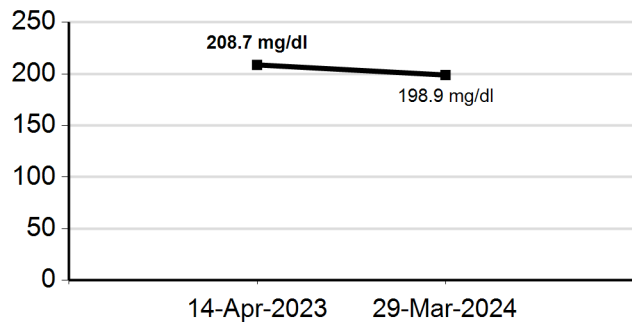
**Platelet Count**



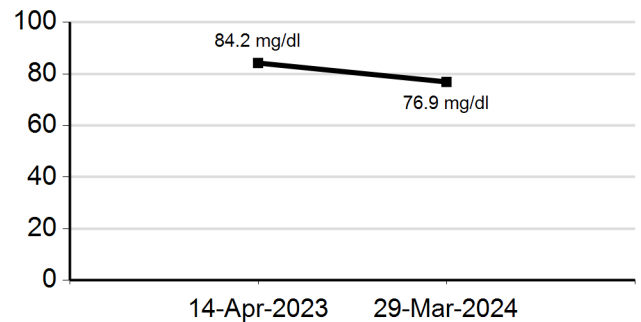
**ESR**



**CHOLESTEROL**



**TRIGLYCERIDES**

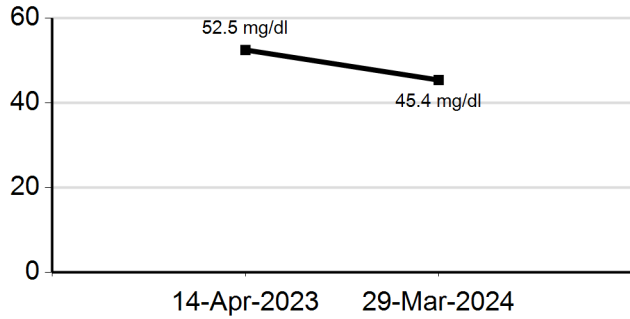




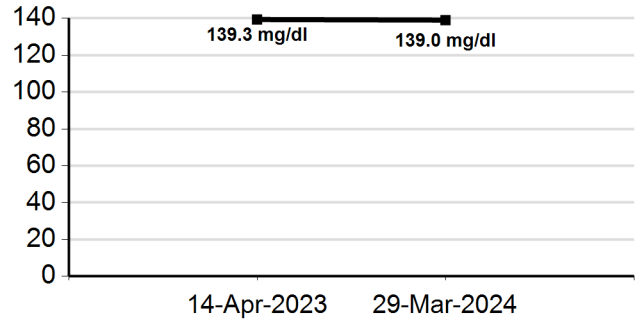
Use a QR Code Scanner Application To Scan the Code

**CID** : 2408912785  
**Name** : MRS.MONA RANE  
**Age / Gender** : 49 Years / Female  
**Consulting Dr.** : -  
**Reg. Location** : Kandivali East (Main Centre)

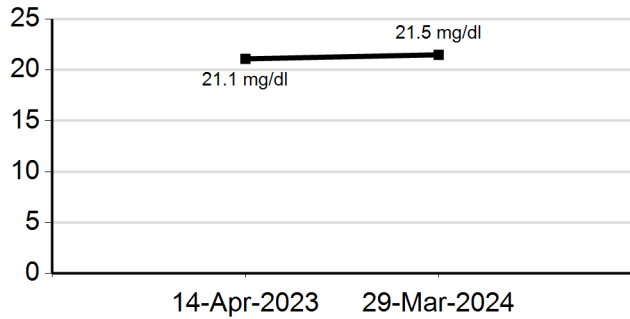
**HDL CHOLESTEROL**



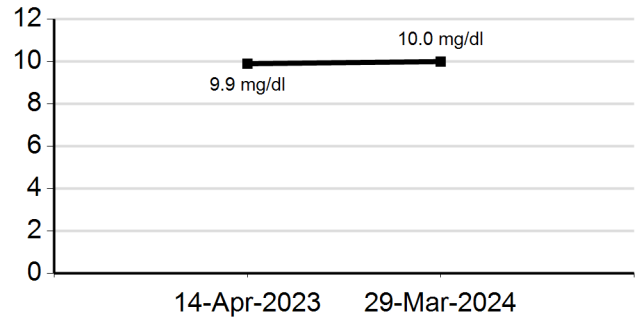
**LDL CHOLESTEROL**



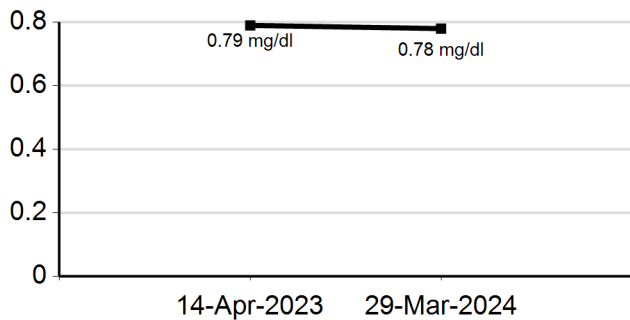
**BLOOD UREA**



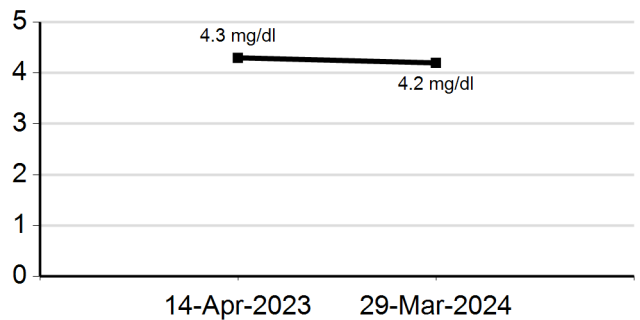
**BUN**



**CREATININE**



**URIC ACID**






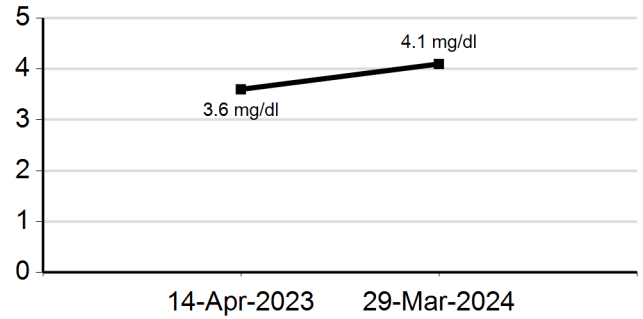
Use a QR Code Scanner Application To Scan the Code

**CID** : 2408912785  
**Name** : MRS.MONA RANE  
**Age / Gender** : 49 Years / Female  
**Consulting Dr.** : -  
**Reg. Location** : Kandivali East (Main Centre)


**CALCIUM**



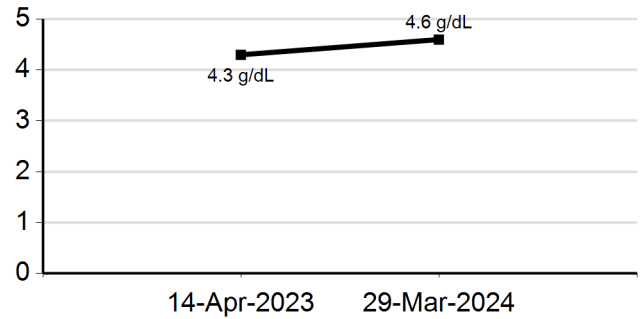
**PHOSPHORUS**



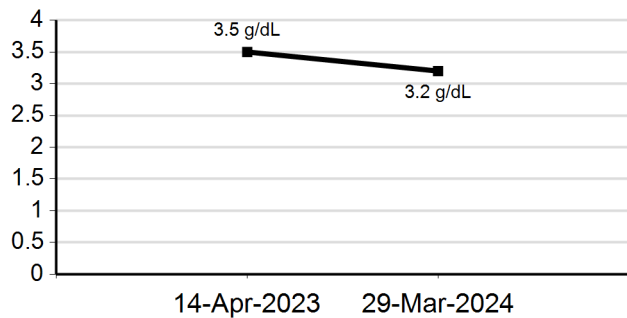
**TOTAL PROTEINS**



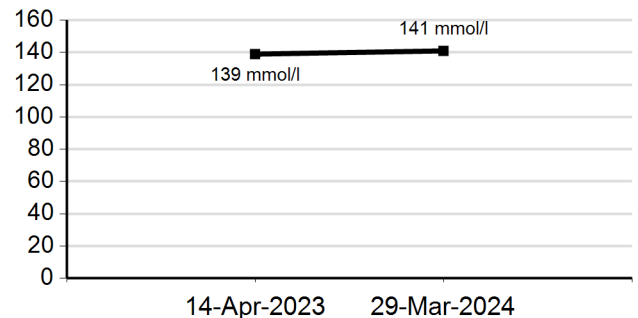
**ALBUMIN**



**GLOBULIN**



**SODIUM**

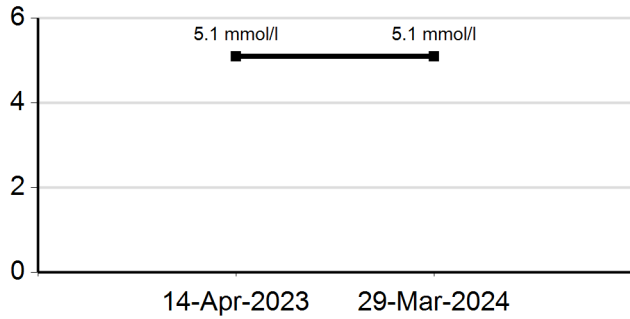




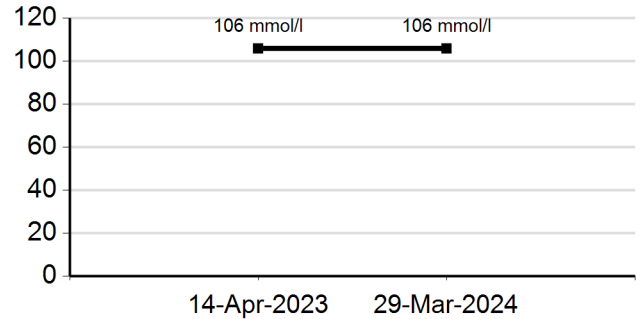
Use a QR Code Scanner Application To Scan the Code

CID : 2408912785  
 Name : MRS.MONA RANE  
 Age / Gender : 49 Years / Female  
 Consulting Dr. : -  
 Reg. Location : Kandivali East (Main Centre)

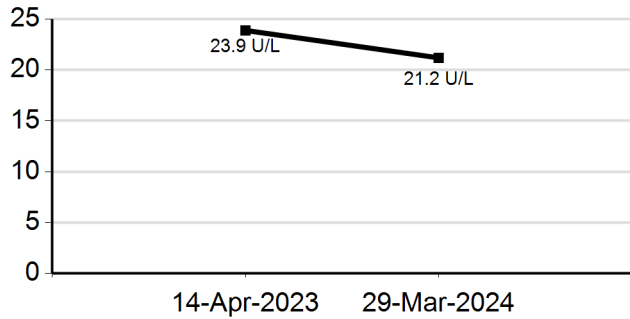
**POTASSIUM**



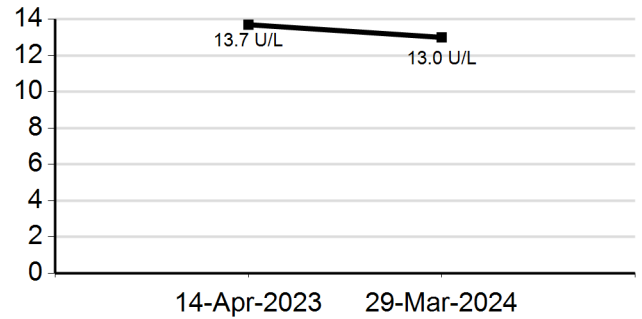
**CHLORIDE**



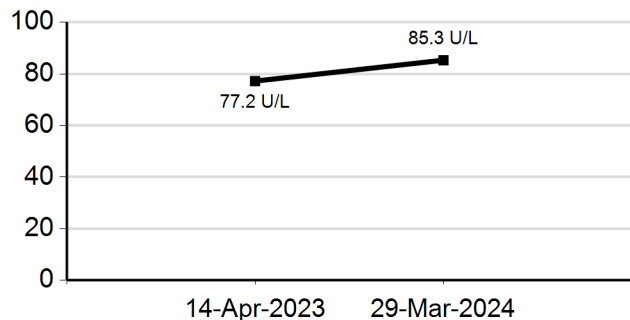
**SGOT (AST)**



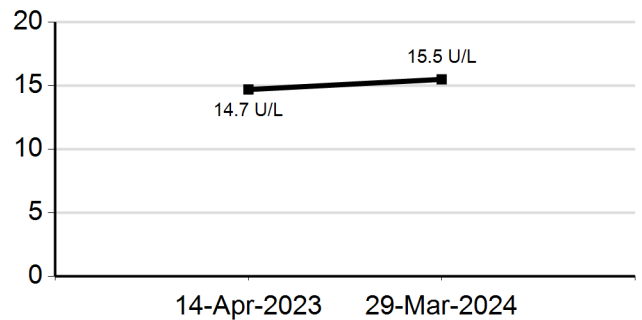
**SGPT (ALT)**



**ALKALINE PHOSPHATASE**



**GAMMA GT**



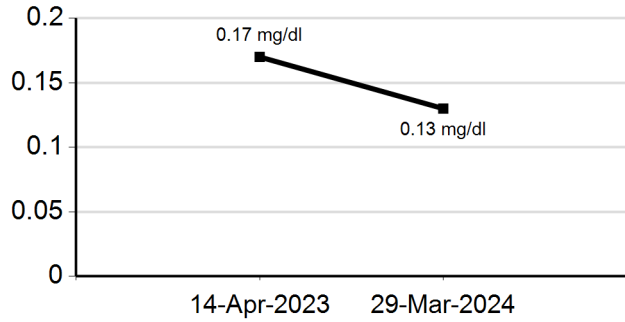




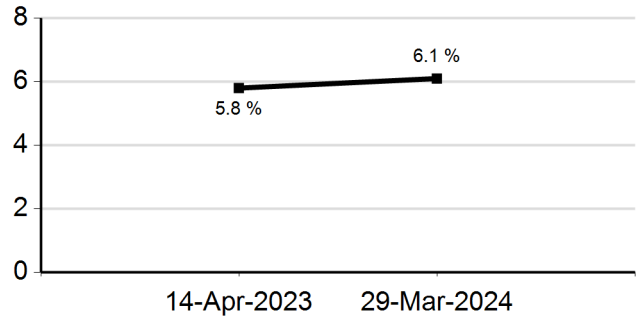
Use a QR Code Scanner Application To Scan the Code

CID : 2408912785  
 Name : MRS.MONA RANE  
 Age / Gender : 49 Years / Female  
 Consulting Dr. : -  
 Reg. Location : Kandivali East (Main Centre)

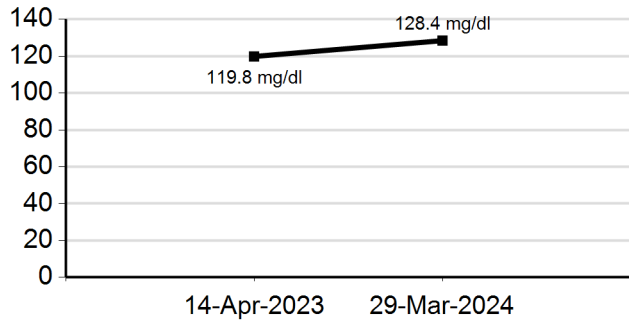
**BILIRUBIN (DIRECT)**



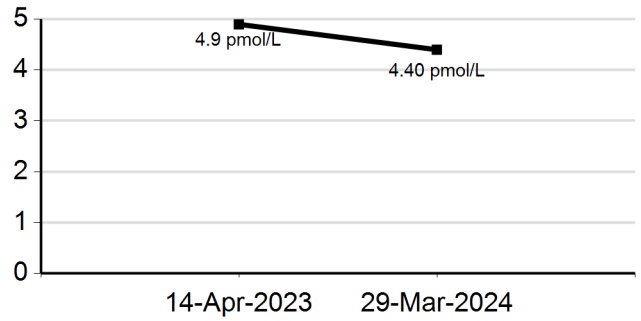
**Glycosylated Hemoglobin (HbA1c)**



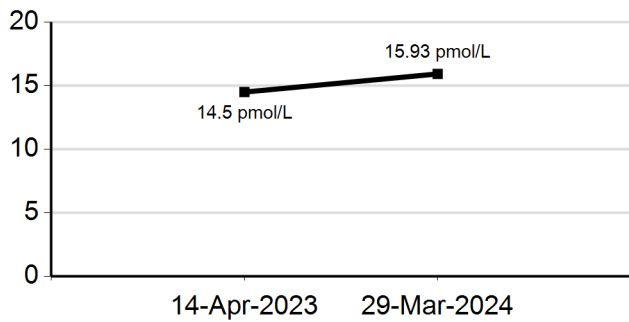
**Estimated Average Glucose (eAG)**



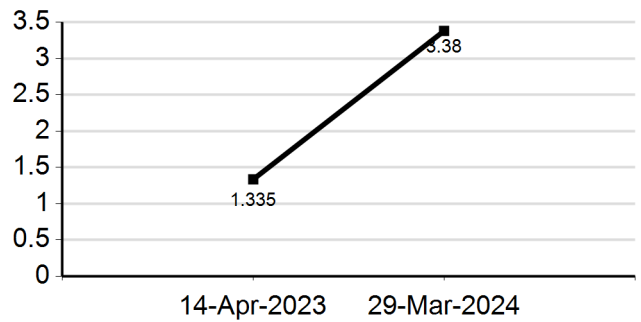
**Free T3**



**Free T4**



**sensitiveTSH**



Authenticity Check



Use a QR Code Scanner  
Application To Scan the Code

**CID** : 2408912785  
**Name** : Mrs MONA RANE  
**Age / Sex** : 49 Years/Female  
**Ref. Dr** :  
**Reg. Location** : Kandivali East Main Centre

**Reg. Date** : 29-Mar-2024  
**Reported** : 29-Mar-2024 / 17:30

## MAMMOGRAPHY

### X RAY MAMMOGRAPHY:

**Both mammograms have been performed with Cranio-Caudal and Medio-Lateral Oblique views**

Dense fibroglandular pattern is noted in both breasts limiting optimal evaluation (Type D).

No evidence of any speculated high density mass lesion / focal asymmetric density / retraction / clusters of microcalcification is seen.

No abnormal skin thickening is seen.

### SONOMAMMOGRAPHY:

Both breasts reveal normal parenchymal echotexture.

No focal solid or cystic mass lesion is seen.

No ductal dilatation is seen.

Bilateral axillae appear normal.

**Click here to view images** <http://3.111.232.119/iRISViewer/NeoradViewer?AccessionNo=2024032908311379>

REGD. OFFICE: Dr. Lal PathLabs Ltd., Block E, Sector-18, Rohini, New Delhi - 110085. | CIN No.: L74899DL1995PLC065388

MUMBAI OFFICE: Suburban Diagnostics (India) Pvt. Ltd., Aston, 2<sup>nd</sup> Floor, Sundervan Complex, Above Mercedes Showroom, Andheri West, Mumbai - 400053.

WEST REFERENCE LABORATORY: Shop No. 9, 101 to 105, Skyline Wealth Space Building, Near Dmart, Premier Road, Vidyavihar West, Mumbai - 400086.

HEALTHLINE: 022-6170-0000 | E-MAIL: customerservice@suburbandiagnosics.com | WEBSITE: www.suburbandiagnosics.com

Authenticity Check



Use a QR Code Scanner  
Application To Scan the Code

CID : 2408912785  
Name : Mrs MONA RANE  
Age / Sex : 49 Years/Female  
Ref. Dr :  
Reg. Location : Kandivali East Main Centre

Reg. Date : 29-Mar-2024  
Reported : 29-Mar-2024 / 17:30

**IMPRESSION:**

**Normal Mammography and Sonomammography of both breasts.**

**ACR BIRADS Category- I (Negative).**

Follow-up Mammography after 1 year is suggested. Please bring all the films for comparison.

**ACR BIRADS CATEGORY**

- I. Negative
- II. Benign.
- III. Probably benign.
- IV. Suspicious / Indeterminate.
- V. Highly Suggestive of malignancy

-----End of Report-----

**DR. SHRIKANT M. BODKE**  
**D.M.R.E., M.B.B.S.**  
**Reg. No. 2006/04/2376**

Note: Investigations have their limitations. Solitary radiological investigations never confirm the final diagnosis. They only help in diagnosing the disease in correlation to clinical symptoms and other related tests. USG is known to have inter-observer variations. Further / Follow-up imaging may be needed in some cases for confirmation / exclusion of diagnosis. Patient was explained in detail verbally about the USG findings, USG measurements and its limitations. In case of any typographical error in the report, patient is requested to immediately contact the center for rectification within 7 days post which the center will not be responsible for any rectification. Please interpret accordingly.

Click here to view images <http://3.111.232.119/iRISViewer/NeoradViewer?AccessionNo=2024032908311379>

REGD. OFFICE: Dr. Lal PathLabs Ltd., Block E, Sector-18, Rohini, New Delhi - 110085. | CIN No.: L74899DL1995PLC065388

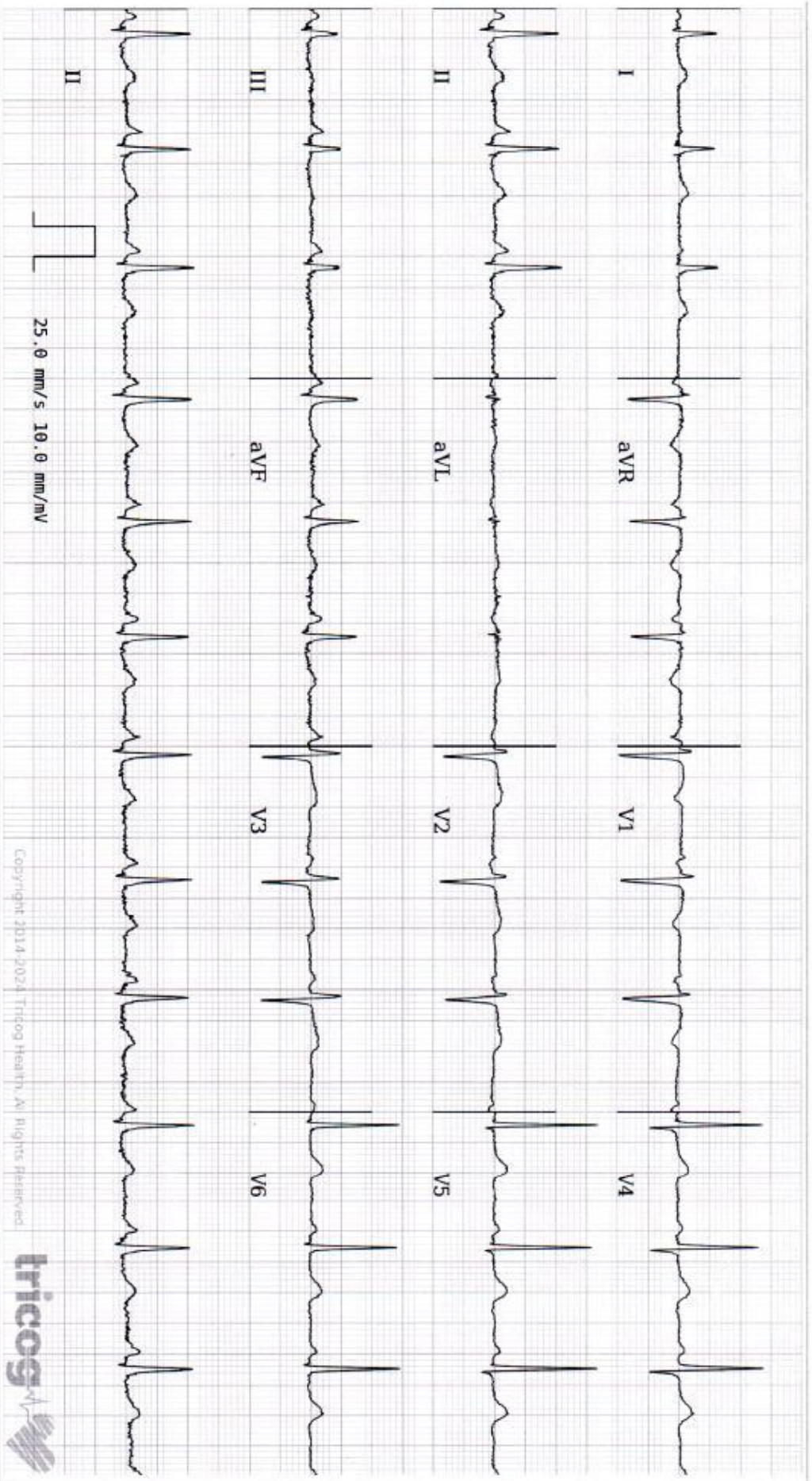
MUMBAI OFFICE: Suburban Diagnostics (India) Pvt. Ltd., Aston, 2<sup>nd</sup> Floor, Sundervan Complex, Above Mercedes Showroom, Andheri West, Mumbai - 400053. Page no 2 of 2

WEST REFERENCE LABORATORY: Shop No. 9, 101 to 105, Skyline Wealth Space Building, Near Dmart, Premier Road, Vidyavihar West, Mumbai - 400086.

HEALTHLINE: 022-6170-0000 | E-MAIL: [customerservice@suburbandiagnosics.com](mailto:customerservice@suburbandiagnosics.com) | WEBSITE: [www.suburbandiagnosics.com](http://www.suburbandiagnosics.com)

Patient Name: MONA RANE  
Patient ID: 2408912785

**SUBURBAN DIAGNOSTICS - KANDIVALI EAST**  
Date and Time: 29th Mar 24 10:41 AM



25.0 mm/s 10.0 mm/mV

Copyright 2014-2024 Tricog Health, A. Rights Reserved



Age **49** NA NA  
years months days

Gender **Female**

Heart Rate **75bpm**

Patient Vitals

BP: 160/90 mmHg

Weight: 61 kg

Height: 165 cm

Pulse: NA

Spo2: NA

Resp: NA

Others:

**Measurements**

QRSD: 84ms

QT: 412ms

QTcB: 460ms

PR: 136ms

P-R-T: 79° 55° 41°

ECG Within Normal Limits: Sinus Rhythm. Please correlate clinically.

REPORTED BY

DR ANHIL PARULEKAR  
MBBS MD MEDICINE, DNB Cardiology  
Cardiologist  
2012082483

Disclaimer: 1) Analysis in this report is based on ECG alone and should be used as an adjunct to clinical history, symptoms, and results of other invasive and non-invasive tests and must be interpreted by a qualified physician. 2) Patient vitals are as entered by the clinician and not derived from the ECG.

Date:- 29/3/2024

CID: 24089/2785

Name:- Mona Rane

Sex/Age: 49/F

**EYE CHECK UP**

Chief complaints: NO

Systemic Diseases: NO

Past history: NO

Unaided Vision:

Aided Vision: C/G N/G C/G N/G

Refraction:

	(Right Eye)				(Left Eye)			
	Sph	Cyl	Axis	Vn	Sph	Cyl	Axis	Vn
Distance								
Near								

Colour Vision: Normal / Abnormal

Remark: ✓

**SUBURBAN DIAGNOSTICS (INDIA) PVT. LTD.**  
Plot No. 3, Aangan,  
Thakur Village, Kandivali (West),  
Mumbai - 400101.  
Tel: 61700000



**CID** : 2408912785  
**Name** : Mrs MONA RANE  
**Age / Sex** : 49 Years/Female  
**Ref. Dr** :  
**Reg. Location** : Kandivali East Main Centre

**Reg. Date** : 29-Mar-2024  
**Reported** : 29-Mar-2024 / 11:41

Use a QR Code Scanner  
Application To Scan the Code

## USG WHOLE ABDOMEN

### LIVER:

The liver is normal in size (14.4 cm) shape and smooth margins. **It shows bright parenchymal echo pattern.** The intra hepatic biliary and portal radical appear normal. No evidence of any intra hepatic cystic or solid lesion seen. The main portal vein measures 10 mm and CBD appears measures 3.2 mm .  
The main portal vein and CBD appears normal.

### GALL BLADDER:

The gall bladder is physiologically distended and appears normal. No evidence of gall stones or mass lesions seen

### PANCREAS:

The pancreas is well visualized and appears normal. No evidence of solid or cystic mass lesion.

### KIDNEYS:

Right kidney measures 9.6 x 3.7 cm. Left kidney measures 10.2 x 4.7 cm.  
Both the kidneys are normal in size shape and echotexture.  
No evidence of any calculus, hydronephrosis or mass lesion seen.

### SPLEEN:

The spleen is normal in size (8.3 cm) and echotexture. No evidence of focal lesion is noted.  
There is no evidence of any lymphadenopathy or ascites.

### URINARY BLADDER:

The urinary bladder is well distended and reveal no intraluminal abnormality.

### UTERUS:

The uterus is anteverted and appears normal. It measures 7.3 x 4.6 x 3.3 cm in size.  
The endometrial thickness is 5 mm.

### OVARIES:

Both the ovaries are well visualized and appears normal.  
There is no evidence of any ovarian or adnexal mass seen.  
Right ovary = 2.2 x 1.5 cm Left ovary = 2.6 x 1.0 cm

Click here to view images <http://3.111.232.119/iRISViewer/NeoradViewer?AccessionNo=2024032908311326>



CID : 2408912785  
Name : Mrs MONA RANE  
Age / Sex : 49 Years/Female  
Ref. Dr :  
Reg. Location : Kandivali East Main Centre

Reg. Date : 29-Mar-2024  
Reported : 29-Mar-2024 / 11:41

Use a QR Code Scanner  
Application To Scan the Code

**IMPRESSION:-**

**GRADE I FATTY LIVER.**

-----End of Report-----

DR. Akash Chhari  
MBBS. MD. Radio-Diagnosis Mumbai  
MMC REG NO - 2011/08/2862

Click here to view images <http://3.111.232.119/iRISViewer/NeoradViewer?AccessionNo=2024032908311326>

Page no 2 of 2

• PATIENT NAME : MRS. MONA RANE	• SEX : FEMALE
• REFERRED BY : ARCOFEMI HEALTHCARE LIMITED	• AGE : 49 YEARS
• CID NO : 2408912785	• DATE : 29/03/2024

**2D & M-MODE ECHOCARDIOGRAM REPORT**  
**COLOR FLOW DOPPLER REPORT**

**ECHO & DOPPLER FINDINGS :**

- No diastolic dysfunction seen at present.
- No regional wall motion abnormality seen at rest at present
- No left ventricular hypertrophy seen.
- All cardiac chambers appear normal in size.
- All cardiac valves show normal structure and physiological function
- No significant stenosis nor regurgitation seen
- No defect seen in the inter ventricular and inter atrial septums.
- No evidence of aneurysm / clots / vegetations/ effusion seen.
- TAPSE and MAPSE measured to 19 mm and 16 mm respectively.
- Mild TR jet. PASP by TR jet measured to 22 mm Hg
- **Visual estimation of LVEF of 60 %.**

**MEASUREMENTS:**

IVS d (mm)	09	Ao (mm)	26
IVS s (mm)	12	LA (mm)	32
LVIDd (mm)	39	EPSS (mm)	01
LVIDs ( mm)	24	EF SLOPE (ml/s)	90
Pwd (mm)	09	MV (mm)	19
Pws (mm)	14		

Conti....2



• PATIENT NAME : MRS. MONA RANE	• SEX : FEMALE
• REFERRED BY : ARCOFEMI HEALTHCARE LIMITED	• AGE : 49 YEARS
• CID NO : 2408912785	• DATE : 29/03/2024

**DOPPLER: Mitral E / A**

Mitral (m/s)	0.8	Aortic (m/s)	1.07
Tricuspid (m/s)	0.7	Pulmonary (m/s)	0.8

**TDI**

Septal e' = 0.1 m/s

Lateral e' = 0.1 m/s

Septal a' = 0.07m/s

Lateral a' = 0.07m/s

Septal s' = 0.06 m/s

Lateral s' = 0.07 m/s

Septal E/e'=08



**Dr. P. Bhatjiwale, M.D**

**PG cert in Clinical Cardiology,**

**Fellowship in 2 D Echo & Doppler Studies**

**Reg. No 68857**

**NOTE :2D ECHO has a poor sensitivity in cases of angina pectoris and does not rule out CAD  
Adv: Please correlate clinically. CAG/ Further cardiac evaluation as clinically indicated.**

-----End of Report-----



CID : 2408912785  
Name : Mrs MONA RANE  
Age / Sex : 49 Years/Female  
Ref. Dr :  
Reg. Location : Kandivali East Main Centre

Reg. Date : 29-Mar-2024  
Reported : 29-Mar-2024 / 14:34

Use a QR Code Scanner  
Application To Scan the Code

### X-RAY CHEST PA VIEW

Both lung fields are clear.  
Both costo-phrenic angles are clear.  
The cardiac size and shape are within normal limits.  
The domes of diaphragm are normal in position and outlines.  
The skeleton under review appears normal.

#### **IMPRESSION:**

**NO SIGNIFICANT ABNORMALITY IS DETECTED.**

-----End of Report-----

DR. Akash Chhari  
MBBS. MD. Radio-Diagnosis Mumbai  
MMC REG NO - 2011/08/2862

Click here to view images <http://3.111.232.119/iRISViewer/NeoradViewer?AccessionNo=2024032908311389>

Page no 1 of 1

Name : *Mana Rave*

Age / Gender *49 / F*

Dr. :

Date : *- 29/3/24*

**GYNAEC EXAMINATION REPORTS**

**PERSONAL HISTORY**

CHIEF COMPLAINTS :

*NO*

MARITAL STATUS :

*married*

MENSTRUAL HISTORY :

(i) MENARCHE :

*@ age - 13 yrs.*

(ii) PRESENT MENSTRUAL HISTORY :

*Irregular : 6 mths.*

(iii) PAST MENSTRUAL HISTORY :

*1 mth ago*

OBSTETRIC HISTORY :

*G, P, L, A, O*  
*- NO*

PAST HISTORY :

PREVIOUS SURGERIES :

*USG. lap w. apt excision*

ALLERGIES :

*NO*

FAMILY HISTORY :

*Parents DM, HTN*

DRUG HISTORY :

*NO*

BOWEL HABITS :

BLADDER HABITS :

*(P)*

**Dr. Jagruti Dhale**  
MBBS  
Consultant Physician  
Reg.No.69548

Name : \_\_\_\_\_ Age / Gender \_\_\_\_\_  
Dr. : \_\_\_\_\_ Date : \_\_\_\_\_

**GYNAEC EXAMINATION REPORTS**

GENERAL EXAMINATION

TEMPERATURE : (98)

RS :

PULSE : 72/100

CVs : / NAD

BP :

Breasts :

Per Abdomen : - n/a, scan of USG healthy

Per vaginal :

PLS skip  
(if not willing)

RECOMMENDATIONS

ADVISE :

  
**Dr. Jagruti Dhale**  
MBBS  
Consultant Physician  
Reg.No.69548