

- 63 . Age not entered, assumed to be 50 years old for purpose of ECG interpretation
- . Sinus rhythm.....normal P axis, V-rate 50- 99
- 149 . Nonspecific T abnormalities, inferior leads.....T <-0.10mV, II III aVF

84
395
405

IS--

57

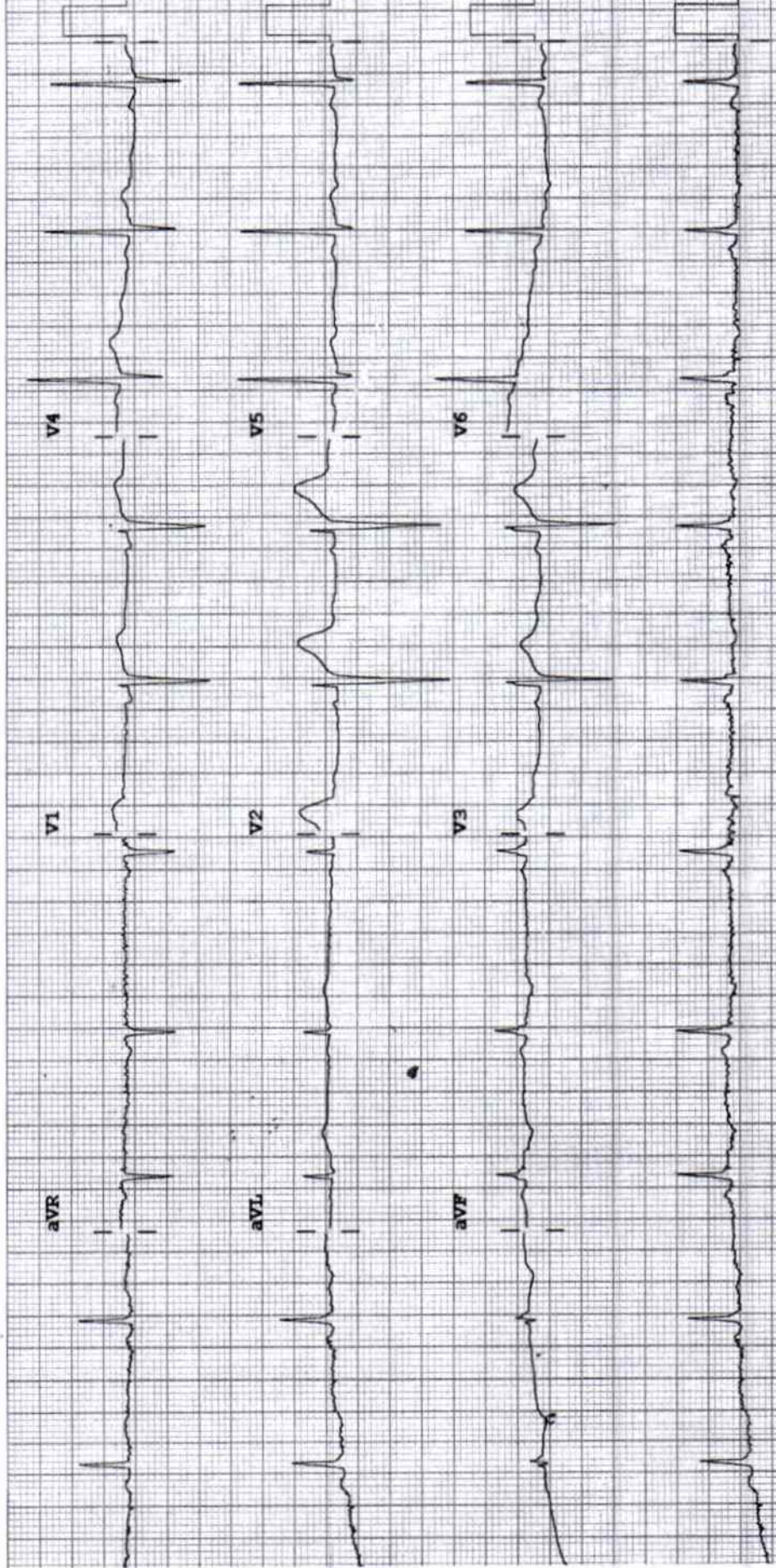
38

-48

ad; Standard Placement

- ABNORMAL ECG -

Unconfirmed Diagnosis



Speed: 25 mm/sec Limb: 10 mm/mV Chest: 10.0 mm/mV

F 50- 0.15-100 Hz

PH100B CL P?

2D ECHOCARDIOGRAPHY & COLOUR DOPPLER STUDY

Name : Mr. Surendra Gharpure

Age / Sex : Yrs. / Male

Done By : Dr. Nitin Tiwari

Date : April 01, 2024

OPD

UHID : 354075

Comments :

Sector echo done in plax, psax, apical 4 & 5 chambers, subcostal view shows:

Normal morphology of mitral, aortic, tricuspid and pulmonary valves.

The left atrium, left ventricle, right atrium and right ventricle are normal in dimension and morphology. There is no regional wall motion abnormality of left ventricle at rest. The left ventricular systolic function is **good**. The global left ventricular ejection fraction is 64 %

The IAS and IVS are intact.

The pericardium is normal. There is no pericardial effusion

There is no clot or vegetation seen.

CW, PW and Colour Doppler: Transmitral flow is suggestive of normal left ventricular diastolic function present. The flow pattern across other cardiac valves is normal. There is no evidence of pulmonary hypertension.

Impression:


Normal cardiac valves and chamber dimensions

No regional wall motion abnormality of left ventricle at rest

Good left ventricular systolic function. LVEF – 64 %

Normal LV diastolic function

No pulmonary hypertension


Dr. Nitin Tiwari
MD, DNB (Med.), DM, DNB (Card.),
MNAMS, MAPSIC
Sr. Interventional Cardiologist

DEPARTMENT OF LABORATORY MEDICINE

BIOCHEMISTRY

Final Report

Patient Name	: MR. SURENDRA GHARPURE	Order Date	: 01/04/2024 08:37 AM
Age / Sex	: 57 Years / Male	Sample Collection	: 01/04/2024 08:52 AM
UHID	: WHN2.0000354075	Receiving Date Time	: 01/04/2024 08:52 AM
Approval Date Time	: 01/04/2024 10:37 AM	Report Date	: 01/04/2024 10:13 AM
Primary Consultant	: DR. WOCKHARDT DOCTOR	Specimen	: Serum
Order No.	: 57		
Bill No.	: OCR3/25/0000004		

PARAMETER	METHOD	RESULT	UNIT	B.R.I
Serum Urea	Urease-GLDH	20.7	mg/dL	1-50
Blood Urea Nitrogen	Calculated	9.67	mg/dL	6-20
Creatinine- Serum				
Creatinine	Enzymatic colorimetric	0.94	mg/dL	0.67-1.17
Plasma Glucose				
Plasma Glucose - Fasting.	Enzymatic Hexokinase	104.38	mg/dL	74-109
Urine Sugar Fasting	Double Sequential Enzyme Reaction - GOD/ POD	Absent		
Uric Acid- Serum				
Uric Acid	Enzymatic colorimetric	6.1	mg/dL	3.4-7
Lipid Profile				
Cholesterol	Colorimetric - Cholesterol Oxidase	151.87	mg/dL	0-200
Triglycerides	Enzymatic colorimetric	133.3	mg/dL	0-150
HDL Cholesterol - Direct	Direct Homogenous Enzymatic Colorimetric	41.7		1. No Risk: >65 2. Moderate Risk: 45-65 3. High Risk: <45
LDL-Cholesterol -Direct	Direct Homogenous Enzymatic Colorimetric	83.51	mg/dL	0-100
VLDL Cholesterol	Calculated	26.66	mg/dL	10-35
Chol/HDL Ratio		3.64		1.Low Risk: 3.3-4.4 2.Average Risk: 4.4-7.1 3.Moderate Risk: 7.1-11.0 4.High Risk: >11.0
Liver Function Test (L.F.T.)				
Alkaline Phosphatase	Colorimetric IFCC	47	U/L	40-129
S.G.O.T (AST)	IFCC Without Pyridoxal 5 Phosphate	22.9	U/L	0-40
S.G.P.T (ALT)	IFCC Without Pyridoxal 5 Phosphate	26.9	U/L	0-50
Total Protein (Serum)	Colorimetric - Biuret Method	6.73	g/dL	6.4-8.3
Albumin, BCG	Colorimetric - Bromo-Cresol Green	4.41	g/dL	3.5-5.2
Globulin	Calculated	2.32	g/dL	1.9-3.5
Albumin/Globulin Ratio	Calculated	1.90		0.9-2
Serum Total Bilirubin	Colorimetric Diazo	0.54	mg/dL	0-1.2
Serum Direct Bilirubin	Colorimetric Diazo	0.24	mg/dL	0-0.4
Serum Indirect Bilirubin	Calculated	0.30	mg/dL	0-1

--- END OF REPORT ---

SOHEL KHAN
Verified By


Dr. LAXMI LOKESH
 Consultant Pathologist

DEPARTMENT OF LABORATORY MEDICINE

HEMATOLOGY

Final Report

Patient Name : MR. SURENDRA GHARPURE	Order Date : 01/04/2024 08:37 AM
Age / Sex : 57 Years / Male	Sample Collection : 01/04/2024 08:52 AM
UHID : WHN2.0000354075	Receiving Date Time : 01/04/2024 08:52 AM
Approval Date Time : 01/04/2024 09:51 AM	Report Date : 01/04/2024 09:49 AM
Primary Consultant : DR. WOCKHARDT DOCTOR	Specimen : EDTA Blood
Order No. : 57	
Bill No. : OCR3/25/0000004	

PARAMETER	METHOD	RESULT	UNIT	B.R.I
Complete Blood Count (With ESR)- EDTA Blood				
Haemoglobin	SLS Method	15.8	g%	11-15
Haematocrit	RBC Pulse Height Detection	46.8	%	40 - 50
MCV	Calculated	96.1	fl	83-101
MCH	Calculated	32.4	pg	27-32
MCHC	Calculated	33.8	g/dl	32-35
RBC Count	DC Detection	4.87	Million/ul	4.5-5.5
RDW-CV	Calculated	12.9	%	12-14
WBC Total Count (TLC)	Electrical Impedance	6900	Cells/cumm	4000 - 10000
Neutrophils	Hydrodynamic Focussing And Microscopy	58	%	40-80
Lymphocytes	Hydrodynamic Focussing And Microscopy	32	%	20-40
Monocytes	Hydrodynamic Focussing And Microscopy	08	%	2-10
Eosinophils	Hydrodynamic Focussing And Microscopy	02	%	0-6
Basophils	Hydrodynamic Focussing And Microscopy	00	%	0-2
Platelet Count	Hydrodynamic Focussing DC	291	Thou/Cumm	150-450
PDW	Calculated	10.3	fL	9.0-17
MPV	Calculated	9.2	fl	9.4-12.3
P-LCR	Calculated	18.8	%	13.0-43.0
PCT	Calculated	0.27	%	0.17-0.35
Blood ESR	Westergren Method	3	mm/hr	0-15

--- END OF REPORT ---

JAMILUDDIN SIDDIQUI
Verified By


Dr. LAXMI LOKESH
 Consultant Pathologist
 MDPATH

Partial Reproduction of Report not permitted. This Report Relates to Sample received by Laboratory
 * B. R. I : BIOLOGICAL REFERENCE INTERVAL ** Test not in Scope of Accreditation

DEPARTMENT OF LABORATORY MEDICINE

BIOCHEMISTRY


Final Report

Patient Name	: MR. SURENDRA GHARPURE	Order Date	: 01/04/2024 08:37 AM
Age / Sex	: 57 Years / Male	Sample Collection	: 01/04/2024 08:52 AM
UHID	: WHN2.0000354075	Receiving Date Time	: 01/04/2024 08:52 AM
Approval Date Time	: 01/04/2024 10:37 AM	Report Date	: 01/04/2024 10:17 AM
Primary Consultant	: DR. WOCKHARDT DOCTOR	Specimen	: EDTA Blood
Order No.	: 57		
Bill No.	: OCR3/25/0000004		

PARAMETER	METHOD	RESULT	UNIT	B.R.I
Glycosylated Haemoglobin- EDTA Blood				
Glycosylated Haemoglobin	HPLC	5.2	%	Action required: 7.0-8.0% Good control: 6.5-7.0% Normal control: 4.8-6.4% Poor control: >8.0%
Estimated Mean glucose	Calculated	107.82	mg/dL	

--- END OF REPORT ---

JAMILUDDIN SIDDIQUI
Verified By


Dr. LAXMI LOKESH
 Consultant Pathologist
 MDPATH

Partial Reproduction of Report not permitted This Report Relates to Sample received by Laboratory
 * B.R.I : BIOLOGICAL REFERENCE INTERVAL ** Test not in Scope of Accreditation

DEPARTMENT OF LABORATORY MEDICINE

BIOCHEMISTRY


Final Report

Patient Name : MR. SURENDRA GHARPURE
Age / Sex : 57 Years / Male
UHID : WHN2.0000354075
Approval Date Time : 01/04/2024 11:48 AM
Primary Consultant : DR. WOCKHARDT DOCTOR
Order No. : 57
Bill No. : OCR3/25/0000004
Order Date : 01/04/2024 08:37 AM
Sample Collection : 01/04/2024 11:13 AM
Receiving Date Time : 01/04/2024 11:17 AM
Report Date : 01/04/2024 11:47 AM
Specimen : Plasma

PARAMETER	METHOD	RESULT	UNIT	B.R.I
Plasma Glucose Post Prandial	Enzymatic Hexokinase	144.63	mg/dl	70-140
Urine Sugar Post Prandial	Double Sequential Enzyme Reaction - GOD/ POD	NA		

--- END OF REPORT ---

JAMILUDDIN SIDDIQUI
Verified By


Dr. LAXMI LOKESH
Consultant Pathologist
MDPATH

Partial Reproduction of Report not permitted This Report Relates to Sample received by Laboratory
* B.R.I : BIOLOGICAL REFERENCE INTERVAL ** Test not in Scope of Accreditation

DEPARTMENT OF LABORATORY MEDICINE

IMMUNOLOGY


Final Report

Patient Name	: MR. SURENDRA GHARPURE	Order Date	: 01/04/2024 08:37 AM
Age / Sex	: 57 Years / Male	Sample Collection	: 01/04/2024 08:52 AM
UHID	: WHN2.0000354075	Receiving Date Time	: 01/04/2024 08:52 AM
Approval Date Time	: 01/04/2024 10:37 AM	Report Date	: 01/04/2024 10:12 AM
Primary Consultant	: DR. WOCKHARDT DOCTOR	Specimen	: Serum
Order No.	: 57		
Bill No.	: OCR3/25/0000004		

<u>PARAMETER</u>	<u>METHOD</u>	<u>RESULT</u>	<u>UNIT</u>	<u>B.R.I</u>
Prostate Specific Antigen Total (PSA Total)- Serum				
PSA Total	ECLIA	0.572	ng/mL	0-4
T3 T4 TSH- Serum				
TOTAL T3	ECLIA	98.81	ng/dl	80-200
TOTAL T4	ECLIA	4.64	ug/dl	4.5-11.7
TSH	ECLIA	3.26	μIU/mL	0.27-4.2

--- END OF REPORT ---

JAMILUDDIN SIDDIQUI
Verified By


Dr. LAXMI LOKESH
 Consultant Pathologist
 MDPATH

Partial Reproduction of Report not permitted. This Report Relates to Sample received by Laboratory
 * B.R.I : BIOLOGICAL REFERENCE INTERVAL ** Test not in Scope of Accreditation

DEPARTMENT OF LABORATORY MEDICINE

CLINICAL PATHOLOGY

Final Report

Patient Name	: MR. SURENDRA GHARPURE	Order Date	: 01/04/2024 08:37 AM
Age / Sex	: 57 Years / Male	Sample Collection	: 01/04/2024 08:52 AM
UHID	: WHN2.0000354075	Receiving Date Time	: 01/04/2024 08:52 AM
Approval Date Time	: 01/04/2024 09:55 AM	Report Date	: 01/04/2024 09:54 AM
Primary Consultant	: DR. WOCKHARDT DOCTOR	Specimen	: Urine
Order No.	: 57		
Bill No.	: OCR3/25/0000004		

PARAMETER	METHOD	RESULT	UNIT	B.R.I
Urine Routine				
Physical Examination				
Colour		Pale Yellow		
Appearance		Clear		
Urinalyser (Roche UriSys 1100)				
Specific Gravity		1.020		1.003 - 1.035
Reaction (pH)		5		
Leukocytes, microscopy		neg	/hpf	
Erythrocytes, microscopy		neg	/hpf	
Nitrite, urinalyser		neg		
Protein, urinalyser		neg		
Glucose, urinalyzer		neg		
Ketone, urinalyser		neg		
Urobilinogen urinalyser		neg		
Billirubin uirnalyser		neg		

--- END OF REPORT ---

SOHEL KHAN
Verified By


Dr. LAXMI LOKESH
 Consultant Pathologist
 MDPATH

Partial Reproduction of Report not permitted. This Report Relates to Sample received by Laboratory
 * B.R.I : BIOLOGICAL REFERENCE INTERVAL ** Test not in Scope of Accreditation

DEPARTMENT OF RADIO DIAGNOSTICS

Patient Name : MR. SURENDRA GHARPURE
Age/Sex : 57 Yrs / Male
UHID : WHN2.0000354075
Reporting Date : 01/04/2024 10:52 AM
Bill No. : OCR3/25/0000004
Order Date : 01/04/2024 08:37 AM
Referred by :
Order No. : 10

USG ABDOMEN WITH PELVIS :

Real time sonography of the abdomen and pelvis was performed using the 3.5 MHz transducer.

The liver is normal in size and shows bright echotexture suggesting fatty infiltration. No focal parenchymal lesion noted. Intrahepatic biliary tree and venous radicles are normal.

The portal vein and CBD appear normal in course and calibre.

The gall bladder is normal in size with a normal wall thickness and there are no calculi noted within.

The pancreas is normal in size and echotexture. No evidence of focal lesion or calcification or duct dilatation seen.

The spleen is normal in size and echotexture.

Both kidneys are normal in size, position and echogenicity.

Cortical thickness and corticomedullary differentiation are normal.

No hydronephrosis or calculi noted.

The urinary bladder is normal in contour, capacity and wall thickness. No vesical calculi noted.

The prostate is normal in size and homogenous in echotexture.

There is no evidence of ascites.

Impression :

Grade I fatty infiltration of liver.



DR. VISHAL GAJBHIYE
M.B.B.S., M.D.
CONSULTANT - RADIOLOGIST

DEPARTMENT OF RADIODIAGNOSTICS

Patient Name	: MR. SURENDRA GHARPURE	Order Date	: 01/04/2024 08:37 AM
Age/Sex	: 57 Yrs / Male	Referred by	:
UHID	: WHN2.0000354075	Order No.	: 10
Reporting Date	: 01/04/2024 12:32 PM		
Bill No.	: OCR3/25/0000004		

CHEST X-RAY PA VIEW :

Both lung fields are clear.

The costophrenic angles and domes of diaphragm appear normal.

No hilar or mediastinal lesion seen.

Cardiac silhouette is within normal limits.

Visualised bony thorax and soft tissues appear normal.

Impression:

Normal Chest X-Ray.



DR. VISHAL GAJBHIYE
M.B.B.S., M.D.
CONSULTANT - RADIOLOGIST