

Out Patient Department

Dr. RAJESH PALLAMRAJU BOLLAPRAGADA  
Mbbs, DNB( Internal Medicine)  
CONSULTANT INTERNAL MEDICINE

Tirumala



UMR No	: VZMU70832	Name	: Mr. DEESARI PAVAN KUMAR
Consultation Date	: 29 Mar 2024	Age/Gender	: 30 Year(s) / Male
Valid Upto	:	Mobile No	: 9666658496
Sponsor	: ARCOFEMI HEALTHCARE PVT LTD	Visit Type	: NORMAL

**OP RECORD**

Informant :

I. Initial Assessment :

*Dr. Rajesh (Intern)*

Height	:	cms
Weight	:	kg
BMI	:	kg/m <sup>2</sup>
Temp	:	F
Pulse Rate	:	bpm
Resp. Rate	:	bpm
BP	:	mm of hg
Pain score	:	
Nutritional Statu	:	

II. Provisional Diagnosis :

*Cholelithiasis*

III. Investigations

IV. Treatment

*(9mm)*

*ECG - WNL*

*Adhuc*

*HbA1c - 6.1*

*1. Review after 2 months*

*Fos - 100*

*Lor - 117*

*L FBS  
PPBS  
HbA1c  
Lipid profile*

For Apointments : Mobile No. : 9491759216 (9 AM to 6 PM)

**TIRUMALA MEDICOVER HOSPITALS**

(A Unit of Sahrudaya Health Care Vizianagaram Pvt. Ltd.)

**తిరుమల మెడికవర్ హాస్పిటల్స్**

# 8-24, P.S.R. Complex, Lower Tank Bunk Road,  
VIZIANAGARAM - 535 003, ANDHRA PRADESH.

8-24, పి.ఎస్.ఆర్. కాంప్లెక్స్, లోవర్ ట్యాంక్ బండ్ రోడ్,  
విజయనగరం-535 003, ఆంధ్రప్రదేశ్.

website : www.tirumalahospitals.com

info@medicoverhospitals.in

Dr. S.V.V.VEDHAVATHI  
BDS  
DENTAL SURGEON

Out Patient Department

Tirumala



UMR No : VZMU70832

Consultation Date : 29-Mar-2024

Valid Upto :

Sponsor : ARCOFEMI HEALTHCARE PVT LTD

Name : Mr. DEESARI PAVAN KUMAR

Age/Gender : 30 Year(s) / Male

Mobile No : 9666658496

Visit Type : NORMAL

**OP RECORD**

Informant :

Height	:	cms
Weight	:	kgs
BMI	:	kg/m2
Temp	:	F
Pulse Rate	:	bpm
Resp.Rate	:	bpm
BP	:	mm of hg
Pain score	:	
Natritional Statu	:	

I. Initial Assessment :

ChC - Patient complains of bad  
breath since 6 months.

II. Provisional Diagnosis :

O/E - Stain+, calc

Bleeding on

III. Investigations

IV. Treatment

probing present.

Δ Chronic generalized gingivitis.

Rx plan - Administer oral prophylaxis.

Rx done

Oral prophylaxis done.  
Oral hygiene instructions  
given.

For Apointments : Mobile No. : 9491759216 (9 AM to 6 PM)

**TIRUMALA MEDICOVER HOSPITALS**

(A Unit of Sahrudaya Health Care Vizianagaram Pvt. Ltd.)

తిరుమల మెడికల్ హాస్పిటల్స్

# 8-24, P.S.R. Complex, Lower Tank Bunk Road,  
VIZIANAGARAM - 535 003, ANDHRA PRADESH.

8-24, పి.ఎస్.ఆర్. కాంప్లెక్స్, లోవర్ ట్యాంక్ బండ్ రోడ్,  
విజయనగరం-535 003, ఆంధ్రప్రదేశ్.

website : www.tirumalahospitals.com

info@medicoverhospitals.in

29/3/24

29 Years

PAVAN KUMARR  
Male

29-Mar-24 10:00:15 AM

Rate 81 . Sinus rhythm.....normal P axis, V-rate 50- 99  
 . Probable left atrial enlargement.....P >50ms, <-0.10mV V1  
 . Baseline wander in lead(s) V4

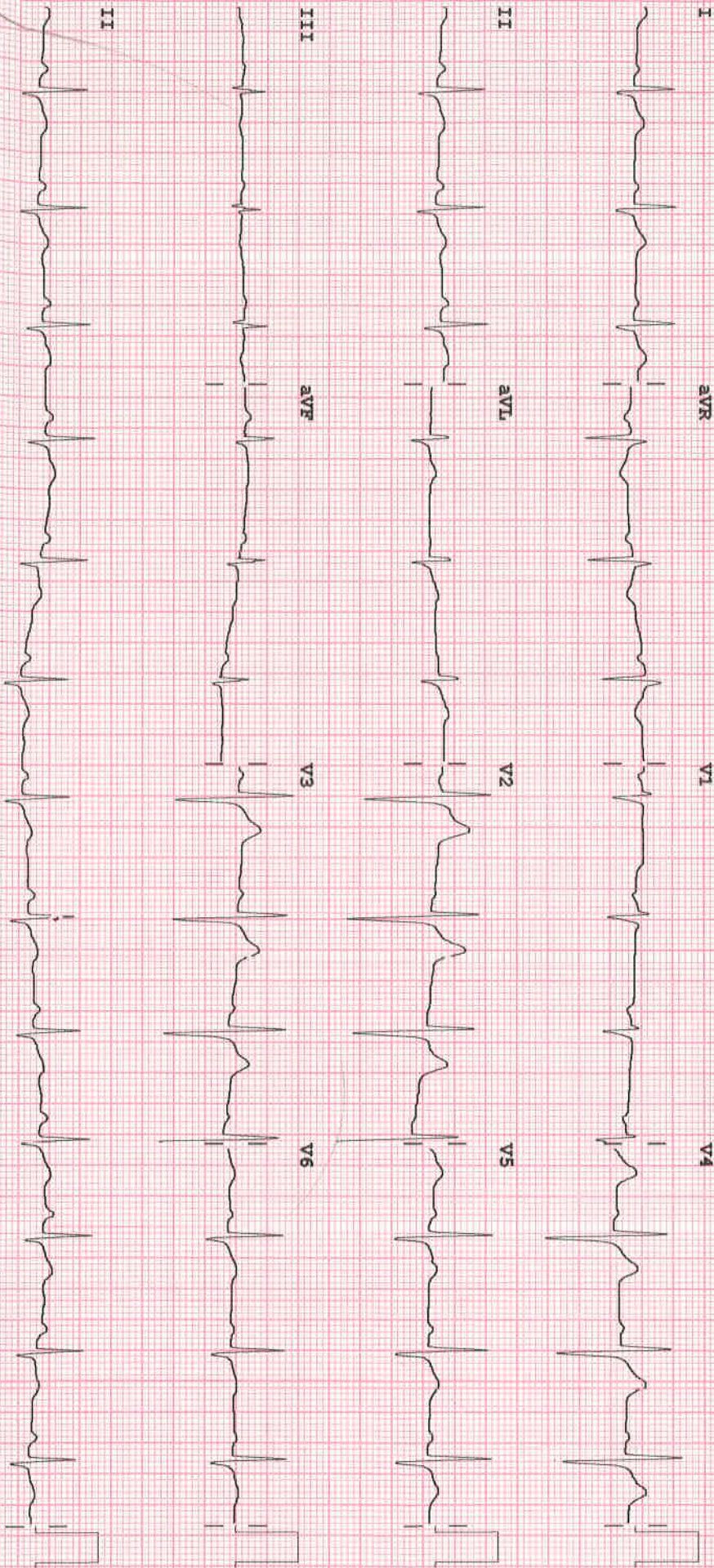
PR 164  
 QRSD 92  
 QT 352  
 QTc 409

--AXIS--  
 P 54  
 QRS 42  
 T 19

- BORDERLINE ECG -

Unconfirmed Diagnosis

12 Lead; Standard Placement



Device:

Speed: 25 mm/sec

Limb: 10 mm/mV

Chest: 10.0 mm/mV

F 50~ 0.15-100 Hz

100B CL

P?

<b>Name</b> : Mr. DEESARI PAVAN KUMAR	<b>Age /Sex</b> : 30 Y(s)/Male
<b>Bill Date</b> : 29-Mar-2024 11:07 AM	<b>UMR No.</b> : VZMU70832
<b>Rec. Dt</b> : 29-Mar-2024 11:23 AM	<b>Bill No.</b> : VZMB95952
<b>Rept. Dt</b> : 29-Mar-2024 01:59 PM	<b>Result No</b> : RES167464
<b>Ref By</b> : Dr.RAJESH PALLAMRAJU BOLLAPRAGADA Mbbs, DNB( I	<b>Passport No.:</b>
<b>Sample Type</b> : Blood	

<u>Parameters</u>	<u>Result</u>	<u>Method</u>
<b>BLOOD GROUPING AND RH</b>		
<b>BLOOD GROUP</b>	: " A "	SLIDE AGGLUTINATION
<b>RH TYPE</b>	: POSITIVE	
<b>ESR</b>	: 10 mm/1st hour	0 - 10 mm/1st hour WESTERGREN`S METHOD
<b>CBP( COMPLETE BLOOD PICTURE)</b>		
<b>HEMOGLOBIN</b>	: 14.9 g/dl	13.0 - 17.0 g/dl
<b>R B C COUNT</b>	: 5.09 10 <sup>6</sup> /μL	4.5 - 5.5 10 <sup>6</sup> /μL
<b>PCV/HCT</b>	: 41.5 %	40 - 50 %
<b>MCV</b>	:* 81 fl	83 - 101 fl
<b>MCH</b>	: 29.3 pg	27 - 32 pg
<b>MCHC</b>	:* 36.0 g/dL	31.5 - 34.5 g/dL
<b>RDW(cv)</b>	: 13.2 %	11.6 - 14.0 %
<b>RDW(sd)</b>	:* 39 μm3	40.0 - 55.0 μm3
<b>WBC</b>		
<b>TC (TOTAL LEUCOCYTE)</b>	: 9.2 10 <sup>3</sup> /μl	4.0 - 11.0 10 <sup>3</sup> /μl
<b>DIFFERENTIAL COUNT</b>		
<b>NEUTROPHILS</b>	: 69 %	40 - 80 %
<b>LYMPHOCYTES</b>	: 23 %	20 - 40 %
<b>MONOCYTES</b>	: 05 %	02 - 10 %
<b>EOSINOPHILS</b>	: 03 %	00 - 06 %
<b>BASOPHILS</b>	: 00 %	00 - 01 %
<b>PLATELET</b>		
<b>PLATELET</b>	: 191 10 <sup>3</sup> /μL	150 - 400 10 <sup>3</sup> /μL
<b>MPV</b>	: 7.7 fl	7.5 - 11.5 fl

\*\*\* End Of Report \*\*\*

Suggested Clinical Correlation \* If necessary, Please discuss

Verified By : 

**Dr. S SIVA JYOTHSNA, MBBS, MD**  
**CONSULTANT PATHOLOGIST**

Test results related only to the item tested.

No part of the report can be reproduced without written permission of the laboratory.

Release Date : 29-Mar-24 1:59:30

**తిరుమల మెడికల్ హాస్పిటల్స్**

**(A UNIT OF SAHRUDAYA HEALTH CARE VIZIANAGARM PVT. LTD.)**

<b>Name</b> : Mr. DEESARI PAVAN KUMAR	<b>Age /Sex</b> : 30 Y(s)/Male
<b>Bill Date</b> : 29-Mar-2024 11:07 AM	<b>UMR No.</b> : VZMU70832
<b>Rec. Dt</b> : 29-Mar-2024 11:23 AM	<b>Bill No.</b> : VZMB95952
<b>Rept. Dt</b> : 29-Mar-2024 01:59 PM	<b>Result No</b> : RES167464
<b>Ref By</b> : Dr.RAJESH PALLAMRAJU BOLLAPRAGADA Mbbs, DNB( I	<b>Passport No:</b>
<b>Sample Type</b> : Blood	

<u>Parameters</u>	<u>Result</u>	<u>Method</u>
<b>BLOOD GROUPING AND RH</b>		
<b>BLOOD GROUP</b>	: " A "	SLIDE AGGLUTINATION
<b>RH TYPE</b>	: POSITIVE	

**BUN(BLOOD UREA NITROGEN)**

BUN (Blood Urea Nitrogen.)	: 11 mg/dL	7.0 - 21.0 mg/dL	Calculatead
----------------------------	------------	------------------	-------------

**HBA1C (GLYCOSYLATED HAEMOGLOBIN)**

HBA1C	: 6.1	Normal : < 5.7% Pre diabetic : 5.7 % - 6.5 % Diabetic : > 6.5 %	HPLC
MPG(Mean Plasma Glucose)	: 139.86	Excellent Control : 90 - 120 mg/dl Good Control : 121 - 150 mg/dl value	Derived from HBA1c
<b>PLBS (POST LUNCH BLOOD</b>	: 135 mg/dL	Norma Range - < 140 mg/dL	Hexokinase

**FBS (FASTING BLOOD GLUCOSE)**

<b>FASTING BLOOD GLUCOSE</b>	: * 101 mg/dL	Normal Range 70 - 99 mg/dL	Hexokinase
------------------------------	---------------	----------------------------	------------

**SERUM CREATININE**

CREATININE	: 0.9 mg/dl	0.5 - 1.4 mg/dl	Method : jaffe
------------	-------------	-----------------	----------------

**BUN / CREATININE RATIO**

BUN (Blood Urea Nitrogen.)	: 11 mg/dL	7.0 - 21.0 mg/dL	Calculatead
SERUM CREATININE	: 0.9 mg/dL	0.5 - 1.4 mg/dL	Alkaline Picrate
<b>BUN / CREATININE RATIO</b>	: 12.2	10 - 20	Calculated
<b>SERUM URIC ACID</b>	: 4.2 mg/dL	3.4 - 7.0 mg/dL	uricase

**TOTAL PROTEIN**

TOTAL PROTEINS	: 7.3 g/dL	6.0 - 8.0 g/dL	Method : Biuret method
----------------	------------	----------------	------------------------

\*\*\* End Of Report \*\*\*

Suggested Clinical Correlation \* If necessary, Please discuss

Verified By :

Dr. S SIVA JYOTHSNA, MBBS, MD

CONSULTANT PATHOLOGIST

తిరుమల మెడికల్ హాస్పిటల్స్

Test results related only to the item tested.

No part of this report can be reproduced without written permission of the laboratory.

(A UNIT OF SAHARJUDAYA HEALTH CARE VIZIANAGARAM PVT. LTD.)

**LABORATORY REPORTS: CLINICAL PATHOLOGY**

<b>Name</b> : Mr. DEESARI PAVAN KUMAR	<b>Age /Sex</b> : 30 Y(s)/Male
<b>Bill Date</b> : 29-Mar-2024 11:07 AM	<b>UMR No.</b> : VZMU70832
<b>Rec. Dt</b> : 29-Mar-2024 11:23 AM	<b>Bill No.</b> : VZMB95952
<b>Rept. Dt</b> : 29-Mar-2024 01:59 PM	<b>Result No</b> : RES167464 / 240303271
<b>Ref By</b> : Dr.RAJESH PALLAMRAJU BOLLAPRAGADA Mbbs, DNB(	<b>Passport No</b> :
<b>Sample Type</b> : Urine	

**CUE(COMPLETE URINE EXAMINATION)**

<u>Parameters</u>	<u>Result</u>	<u>Biological Reference Intervals</u>
<b><u>PHYSICAL EXAMINATION</u></b>		
<b>COLOUR</b>	: PALE YELLOW	PALE YELLOW
<b>APPEARANCE</b>	: CLEAR	CLEAR
<b><u>CHEMICAL EXAMINATION</u></b>		
<b>SPECIFIC GRAVITY</b>	: 1.005	1.000 - 1.030
<i>Dipstick</i>		
<b>PH</b>	: 6.0	5.0 - 8.0
<i>Dipstick</i>		
<b>PROTEIN</b>	: NIL	NIL to +++
<i>Dipstick/Heat coagulation test</i>		
<b>GLUCOSE</b>	: NIL	NIL to ++++
<i>Dipstick/Benedict's test</i>		
<b>UROBILINOGEN</b>	: NIL	NIL to ++++
<i>Dipstick</i>		
<b>KETONE</b>	: NIL	NIL to ++++
<i>Dipstick/Rothera's Nitroprusside test.</i>		
<b>BLOOD</b>	: NIL	NIL to ++++
<i>Dipstick/Microscopy</i>		
<b>BILIRUBIN</b>	: NIL	NIL to ++++
<i>Dipstick/Fouchet's test</i>		
<b>NITRITE</b>	: NEGATIVE	NEGATIVE
<i>Dipstick</i>		
<b>LEUCOCYTES</b>	: NIL	NIL to ++++
<i>Dipstick/Microscopy</i>		
<b><u>MICROSCOPIC EXAMINATION</u></b>		
<b>PUS CELLS</b>	: * 3-5	2 - 3 hpf
<b>RBC</b>	: NIL	NIL - NIL NIL
<b>EPITHELIAL CELLS</b>	: * 0-1	1 - 2 /hpf
<b>CRYSTALS</b>	: NIL	NIL
<b>CASTS</b>	: NIL	NIL
	*** End Of Report ***	

*(Handwritten signature)*

<b>Name</b> : Mr. DEESARI PAVAN KUMAR	<b>Age /Sex</b> : 30 Y(s)/Male
<b>Bill Date</b> : 29-Mar-2024 11:07 AM	<b>UMR No.</b> : VZMU70832
<b>Rec. Dt</b> : 29-Mar-2024 11:23 AM	<b>Bill No.</b> : VZMB95952
<b>Rept. Dt</b> : 29-Mar-2024 01:59 PM	<b>Result No</b> : RES167464
<b>Ref By</b> : Dr.RAJESH PALLAMRAJU BOLLAPRAGADA Mbbs, DNB( I	<b>Passport No:</b>
<b>Sample Type</b> : SERUM	

<u>Parameters</u>	<u>Result</u>	<u>Biological Reference Inte</u>	<u>Method</u>
<b>LIPID PROFILE</b>			
TOTAL CHOLESTEROL	: 176 mg/dL	Desirable : : < 200 mg/dL Borderline High : : 200 - 239 mg/dL High risk : > 240 mg/dL	METHOD : Enzymatic colorimetric
HDL CHOLESTEROL	: 44 mg/dL	Low : : < 40 mg/dL High : : > 60 mg/dL	Homogeneous enzymatic colorimetric
LDL CHOLESTEROL	:* 117 mg/dL ✓	Optimal - < 100 mg/dL	Direct-Enzymatic colorimetric Calculation
VLDL	: 15 mg/dl		Calculation
SERUM TRYGLYCERIDES	: 75 mg/dL	< 150 mg/dL	METHOD: Enzymatic colorimetric
<b>T3,T4 AND TSH</b>			
T3	: 1.80 ng/mL	0.8 - 2.0 ng/mL	Method : ECLIA
T4	: 12.89 ug/dL	5.1 - 14.1 ug/dL	Method : ECLIA
TSH(THYROID STIMULATING	: 3.31 uIU/mL	0.270 - 4.20 uIU/mL	Method : ECLIA
<b>LFT(LIVER FUNCTION TEST)</b>			
TOTAL BILIRUBIN	: 0.5 mg/dL	< 1.2 mg/dL	Method : Diazo Method
DIRECT BILIRUBIN	: 0.2 mg/dL	<= 0.20 mg/dL	Method: Diazo Method
INDIRECT BILIRUBIN	: 0.3 mg/dL	<= 1.0 mg/dL	Calculated
SGPT (ALT)	: 17 U/L	<= 41 U/L	Method : UV without P5P
SGOT (AST)	: 15 U/L	<= 40 U/L	Method : UV without P5P
ALKALINE PHOSPHATASE (ALP)	: 66 U/L		Method : PNPP
TOTAL PROTEINS	: 7.3 g/dL	6.0 - 8.0 g/dL	Method : Biuret method
SERUM ALBUMIN	:* 5.6 g/dL	3.5 - 5.2 g/dL	Method : Bromcresol Green (BCG)
GLOBULINS	:* 1.7 g/dL	2.5 - 3.5 g/dL	Calculated
A/G RATIO	:* 3.29	1.2 - 2.5	Calculation

\*\*\* End Of Report \*\*\*

Suggested Clinical Correlation \* If necessary, Please  
discuss  
Verified By



**Dr. S SIVA JYOTHSNA, MBBS, MD**  
**CONSULTANT PATHOLOGIST**

Test results related only to the item tested.

No part of the report can be reproduced without written permission of the laboratory.

Release Date : 29-Mar-24 1:59:58

తిరుమల మెడికల్ హాస్పిటల్స్

**(A UNIT OF SAHRUDAYA HEALTH CARE VIZIANAGARM PVT. LTD.)**

# Tirumala Medcover Hospital Tirumala

Near R.T.C. Complex, Vizianagaram, Andhra Pradesh 535003  
Ph:08922 - 223921, 225850, 9491759216, Fax, 233558



## DEPARTMENT OF RADIOLOGY

<b>Patient Name</b> : Mr. DEESARI PAVAN KUMAR	<b>Age / Gender</b> : 30 Y(s)/Male
<b>Bill No/ UMR No</b> : VZMB95952/VZMU70832	<b>Referred By</b> : Dr. RAJESH PALLAMRAJU BOLLAPATI
<b>Received Dt</b> : 29-Mar-24 11:07 am	<b>Report Date</b> : 29-Mar-24 12:01 pm

### USG ABDOMEN

#### FINDINGS

**LIVER** : Normal in size and echotexture. Smooth contour. No focal parenchymal lesion

**GALL BLADDER** : Partially distended with a normal wall thickness. CBD appear normal. Multiple calculi noted largest measuring approx 9mm.

**PANCREAS** : Head and body of pancreas are normal in size and echotexture. Rest obscured by bowel gas shadow.

**SPLEEN** : Normal in size and echotexture.

**RIGHT KIDNEY** : Normal in size, position and echogenecity. CMD maintained. No hydronephrosis or calculi.

**LEFT KIDNEY** : Normal in size, position and echogenecity. CMD maintained. No hydronephrosis or calculi.

**URINARY BLADDER** : Partially distended , normal in contour, capacity and wall thickness.No vesical calculi noted.

**PROSTATE** It is normal in size and homogenous inechotexture.

#### IMPRESSION

\*Cholelithiasis.

\*\*\* End Of Report \*\*\*

తిరుమల మెడికవర్ హాస్పిటల్

Dr. N. DIVYA, MBBS, MD(Radiology)

VERIFIED BY

Approved By

Dispatched By

(A UNIT OF SAHRUDAYA HEALTH CARE VIZIANAGARAM PVT. LTD.)



# Tirumala Medicover Hospitals

Near R.T.C. Complex, Vizianagaram, Andhra Pradesh 535003  
Ph:08922 - 223921, 225850, 9491759216, Fax, 233558



## DEPARTMENT OF RADIOLOGY

<b>Patient Name</b> : Mr. DEESARI PAVAN KUMAR	<b>Age / Gender</b> : 30 Y(s)/Male
<b>Bill No/ UMR No</b> : VZMB95952/VZMU70832	<b>Referred By</b> : Dr. RAJESH PALLAMRAJU BOLLAI
<b>Received Dt</b> : 29-Mar-24 11:07 am	<b>Report Date</b> : 29-Mar-24 01:55 pm

### X-RAY CHEST PA VIEW

#### FINDINGS

Trachea is central

Bony thorax and soft tissue shadows are normal.

Both lung fields is grossly normal.

Bilateral hilar regions are normal. No e/o. lymphadenopathy.

Bilateral C.P angle is clear.

#### IMPRESSION

\*No Significant Abnormality.

\*\*\* End Of Report \*\*\*

తిరుమల మెడికవర్ హాస్పిటల్స్

Dr. DIVYA, MBBS,MD(Radiology)

VERIFIED BY: [Signature] UNIT OF SAHARUDAYA HEALTH CARE VIZIANAGARAM PVT. LTD.)

Medicam

29/3/2024

D. Pawan Kumar

Age 130



# SWAMY EYE HOSPITAL

Super Speciality NABH Accredited Eye Hospital

**Dr. G.V. Prasad**  
M.D. Ophthalmology, (AIIMS)

**Dr. Prathima .M**  
M.B.B.S., DNB, FAICO (Retina) FAIOL

**Dr. M. Ravall**  
M.S. Ophthalmology, MD General Medicine Gold Medalist



**Dr. M. Kumara Swamy**  
M.S. Ophthalmology

ART  $\pm 1 - 0.50 \times 18$   
 $- 0.25 / - 0.25 \times 130$

NCT  $\pm 11$   
 $11$

Medical Text -

↑ Gp  
B6 of  
elw worked

fendas (undilated)

RE

~~WR~~  
LB

CDR-0.5  
mildTP  
FRP

CDR-0.5  
mildTP  
FRP

? Allergic conjunctivitis

1) SF2 eld BE BD  
- (1)

2) Compu eld BE  
utp - (1)

2

Putchala Veedhi, Near Old Bus Stand, Vizianagaram - 535 002. (Clinic): 08922 - 225722

Behind Inox Multiplex, Near RTC Complex, Vizianagaram-535003, Ph:08922-223322