



बैंक ऑफ़ बड़ौदा
Bank of Baroda

नाम बिजल कुमारी अशोकभाई पटेल

Name BIJAL KUMARI ASHOKBHAI PATEL

कर्मचारी कूट क्र.

E.C. No. 079392



जारीकर्ता प्राधिकारी
Issuing Authority

धारक के हस्ताक्षर
Signature of Holder



746, Viraval Village, Navsari, Viraval, Gujarat 396445, India

Latitude
20.9621122°

Longitude
72.9291497°

Local 12:59:15 PM
GMT 07:29:15 AM

Altitude 6 meters
Friday, 29.03.2024



(Regd. No. E / 1390 / Navsari)

YASHFEEN CARDIAC HOSPITAL™

MANAGED BY :- YASHFEEN FOUNDATION

VIRAVAL, NAVSARI. 396 445. PHONE : (H) (02637) 235725

Website : www.yashfeenhospital.in E-mail : info@yashfeenhospital.in

(Stationary For Report Only)

2D ECHO CARDIOGRAPHY COLOUR DOPPLER REPORT

Patient Name & No	: BIJALKUMARI ASHOKBHAI PATEL CH23053072	Age/Sex	UHID :	: 5115
Doctor	: Mohil Nagad	35/ F	No :	: 7780
Referred By	:		Date :	: 29/03/2024

M-Mode findings

LVIDd : 42mm
 LVIDs : 28mm
 IVSd : 10mm
 PWd : 09mm
 EF : 60%
 Aorta : 22mm
 LA : 35mm

2D Imaging

Aortic Valve : Trileaflet, Normal
 Mitral Valve : Thin, Pliable, Normal Mobility, Normal function
 Tricuspid Valve : Normal
 Pulmonary Valve : Normal

=> : All cardiac chambers are normal sized.
 => : All cardiac valves are normal.
 => : No regional wall motion abnormality.
 => : Normal LV systolic function.
 => : Normal LV diastolic function.
 => : IAS/IVS intact.
 => : No obvious clots/ vegetations/ or effusion.
 => : IVC Normal size.

Doppler Findings

=> : No MS/MR, No TS/TR, No AS/AR & No PS/PR
 Mitral inflow Pattern : E > A
 Tissue Doppler Findings : E' > A'

Impression : Normal LVEF:60%, No RWMA.

Report Prepared By



Report Checked By
R. MOHIL NAGAD
 M.D. Medicine, Cardiology
 Senior Consultant, Interventional Cardiology
 Reg. No. G-2289
 Non Invasive Cardiologist
 YASHFEEN HOSPITAL, NAVSARI

Designed By : Sarita Infotech Pvt. Ltd., Navsari

YASHFEEN IMAGING & RADIOLOGY DEPARTMENT

MANAGED BY :- YASHFEEN FOUNDATION

VIRAVAL, NAVSARI. 396 445. PHONE : (H) (02637) 235725

Website : www.yashfeenhospital.in E-mail : info@yashfeenhospital.in

Patient's Name:	BIJALKUMARI A. PATEL	Age & Sex:	35Yrs/F
Ref. by Dr.	SELF	Date:	29-03-2024

X RAY CHEST (PA VIEW)

Both lung fields appear normal.

Both hila appear normal.

Both CP angles appear clear.

Cardiac size appears within normal limit.


Both domes of diaphragm appear normal.

Bony thoracic cage appears normal.

IMPRESSION:

- Normal X-ray chest (PA view).




Dr. DHARMESH DESAI
(M.D. RADIOLOGY)
Reg. No. G 284
YASHFEEN GROUP OF HOSPITAL

Please contact immediately for any typographical error.

This is only professional opinion, not a final diagnosis. Kindly correlate clinically. Not valid for medicolegal purpose.



YASHFEEN CARDIAC HOSPITAL™

At. & Po. Viraval, Navsari. 396 445. Phone (H) (02637) 235725

Website : www.yashfeenhospital.in E-mail : info@yashfeenhospital.in

(For Laboratory Reports Only)



Patient Name : BIJALKUMARI ASHOKBHAI PATEL
Ref By Dr. : -
Sample Time : 29/03/2024 09:06 No : 18

Age : 35 Years Sex : F
Area : Chhapra Date : 29/03/2024
Time : 12:49PM

HAEMOGRAM

Test	Findings	UOM	Normal Range
HAEMOGLOBIN	11.7	gm/dl	M-13.5-17.0 gm/dl F-11.5-15.5 gm/dl
HAEMOGRAM			
RED BLOOD CELL	5.98	10 ⁶ /μL	3.76-5.70
TOTAL LEUCOCYTE COUNT	8100	cells/cumm	4,000-11,000cells/cumm
Differential Count			
Neutrophil	58	%	40-75 %
Lymphocytes	36	%	20-40 %
Eosinophil	3	%	01-06 %
Monocytes	3	%	02-10 %
Basophils	0	%	00-00 %
PLATELET COUNT	391000	lacs/cumm	1.5-5.5 Lacs/cumm
RBC INDICES			
P.C.V.	36.5	%	Male-40-56%, Female-37-47%
M.C.V.	61.0	cu/microns	76.0-94.0
M.C.H.	19.5	pg	27.0-30.0
M.C.H.C.	31.9	-	30.0-35.0
BLOOD GROUP	"O"	-	-
RH FACTOR	POSITIVE	-	-
E.S.R.(1 hour)	22	mm/hr.	Male-5-10 mm/hr, Female-5-20 mm/hr

Remarks

Designed By : Sarita Infotech Pvt. Ltd., Navsari

f. chaw
Dr. PIYUSH B. CHAUDHARI

M.D. Medicine

Reg. No. G-21518

Yashfeen Cardiac Hospital

Sarita
Signature

Technician

Thanks for Reference



YASHFEEN CARDIAC HOSPITAL™

At. & Po. Viraval, Navsari. 396 445. Phone (H) (02637) 235725
Website : www.yashfeenhospital.in E-mail : info@yashfeenhospital.in
(For Laboratory Reports Only)



Patient Name : BIJALKUMARI ASHOKBHAI PATEL Age : 35 Years Sex : F
Ref By Dr. : - Area : Chhapra Date : 29/03/2024
Sample Time : 29/03/2024 10:04 No : 18 Time : 12:49PM

HAEMOGLOBIN A1 C ESTIMATION

Test	Findings	UOM	Normal Range
Hb A1C	6.9	%	>8 :Action Suggested, 7-8 :Good Control, <7 :Goal, 6-7 :Near Normal Glycemia, <6 :Non-diabetic Level
Technique METHOD - HPLC		-	
Mean Blood Glucose	152.1	mg/dL	



P. Chaudhari
Dr. PIYUSH B. CHAUDHARI
M.D. Medicine
Reg. No. G-21518

Remarks

Designed By : Sarita Infotech Pvt. Ltd., Navsari

Yashfeen Cardiac Hospital

[Signature]
Signature
Technician

Thanks for Reference



YASHFEEN CARDIAC HOSPITAL™

At. & Po. Viraval, Navsari. 396 445. Phone (H) (02637) 235725

Website : www.yashfeenhospital.in E-mail : info@yashfeenhospital.in

(For Laboratory Reports Only)



Patient Name : BIJALKUMARI ASHOKBHAI PATEL
Ref By Dr. : -
Sample Time : 29/03/2024 10:04 No : 18

Age : 35 Years Sex : F
Area : Chhapra Date : 29/03/2024
Time : 12:50PM

LIPID PROFILE TEST REPORT

Test	Findings	UOM	Normal Range
S.CHOLESTEROL	131.4	mg/dL	<200:Desirable, 200-239:Borderline High, >=240:High
HDL CHOLESTEROL	32.9	mg/dL	<40:Low(High Risk), >=60:High(Low Risk)
LDL CHOLESTEROL	106.7	mg/dL	<100.0: Optimal, 100.0-129.0: Nearoptimal/ Aboveoptimal, 130.0-159.0:Borderline High, 160.0-189.0:High, >=190.0:Very High
VLDL CHOLESTEROL	23.6	mg/dL	Upto 40.0 mg/dL
S.TRIGLYCERIDES	118.0	mg/dL	<150.0:Normal, 150.0-199.0:Borderline high, 200.0-499.0:High, >=500.0:Very High
CHOL/ HDL RATIO	4.0	mg/dL	LESS THAN 5.0
LDL/ HDL RATIO	3.2	mg/dL	LESS THAN 5.0
REMARK	-	-	



P. Chaudhary
Dr. PIYUSH B. CHAUDHARI
M.D. Medicine
Reg. No. G-21518

Remarks

Designed By : Sarita Infotech Pvt. Ltd., Navsari

Yashfeen Cardiac Hospital

Amrasis
signature

Thanks for Reference


Technician



YASHFEEN CARDIAC HOSPITAL™

At. & Po. Viraval, Navsari. 396 445. Phone (H) (02637) 235725

Website : www.yashfeenhospital.in E-mail : info@yashfeenhospital.in
(For Laboratory Reports Only)



Patient Name : BIJALKUMARI ASHOKBHAI PATEL
Ref By Dr. : -
Sample Time : 29/03/2024 10:04 No : 18

Age : 35 Years Sex : F
Area : Chhapra Date : 29/03/2024
Time : 12:50PM

LIVER FUNCTION TEST REPORT

Test	Findings	UOM	Normal Range
TOTAL BILIRUBIN	0.4	mg/dL	0-1.0 mg/dL
DIRECT BILIRUBIN	0.2	mg/dL	0-0.8 mg/dL
INDIRECT BILIRUBIN	0.2	mg/dL	0-0.2 mg/dL
SGPT	11.1	U/L	Below 40.0 U/L
S.ALKALINE PHOSPHATASE	83.3	U/L	Child-170.0-515.0 U/L, Adults-37.0-147.0 U/L
TOTAL PROTEIN	7.0	g/dl	6.0-8.0 g/dl
ALBUMIN	4.4	g/dl	3.0-5.0 g/dl
GLOBULIN	2.6	g/dl	3.0-3.5 g/dl
A/G	1.7	g/dl	
SGOT	11.3	U/L	Below 40.0 U/L



P. Chaudhari
Dr. PIYUSH B. CHAUDHARI
M.D. Medicine
Reg. No. G-21518

Remarks

Designed By : Sarita Infotech Pvt. Ltd., Navsari

Yashfeen Cardiac Hospital

Rethod

Signature

Thanks for Reference

Technician



YASHFEEN CARDIAC HOSPITAL™

At. & Po. Viraval, Navsari. 396 445. Phone (H) (02637) 235725

Website : www.yashfeenhospital.in E-mail : info@yashfeenhospital.in
(For Laboratory Reports Only)




Patient Name : BIJALKUMARI ASHOKBHAI PATEL
Ref By Dr. : -
Sample Time : 29/03/2024 10:04 No : 18

Age : 35 Years Sex : F
Area : Chhapra Date : 29/03/2024
Time : 12:50PM

GGT TEST REPORT

Test	Findings	UOM	Normal Range
SERUM GGT	25.0	U/L	10.0-71.0 U/L



P. Chaudhary
Dr. PIYUSH B. CHAUDHARI
M.D. Medicine
Reg. No. G-21518

Remarks

Designed By : Sarita Infotech Pvt. Ltd., Navsari

Yashfeen Cardiac Hospital

Sarita
signature

Thanks for Reference

Technician



YASHFEEN CARDIAC HOSPITAL™

At. & Po. Viraval, Navsari. 396 445. Phone (H) (02637) 235725
Website : www.yashfeenhospital.in E-mail : info@yashfeenhospital.in
(For Laboratory Reports Only)



Patient Name : BIJALKUMARI ASHOKBHAI PATEL Age : 35 Years Sex : F
Ref By Dr. : - Area : Chhapra Date : 29/03/2024
Sample Time : 29/03/2024 10:04 No : 18 Time : 12:50PM

BLOOD SUGAR TEST REPORT

Test	Findings	UOM	Normal Range
FASTING BLOOD SUGAR	136.5	mg/dL	70-110 mg/dL
FASTING URINE SUGAR	NIL	-	NIL
POSTPANDRIAL BLOOD SUGAR	190.0	mg/dL	70-140 mg/dL
POSTPANDRIAL URINE SUGAR	NIL	-	NIL



P. Chaudhari
Dr. PIYUSH B. CHAUDHARI
M. D. Medicine
Reg. No. G-21518

Remarks

Designed By : Sarita Infotech Pvt. Ltd., Navsari

Yashfeen Cardiac Hospital

Amrisha
Signature
Technician

Thanks for Reference



YASHFEEN CARDIAC HOSPITAL™

At. & Po. Viraval, Navsari. 396 445. Phone (H) (02637) 235725
Website : www.yashfeenhospital.in E-mail : info@yashfeenhospital.in
(For Laboratory Reports Only)



Patient Name : BIJALKUMARI ASHOKBHAI PATEL Age : 35 Years Sex : F
Ref By Dr. : - Area : Chhapra Date : 29/03/2024
Sample Time : 29/03/2024 10:04 No : 18 Time : 12:50PM

RENAL FUNCTION TEST REPORT

Test	Findings	UOM	Normal Range
S.CREATININE	0.5	mg/dL	Male-0.9-1.4 mg/dL, Female-0.8-1.2 mg/dL
S.URIC ACID	5.3	mg/dL	Male:3.5-7.2 mg/dL, Female:2.6-6.0 mg/dL
BLOOD UREA NITROGEN	4.6	mg/dL	4.7-23.0 mg/dL



P. Meel
Dr. PIYUSH B. CHAUDHARI
M.D. Medicine
Reg. No. G-21518

Remarks

Designed By : Sarita Infotech Pvt. Ltd., Navsari

Yashfeen Cardiac Hospital

Amrisha
Signature

Thanks for Reference

Technician



YASHFEEN CARDIAC HOSPITAL™

At. & Po. Viraval, Navsari. 396 445. Phone (H) (02637) 235725
Website : www.yashfeenhospital.in E-mail : info@yashfeenhospital.in
(For Laboratory Reports Only)



Patient Name : BIJALKUMARI ASHOKBHAI PATEL Age : 35 Years Sex : F
Ref By Dr. : - Area : Chhapra Date : 29/03/2024
Sample Time : 29/03/2024 10:05 No : 18 Time : 12:50PM

THYROID FUNCTION TEST REPORT

Test	Findings	UOM	Normal Range
T3 (TRIODOTHYRONINE)	1.31	ng/ml	Newborns:0.73-2.88, 6 Days-3 Months:0.80-2.75, 4-12Months:0.86-2.65, 1-6 Years:0.92-2.48, 7-11 Years:0.93-2.31, 12-20Years:0.91-2.18, Adults:0.80-2.00
T4(THYROXINE)	7.71	µg/dl	Newborns:5.04-18.5, 6 Days-3 Months:5.41-17.0, 4-12 Months:5.67-16.0, 1-6 Years:5.95-14.7, 7-11 Years:5.99-13.8, 12-20 Years:5.91-13.2, Adults:5.10-14.1
TSH	2.38	µIU/ml	Newborns:0.70-15.2, 6 Days-3 Months:0.72-11.0, 4-12 Months:0.73-8.35, 1-6 Years:0.70-5.97, 7-11 Years:0.60-4.84, 12-20 Years:0.51-4.30, Adults:0.27-4.20

TECHNIQUE
ELECTROCHEMILUMINESCEN
CE



P. Chaudhary
Dr. PIYUSH B. CHAUDHARI
M.D. Medicine
Reg. No. G-21518

Remarks

Designed By : Sarita Infotech Pvt. Ltd., Navsari

Yashfeen Cardiac Hospital

S. Desai
Signature

Thanks for Reference

Technician



YASHFEEN CARDIAC HOSPITAL™

At. & Po. Viraval, Navsari. 396 445. Phone (H) (02637) 235725
Website : www.yashfeenhospital.in E-mail : info@yashfeenhospital.in
(For Laboratory Reports Only)



Patient Name : BIJALKUMARI ASHOKBHAI PATEL Age : 35 Years Sex : F
Ref By Dr. : - Area : Chhapra Date : 29/03/2024
Sample Time : 29/03/2024 10:05 No : 18 Time : 12:50PM

ROUTINE URINE ANALYSIS

Test	Findings	UOM	Normal Range
<u>PHYSICAL EXAMINATION</u>			
Quantity	-	-	-
Colour	YELLOW	-	-
Appearance	CLEAR	-	-
Reaction	ACIDIC	-	-
Sp. Gravity	1.005	-	-
<u>CHEMICAL EXAMINATION</u>			
U.Albumin	NIL	-	-
Sugar	NIL	-	-
Acetone	NIL	-	-
Bile Salt	NIL	-	-
Bile Pigment	NIL	-	-
Occult Blood	NIL	-	-
<u>MICROSCOPIC EXAMINATION</u>			
Pus Cells	5-6	/hpf	
Epithelial cells	3-4	/hpf	
Red cells	ABSENT	/hpf	
Casts	-	/hpf	
Crystals	AMORPHOUS SEEN	/hpf	
Others	BACTERIA {FEW} SEEN	/hpf	



P. Chaudhari
Dr. PIYUSH B. CHAUDHARI
M. D. Medicine
Reg. No. G-21518

Remarks

Designed By : Sarita Infotech Pvt. Ltd., Navsari

Yashfeen Cardiac Hospital

Signature
signature

Thanks for Reference

Technician

BIJALKUARI,
ID:
DOB:
35 Years
Female, Unknown
Med.:
Location:
Referring Physician:
Notes:

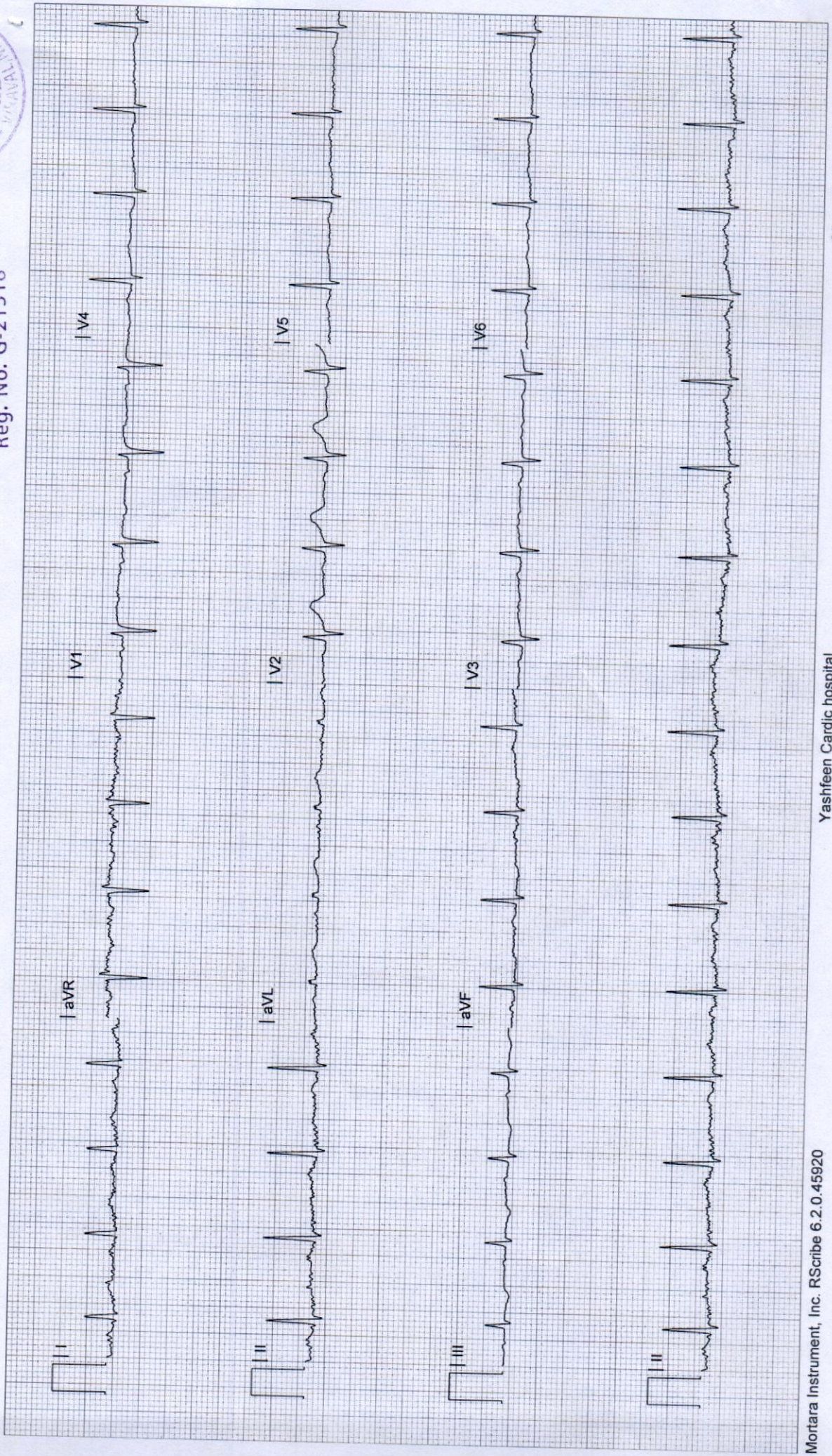
29-03-2024 10:12:49

Vent. Rate: 94 BPM
PR int: 151 ms
QRS dur: 84 ms
QT/QTc: 351/402 ms
P-R-T axes: 37 53 -5
Avg. RR: 637 ms
QTcB: 439 ms
QTcF: 407 ms

SINUS RHYTHM
NONSPECIFIC ST & T-WAVE ABNORMALITY
BORDERLINE ECG

UNCONFIRMED REPORT
Reviewed by:

Signed by: *f. chaudh*
Date:
Dr. PIYUSH B. CHAUDHARI
M.D. Medicine
Reg. No. G-21518



YASHFEEN IMAGING & RADIOLOGY DEPARTMENT

MANAGED BY :- YASHFEEN FOUNDATION

VIRAVAL, NAVSARI. 396 445. PHONE : (H) (02637) 235725

Website : www.yashfeenhospital.in E-mail : info@yashfeenhospital.in

Name	BIJALKUMARI A. PATEL	Age	35Y/F
Ref by Dr	SELF	Date	29/03/2024

USG ABDOMEN & PELVIS (SCREENING)(TVS)

Liver appears normal in size & shape with normal echopattern.
No e/o focal or diffuse lesion. IHBR appear normal.
PV and CBD appear normal.

Gall bladder appears distended & normal in shape & size. No e/o calculus or mass seen.
Walls appear normal.

Pancreas appears normal in size and echogenicity. No e/o focal or diffuse lesion.

Spleen appears enlarged in size and shows normal echopattern. No e/o focal lesion.

Both Kidneys appear normal in size and echopattern. CM Differentiation is preserved.
No e/o calculus or hydronephrosis on either side.
Perirenal spaces appear normal on either side.
Suprarenal regions appear normal on either side. No e/o mass lesion.

Bladder is empty (due to non-compliance of patient). Adv: Follow up USG with normally distended bladder.

Uterus appears anteverted, normal in size & shows normal echopattern.
Endometrial cavity is empty. ET- 14 mm. No e/o focal or diffuse mass lesion.
Both ovaries appear normal in size & echopattern.
No e/o adnexal mass on either side.

RIF region appears normal.

No e/o ascites.

IMPRESSION:

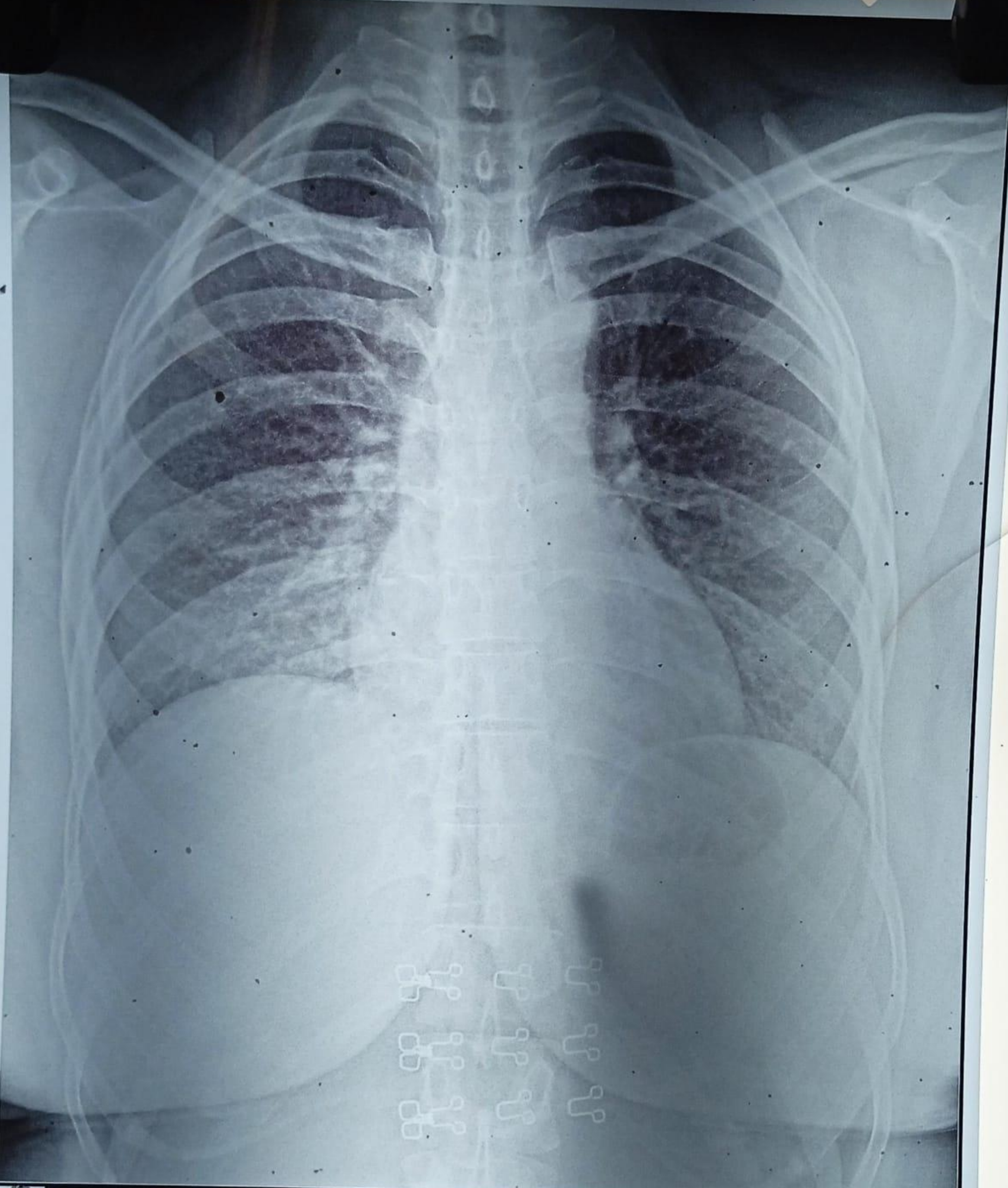
Mild splenomegaly.



Dr. DHARMESH DESAI
(M.D. Radiology)
Reg. No. G - 45284
Dr. Dharmesh Desai
MD
YASHFEEN GROUP OF HOSPITAL

Please contact immediately for any typographical error.

This is only professional opinion, not a final diagnosis. Kindly consult clinically. Not valid for medical/legal purposes.



3053072 BIJALKUMARI A PATEL 35/Y 290324793. ChestErect PA 29/03/2024
YASHFEEN GROUP OF HOSPITALS NAVSARI PH:9924047789