

REDIUS

DIAGNOSTICS



Medical Form & EYE CHECK UP

Demographic Information:

Name	:	Asha Chaudhari	Date	:	29/03/24
Age	:				
Sex	:	♀			

VITALS CHECKUP

Blood Pressure	:-	110/70	HEIGHT [IN CM]	:-	154
Heart Rate	:-	72/min	Weight (in Kgs)	:-	53
Spo2	:-	98%	BMI VALUE	:-	22.3
PULSE	:-	74/min	BMI STATUS	:-	(Normal)

HISTORY

Current Health Complaints		NO
Past History		NO
Family History		Mother - DM + HTN
Allergies		NO
Ongoing Medication		NO

Any other problems needing attention / Overall Assessment :

REMARKS :-

①

EYE TEST

1. VISION :-

A. NEAR VISION

RIGHT EYE :- ②
LEFT EYE :- ②

B. DISTANCE VISION

RIGHT EYE :- 6/9 with
LEFT EYE :- 6/9 specs

2. COLOR VISION :-

RIGHT EYE :- ②
LEFT EYE :- ②

3. NIGHT VISION :-

RIGHT EYE :- ②
LEFT EYE :- ②

REMARKS :- NAD

DOCTOR SIGN

Revival Diagnostic
401, Aqua Corridor,
B/s. Star Bazar, Surat-395009
Mo. 91062-28601

C. V. Patel

Dr. Chirag Patel
M.B.B.S. G-49432



REVIVAL

DIAGNOSTICS



Dental Checkup

Patient Name: - Asha choudhari

Age: - 59 Sex: - F

Past Medical History

1) Smoking 2) Alcohol 3) Hepatitis B & C 4) Diabetics 6) Tobacco 5) Allergy 6) Asthma

7) Any Other: NO

PDH: - B

O/E: - B

Investigation: NO

Treatment: - NO

Doctor's Sign and Stamp

Consent Form:

Asha choudhari have given true & total information to the dentist regarding past & present illness as well as ongoing medical treatment. I have been fully informed regarding treatment for present illness. Along with benefit & possible risk from medicines / Surgery / Anesthetic drugs to be used by the dentist in my own understanding language. I hereby willingly permit the dentist to undertake the treatment or surgical intervention.

Patient Signature: A.v. choudhari

Revival Diagnostic
401, Aqua Corridor,
B/s. Star Bazar, Surat-395009
Mo. 91062-28601

0261-2747788; 9525947712

4th FLOOR, AQUA CORRIDOR, BESIDE STAR BAZAR ADAJAN 395009



revivaldiagnostics.surat@gmail.com



REVIVAL DIAGNOSTICS

Name	CHAUDHARI ASHA VINOD	Age/Gender	59Yrs/Female
Reg No.	3116/24	Receipt No	19289
Referred By	Bank of Baroda (BOB) - MEDI WHEEL()	Mode of Payment	CREDIT
Collection Type	CENTER	Collection DateTime	29-Mar-2024 08:34 AM

BLOOD GROUP - 290324158 Released at 29-Mar-2024 01:05 PM

Parameter	Result	Biological Ref.Range	Method
-Blood Group	"O"		
-Rh Factor	POSITIVE		

CBC - 290324158 Released at 29-Mar-2024 10:45 AM

Parameter	Result	Biological Ref.Range	Method
-Haemoglobin	11.4 gm/dL	L (12 - 16 gm/dL)	Auto
-RBC Count	5.39 mill/cumm	(4.2 - 5.4 mill/cumm)	Auto
-Total WBC Count	7300 /cumm	(4000 - 10000 /cumm)	Auto
-Platelet Count	3.03 lakh/cumm	(1.5 - 4.5 lakh/cumm)	Auto

Blood Indices

-HCT	38.5 %	L (40 - 55 %)	Auto
-MCV	70.5 fl	L (80 - 92 fl)	Auto
-MCH	20.8 pg	L (27 - 31 pg)	Auto
-MCHC	29.5 gm/dL	L (32 - 36 gm/dL)	Auto
-RDW	14.9 %	(11 - 15 %)	Auto

Diff WBC Count

-Polymorphs	51 %	(40 - 80 %)	Microscopically
-Lymphocytes	42 %	H (20 - 40 %)	Microscopically
-Eosinophils	05 %	(1 - 6 %)	Microscopically
-Monocytes	02 %	(2 - 7 %)	Microscopically
-Basophils	00 %	(0 - 1 %)	Microscopically
-PLATELET ON SMEAR	Adequate		Microscopically
-MALARIAL PARASITES	Malarial Parasites Not Detected		Microscopically

[Test performed on Fully Automated Hematology Analyzer ERBA H-360]

Revival Diagnostics

401-Aqua Corridor,
Beside Star Bazar, Adajan,
Surat-395009. Mo. 9825947712

Dr. Shivangi Gandhi
M.B.B.S, M.D (Pathology)

0261-2747788, 98259 47712

4th Floor, Aqua Corridor, Hazira Road, Adajan Pal, Surat - 395009.

revivaldiagnostics.surat@gmail.com

www.revivaldiagnostics.com



REVIVAL DIAGNOSTICS

Name	CHAUDHARI ASHA VINOD	Age/Gender	59Yrs/Female
Reg No.	3116/24	Receipt No	19289
Referred By	Bank of Baroda (BOB) - MEDI WHEEL()	Mode of Payment	CREDIT
Collection Type	CENTER	Collection DateTime	29-Mar-2024 08:34 AM

ESR - 290324158 Released at 29-Mar-2024 11:01 AM

Parameter	Result	Biological Ref.Range	Method
-E.S.R	08 mm/hr	(3 - 15 mm/hr)	

Revival Diagnostics

401-Aqua Corridor,
Beside Star Bazar, Adajan,
Surat-395009. Mo. 9825947712

Dr. Shivangi Gandhi
M.B.B.S, M.D (Pathology)

0261-2747788, 98259 47712

4th Floor, Aqua Corridor, Hazira Road, Adajan Pal, Surat - 395009.

revivaldiagnostics.surat@gmail.com

www.revivaldiagnostics.com



REVIVAL DIAGNOSTICS

Name	CHAUDHARI ASHA VINOD	Age/Gender	59Yrs/Female
Reg No.	3116/24	Receipt No	19289
Referred By	Bank of Baroda (BOB) - MEDI WHEEL()	Mode of Payment	CREDIT
Collection Type	CENTER	Collection DateTime	29-Mar-2024 08:34 AM

FBS & PPBS - 290324159 Released at 29-Mar-2024 02:49 PM

Parameter	Result	Biological Ref.Range	Method
-Fasting Blood Sugar (FBS)	96 mg/dL	70-100 mg/dl Impaired Tolerance: 100-125 Diabetes Mellitus: >=126 (American diabetes association guidelines 2022)	
-Fasting Urine Sugar	Absent		
-Fasting Urine Acetone	Absent		
-PPBS	123 mg/dL	(90 - 140 mg/dL)	
-PP2BS URINE SUGAR	Absent		
-PP2BS URINE ACETONE	Absent		

Revival Diagnostics

401-Aqua Corridor,
Beside Star Bazar, Adajan,
Surat-395009. Mo. 9825947712

Sg

Dr. Shivangi Gandhi
M.B.B.S, M.D (Pathology)

0261-2747788, 98259 47712

4th Floor, Aqua Corridor, Hazira Road, Adajan Pal, Surat - 395009.

revivaldiagnostics.surat@gmail.com

www.revivaldiagnostics.com

This Medical Report is Not Intended for Medico-legal Purposes. Laboratory Test Results are Subject to Technical limitation and Should be Clinically Correlate for Final Diagnosis



REVIVAL DIAGNOSTICS

Name	CHAUDHARI ASHA VINOD	Age/Gender	59Yrs/Female
Reg No.	3116/24	Receipt No	19289
Referred By	Bank of Baroda (BOB) - MEDI WHEEL()	Mode of Payment	CREDIT
Collection Type	CENTER	Collection DateTime	29-Mar-2024 08:34 AM

LIVER FUNCTION TEST (LFT) - 290324161 Released at 29-Mar-2024 02:49 PM

Parameter	Result	Biological Ref.Range	Method
-Serum Total Bilirubin	0.6 mg/dL	(0 - 1.3 mg/dL)	Diazo
-Serum Direct Bilirubin	0.2 mg/dL	(0 - 0.4 mg/dL)	Diazo
-Serum InDirect Bilirubin	0.4 mg/dL	(0.1 - 1.3 mg/dL)	Calculated
-Total Protein (TP)	6.6 gm/dL	(6.4 - 8.3 gm/dL)	Biuret
-Albumin (ALB)	3.9 gm/dL	(3.5 - 5.2 gm/dL)	BCG
-Globulin	2.7 gm/dL	(2.3 - 3.6 gm/dL)	Calculated
-A/G Ratio	1.44 gm/dL	(1 - 2.3 gm/dL)	Calculated
-SGPT(ALT)	13 U/L	(5 - 45 U/L)	IFCC, Kinetic without Pyridoxal Phosphate
-SGOT (AST)	15 U/L	(0 - 35 U/L)	IFCC, Without Pyridoxal Phosphate
-Alkaline Phosph.	90 U/L	(42 - 128 U/L)	ALP-AMP
-GGT	17 U/L	(5 - 50 U/L)	Glupa-C

[Test performed on Fully Automated Biochemistry Analyzer ERBA EM200]

Revival Diagnostics

401-Aqua Corridor,
Beside Star Bazar, Adajan,
Surat-395009. Mo. 9825947712

sg

Dr. Shivangi Gandhi
M.B.B.S, M.D (Pathology)

0261-2747788, 98259 47712

4th Floor, Aqua Corridor, Hazira Road, Adajan Pal, Surat - 395009.

revivaldiagnostics.surat@gmail.com

www.revivaldiagnostics.com



REVIVAL DIAGNOSTICS

Name	CHAUDHARI ASHA VINOD	Age/Gender	59Yrs/Female
Reg No.	3116/24	Receipt No	19289
Referred By	Bank of Baroda (BOB) - MEDI WHEEL()	Mode of Payment	CREDIT
Collection Type	CENTER	Collection DateTime	29-Mar-2024 08:34 AM

Creatinine - 290324161 Released at 29-Mar-2024 02:49 PM

Parameter	Result	Biological Ref.Range	Method
-Creatinine	0.6 mg/dL	(0.6 - 1.14 mg/dL)	ENZYMATIC

BUN - 290324161 Released at 29-Mar-2024 11:52 AM

Parameter	Result	Biological Ref.Range	Method
-Blood Urea Nitrogen (BUN)	8 mg/dL	(6 - 20 mg/dL)	Calculated

Uric Acid - 290324161 Released at 29-Mar-2024 02:49 PM

Parameter	Result	Biological Ref.Range	Method
-Uric Acid	5.8 mg/dL	(3.5 - 7.2 mg/dL)	Uricase-POD

Revival Diagnostics

401-Aqua Corridor,
Beside Star Bazar, Adajan,
Surat-395009. Mo. 9825947717

Dr. Shivangi Gandhi
M.B.B.S, M.D (Pathology)

0261-2747788, 98259 47712

4th Floor, Aqua Corridor, Hazira Road, Adajan Pal, Surat - 395009.

revivaldiagnostics.surat@gmail.com

www.revivaldiagnostics.com



REVIVAL DIAGNOSTICS

Name	CHAUDHARI ASHA VINOD	Age/Gender	59Yrs/Female
Reg No.	3116/24	Receipt No	19289
Referred By	Bank of Baroda (BOB) - MEDI WHEEL()	Mode of Payment	CREDIT
Collection Type	CENTER	Collection DateTime	29-Mar-2024 08:34 AM

Lipid Profile - 290324161 Released at 29-Mar-2024 02:50 PM

Parameter	Result	Biological Ref.Range	Method
-Serum Cholesterol	194 mg/dL	Desirable < 200 mg/dl Borderline High : 200-239 mg/dl High : > 240 mg/dl	CHOD-PAP
-Serum Triglyceride	132 mg/dL	Normal < 150 mg/dl Borderline High : 150 - 199 mg/dl High : 200 - 499 mg/dl Very High : 500 mg/dl	GPO-POD Method
-Serum HDLD(Direct)	45 mg/dL	Normal :> 55 mg/dl Borderline : 35-55 mg/dl Undesirable: < 35 mg/dl	PVS-PEGME Precipitation with CHOD-POD
-Serum VLDL	26 mg/dL	(5 - 30 mg/dL)	Calculated
-Serum LDL(Direct)	123 mg/dL	Optimal:< 100 mg/dl Above Optimal : 100- 129 mg/dl Borderline High : 130-159 mg/dl High : > 160-189mg/dl Very High : >190 mg/dl	Calculated
-Chol/HDL	4.31	Low risk: <3.8 Medium Risk: 3.8 to 5.9 High Risk: > 6	Calculated
-LDL/Chol	1.58	Low risk: <3.55 Medium Risk: 3.55 to 4.0 High Risk: > 6	Calculated

[Test performed on Fully Automated Biochemistry Analyzer ERBA EM200]

Revival Diagnostics
401-Aqua Corridor,
Beside Star Bazar, Adajan,
Surat-395009. Mo. 9825947712

Sg

Dr. Shivangi Gandhi
M.B.B.S, M.D (Pathology)

0261-2747788, 98259 47712

4th Floor, Aqua Corridor, Hazira Road, Adajan Pal, Surat - 395009.

revivaldiagnostics.surat@gmail.com

www.revivaldiagnostics.com




REVIVAL DIAGNOSTICS

Name	CHAUDHARI ASHA VINOD	Age/Gender	59Yrs/Female
Reg No.	3116/24	Receipt No	19289
Referred By	Bank of Baroda (BOB) - MEDI WHEEL()	Mode of Payment	CREDIT
Collection Type	CENTER	Collection DateTime	29-Mar-2024 08:34 AM

Urine Routine & Micro Examination - 290324163 Released at 29-Mar-2024 01:17 PM

Parameter	Result	Biological Ref.Range	Method
Physical Examination			
-Quantity	30		Manual
-Colour	Pale Yellow	Pale Yellow	Manual
-Appearance	Clear	Clear	Manual
-Reaction (pH)	Acidic		Dipstick
-Specific Gravity	1.025		Dipstick
Chemical Examination			
-Proteins.	Absent		Dipstick
-Sugar	Absent		Dipstick
-Acetone.	Absent		Dipstick
-Bile Salts	Absent	Absent	Dipstick
-Bile Pigments	Absent	Absent	Dipstick
-Occult Blood Test (OBT).	Negative		Dipstick
Microscopic Examination			
-Pus Cells	2-3		Microscopically
-Red Blood Cells	Absent		Microscopically
-Epithelial Cells	1-2		Microscopically
-Bacteria.	Absent		Microscopically
-Crystals	Absent	Absent	Microscopically
-Others	NIL	Absent	Microscopic Examination

Revival Diagnostics
401-Aqua Corridor,
Beside Star Bazar, Adajan,
Surat-395009. Mo. 9825947712


Dr. Shivangi Gandhi
M.B.B.S, M.D (Pathology)

 0261-2747788, 98259 47712

 4th Floor, Aqua Corridor, Hazira Road, Adajan Pal, Surat - 395009.

 revivaldiagnostics.surat@gmail.com

 www.revivaldiagnostics.com



REVIVAL DIAGNOSTICS

Name	CHAUDHARI ASHA VINOD	Age/Gender	59Yrs/Female
Reg No.	3116/24	Receipt No	19289
Referred By	Bank of Baroda (BOB) - MEDI WHEEL()	Mode of Payment	CREDIT
Collection Type	CENTER	Collection DateTime	29-Mar-2024 08:34 AM

Total T3 T4 TSH - 290324161 Released at 29-Mar-2024 12:50 PM

Parameter	Result	Biological Ref.Range	Method
-Total T3	0.99 ng/ml	(0.87 - 1.78 ng/ml)	Fluorescence Enzyme Immunoassay
-Total T4	5.12 ug/dl	(4.6 - 11 ug/dl)	Fluorescence Enzyme Immunoassay
-TSH	4.74 uIU/ml	0.50 - 5.50 uIU/ml 5.5 to 15 ul U/ml - Suggested Clinical co-relation or Repeat test with new sample as physiological factors can give falslely high TSH Above 15uIU/ml Hypopyhyroid PREGNANT WOMEN normal ranges for TSH: 1st Trimester : 0.0878 - 2.8293 uIU/ml 2nd Trimester : 0.1998 - 2.7915 uIU/ml 3rd Trimester : 0.307 - 2.9028 uIU/ml Ref: TIETZ Fundamentals of Clinical Chemistry	Fluorescence Enzyme Immunoassay

[Test performed on Fully Automated Immunology Analyzer Maglumi-600]

Revival Diagnostics
401-Aqua Corridor,
Beside Star Bazar, Adajan,
Surat-395009. Mo. 9825947712

Sg

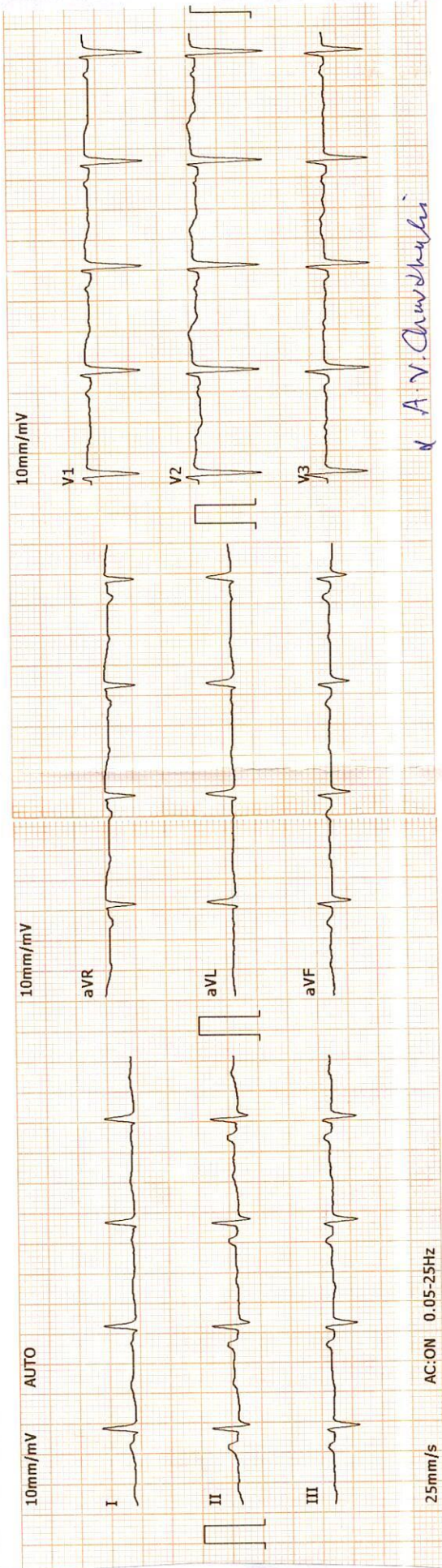
Dr. Shivangi Gandhi
M.B.B.S, M.D (Pathology)

0261-2747788, 98259 47712

4th Floor, Aqua Corridor, Hazira Road, Adajan Pal, Surat - 395009.

revivaldiagnostics.surat@gmail.com

www.revivaldiagnostics.com

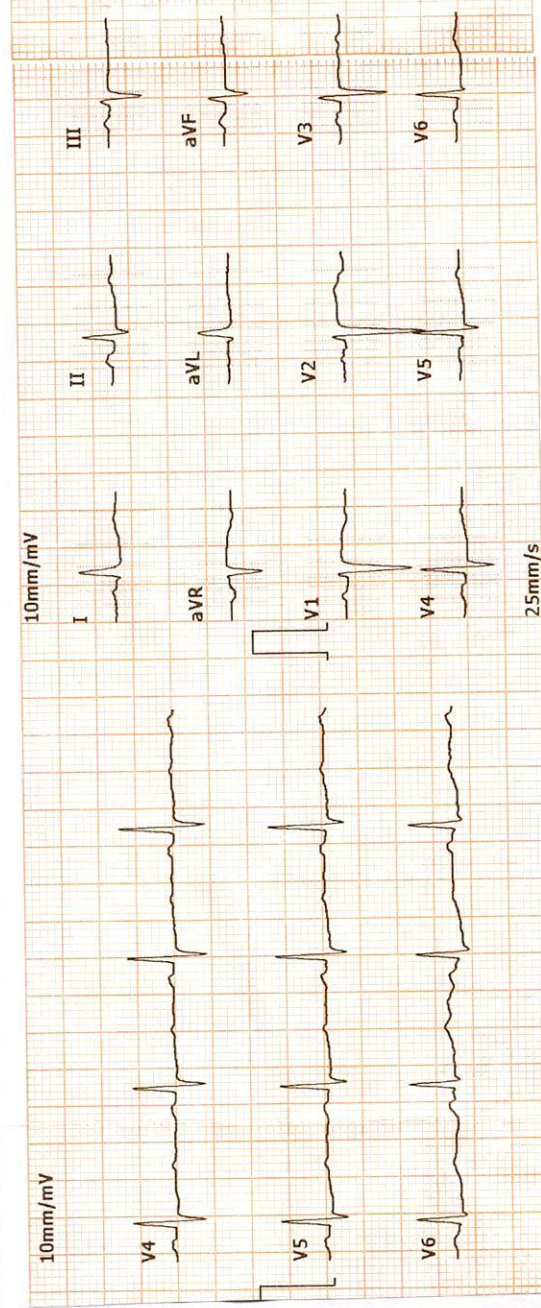


2024-3-29 9:37:21 ID: 00008887

ID Card: Name: CHAUDHARI ASHA Gender: Female
Age: 59 Height(cm):
Weight(Kg): BP(mmHg): /

HR.....bpm 85
P-R.....ms 116
Q-R-S.....ms 86
QT/QTc.....ms 390/463
P/QRS/T AXES.....deg 76/-8/76
RV5/SV1.....mV 0.69/0.78
RV5+SV1.....mV 1.47

*The result must be confirmed by doctor!
Report Confirmed by:



DR. ADITYAS BORA
MBBS, MD, PGDCC
PHYSICIAN & CLINICAL CARDIOLOGIST
G-54906

Revival Diagnostics
401-Aquã Corridor,
Beside Star Gazer, Adajan,
Goregaon - 405009. Mo. 9825947712



REVIVAL DIAGNOSTICS

Name	CHAUDHARI ASHA VINOD	Age/Gender	59Yrs/Female
Reg No.	3116/24	Receipt No	19289
Referred By	Bank of Baroda (BOB) - MEDI WHEEL()	Mode of Payment	CREDIT
Collection Type	CENTER	Collection DateTime	29-Mar-2024 08:03 AM

Ecg

1. The rhythm is sinus.
2. Heart rate is 85 beats per minute.
3. Normal P,QRS,T wave axis.
4. Normal PR,QRS,Q.T. Duration.
5. No pathological q wave or ST-T changes seen.
6. No evidence of chamber hypertrophy or enlargement seen.

IMPRESSION : ECG WITHIN NORMAL LIMITS

Signature

Revival Diagnostics
401-Aqua Corridor,
Beside Star Bazar, Adajan,
Surat-395009. Mo. 9825947712

DR. ADITYA S. BORA
MBBS, DNB, PGDCC
PHYSICIAN & CLINICAL CARDIOLOGIST
G-54906

0261-2747788, 98259 47712

4th Floor, Aqua Corridor, Hazira Road, Adajan Pal, Surat - 395009.

revivaldiagnostics.surat@gmail.com

www.revivaldiagnostics.com



REVIVAL DIAGNOSTICS

Name	CHAUDHARI ASHA VINOD	Age/Gender	59Yrs/Female
Reg No.	3116/24	Receipt No	19289
Referred By	Bank of Baroda (BOB) - MEDI WHEEL()	Mode of Payment	CREDIT
Collection Type	CENTER	Collection DateTime	29-Mar-2024 08:03 AM

2D ECHO

2D ECHOCARDIOGRAPHY & COLOR DOPPLER REPORT

INDICATION: Preventive Health check up

- **CARDIAC CHAMBERS :** Left Ventricle : Normal size , Left Atrium: Normal size.
- NO e/o thrombus in LA/LV
- Right Atrium: Normal size. Right Ventricle: Normal Size,
- **Normal Right Ventricular function.** (TAPSE=20mm)
- **Normal Left Ventricular systolic function.** LVEF = 60%
- **No regional wall abnormality. No thinning / scarring / dyskinesia of LV wall**
- **No Left Ventricular Hypertrophy.** (IVSd= 09 mm),
- **LV Compliance:**
- **NO Left Ventricular Diastolic Dysfunction [LVDD].**

VALVES :

- Structurally Normal Mitral valve/ Aortic valve/Tricuspid valve/ Pulmonary valve .
- No significant Valvular Stenosis
- **Doppler findings: AV max = 1.23 m/s, PV max = 0.91 m/s.**
- Trivial MR, Trivial Tricuspid regurgitation.
- **No Pulmonary Arterial Hypertension.** PASP by TRjet vel.method = 24 mmHg.
- **SEPTAE:** IAS / IVS Appear Intact.
- **IVC :** Normal in dimension and shows good inspiratory 13mm collapse.
- **OTHERS:** No e/o Pericardial effusion / vegetation.

IMPRESSION:

**NORMAL LV SYSTOLIC FUNCTION, LVEF= 60 %, NO RWMA,
NO LVH , NO LVDD , NO PAH.**

Revival Diagnostics
401-Aqua Corridor,
Beside Star Bazar, Adajan,
Surat-395009. Mo. 9825947712

DR. ADITYA S. BORA
MBBS, DNB, PCCDC
PHYSICIAN & CLINICAL CARDIOLOGIST
G-54906
Signature

0261-2747788, 98259 47712

4th Floor, Aqua Corridor, Hazira Road, Adajan Pal, Surat - 395009.

revivaldiagnostics.surat@gmail.com

www.revivaldiagnostics.com



NAME : CHAUDARI ASHA VINOD
AGE: 59 YRS / FEMALE
REF BY: MEDI WHEEL





REVIVAL DIAGNOSTICS

Name	CHAUDHARI ASHA VINOD	Age/Gender	59Yrs/Female
Reg No.	3116/24	Receipt No	19289
Referred By	Bank of Baroda (BOB) - MEDI WHEEL()	Mode of Payment	CREDIT
Collection Type	CENTER	Collection DateTime	29-Mar-2024 08:03 AM

CHEST RADIOGRAPH (PA VIEW)

- Hilar shadows are within normal limits.
- Pulmonary vasculature appears normal.
- Cardiac appears normal in size.
- Both domeh of the diaphragm are smooth.
- Both costophrenic recesses are clear.
- Both lung fields appear normal.
- Visualized bones and soft tissue shadows appear normal.

IMPRESSION: NORMAL STUDY.

DR.CHIRAG K PATEL
RADIOLOGIST

Dr. Chirag K. Patel
MBBS-DMPD
Reg. No. G-23509
Signature
Revival Diagnostic
4th Floor, Aqua Corridor,
Nr. Star Bazar, Hazira Main Road,
Adajan, Surat-395009.
Mo. 97266 726683

📞 0261-2747788, 98259 47712

📍 4th Floor, Aqua Corridor, Hazira Road, Adajan Pal, Surat - 395009.

@ revivaldiagnostics.surat@gmail.com

🌐 www.revivaldiagnostics.com



REVIVAL DIAGNOSTICS

Name	CHAUDHARI ASHA VINOD	Age/Gender	59Yrs/Female
Reg No.	3116/24	Receipt No	19289
Referred By	Bank of Baroda (BOB) - MEDI WHEEL()	Mode of Payment	CREDIT
Collection Type	CENTER	Collection DateTime	29-Mar-2024 08:03 AM

USG OF ABDOMEN & PELVIS

LIVER:

Liver is normal in size, shape and echotexture.
No evidence of focal SOL or dilatation of IHBR seen.
Portahepatis appear normal.

GALLBLADDER:

Gallbladder is distended and appears normal.
No e/o calculus, mass lesion or changes of cholecystitis seen.

PANCREAS:

Pancreas appears normal in size, shape and echotexture.
No e/o focal lesion, mass or changes of pancreatitis seen.

SPLEEN:

Spleen appears normal in size, shape and echotexture.

PARAAORTIC REGION:

Aorta grossly appears normal. No e/o paraaortic lymphnodes seen.

KIDNEYS:

Both kidneys appear normal in size, shape, position and echotexture.
Cortex and collecting system of both kidneys appear normal.
No evidence of calculus or obstructive uropathy on either side.

URINARY BLADDER:

Bladder is distended and appears normal.
No calculus, mass lesion or changes of cystitis is seen.

UTERUS:

not visualized. h/o hysterectomy.

Both adnexal region appear normal.
No e/o adnexal mass lesion seen on either side.
No evidence of free fluid seen in pelvis.

COMMENTS: NORMAL USG ABDOMEN AND PELVIS.

Dr. Chirag K. Patel

MBBS-DMPD

Reg. No. G-23509

Revival Diagnostic

4th Floor, Aqua Corridor,
Nr. Star Bazar, Hazira Main Road,
Adajan, Surat-395009. **Signature**
Mo. 97266 726683

0261-2747788, 98259 47712

4th Floor, Aqua Corridor, Hazira Road, Adajan Pal, Surat - 395009.

revivaldiagnostics.surat@gmail.com

www.revivaldiagnostics.com



REVIVAL DIAGNOSTICS

Name	CHAUDHARI ASHA VINOD	Age/Gender	59Yrs/Female
Reg No.	3116/24	Receipt No	19289
Referred By	Bank of Baroda (BOB) - MEDI WHEEL()	Mode of Payment	CREDIT
Collection Type	CENTER	Collection DateTime	29-Mar-2024 08:03 AM

SONOGRAPHY OF BOTH BREASTS

TECHNIQUE- USG of both breast done by using 10 MHz high frequency.

FINDINGS -

RT BREAST:

On USG

Right breast shows normal parenchymal pattern.

No e/o skin thickening, nipple retraction, microcalcification.

No e/o focal SOL, architectural distortion.

3-4 smooth oval shaped mixed echoic area in the right axillary region, largest 42 x 30 mm with mild vascularity.

LT BREAST:

On USG

Left breast shows normal parenchymal pattern.

No e/o skin thickening, nipple retraction, microcalcification.

No e/o focal SOL, architectural distortion.

No e/o lymphadenopathy is noted in left axillary region.

COMMENT – Findings suggest ,

Right breast - right axillary lesions as described above - more likely lymphadenopathy - infective / inflammatory.

Left breast - Normal

need further evaluation.

Dr. Chirag K. Patel

MBBS-DMPD

Reg. No. G-23509

Revival Diagnostic

4th Floor, Aqua Corridor,

Nr. Star Bazar, Hazira Road, Adajan, Surat-395009.

Mo. 97266 726583

Dr. Chirag K. Patel
Radiologist