

MRS. YAMINI RATHORE

BOB

34 YEARS /FEMALE

01-4-2024

Height: 169 Cms

Weight: 74 Kg

BP: - 120/74 mmhg

Pulse: - 88/- Regular

BMI: - 25.9 kg/m²

EYE: - NORMAL

The Medical Examiner should record the findings under one of the following categories:-
OVERWEIGHT



Dr. D. S. Chhabra
M.B.B.S. M.D.

DR. D.S. CHHABRA
MBBS. MD.

MRS. RATHORE YAMINI**32 Years /F****BANK OF BARODA****01-04-2024****HEAMOGRAM**

Test Name	Results	Normal Range
Haemoglobin (HB)	11.3	11 - 16 gm%
R.B.C. Count	3.94	3.8 - 4.8 milli./cu.mm
PCV	37.7	36 - 46 %
MCV	95.69	80 - 98 fl
MCH	28.68	27 - 32 pg
MCHC	29.97	31.5 - 34.5 %
TOTAL WBC COUNT	7,700	4,000 to 11,000 /cu.mm
DIFFERENTIAL WBC COUNT	.	
Neutrophils	65	40 - 75 %
Lymphocytes	30	20 - 40 %
Monocytes	03	02 - 08 %
Eosinophils	02	01 - 05 %
Basophils	00	00 - 01 %
PLATELET COUNT	3.11	1.5 - 4 Lacs/cu.mm.
E.S.R	12	M- 0-10 at the end of 1 hr. F- 0-20 at the end of 1 hr

Dr. POOJA PRAPANNA
MD**DR. POOJA PRAPANNA****M.D.**

MRS. RATHORE YAMINI**32 Years /F****BANK OF BARODA****01-04-2024****LIPID PROFILE**

Test Name	Results	Normal Range
TOTAL LIPIDS	552	400 - 700 mg/dl
CHOLESTROL	200.0	<200 mg/dl- Desirable 200 - 239 mg/dl - Borderline High >240 Mg/dl High
HDL CHOLESTROL	43.0	35- 60 mg/dl
TRIGLYCERIDE	102.0	<150 mg/dl Normal 150 - 199 mg/dl Borderline High 200 - 499 mg/dl High
LDL CHOLESTROL	136.6	<100 mg/dl Optimal 100- 129 mg/dl Borderline high 160 - 189 mg/dl High
VLDL CHOLESTROL	20.4	<40 mg/dl
RISK RATIO	4.65	3 - 6

DR. POOJA PRAPANNA**DR. POOJA PRAPANNA****M.D.**

MRS. RATHORE YAMINI

32 Years /F

BANK OF BARODA

01-04-2024

BIOCHEMISTRY

Test Name	Results	Normal Range
SERUM BILIRUBIN	:-	
TOTAL BILIRUBIN	0.91	0 - 1 mg/dl
DIRECT BILIRUBIN	0.16	<0.25 mg/dl
INDIRECT BILIRUBIN	0.75	< 1.0 mg/dl
S.G.O.T	25.0	0 - 45 IU/L
S.G.P.T	20.0	0 - 45 IU/L
ALKALINE PHOSPHATE	68.0	Adult - 42 - 128 IU/L Child - 150 - 630 IU/L
TOTAL PROTEIN	6.84	6.0 to 8.0 g/dl
ALBUMIN	4.36	3.2 to 5.0 g/dl
GLOBULIN	2.48	1.9 to 3.5
A:G RATIO	1.76	1.2 TO 2.3
GAMA GT	30.0	5 - 43 IU/L

Dr. POOJA PRAPANNA
MDDR. POOJA PRAPANNA
M.D.

MRS. RATHORE YAMINI
BANK OF BARODA

32 Years /F
01-04-2024

Test Name	Results	Normal Range
-----------	---------	--------------

HAEMATOLOGY PROFILE

BLOOD GROUP	: -	
"ABO " GROUP	"A"	
Rh (D) Factor	Positive	
	.	
	.	
(Cross matching & recheck of Blood Group is mandatory before any transfusion)	.	
HBA1C	5.20	Normal 4-6 % Good Control 6-7 % Fair Control 7-8 % Unsatisfactory Control 8-10 % Poor Control Above 10 %

SEROLOGY PROFILE

HBsAg Non Reactive

* Test done by screening methods.
Requires confirmation at refferal centre.

Dr. POOJA PRAPANNA
MD

Contd...2.00
DR. POOJA PRAPANNA

4D SONOGRAPHY • COLOR DOPPLER • ECHO • PATHOLOGY • DIGITAL X-RAY & OPG • TMT • ECG • HOLTER

MRS. RATHORE YAMINI
BANK OF BARODA32 Years /F
01-04-2024

Test Name	Results	Normal Range
<u>BIOCHEMISTRY</u>		
FASTING BLOOD SUGAR	74.0	70 - 110 mg/dl
P.P. BLOOD SUGAR	84.0	upto 140 mg/dl
BUN	11.0	5 - 21 Mg/dl
CREATININE	0.68	0.6 - 1.4 mg\dl
URIC ACID	5.63	2.5 - 6.8 mg\dl
CALCIUM	8.90	8.5 - 10.5 mg\dl

Dr POOJA PRAPANNA
MD

DR. POOJA PRAPANNA

M.D.

Note :- All pathological tests have technical and biological limitations. Please correlate clinically as well as with other investigative findings.
A review should be requested in case of any disparity. This report is not valid for medicolegal purpose.

Pt. Name: MRS. RATHORE YAMINI
Ref. By: BANK OF BARODA

Age/Sex: 32 Yrs /F
Date: 01-Apr-2024

CYTOPATHOLOGY

Material Received:- 1 Pap Smear Prepared.

Smear adequacy :- Satisfactory.

Fair no. clusters of superficial and intermediate squamous epithelial cells

Endocervical cells: Seen, with squamous metaplastic cells

Organism: Altered flora (coccobacilli seen)

Negative for intraepithelial lesion or malignancy

Impression: Features are suggestive of Bacterial vaginosis

Advise: Follow up

Dr. POOJA PRAPANNA
MD

DR. POOJA PRAPANNA
M.D.

Note :- All pathological tests have technical and biological limitations. Please correlate clinically as well as with other investigative findings.

MRS. RATHORE YAMINI
BANK OF BARODA32 Years /F
01-04-2024**URINE EXAMINATION**

Test Name	Results	Normal Range
PHYSICAL EXAMINATION		
Quantity	30 ml	
Colour	Pale Yellow	
Appearance	Clear	
Deposits	Absent	
Specific Gravity	1.015	
Reaction	Acidic	
CHEMICAL EXAMINATION		
Albumin	Nil	
Sugar	Nil	
Ketones	Absent	
Bile Pigments	Negative	
Bile Salt	Negative	
Hematuria	Negative	
MICROSCOPIC EXAMINATION		
Pus Cells	1- 2 /hpf	
Red Blood Cells	Nil/hpf	
Epithelial Cell	1 - 2 /hpf	
Crystals	Nil	
Casts	Absent	

Dr. POOJA PRAPANNA
MD

DR. POOJA PRAPANNA

M.D.

MRS. YAMINI RATHORE

32 Yrs./F

BOB

01st April, 2024

X-RAY CHEST PA VIEW

Bony cage is normal.

Trachea is central. C.P. angles are clear.

Cardiac contour and cardiothoracic ratio are normal.

Lung fields are clear.

DR.D.S.CHHABRA.

M.D.

4D SONOGRAPHY • COLOR DOPPLER • ECHO • PATHOLOGY • DIGITAL X-RAY & OPG • TMT • ECG • HOLTER

MRS. YAMINI RATHORE**32 Yrs/F****BOB****01st April, 2024****ABDOMINAL SONOGRAPHY**

Liver is of normal size, shape, has smooth margins & regular contours and the parenchyma reveals normal echostructure. No focal lesion.

Gall bladder is of normal size, shape, has thin walls & the contents are clear fluid. No evidence of any calculus. Biliary tree is undilated.

Pancreas is normal, no focal / diffuse pathology. Spleen is normal.

Both kidneys are normal in size [measure about 11 cms. in length], shape and echostructure. No calculus in both. The collecting system and ureter on both side are undilated.

Urinary bladder is normal in size, shape and has thin walls.

Uterus is of normal size [measures about 8 x 5 x 4 cms. in diam.] and is normal in shape. The uterine outlines are smooth & regular and the myometrial & endometrial echopattern is normal. No mass.

Both ovaries are normal in size, shape and echostructure.

No adnexal / pelvic mass or cyst. No pelvic collection.

There is no ascitis. No obvious abdominal lymphadenopathy. No sub / supra diaphragmatic pathology on either side.

IMPRESSION :

Normal study.



DR.D.S.CHHABRA.
M.D.



LABORATORY REPORT



Name : YAMINI RATHORE	Sex/Age : Female / 32 Years	Case ID : 40401600113
Ref. By :	Dis. At :	Pt. ID :
Bill. Loc. : UNIQUE DIAGNOSTIC CENTRE INDORE		Pt. Loc. :
Reg Date and Time : 01-Apr-2024 13:18	Sample Type : Serum	Mobile No. :
Sample Date and Time : 01-Apr-2024 13:18	Sample Coll. By : non	Ref Id1 :
Report Date and Time : 01-Apr-2024 15:42	Acc. Remarks : -	Ref Id2 :

TEST	RESULTS	UNIT	BIOLOGICAL REF RANGE	REMARKS
Thyroid Function Test				
Triiodothyronine (T3) <small>CMIA</small>	116.12	ng/dL	58 - 159	
Thyroxine (T4) <small>CMIA</small>	8.04	µg/dL	5.5 - 11.0	
TSH <small>CMIA</small>	3.55	µIU/mL	0.4 - 4.2	

INTERPRETATIONS

- Circulating TSH measurement has been used for screening for euthyroidism, screening and diagnosis for hyperthyroidism & hypothyroidism. Suppressed TSH (<0.01 µIU/mL) suggests a diagnosis of hyperthyroidism and elevated concentration (>7 µIU/mL) suggest hypothyroidism. TSH levels may be affected by acute illness and several medications including dopamine and glucocorticoids. Decreased (low or undetectable) in Graves disease. Increased in TSH secreting pituitary adenoma (secondary hyperthyroidism), PRTN and in hypothalamic disease thyrotropin (tertiary hyperthyroidism). Elevated in hypothyroidism (along with decreased T4) except for pituitary & hypothalamic disease.
- Mild to modest elevations in patient with normal T3 & T4 levels indicates impaired thyroid hormone reserves & incipient hypothyroidism (subclinical hypothyroidism).
- Mild to modest decrease with normal T3 & T4 indicates subclinical hyperthyroidism.
- Degree of TSH suppression does not reflect the severity of hyperthyroidism, therefore, measurement of free thyroid hormone levels is required in patient with a suppressed TSH level.

CAUTIONS

Sick, hospitalized patients may have falsely low or transiently elevated thyroid stimulating hormone. Some patients who have been exposed to animal antigens, either in the environment or as part of treatment or imaging procedure, may have circulating antianimal antibodies present. These antibodies may interfere with the assay reagents to produce unreliable results.

TSH ref range in pregnancy

First trimester
Second trimester
Third trimester

Reference range (microIU/ml)

0.24 - 2.00
0.43-2.2
0.8-2.5

Note:(LL-VeryLow,L-Low,H-High,HH-VeryHigh ,A-Abnormal)

Dr. Chetana Bora
MD Pathology

Dr. A Mishra
M.D. Microbiology

Dr. Soma Yadav
M.D. (Pathology)

Printed On : 01-Apr-2024 15:53

DR. PRIYANK JAIN
M.D.,D.M.
CONSULTANT CARDIOLOGIST

UNIQUE DIAGNOSTIC CENTRE
45-B, Jaora Compound,
Opp. M.Y.Hospital, M.Y.H. Road,
INDORE - 452 001. (M. P.).
Phone : 2704118. 4082228

ECHOCARDIOGRAPHY REPORT

NAME : **MRS. YAMINI RATHORE** **Age** : **32 Yrs./ F**
REFERRED BY : **BOB** **Date** : **01st April, 2024**

ECHOCARDIOGRAPHIC OPINION

INTERPRETATION :-

- ** No RWMA.**
- ** Good biventricular function. LVEF : 60 %.**
- ** Normal cardiac valves, healthy pericardium.**
- ** Grade I diastolic dysfunction.**



Dr. PRIYANK JAIN
MBBS, MD, DM.
Reg. No. 19547

DR. PRIYANK JAIN. M.D.,D.M.

TWO DIMENSIONAL ECHOCARDIOGRAPHY

M Mode examination revealed normal movement of both mitral leaflets during diastole.

No SAM or mitral valve prolapse is seen.

Mitral valve opening is normal. No evidence of mitral valve prolapse is seen.

Tricuspid valve is normal, pulmonary valve is normal, aortic root is normal in size, dimensions of left atrium and left ventricle are normal.

Aortic cusps are not thickened and enclosure line is central.

Aortic valve has three cusps and its opening is not restricted.

2 - D imaging in PLAX, SAX and apical views revealed a normal sized left ventricle.

Movement of septum, anterior, posterior, inferior and lateral walls is normal. Global LVEF is 60 %.

Right atrium and right ventricle are normal in size.

Tricuspid valve leaflets move normally.

Pulmonary valve is normal.

Interatrial and interventricular septa are intact.

No intracardiac mass or thrombus is seen.

No pericardial pathology is observed.

MEASUREMENTS :


[C] DIMENSIONS	OBSERVED VALUES	Normal Values (For Adults)
1. Aortic Root diameter	: 2.7 cms.	2.0-3.7 cm < 2.2 cm / M ²
2. Aortic Valve Opening	: 2.7 cms.	1.5-2.6 cm
3. Right Ventricular Dimension	: --	
4. Left Atrial Dimension	: 3.3 cms.	1.9-4.0 cm < 2.2 cm / M ²
5. Left Ventricular ED Dimension	: 3.6 cms.	3.7-5.6 cm < 3.2 cm / M ²
6. Left Ventricular ES Dimension	: 2.1 cms.	2.2-4.0 cm
7. Inter Ventricular ED Septal thickness	: 1.2 cms.	0.6-1.2 cm
8. Left Ventricular ED PW thickness	: 1.2 cms.	0.5-1.0 cm
9. IVS / LVPW	: 01	< 1.3

[E] INDICES OF LEFT VENTRICULAR FUNCTION		
1. Mitral E - Septal Separation	: 0.5	< 0.9- cm
2. Left Ventricular Ejection Fraction	: 60 %	60 - 80 %

DOPPLER

Peak Flow Velocity (M/Sec.)		Peak Gradient (mmHg.)	Regurgitation
MV	Normal	--	Normal
TV	Normal	--	Normal
AV	Normal	--	Normal
PV	Normal	--	Normal

PASP : Normal



बैंक ऑफ़ बड़ौदा
Bank of Baroda

Name : Yamini Rathore

E.C.No. : 103750

जारीकर्ता प्राधिकारी

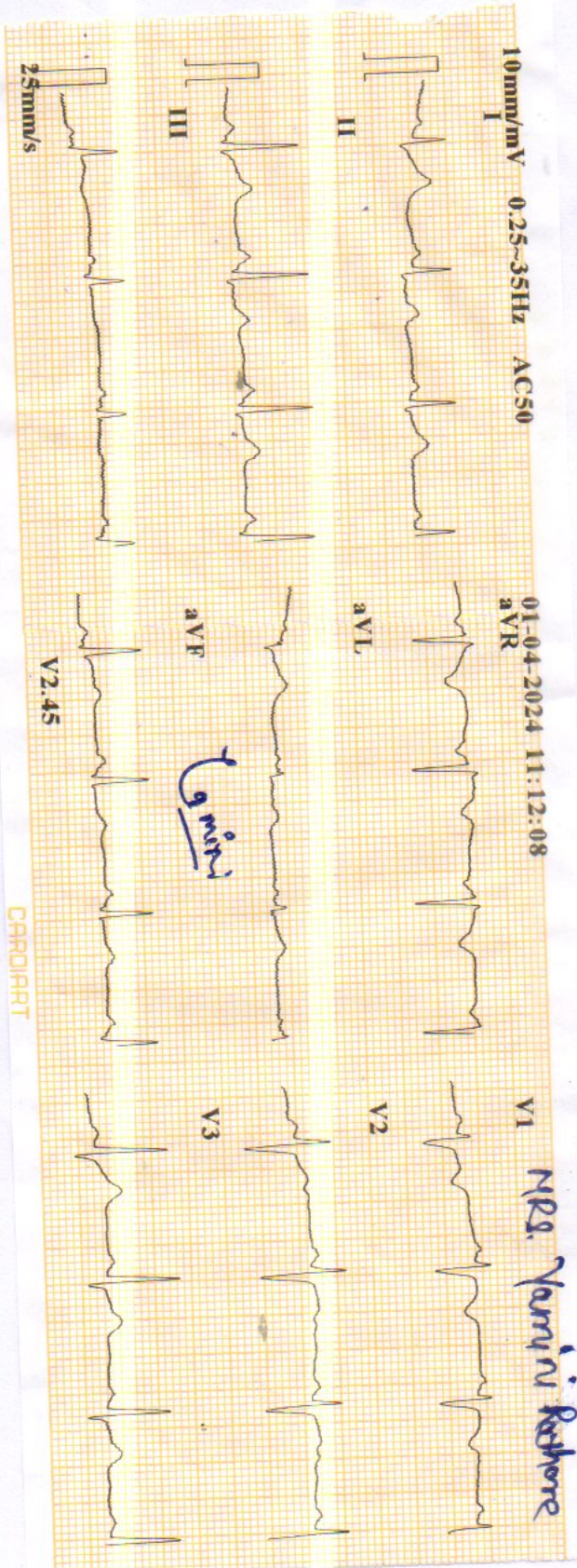


धारक के हस्ताक्षर

Scanned with OKEN Scanner

Dr. D. S. Chhabra
Reg. No. 5007





BPL

ID	: 240401-1112
Name	:
Age	: 34 yr
Sex	: R Male
BP	:
Height	: cm
Weight	: kg
HR	: 83 bpm
P Dur	: 92 ms
PR int	: 116 ms
QRS Dur	: 89 ms
QT/QTc int	: 340/400 ms
P/QRS/T axis	: 53/56/27 °
RV5/SV1 amp	: 1.060/0.516 mV
RV5+SV1 amp	: 1.576 mV
RV6/SV2 amp	: 1.181/0.698 mV



DR. PRIYANKA JAIN
MBBS, MD, DM
Regd. No. 19547

②
ECG

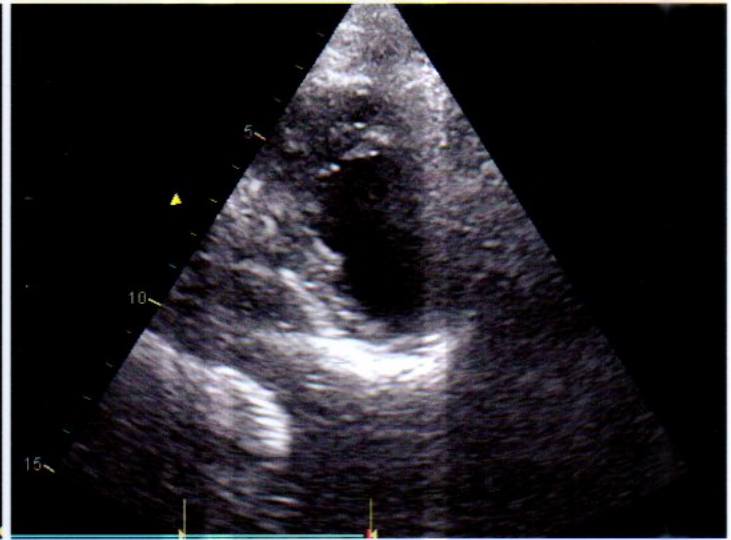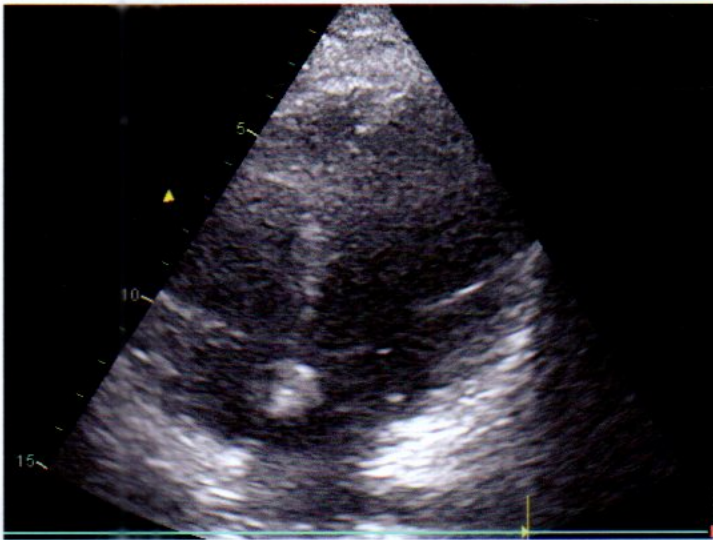
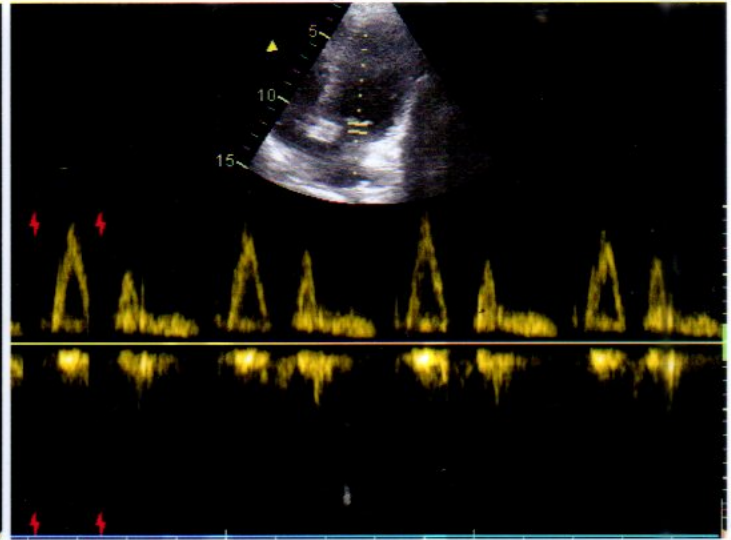
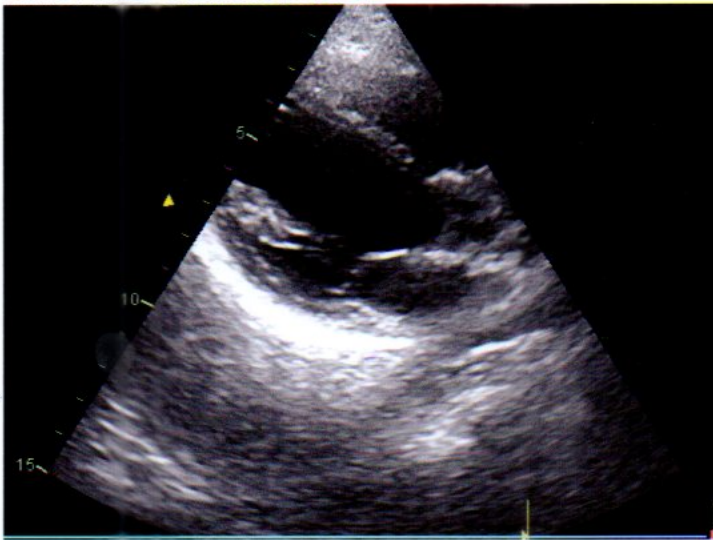UNIQUE DIAGNOSTIC CENTRE INDORE

01 Apr 2024

Name : MRS. YAMINI RATHORE

Ref.by : BOB

Done by : DR. PRIYANK JAIN M.D.,DM.



IVC	1.2 cm
LA	3.6 cm
LV	2.1 cm
RV	1.2 cm
Wd	1.3 cm
Ws	1.3 cm
(Teich)	54 ml
(Teich)	14 ml
(Teich)	75 %
(Teich)	41 ml
(Teich)	43 %

Diam	3.3 cm
Ao	1.22

