


MER- MEDICAL EXAMINATION REPORT

Date of Examination	29/3/14		
NAME	DURGAM RAO		
AGE	37	Gender	M
HEIGHT(cm)	172	WEIGHT (kg)	70
B.P.	120/86		
E.C.G	normal		
X Ray	normal		
Vision Checkup	—		
Present Ailments	None		
Details of Past ailments (If Any)	No		
Comments / Advice : She /He is Physically Fit	Medicines Rx		

264



Dr. SMR Rastogi
 MBBS, DCP
 Reg. No. 37370


Signature with Stamp of Medical Examiner

You have been informed that ent ,diet, ophthal consultation facility is not available at our centre. If you are ready then your test can be start

2D echo test facility is not available at our center, instead we do TMT test.

By 4





Handwritten signature



MODERN PATHOLOGY & DIAGNOSTIC CENTRE

DIAGNOSTIC CENTRE

Dr. R. P. Rastogi
M.B.B.S., M.D. (Path & Bact)



CLINIC :

1/4A, Vineet Khand, (Opp Jaipuria Management)
Gomti Nagar, Lucknow - 226 010
Ph.: 0522-4008184, 4308184 • 8112323230
Mob.: 7618884441, 9450389932, 8177063877

Date : 29-Mar-2024
Name : **Mr. DURGESH RAI**
Ref.By : APOLLO HEALTH
Age : 37 Yrs.
Sex : Male

Haemoglobin 14.2 gm% 14 - 17

Total Leucocyte Count 5100 Cells/cumm. 4000-11000

Differential Leucocyte Count

Polymorphs	64	%	45 - 70
Lymphocytes	30	%	20 - 45
Eosinophils	01	%	0 - 6
Monocytes	05	%	0 - 8
Basophils	00	%	0 - 1

Erythrocyte Sedimentation Rate (Wintrobe)

ESR	06	mm in 1st Hr.	0 - 9
PCV	44.9	cc%	40 - 52
Corrected ESR	02	mm in 1st Hr.	0 - 9

Platelet Count 1.55 lakh/cumm. 1.5 - 4.0

Red Cells Count 4.80 million/cmm 3.90 to 5.80

Absolute values

MCV	93.6	fL	77 - 97
MCH	29.5	pg	27 - 31
MCHC	31.5	gm /dl	31 - 34

Dr. Sanjay Rastogi
M.B.B.S., DCP, CRIAT (BARC)

Dr. Smita Rastogi
M.B.B.S., DCP

Results, adhering to W.H.O. and International Federation of Clinical Chemists Quality Control Standards.

SAMPLE COLLECTION FACILITY AVAILABLE

Report needs clinicopathological correlation ♦ Not for Medico Legal Purpose

e-mail : mpdcgn@gmail.com ♦ For online reports - www.modernpath.in

♦ Please ask for your computerized bill ♦ Pay only the printed collection charges



MODERN PATHOLOGY & DIAGNOSTIC CENTRE

CLINIC :

1/4A, Vineet Khand, (Opp Jaipuria Management)
Gomti Nagar, Lucknow - 226 010
Ph.: 0522-4008184, 4308184 • 8112323230
Mob.: 7618884441, 9450389932, 8177063877

Dr. R. P. Rastogi
M.B.B.S., M.D. (Path & Bact)



Date : 29-Mar-2024

Name : **Mr. DURGESH RAI**

Ref.By : APOLLO HEALTH

Age : 37 Yrs.

Sex : Male

General Blood Picture

RBCs RBCs are Normocytic & Normochromic.
No Normoblasts are seen.

WBCs TLC is within normal range.
DLC shows normal counts.
No immature cells of WBC seen.

PLATELETS Platelets are adequate in number and morphology.

OTHERS No haemoparasites are seen.

IMPRESSION Normal GBP

Dr. Sanjay Rastogi
M.B.B.S., DCP, CRIAT (BARC)

Dr. Smita Rastogi
M.B.B.S., DCP

Results, adhering to W.H.O. and International Federation of Clinical Chemists Quality Control Standards.

SAMPLE COLLECTION FACILITY AVAILABLE

Report needs clinicopathological correlation ♦ Not for Medico Legal Purpose

e-mail : mpdcgn@gmail.com ♦ For online reports - www.modernpath.in

♦ Please ask for your computerized bill ♦ Pay only the printed collection charges



MODERN PATHOLOGY & DIAGNOSTIC CENTRE

DIAGNOSTIC CENTRE

Dr. R. P. Rastogi
M.B.B.S., M.D. (Path & Bact)



CLINIC :
1/4A, Vineet Khand, (Opp Jaipuria Management)
Gomti Nagar, Lucknow - 226 010
Ph.: 0522-4008184, 4308184 • 8112323230
Mob.: 7618884441, 9450389932, 8177063877

Date : 29-Mar-2024
Name : **Mr. DURGESH RAI**
Ref.By : APOLLO HEALTH
Age : 37 Yrs.
Sex : Male

KFT			
UREA	18.4	mg %	15 - 50
CREATININE	1.08	mg %	0.5 - 1.5
URIC ACID	5.5	mg %	2 - 7
CALCIUM	9.4	mg %	8.8 - 10.0

Blood Group & Rh : "B" Positive

Urine Sugar (Fasting) : NIL

Urine Sugar (PP) : NIL

Plasma Glucose - F
GOD-POD Method : 96 mg/dl 70 - 110

Plasma Glucose - PP
GOD POD Method : 161 mg/dl 110 - 170

LFT T&D			
Total Bilirubin	0.59	mg%	0.2 - 1.0
Direct Bilirubin	0.17	mg%	0.0 to 0.40
Indirect Bilirubin	0.42	mg%	0.10 to 0.90
S.G.P.T	65	IU/L	5 - 40
S.G.O.T	54	IU/L	5 - 50
ALP	82	IU/L	40 to 129

Serum Gamma G.T. : 34 IU/L 11 - 50

Dr. Sanjay Rastogi
M.B.B.S., DCP, CRIAT (BARC)

Dr. Smita Rastogi
Contd... M.B.B.S., DCP

Results, adhering to W.H.O. and International Federation of Clinical Chemists Quality Control Standards.

SAMPLE COLLECTION FACILITY AVAILABLE

Report needs clinicopathological correlation ♦ Not for Medico Legal Purpose

e-mail : mpdcgn@gmail.com ♦ For online reports - www.modernpath.in

♦ Please ask for your computerized bill ♦ Pay only the printed collection charges



MODERN PATHOLOGY & DIAGNOSTIC CENTRE

CLINIC :

1/4A, Vineet Khand, (Opp Jaipuria Management)
Gomti Nagar, Lucknow - 226 010
Ph.: 0522-4008184, 4308184 • 8112323230
Mob.: 7618884441, 9450389932, 8177063877

Dr. R. P. Rastogi
M.B.B.S., M.D. (Path & Bact)



Date : 29-Mar-2024

Name : **Mr. DURGESH RAI**

Ref.By : APOLLO HEALTH

Age : 37 Yrs.

Sex : Male

LIPID PROFILE

Triglycerids	133	mg%	70 - 190
S. Cholestrol S.	212	mg%	130 - 230
S. HDL Cholestrol	49.1	mg%	35 - 75
S. LDL Cholestrol	136.3	mg%	75 - 150
VLDL	26.6	mg%	0 - 34
Chol / HDL factor	4.32		
LDL / HDL Factor	2.78		

COMMENTS

- * Triglycerides (TG) are the main dietary lipids. Cholesterol constitutes a small part of the dietary lipids, it is mostly synthesised in the liver. Both TG and Chol. are transported through the plasma by lipoproteins (Chylomicrons, VLDL, LDL, IDL, HDL).
- * LDL is the major cholesterol particle in plasma and high levels are strongly implicated in the formation of atheroma. An increase in the LDL leads to hypercholesterolemia, and therefore a risk factor for IHD. LDL increases with age particularly in females. Oestrogen lower LDL and raise HDL. Raised chol. in females is mostly due to disturbed thyroid function.
- * Increase in VLDL leads to hyperglyceridaemia. Raised TGs are associated with increased risk of CHD. Very high TGs increase the risk of Pancreatitis. Cholesterol is often raised due to Diabetes, Renal disease, Diuretic or Betablocker therapy.

TYPES OF HYPERLIPOPROTEINEMIAS

TYPE 1: Normal cholesterol TG greatly raised	TYPE 3: Cholesterol increased TG increased
TYPE 2a: Cholesterol increased LDL increased TG normal	TYPE 4: Cholesterol normal /increased VLDL increased TG increased
TYPE 2b Chol. increased VLDL raised TG increased LDL increased	TYPE 5: Cholesterol increased LDL reduced VLDL increased TG greatly increased

Dr. Sanjay Rastogi
M.B.B.S., DCP, CRIAT (BARC)

Dr. Smita Rastogi
Contd... M.B.B.S., DCP

Results, adhering to W.H.O. and International Federation of Clinical Chemists Quality Control Standards.

SAMPLE COLLECTION FACILITY AVAILABLE

Report needs clinicopathological correlation ♦ Not for Medico Legal Purpose

e-mail : mpdcgn@gmail.com ♦ For online reports - www.modernpath.in

♦ Please ask for your computerized bill ♦ Pay only the printed collection charges

CLINIC :
1/4A, Vineet Khand, (Opp Jaipuria Management)
Gomti Nagar, Lucknow - 226 010
Ph.: 0522-4008184, 4308184 • 8112323230
Mob.: 7618884441, 9450389932, 8177063877

Date	: 29-Mar-2024		
Name	: Mr. DURGESH RAI	Age	: 37 Yrs.
Ref.By	: APOLLO HEALTH	Sex	: Male

Urine Examination

PHYSICAL			
Colour	Straw		
Turbidity	Nil		
Deposit	Nil		
Reaction	Acidic		
*Specific Gravity	1.015		
CHEMICAL			
- Protein	Nil		
Sugar	Nil		
*Bilc Salts	Nil		
*Bile Pigments	Nil		
Phosphate	Nil		
MICROSCOPIC			
Pus Cells	Nil		/hpf
Epithelial Cells	Occasional		/hpf
Red Blood Cells	Nil		/hpf
Casts	Nil		
Crystals	Nil		
Others	Nil		

Page 3
Dr. Sanjay Rastogi
M.B.B.S., DCP, CRIAT (BARC)

Dr. Smika Rastogi
Contd... M.B.B.S., DCP

Results, adhering to W.H.O. and International Federation of Clinical Chemists Quality Control Standards.

SAMPLE COLLECTION FACILITY AVAILABLE

Report needs clinicopathological correlation ♦ Not for Medico Legal Purpose

e-mail : mpdcgn@gmail.com ♦ For online reports - www.modernpath.in

♦ Please ask for your computerized bill ♦ Pay only the printed collection charges



MODERN PATHOLOGY & DIAGNOSTIC CENTRE

DIAGNOSTIC CENTRE

Dr. R. P. Rastogi
M.B.B.S., M.D. (Path & Bact)



CLINIC :

1/4A, Vineet Khand, (Opp Jaipuria Management)
Gomti Nagar, Lucknow - 226 010
Ph.: 0522-4008184, 4308184 • 8112323230
Mob.: 7618884441, 9450389932, 8177063877

Date	: 29-Mar-2024	Age	: 37 Yrs.
Name	: Mr. DURGESH RAI	Sex	: Male
Ref.By	: APOLLO HEALTH		

Glycosylated Haemoglobin	5.4	%	4.5 TO 6.0
INTERPRETATION AND COMMENTS			
<p>NON DIABETIC : 4.5 to 6.0 % GOOD CONTROL: 6.0 to 7.0 FAIR CONTROLLED 7.0 AND 8.0 UNCONTROLLED 8.0 AND ABOVE</p> <p>Glycosylated haemoglobin is the adducted glucose in the haemoglobin of the red blood cells, this adduction is stable for the life time of the RBC (i.e 120 days). There fore the measure of glycosylated haemoglobin reflects the average blood glucose concentration over the preseding several weeks. The sudden change in blood glucose level would not effect the glycosylated haemoglobin level ,which serves as a better marker of long term metabolic control and the efficacy of therapy.</p>			

Dr. **Sanjay Rastogi**
M.B.B.S., DCP, CRIAT (BARC)

Dr. Smita Rastogi
Contd... M.B.B.S., DCP

Results, adhering to W.H.O. and International Federation of Clinical Chemists Quality Control Standards.

SAMPLE COLLECTION FACILITY AVAILABLE

Report needs clinicopathological correlation ♦ Not for Medico Legal Purpose

e-mail : mpdcgn@gmail.com ♦ For online reports - www.modernpath.in

♦ Please ask for your computerized bill ♦ Pay only the printed collection charges



MODERN PATHOLOGY & DIAGNOSTIC CENTRE

DIAGNOSTIC CENTRE

Dr. R. P. Rastogi
M.B.B.S., M.D. (Path & Bact)



CLINIC :

1/4A, Vineet Khand, (Opp Jaipuria Management)
Gomti Nagar, Lucknow - 226 010
Ph.: 0522-4008184, 4308184 • 8112323230
Mob.: 7618884441, 9450389932, 8177063877

Date	: 29-Mar-2024	Age	: 37 Yrs.
Name	: Mr. DURGESH RAI	Sex	: Male
Ref.By	: APOLLO HEALTH		

THYROID TEST

Tri-iodothyronine (T3)	1.16	nmol/L	0.50 to 2.50
Thyroxine (T4)	5.50	mcg/dL	5.0 to 12.5
Thyroid Stimulating Hormone (TSH)	3.18	mlU/ ml	0.3 to 6.0

COMMENTS

- 1) Primary hyperthyroidism is accompanied by elevated Serum T3 and T4 values along with depressed TSH levels.
- 2) Primary Hypothyroidism is accompanied by depressed serum T3 and T4 values and elevated serum TSH levels.
- 3) Normal T4 levels accompanied by high T3 levels are seen in patients with T3 thyrotoxicosis.
- 4) Slightly elevated T3 levels may be found in pregnancy and esterogen therapy, while depressed levels maybe encountered in severe illness, malnutrition, renal failure and during therapy with drugs like propranolol and propylthiouracil.
- 5) Elevated TSH levels may also be indicative of TSH secreting Pituitary Tumour.

Dr. Sanjay Rastogi
M.B.B.S., DCP, CRIAT (BARC)

Dr. Smita Rastogi
M.B.B.S., DCP

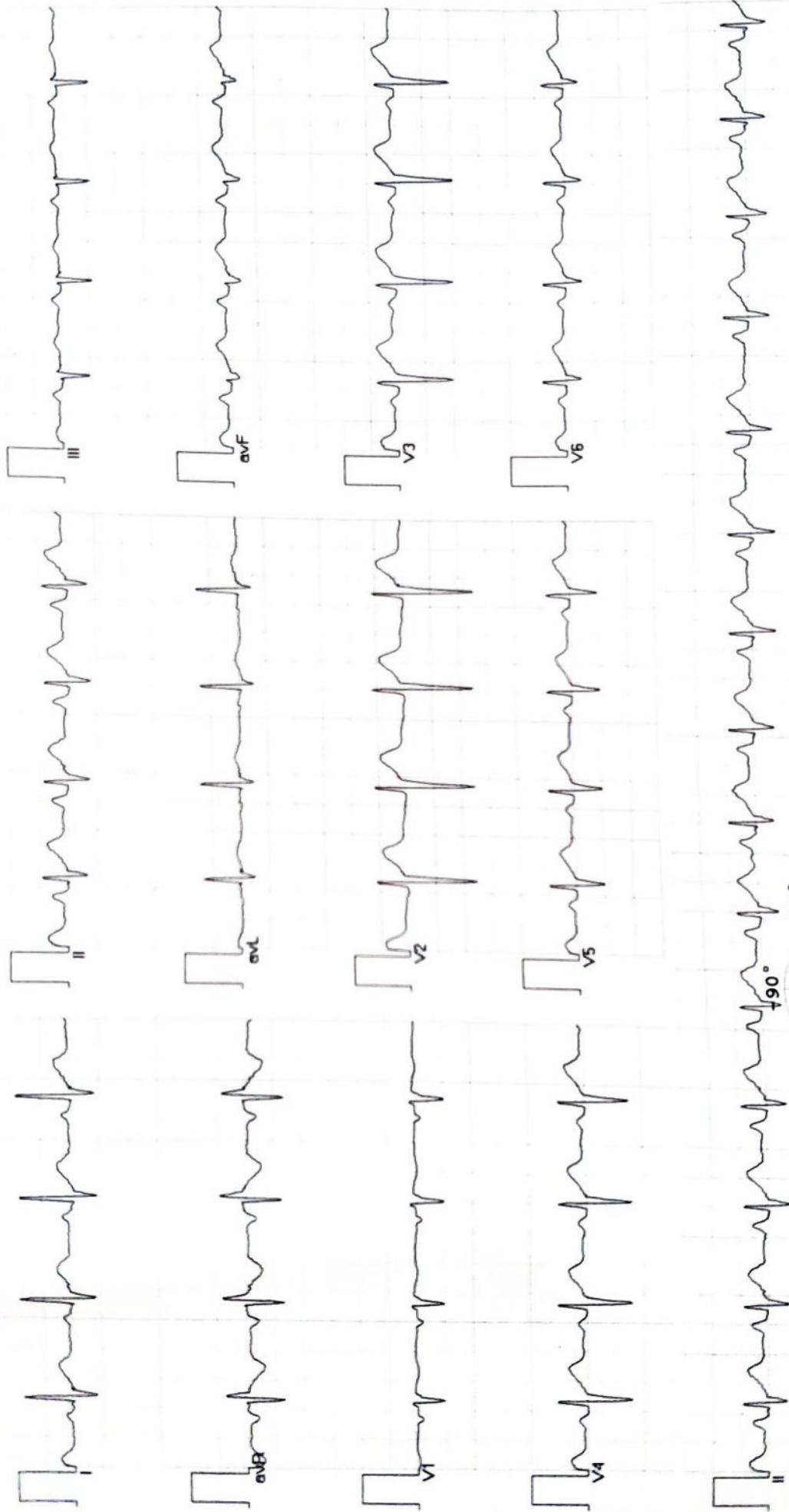
Results, adhering to W.H.O. and International Federation of Clinical Chemists Quality Control Standards.

SAMPLE COLLECTION FACILITY AVAILABLE

Report needs clinicopathological correlation ♦ Not for Medico Legal Purpose

e-mail : mpdcgn@gmail.com ♦ For online reports - www.modernpath.in

♦ Please ask for your computerized bill ♦ Pay only the printed collection charges



Vent Rate : 90 bpm
 PR Interval : 144 ms
 QR Duration: 84 ms
 QT/QTc Int : 344/395 ms
 P-QRS-T axis: 62.00° -13.00° 49.00°



Normal ECG

Aliengers ECG (Pisces)(PIS215191030)

Axis DR. ANANT MOHAN
 Reg. No. 24009

(Handwritten signature)



MODERN PATHOLOGY & DIAGNOSTIC CENTRE

Dr. R. P. Rastogi
M.B.B.S., M.D. (Path & Bact)



CLINIC :
1/4A, Vineet Khand, (Opp Jaipuria Management)
Gomti Nagar, Lucknow - 226 010
Ph.: 0522-4008184, 4308184 • 8112323130
Mob.: 7618884441, 9450389932, 8177068877



TEST REQUEST ID :012403290041	SAMPLE DATE	:29/Mar/2024 09:35AM
NAME :Mr. DURGESH RAI	SAMPLE REC. DATE	:29/Mar/2024 09:35AM
AGE/SEX :37 YRS/MALE	REPORTED DATE	:29/Mar/2024 12:08PM
REFERRED BY : Apollo Health and Lifestyle Limited,	BARCODE NO	:01290041

USG WHOLE ABDOMEN-MALE

Liver: is enlarged in size (157 mm). Parenchymal echogenicity is increased. No focal echovariant lesion is seen. Intrahepatic biliary radicles are not dilated.

Gall Bladder: is well distended. Lumen is anechoic. Wall is of normal thickness.

CBD: is normal in diameter. Portal vein is normal in diameter.

Pancreas: is normal in size, shape and echotexture. No focal echovariant lesion is seen. Pancreatic duct is not dilated.

Spleen: is normal in size (103 mm), shape and echotexture. No focal echovariant lesion is seen. Splenic vein is normal.

Both Kidneys: are normal in size (RK- 99 x 46 mm & LK -105 x 52 mm), shape, position and excursion. Parenchymal echogenicity and echotexture is normal with maintained corticomedullary differentiation. No mass, cyst or calculi is seen. Pelvicalyceal systems are not dilated. Ureters are not dilated.

Urinary bladder: is well distended. Lumen is anechoic. Wall is of normal thickness. No mass or calculus is seen.

Prostate: is normal in size (35 x 35 x 30 mms, wt = 19.9 gms), shape and echotexture. No focal echovariant lesion is seen. Prostatic capsule appears to be intact. Median lobe is not projecting in UB lumen. Both seminal vesicles appear normal.

Both iliac fossae are clear. No obvious bowel pathology is noted.
There is no free fluid in peritoneal cavity.

OPINION: HEPATOMEGALY WITH GRADE-1 FATTY LIVER

*** End Of Report ***

Dr. Sanjay Rastogi
M.B.B.S., DCP, CRIAT (BARC)

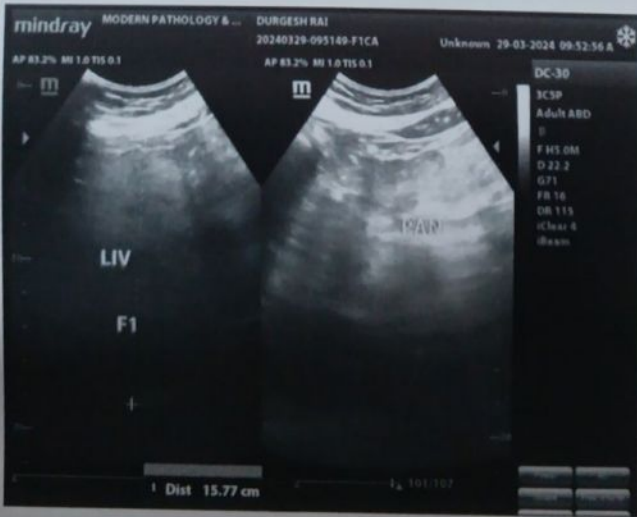
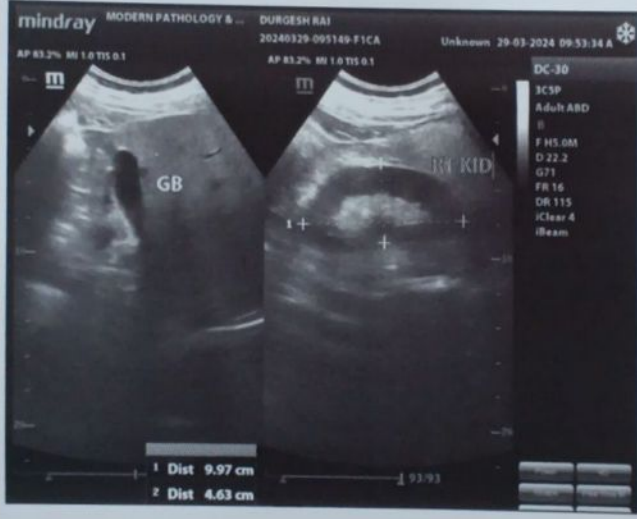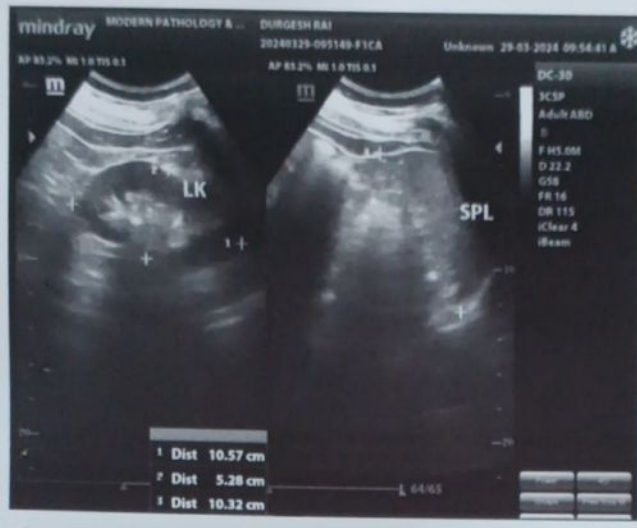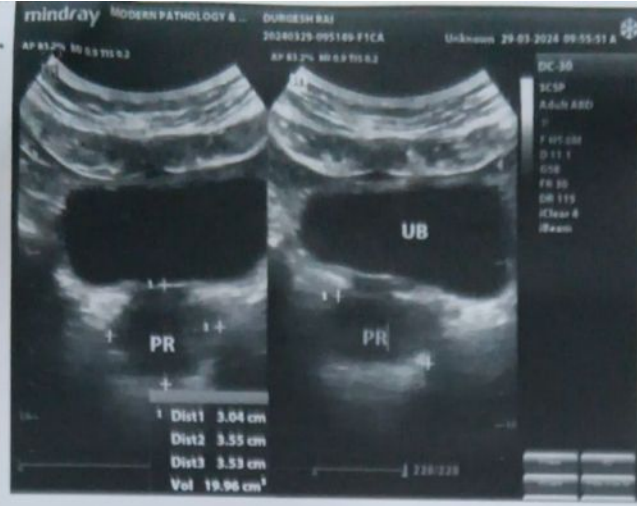Dr. Smita Rastogi
M.B.B.S., DCP

Results, adhering to W.H.O. and International Federation of Clinical Chemists Quality Control Standards.
SAMPLE COLLECTION FACILITY AVAILABLE

Report needs clinicopathological correlation ♦ Not for Medico Legal Purpose

e-mail : mpdcgn@gmail.com ♦ For online reports - www.modernpath.in

♦ Please ask for your computerized bill ♦ Pay only the printed collection charges





MODERN PATHOLOGY & DIAGNOSTIC CENTRE

Dr. R. P. Rastogi
M.B.B.S., M.D. (Path & Bact)



CLINIC :
1/4A, Vineet Khand, (Opp Jaipuria Management)
Gomti Nagar, Lucknow - 226 010
Ph.: 0522-4008184, 4308184 • 8112323230
Mob.: 7618884441, 9450389932, 8177063877



TEST REQUEST ID :012403290041	SAMPLE DATE	:29/Mar/2024 09:35AM
NAME :Mr. DURGESH RAI	SAMPLE REC. DATE	:29/Mar/2024 09:35AM
AGE/SEX :37 YRS/MALE	REPORTED DATE	:29/Mar/2024 01:36PM
REFERRED BY : Apollo Health and Lifestyle Limited,	BARCODE NO	:01290041

XRAY CHEST PA

- Trachea is central in position.
- Bilateral lung fields are normally aerated.
- Both hilar shadows are normal.
- Both C.P. angles are clear.
- Cardiac shadow is within normal limits.
- Bony cage appears normal.

OPINION: NORMAL STUDY.

Please correlate clinically.

*** End Of Report ***

Dr. Sanjay Rastogi
M.B.B.S., DCP, CRIAT (BARC)

DR. PANKAJ UPADHYAYA

Dr. Smita Rastogi
M.B.B.S., DCP

Results, adhering to W.H.O. and International Federation of Clinical Chemists Quality Control Standards.

D.M.B.D.
Consultant Radiologist

Report needs clinicopathological correlation ♦ Not for Medico Legal Purpose

Print Date/Time: 29/03/2024 1:50 PM e-mail : mpdcgn@gmail.com ♦ For online reports - www.modernpath.in

♦ Please ask for your computerized bill ♦ Pay only the printed collection charges

MODERN PATHOLOGY AND DIAGNOSTIC CENTER

Gomti Nagar Lucknow

Report



DURGESH RAI / 37 Yrs / M / 172 Cms / 78 Kg

Date: 29 - 03 - 2024 Refd By : APOLLO HEALTH Examined By:

Stage	Time	Duration	Speed(Kmph)	Elevation	METS	Rate	% THR	BP	RPP	PVC	Comments
Supine	00:03	0:03	00.0	00.0	01.0	094	51 %	126/86	118	00	
Standing	00:07	0:04	00.0	00.0	01.0	094	51 %	126/86	118	00	
HV	00:11	0:04	00.0	00.0	01.0	096	52 %	126/86	120	00	
ExStart	00:23	0:12	00.0	00.0	01.0	100	55 %	126/86	126	00	
BRUCE Stage 1	03:23	3:00	02.7	10.0	04.7	145	79 %	134/90	194	00	
BRUCE Stage 2	06:23	3:00	04.0	12.0	07.1	169	92 %	140/94	236	00	
PeakEx	06:27	0:04	00.0	00.0	07.2	170	93 %	144/96	244	00	
Recovery	07:27	1:00	00.0	00.0	01.2	156	85 %	140/92	218	00	
Recovery	08:27	2:00	00.0	00.0	01.0	130	71 %	136/90	176	00	
Recovery	09:27	3:00	00.0	00.0	01.0	124	68 %	132/86	163	00	
Recovery	09:56	3:30	00.0	00.0	01.0	120	66 %	128/86	153	00	

FINDINGS :

Exercise Time : 06:04
 Max HR Attained : 170 bpm 93% of Target 183
 Max BP Attained : 144/96 (mm/Hg)
 Max WorkLoad Attained : 7.2 Fair response to induced stress

Test End Reasons : Test Complete

REPORT :

CONCLUSIONS:

1. STRESS TEST IS NEGATIVE FOR EXERCISE INDUCED ISCHAEMIC HEART DISEASE.

Dr. Anamika Jaiswal
 DR. ANAMIKA JAISWAL
 MID
 Reg. No. AA659

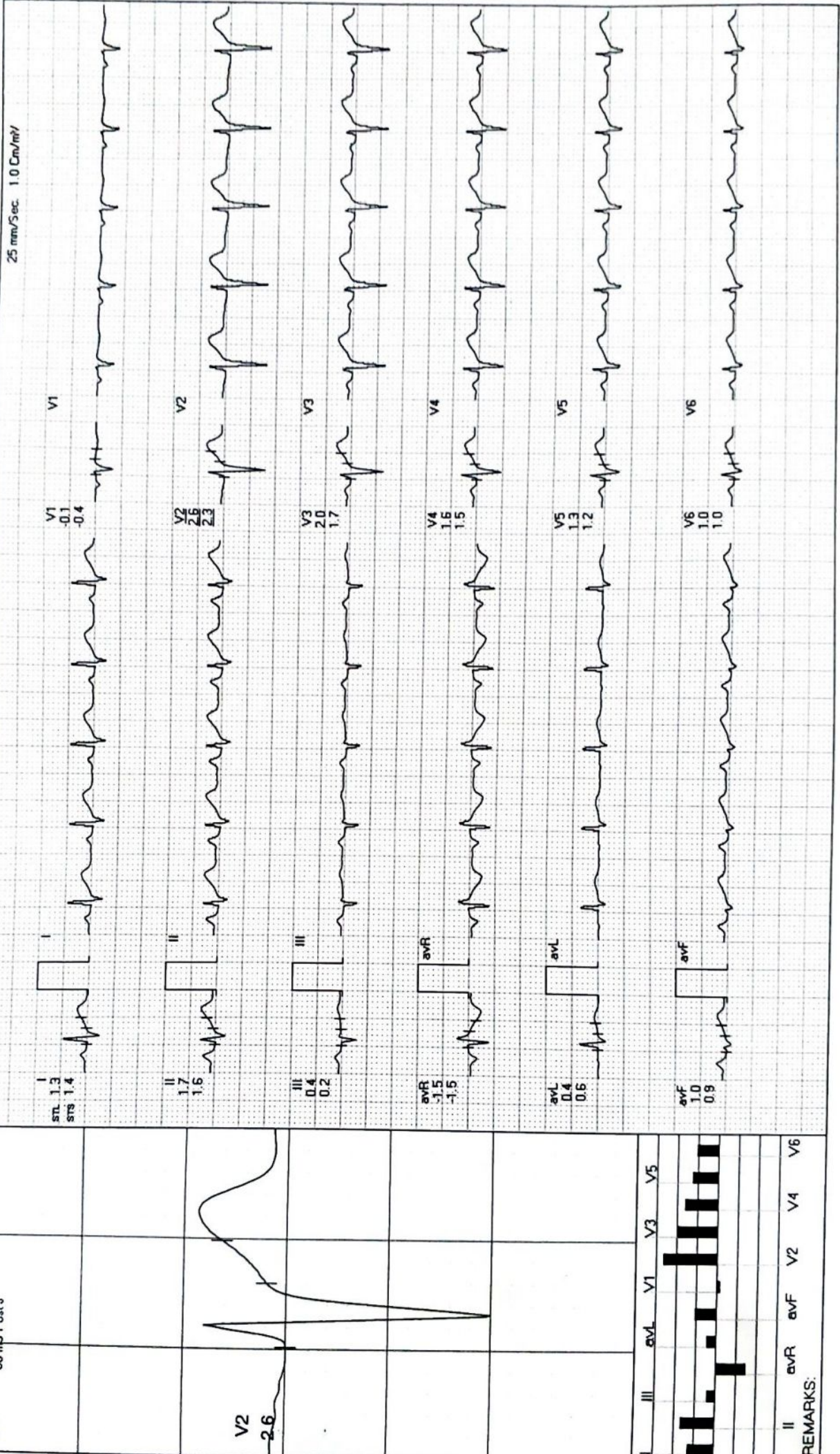
MODERN PATHOLOGY AND DIAGNOSTIC CENTER

DURGESH RAI / 37 Yrs / M / 172 Cms / 78 Kg / HR : 94

BRUCE:Supine(0:05)



Date: 29-03-2024 METS: 1.0/ 94 bpm 51% of THR BP: 126/86 mmHg Combined Medians/ BLC On/ Notch On/ HF 0.05 Hz/LF 35 Hz ExTime 00:00 0.0 Kmph. 0.0%



REMARKS:

MODERN PATHOLOGY AND DIAGNOSTIC CENTER

DURGESH RAI / 37 Yrs / M / 172 Cms / 78 Kg / HR : 94

BRUCE: Standing(0:04)

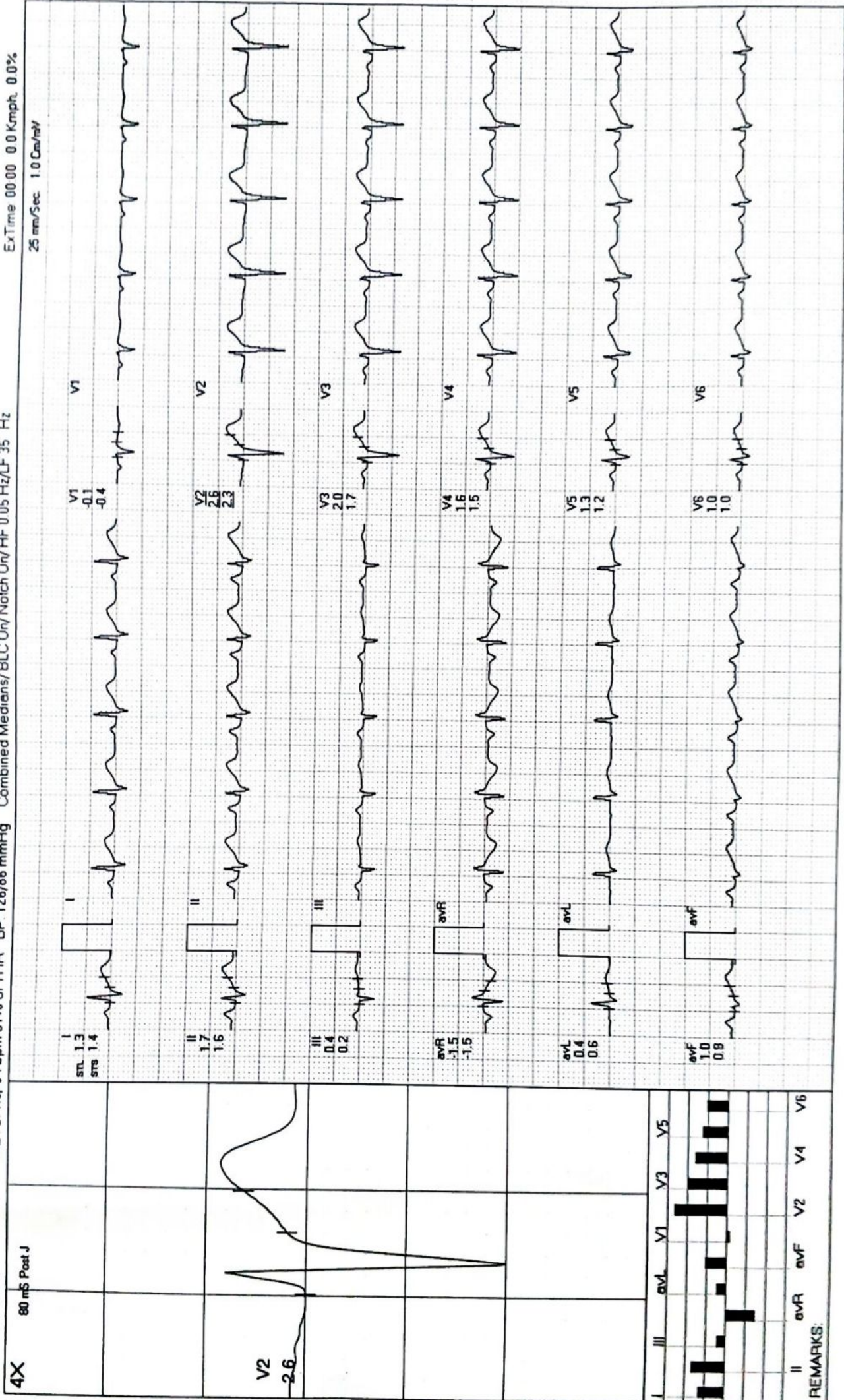


Date: 29-03-2024

METS 1.0 / 94 bpm 51% of THR BP: 126/86 mmHg Combined Medians/BLC On/Notch On/HF 0.05 Hz/LF 35 Hz

ExTime 00:00 0.0 Kmph. 0.0%

25 mm/Sec 1.0 Cm/mV



Lead	I	II	III	aVR	aVL	aVF	V1	V2	V3	V4	V5	V6
ST-T												

REMARKS:

MODERN PATHOLOGY AND DIAGNOSTIC CENTER

DURGESH RAI / 37 Yrs / M / 172 Cms / 78 Kg / HR : 96

BRUCE:HV(0:06)

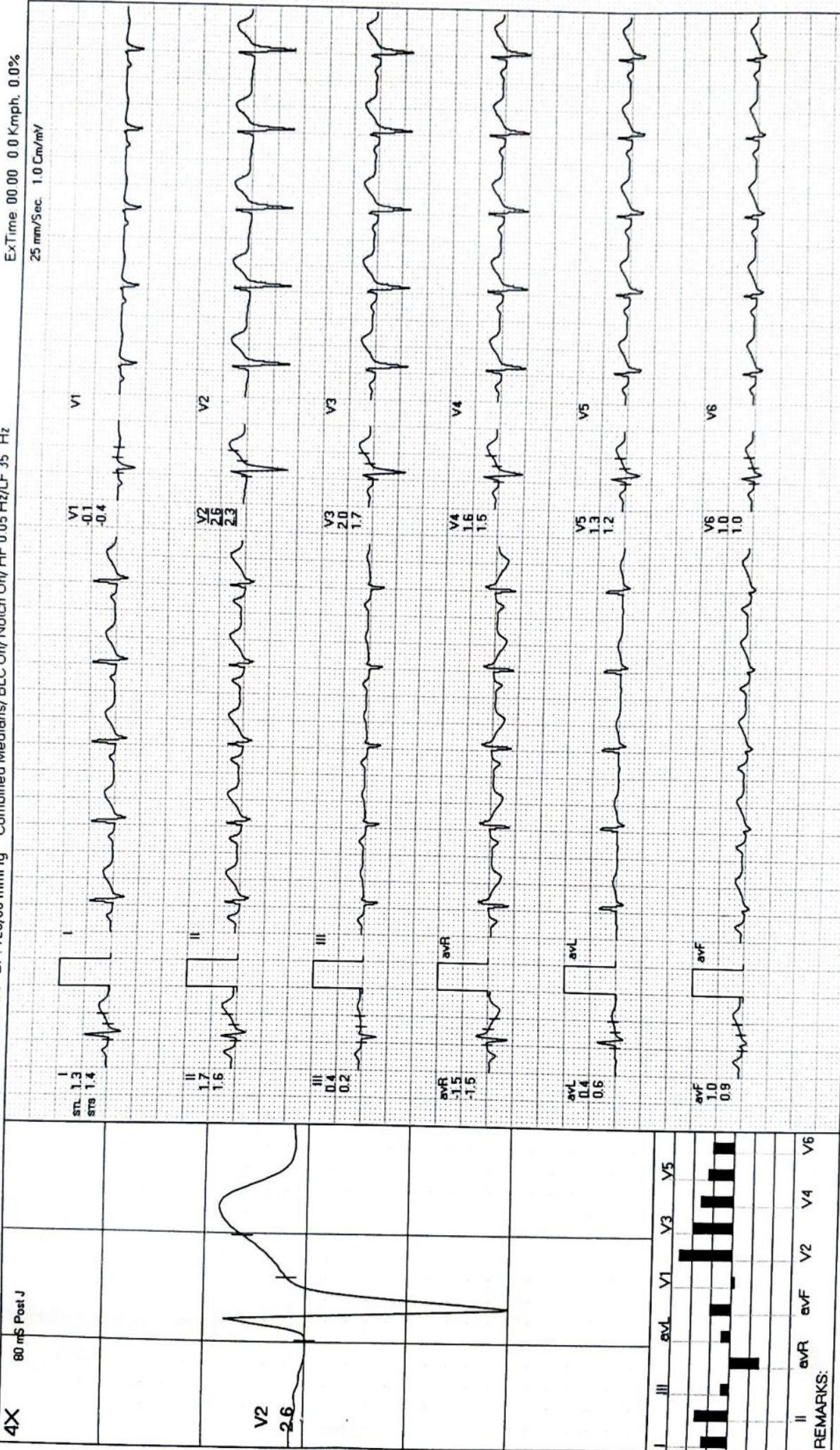


Date: 29 - 03 - 2024

METS: 1.0/96 bpm 52% of THR BP: 126/86 mmHg Combined Medians/BLC On/ Notch On/HF 0.05 Hz/LF 35 Hz

ExTime 00:00 0.0 Kmph, 0.0%

25 mm/Sec. 1.0 Cm/mV



4X 80 mB Post J

V2 2.6


III aVL V1 V3 V5

II aVR aVF V2 V4 V6

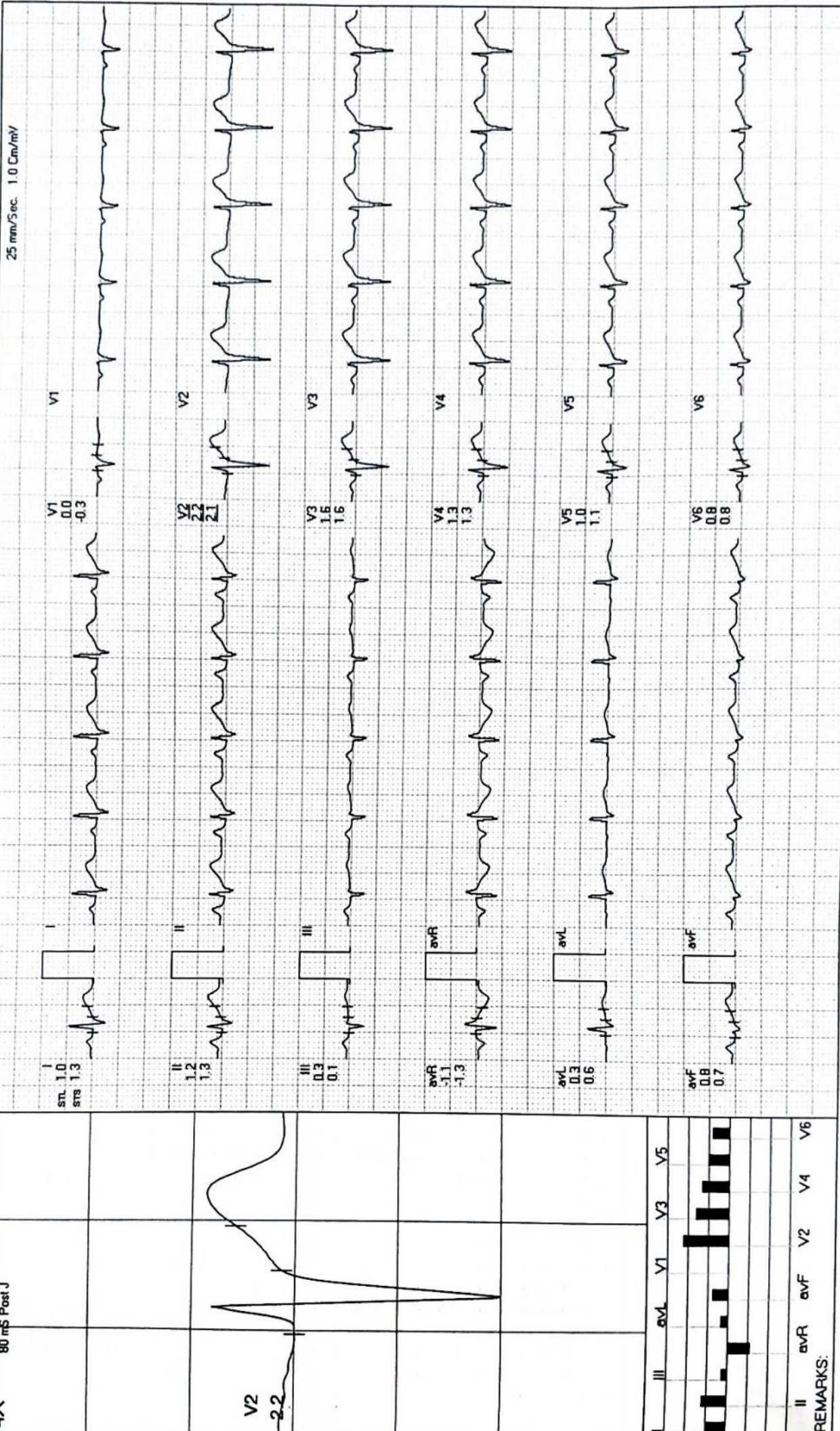
REMARKS:

MODERN PATHOLOGY AND DIAGNOSTIC CENTER

DURGESH RAI / 37 Yrs / M / 172 Cms / 78 Kg / HR : 100



Date: 29 - 03 - 2024 METS: 1.0/100 bpm 55% of THR BP: 126/86 mmHg Combined Medians/BLC On/ Notch On/ HF 0.05 Hz/LF 35 Hz
 4X 80 mS Post J ExTime 00:00 0.0 Km/h, 0.0%
 25 mm/Sec. 1.0 Cm/mV



REMARKS:
 I II III aVR aVL aVF V1 V2 V3 V4 V5 V6

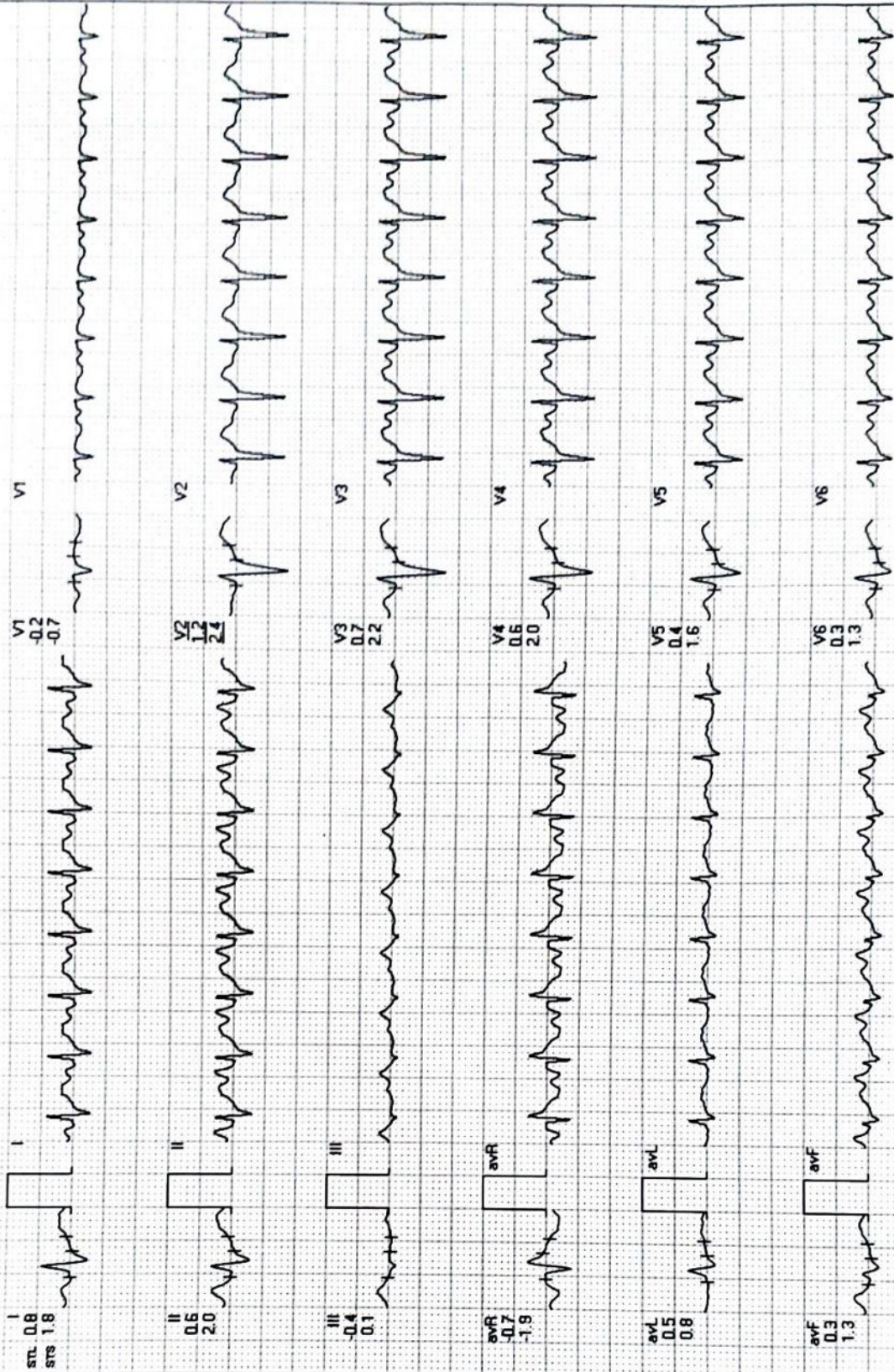MODERN PATHOLOGY AND DIAGNOSTIC CENTER

DURGESH RAI / 37 Yrs / M / 172 Cms / 78 Kg / HR : 145

BRUCE: Stage 1(3:00)



Date: 29-03-2024 METS: 4.7/145 bpm 79% of THR BP: 134/90 mmHg Combined Medians/BLC On/Notch On/HF 0.05 Hz/LF 35 Hz ExTime: 03:00 2.7 Km/h 10.0%
 4X 60 mS Post J 25 mm/Sec. 1.0 Cm/mV



Lead	ST (mV)	T (mV)
I	0.8	1.8
II	0.6	2.0
III	-0.4	0.1
avR	-0.7	-1.9
avL	0.5	0.8
avF	0.3	1.3
V1	-0.2	-0.7
V2	1.2	2.2
V3	0.7	2.2
V4	0.6	2.0
V5	0.4	1.6
V6	0.3	1.3

REMARKS:

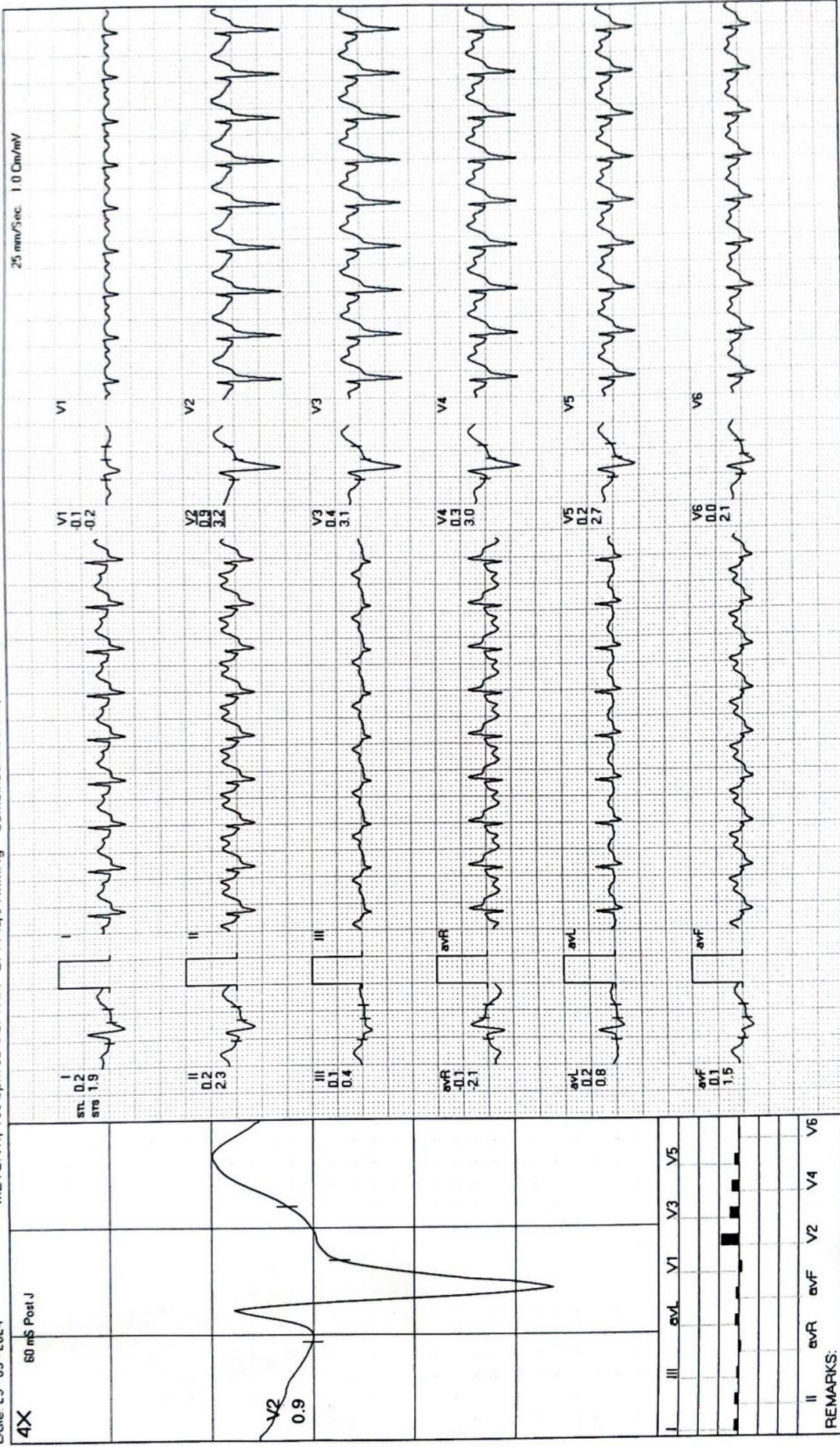
MODERN PATHOLOGY AND DIAGNOSTIC CENTER

DURGESH RAI / 37 Yrs / M / 172 Cms / 78 Kg / HR : 169

BRUCE: Stage 2(3:00)



Date: 29-03-2024 METS: 7.1/169 bpm 92% of THR BP: 140/94 mmHg Combined Medians/BLC On/Notch On/HF 0.05 Hz/LF 35 Hz ExTime: 06:00 4.0 Kmph. 12.0%
 4X 60 mS Post J 25 mm/Sec. 1.0 Cm/mV



REMARKS:

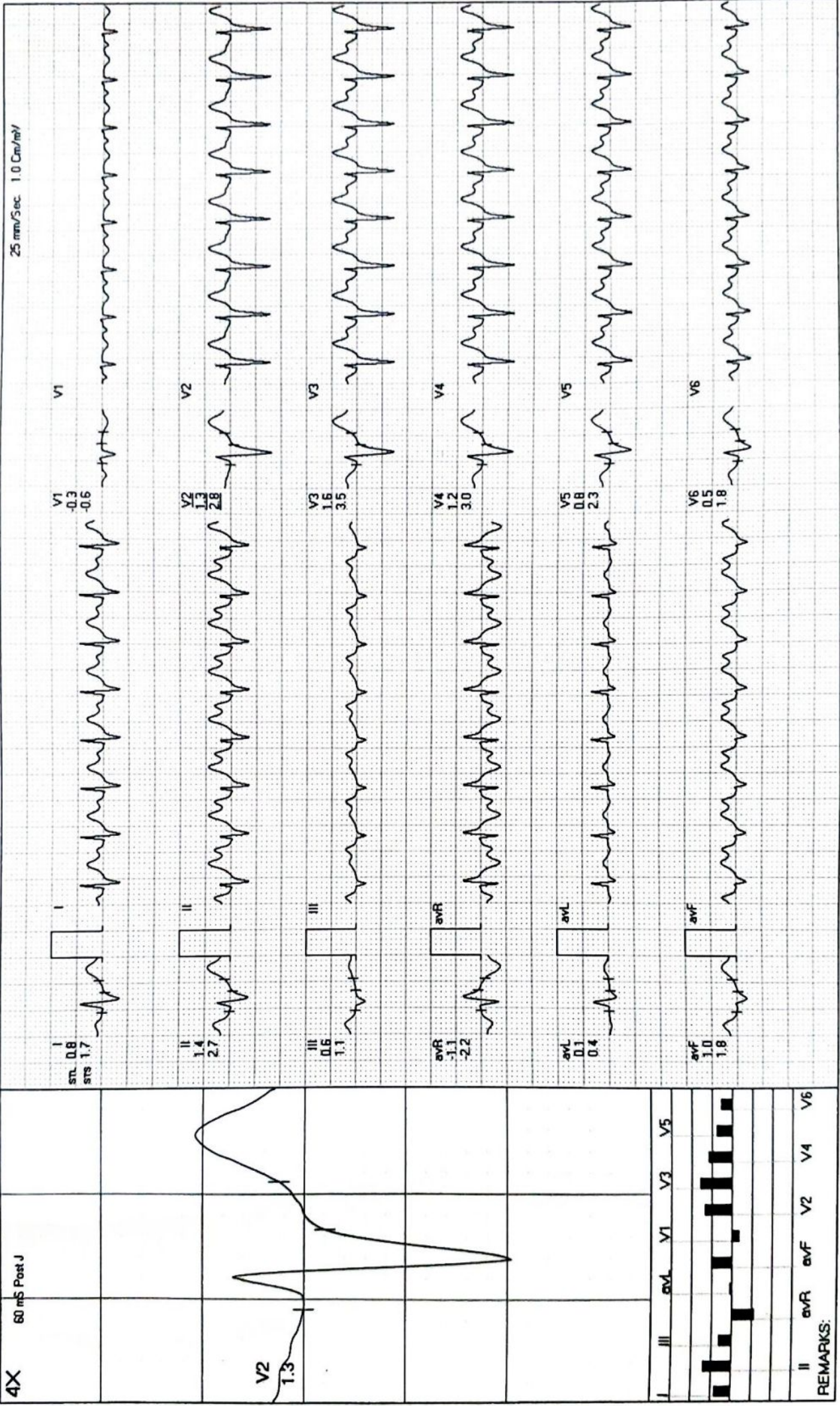
MODERN PATHOLOGY AND DIAGNOSTIC CENTER

DURGESH RAI / 37 Yrs / M / 172 Cms / 78 Kg / HR : 156

Recovery(1:00)



Date: 29-03-2024 METS: 1.2/156 bpm 85% of THR BP: 140/92 mmHg Combined Medians/BLC On/Notch On/HF 0.05 Hz/LF 35 Hz ExTime 06:04 0.0 Kmph 0.0%



REMARKS:

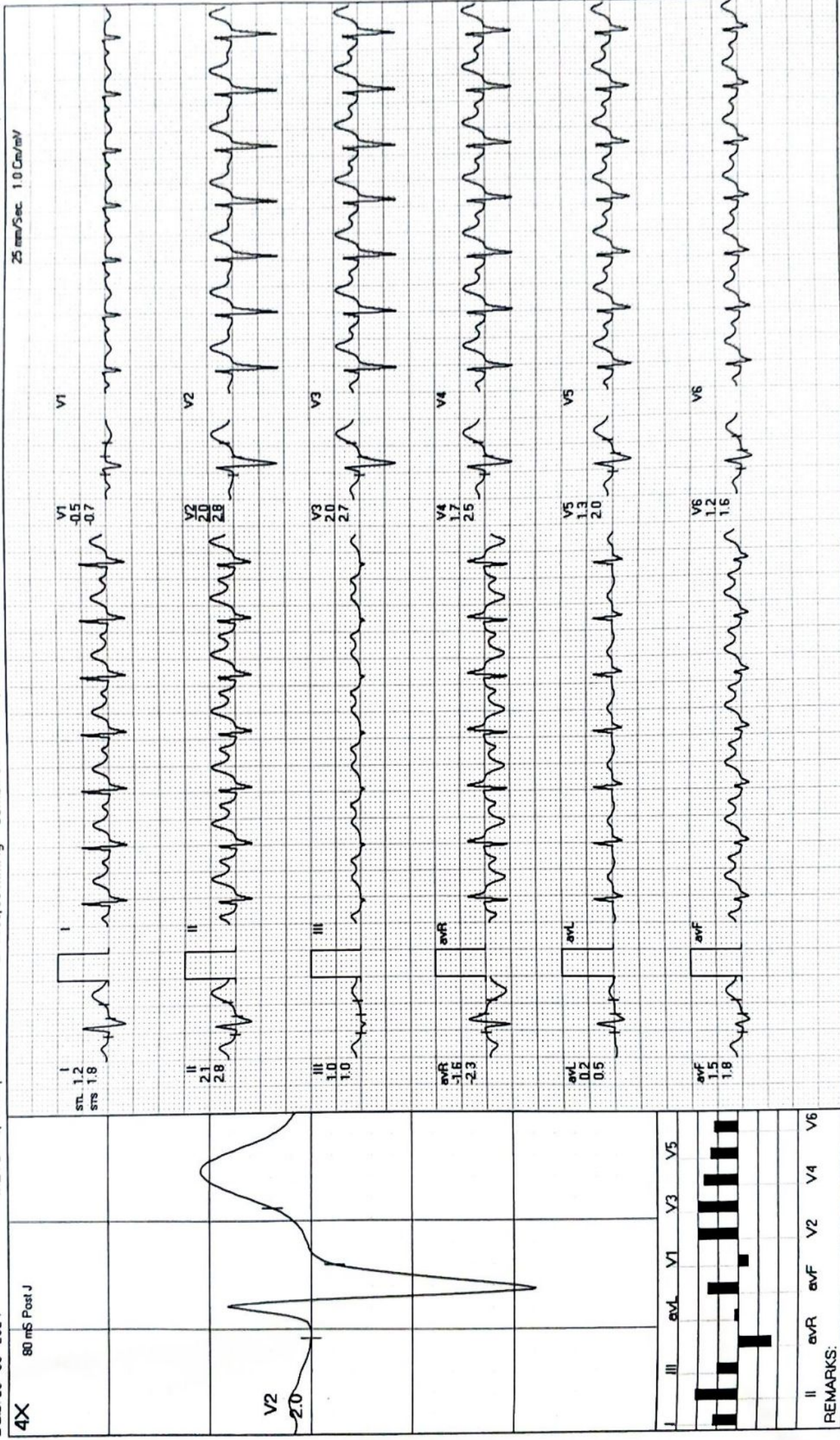
MODERN PATHOLOGY AND DIAGNOSTIC CENTER

DURGESH RAI / 37 Yrs / M / 172 Cms / 78 Kg / HR : 130

Recovery(2:00)



Date: 29-03-2024 METS 1 0/130 bpm 71% of THR BP: 136/90 mmHg Combined Medians/BLC On/ HF 0.05 Hz/LF 35 Hz ExTime 06:04 0.0 Kmph. 0.0%

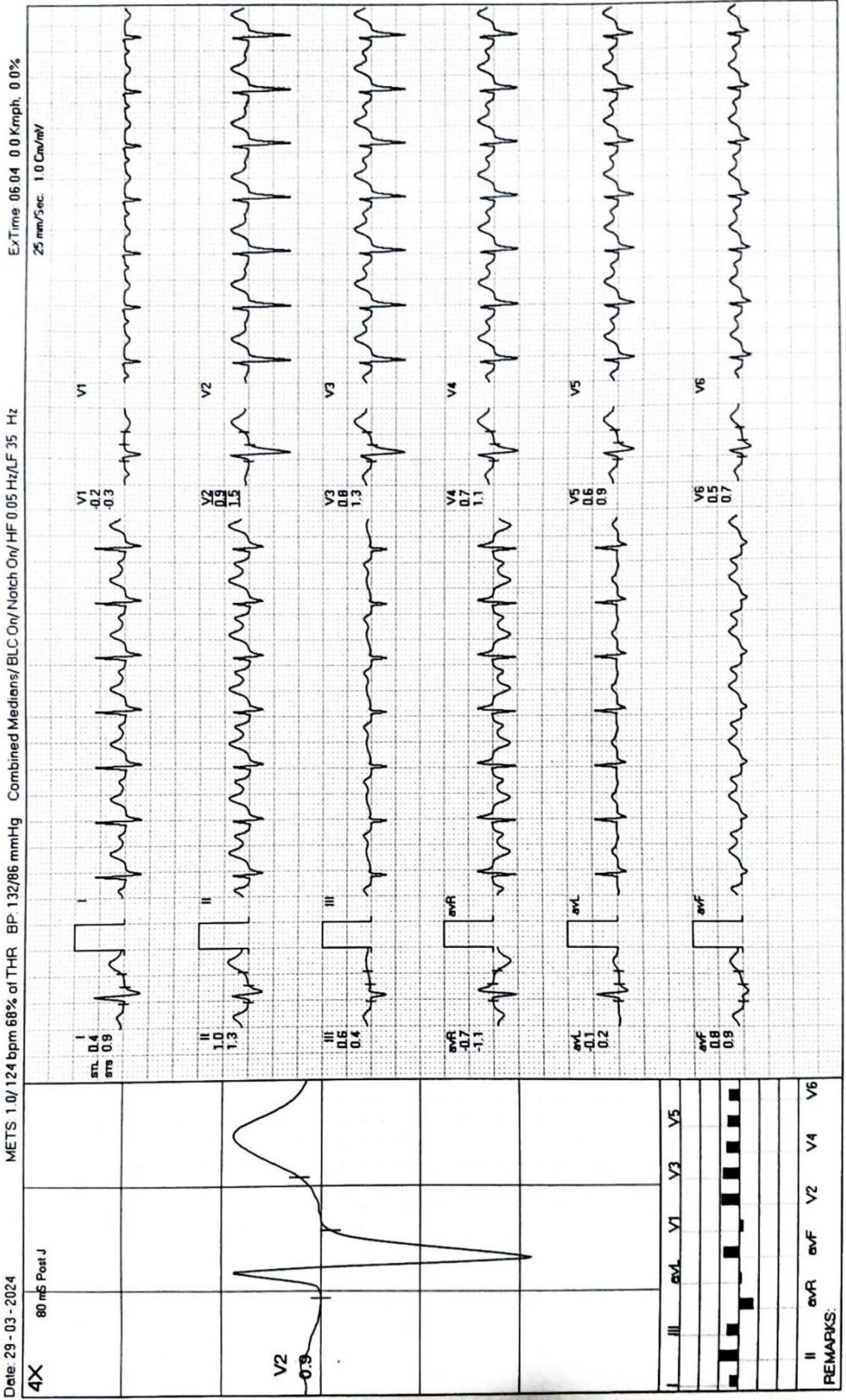


REMARKS:

MODERN PATHOLOGY AND DIAGNOSTIC CENTER

DURGESH RAI / 37 Yrs / M / 172 Cms / 78 Kg / HR : 124

Recovery(3:00)



REMARKS:

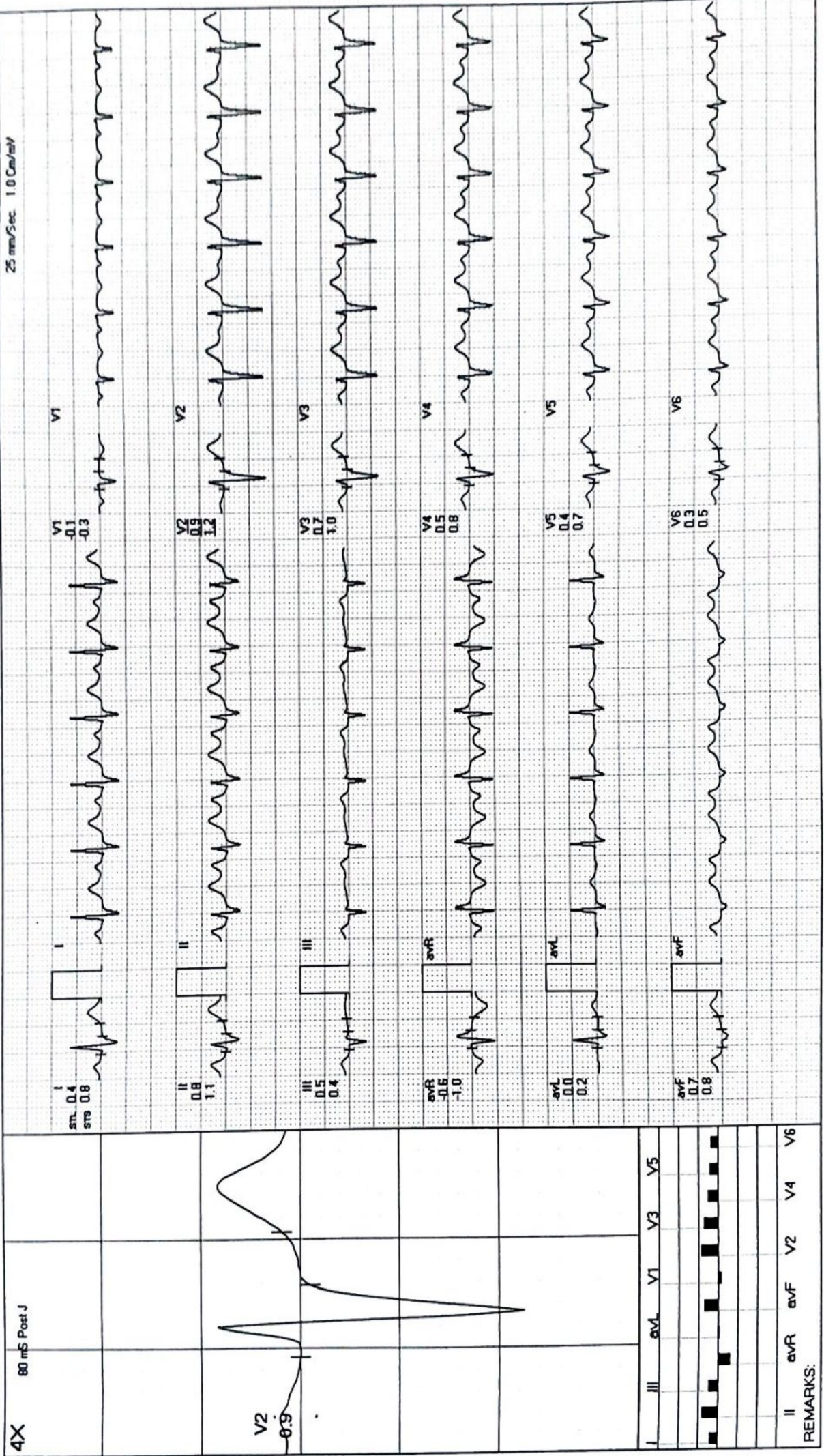


Recovery(3:30)

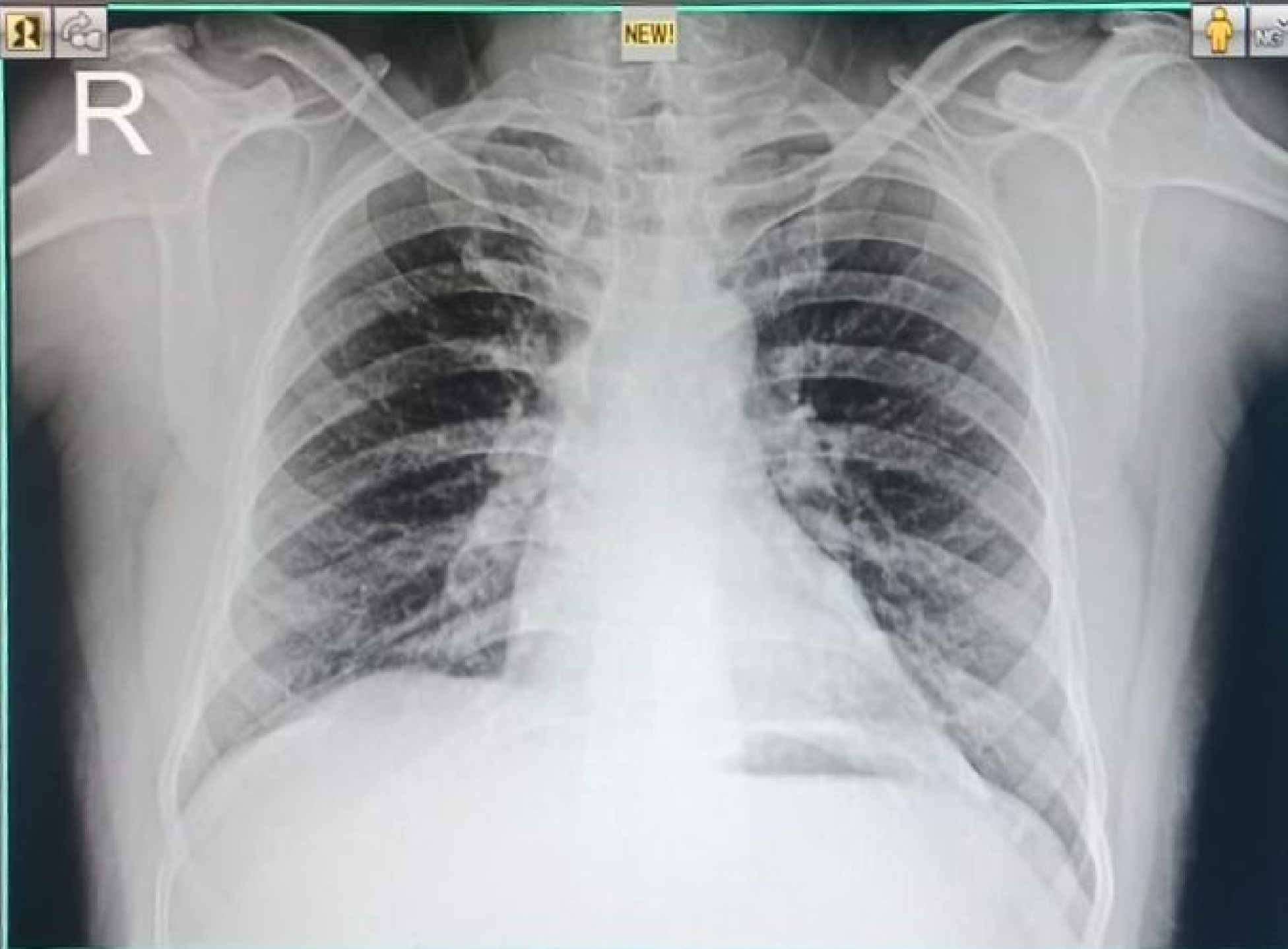MODERN PATHOLOGY AND DIAGNOSTIC CENTER

DURGESH RAI / 37 Yrs / M / 172 Cms / 78 Kg / HR : 120

Date 29-03-2024 METS 1.0/120 bpm 66% of THR BP: 128/86 mmHg Combined Medians/BLC On/ HF 0.05 Hz/LF 35 Hz ExTime 06:04 0.0 Km/ph. 0.0% 25 mm/Sec. 1.0 Cm/box



REMARKS:



24032903995 MR DURGESH RAI 37 YRS M DR SELF CHEST PA
03/29/2024 MODERN PATHOLOGY & DIAGNOSTIC CENTRE GOMTI NAGAR LUCKNOW