

**HEALTH CHECK UP**

Name : Chirag Kulkarni

Date : 13/4/24

Age : 33

Sex : Male / Female

Marital status : Married / Single

**PERSONAL HISTORY**

Habits : Smoking / Tobacco & Snuff / Alcohol No

Drug allergy if any : .....

Medical : ..... Nil

Surgical : .....

Height 170 cm Weight 82 Kg. BP 120/80 mmHg Pulse 72

Vision : Rt 6/24 Lt 6/24 With Spectacles ..... Rt 6/6 Lt 6/6

Colour Vision : Normal / Abnormal Near Vision MC, RE

**FAMILY HISTORY**

Father ..... Mother ..... Siblings .....

CVS : Heart Sound ..... Normal Murmurs ..... Absent Thrills ..... Absent

RS : Rate ..... /mt Breath sounds ..... Normal Adventitious ..... Absent

ABDOMEN : Tenderness ..... Absent Rigidity ..... Absent Bowel sound ..... Normal

Liver ..... NAD Kidney ..... NAD Hernia ..... Absent

CNS : Cranial Nerves ..... NAD Sensory System ..... NAD Motor System ..... NAD

ENT ..... NAD

Remarks

Dr. Bharti Jeswani  
MBBS

Dr. Seema Kale  
MBBS, MD

Dr. S. K. Suri  
MBBS

Dr. Meenakshi  
MBBS

HOME SAMPLE COLLECTION FACILITY AVAILABLE

Licensee : Bharti Medicare Pvt. Ltd. The Apollo Clinic, C-70, Major Sudesh Kumar Marg, Opp. Madhav Park, Near Main Market, Rajouri Garden, New Delhi-110 027  
Phone : (011) 2591 8222 / 8333 / 8444, ☎ 9811061009, E-mail : rajourigarden@theapolloclinic.com, Website : www.apolloclinicrajourigarden.com

MSME UAM NO. : DL11E0021531

Fw: Health Check up Booking Confirmed Request(bobE18424),Package Code-  
PKG10000474, Beneficiary Code-294506

CHIRAG KALRA <kalra.chirag@rediffmail.com>

Fri 12-Apr-24 5:33 PM

To:Nirman Bhavan Branch, South Delhi Region <NIRDEL@bankofbaroda.com>

You don't often get email from kalra.chirag@rediffmail.com. [Learn why this is important](#)

को नहीं जानते तो मेल में दी गयी लिंक पर क्लिक ना करें या अटैचमेंट ना खोलें.  
THE BANK'S DOMAIN. DO NOT CLICK ON LINKS OR OPEN ATTACHMENTS UNLESS YOU KNOW

From: wellness@mediwheel.in

Sent: Wed, 10 Apr 2024 18:15:42

To: kalra.chirag@rediffmail.com

Cc: customercare@mediwheel.in

Subject: Health Check up Booking Confirmed Request(bobE18424),Package Code-PKG10000474,  
Beneficiary Code-294506

MedSave

011-41195959

Dear **Chirag kalra,**

We are pleased to confirm your health checkup booking request with the following details.

**Hospital Package Name** : Mediwheel Full Body Health Checkup Male Below 40

**Patient Package Name** : Mediwheel Full Body Health Checkup Male Below 40

**Name of Diagnostic/Hospital** : Apollo Bharti Apollo Bharti Medicare Pvt. Ltd.

**Address of Diagnostic/Hospital-** : C70, Opp. Madhav Park, Major Sudesh Kumar Marg -110027

**City** : Delhi

**State** : DELHI

**Pincode** : 110027

ID: 159

chirag kalra

Male 33Years

170cm 82kg 120/80 mmHg

Req. No. :

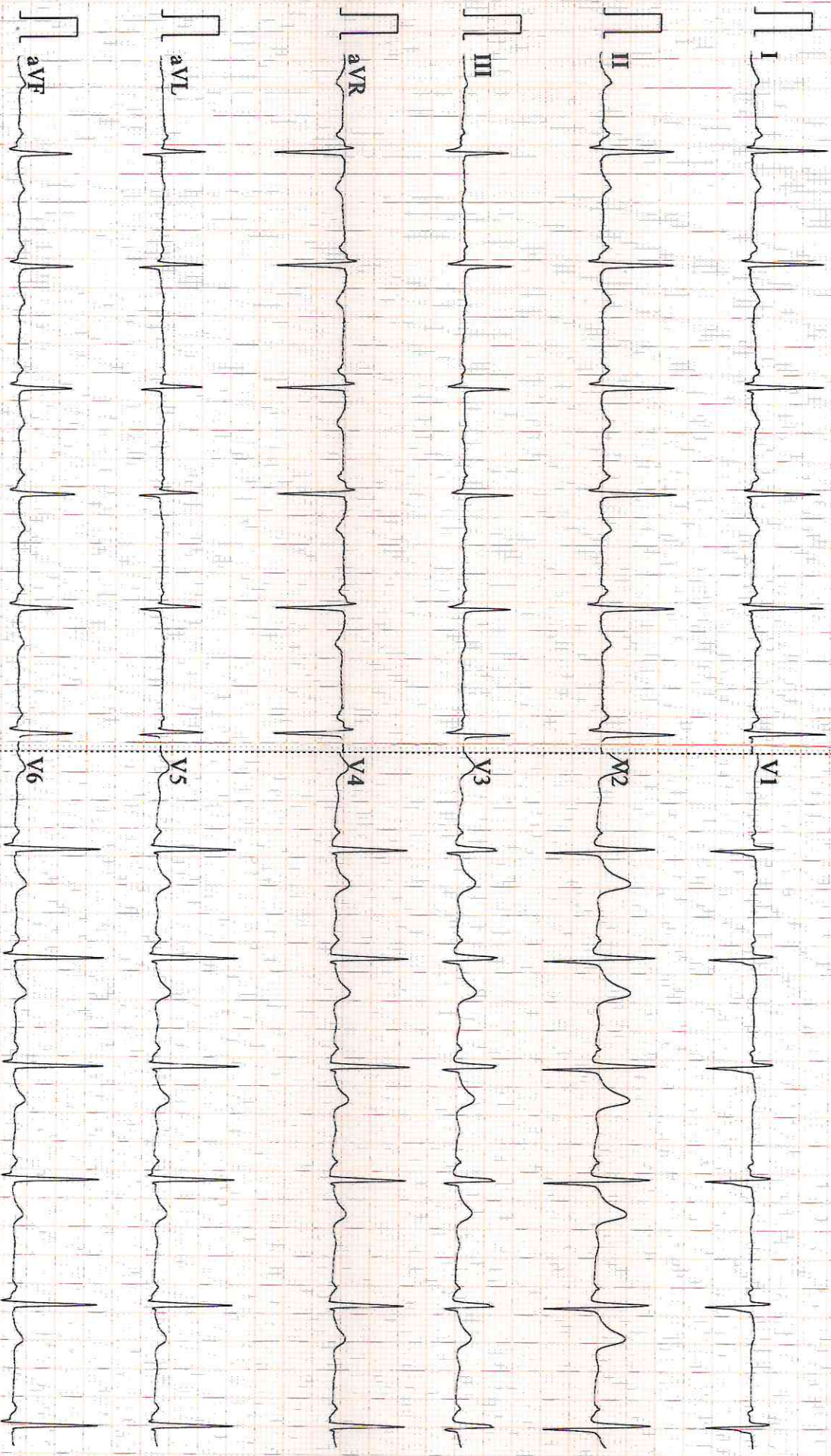
Room No. : 5

13-04-2024 09:45:31

HR	: 72	bpm
P	: 106	ms
PR	: 126	ms
QRS	: 86	ms
QT/QTcBz	: 386/423	ms
P/QRS/T	: 49/49/50	°
RV5/SV1	: 1.403/0.766	mV

Diagnosis Information:  
Sinus rhythm  
Normal ECG

Report Confirmed by:



I am not interested in giving the stool sample

Chirag  
13/04/2024  
Chirag Kalra

• CLINICAL CORRELATION IS ESSENTIAL FOR FINAL DIAGNOSIS. • IF THE TESTS RESULTS ARE UNEXPECTED PLEASE CONTACT THE LABORATORY.  
• ALL THE CONGENITAL ANOMALIES IN THE FETUS MAY NOT BE DIAGNOSED IN ULTRASONOGRAPHY. • THIS REPORT IS NOT VALID FOR MEDICOLEGAL PURPOSE.

Licensee : Bharti Medicare Pvt. Ltd. The Apollo Clinic, C-70, Major Sudesh Kumar Marg, Opp. Madhav Park, Near Main Market, Rajouri Garden, New Delhi-110 027  
Phone : (011) 2591 8222 / 8333 / 8444, 📞 9811061009, E-mail : rajourigarden@theapolloclinic.com, Website : www.apolloclinicrajourigarden.com

**MSME UAM NO. : DL11E0021531**

**Patient Name** : Mr. Chirag Kalra  
**UHID/MR No.** : FRAJ.0000245726  
**Visit Date** : 13-04-2024 09:01  
**Sample Collected on** : 13-04-2024 09:06  
**Sample No** : WHB1404110  
**Ref Doctor** : SELF  
**Emp/Auth/TPA ID** : 451582  
**Sponsor Name** : MEDIWHEELS HEALTH CARE

**Age / Gender** : 33Y/Male  
**OP Visit No** : FRAJOPV121281  
**Reported on** : 13-04-2024 14:20  
**Specimen** : Whole Blood (Edta)  
**Pres Doctor:** :


**DEPARTMENT OF LABORATORY MEDICINE**

TEST NAME	RESULT	BIOLOGICAL REFERENCE INTERVALS	UNITS
<b>COMPLETE BLOOD COUNT</b>			
Hb (Haemoglobin) Method: Non Cyanide	13.9	13 - 18	gm/dl
PCV/Haematocrit Method: RBC pulse height detect	45.7	40 - 50	%
ESR. Method: Westergren's Method	08	0 - 20	mm/1st Hr
TLC Method: DC Detection Method	6300	4000 - 10000	/cumm.
RBC COUNT. Method: DC Detection Method	4.67*	5 - 6	Million/cmm
PLATELET COUNT Method: DC Detection Method	2.68	1.5 - 4.1	lakh/cumm.
MCV Method: Derived	97.8	77 - 98	fl
MCH Method: Derived	29.7	27 - 32	pg
MCHC Method: Derived	30.3*	31.5 - 34.5	gm/dl
NEUTROPHIL Method: Microscopy	57	40 - 70	%
LYMPHOCYTE Method: Microscopy	36	20 - 40	%
EOSINOPHIL Method: Microscopy	04	1.0 - 6.0	%
MONOCYTE Method: Microscopy	03	2.0 - 10.0	%
<b>BLOOD GROUP AND RH TYPE</b>			
ABO Group	B		
RH	Positive		

**End of the report**

*Results are to be correlated clinically*

Lab Technician / Technologist  
Yogita

  
Dr. Prashant Purwar  
MBBS, DCP  
Consultant Pathologist

• CLINICAL CORRELATION IS ESSENTIAL FOR FINAL DIAGNOSIS. • IF THE TESTS RESULTS ARE UNEXPECTED PLEASE CONTACT THE LABORATORY.  
 • ALL THE CONGENITAL ANAMOLIES IN THE FETUS MAY NOT BE DIAGNOSED IN ULTRASONOGRAPHY. • THIS REPORT IS NOT VALID FOR MEDICOLEGAL PURPOSE.

Licensee : Bharti Medicare Pvt. Ltd. The Apollo Clinic, C-70, Major Sudesh Kumar Marg, Opp. Madhav Park, Near Main Market, Rajouri Garden, New Delhi-110 027  
 Phone : (011) 2591 8222 / 8333 / 8444, 9811061009, E-mail : rajourigarden@theapolloclicin.com, Website : www.apolloclicinrajourigarden.com

**MSME UAM NO. : DL11E0021531**

**Patient Name** : Mr. Chirag Kalra  
**UHID/MR No.** : FRAJ.0000245726  
**Visit Date** : 13-04-2024 09:01  
**Sample Collected on** : 13-04-2024 10:20  
**Sample No** : PLF1340282  
**Ref Doctor** : SELF  
**Emp/Auth/TPA ID** : 451582  
**Sponsor Name** : MEDIWHEELS HEALTH CARE

**Age / Gender** : 33Y/Male  
**OP Visit No** : FRAJOPV121281  
**Reported on** : 14-04-2024 10:31  
**Specimen** : Plasma(Fluoride)  
**Pres Doctor:** :


**DEPARTMENT OF LABORATORY MEDICINE**

TEST NAME	RESULT	BIOLOGICAL REFERENCE INTERVALS	UNITS
<b>GLUCOSE - ( FASTING )</b>			
GLUCOSE - ( FASTING ) Method: (GOD-POD).	88	70 - 110	mg/dL
<b>GLUCOSE - ( POST PRANDIAL )</b>			
GLUCOSE - ( POST PRANDIAL ) Method: (GOD-POD)	135	70-140	mg/dl
<b>GLYCOSYLATED HEMOGLOBIN (HBA1C)</b>			
GLYCOSYLATED HEMOGLOBIN (HBA1C) - WHOLE BLOOD Method: BORONATE AFFINITY	5.4	4.2 - 6.0	%
<b>LIPID PROFILE TEST (PACKAGE)</b>			
CHOLESTEROL Method: CHOD - PAP	157	Desirable < 200 Borderline High : 200-239 High : > 240	mg/dl
Triglyceride Method: GPO-PAP	78	50-200	mg/dl
HDL Method: DIRECT	45.1	30 - 50	mg/dl
LDL Method: DIRECT	96.3	60 - 100	mg/dl
VDL Method: Calculated	15.6	<40	mg/dl
CHOLESTEROL / HDL RATIO Method: Calculated.	3.4	0 - 4.5	
<b>Thyroid Profile 2(Free T4, Free T3 And TSH)</b>			
Serum FT3	4.2	3.2 - 5.9	pmol/l
Serum FT4	13.8	10.6 - 21.0	pmol/l
Serum TSH	1.9	0.38 - 5.0	uIU/ml

**End of the report**

*Results are to be correlated clinically*

Lab Technician / Technologist  
Yogita

  
 Dr. Prashant Purwar  
 MBBS, DCP  
 Consultant Pathologist

• CLINICAL CORRELATION IS ESSENTIAL FOR FINAL DIAGNOSIS. • IF THE TESTS RESULTS ARE UNEXPECTED PLEASE CONTACT THE LABORATORY.  
 • ALL THE CONGENITAL ANAMOLIES IN THE FETUS MAY NOT BE DIAGNOSED IN ULTRASONOGRAPHY. • THIS REPORT IS NOT VALID FOR MEDICOLEGAL PURPOSE.

**Licensee** : Bharti Medicare Pvt. Ltd. The Apollo Clinic, C-70, Major Sudesh Kumar Marg, Opp. Madhav Park, Near Main Market, Rajouri Garden, New Delhi-110 027  
 Phone : (011) 2591 8222 / 8333 / 8444, 📞 9811061009, E-mail : rajourigarden@theapolloclinic.com, Website : www.apolloclinicrajourigarden.com

**MSME UAM NO. : DL11E0021531**

**Patient Name** : Mr. Chirag Kalra  
**UHID/MR No.** : FRAJ.0000245726  
**Visit Date** : 13-04-2024 09:01  
**Sample Collected on** : 13-04-2024 09:06  
**Sample No** : SR01913027  
**Ref Doctor** : SELF  
**Emp/Auth/TPA ID** : 451582  
**Sponsor Name** : MEDIWHEELS HEALTH CARE

**Age / Gender** : 33Y/Male  
**OP Visit No** : FRAJOPV121281  
**Reported on** : 14-04-2024 10:32  
**Specimen** : Serum  
**Pres Doctor:** :

DEPARTMENT OF LABORATORY MEDICINE

TEST NAME	RESULT	BIOLOGICAL REFERENCE INTERVALS	UNITS
<b>LIVER FUNCTION TEST (PACKAGE)</b>			
BILIRUBIN - TOTAL Method: Jendrassik	0.71	0.1 - 1.3	mg/dl
Bilirubin (Direct)-Serum Method: Diazo.	0.19	0 - 0.3	mg/dl
A/G Method: Calculated	1.4	1.0 - 2.0	
BILIRUBIN - INDIRECT. Method: Calculated.	0.52	<1.1	
SGOT /AST Method: IFCC (With P5P)	41.7*	0 - 35	U/L
SGPT/ALT Method: IFCC (With P5P)	65.8*	0 - 45	U/L
ALKALINE PHOSPHATE Method: AMP BUFFER	59.4	30 - 117	U/L
GGT. Method: SZAZ	25.3	10 - 50	U/L
TOTAL PROTEIN Method: Biuret	7.0	5.8-8.0	g/dl
ALBUMIN Method: BCG	4.1	3.7-5.2	g/dl
GLOBULIN Method: Calculated	2.9	2.5 - 3.5	mg/dL

End of the report

Results are to be correlated clinically

Lab Technician / Technologist  
 Yogita

  
 Dr. Prashant Purwar  
 MBBS, DCP  
 Consultant Pathologist

• CLINICAL CORRELATION IS ESSENTIAL FOR FINAL DIAGNOSIS. • IF THE TESTS RESULTS ARE UNEXPECTED PLEASE CONTACT THE LABORATORY.  
 • ALL THE CONGENITAL ANAMOLIES IN THE FETUS MAY NOT BE DIAGNOSED IN ULTRASONOGRAPHY. • THIS REPORT IS NOT VALID FOR MEDICOLEGAL PURPOSE.

Licensee : Bharti Medicare Pvt. Ltd. The Apollo Clinic, C-70, Major Sudesh Kumar Marg, Opp. Madhav Park, Near Main Market, Rajouri Garden, New Delhi-110 027  
 Phone : (011) 2591 8222 / 8333 / 8444, 9811061009, E-mail : rajourigarden@theapolloclinic.com, Website : www.apolloclinicrajourigarden.com

MSME UAM NO. : DL11E0021531



**TRUTHING LIVES**  
**Patient Name** : Mr. Chirag Kalra  
**UHID/MR No.** : FRAJ.0000245726  
**Visit Date** : 13-04-2024 09:01  
**Sample Collected on** : 13-04-2024 09:06  
**Sample No** : SR01913027  
**Ref Doctor** : SELF  
**Emp/Auth/TPA ID** : 451582  
**Sponsor Name** : MEDIWHEELS HEALTH CARE

**Apollo Clinic**  
*Expertise. Closer to you.*

**Age / Gender** : 33Y/Male  
**OP Visit No** : FRAJOPV121281  
**Reported on** : 14-04-2024 10:33  
**Specimen** : Serum  
**Pres Doctor:** :


**DEPARTMENT OF LABORATORY MEDICINE**

<b>TEST NAME</b>	<b>RESULT</b>	<b>BIOLOGICAL REFERENCE INTERVALS</b>	<b>UNITS</b>
<b>KFT - RENAL PROFILE-SERUM</b>			
UREA Method: Urease	14.3	10-50	mg/dl
Creatinine Method: Jaffe	0.92	0.5 - 1.3	mg/dl
Uric Acid Method: Uricase	5.3	3.5 - 7.2	mg/dl
Sodium(Na) Method: ISE	136.8	136 - 142	mmol/L
Potassium(K) Method: ISE	3.9	3.8 - 5.0	mmol/L
Chloride(Cl) Method: ISE	101.1	95 - 103	mmol/L
Calcium. Method: OCPC	9.4	9.2 - 11.0	mg/dl
Phosphorus Method: Molybdate UV	3.6	2.3 - 4.7	mg/dl

**End of the report**

*Results are to be correlated clinically*

Lab Technician / Technologist  
Yogita

  
Dr. Prashant Purwar  
MBBS, DCP  
Consultant Pathologist

• CLINICAL CORRELATION IS ESSENTIAL FOR FINAL DIAGNOSIS. • IF THE TESTS RESULTS ARE UNEXPECTED PLEASE CONTACT THE LABORATORY.  
• ALL THE CONGENITAL ANAMOLIES IN THE FETUS MAY NOT BE DIAGNOSED IN ULTRASONOGRAPHY. • THIS REPORT IS NOT VALID FOR MEDICOLEGAL PURPOSE.

**Licensee** : Bharti Medicare Pvt. Ltd. The Apollo Clinic, C-70, Major Sudesh Kumar Marg, Opp. Madhav Park, Near Main Market, Rajouri Garden, New Delhi-110 027  
Phone : (011) 2591 8222 / 8333 / 8444, 9811061009, E-mail : rajourigarden@theapolloclinic.com, Website : www.apolloclinicrajourigarden.com

**MSME UAM NO. : DL11E0021531**



**Patient Name** : Mr. Chirag Kalra  
**UHID/MR No.** : FRAJ.0000245726  
**Visit Date** : 13-04-2024 09:01  
**Sample Collected on** : 13-04-2024 09:06  
**Sample No** : UR1050743  
**Ref Doctor** : SELF  
**Emp/Auth/TPA ID** : 451582  
**Sponsor Name** : MEDIWHEELS HEALTH CARE

**Age / Gender** : 33Y/Male  
**OP Visit No** : FRAJOPV121281  
**Reported on** : 13-04-2024 16:03  
**Specimen** : Urine  
**Pres Doctor:** :

DEPARTMENT OF LABORATORY MEDICINE

URINE ROUTINE EXAMINATION

URINE EXAMINATION TEST REPORT

Test Name	Observed Value	Unit	Reference Range
<b>Urine R/M Examination</b>			
Quantity	25	ml.	
Colour	Pale Yellow		Pale Yellow
Transparency	Clear		Clear
Urine Specific Gravity	1.020		1.005 - 1.030
Dipstick			
pH	6.0		5.5 - 7.5
Dipstick / pH paper			
<b>Chemical Examination</b>			
Protein	Nil		Nil
Dipstick/Heat & acetic acid			
Sugar	Nil		Nil
Dipstick/Benedicts reagent			
<b>Microscopic Examination</b>			
Pus Cells	0-1	/HPF	1-2
RBC'S	Nil	/HPF	Nil
Casts	Nil	/HPF	Nil
Crystals	Nil		Nil
Epithelial Cells	Occasional	/HPF	1-2
Bacteria	Nil	/HPF	Nil

End of the report

Results are to be correlated clinically

Lab Technician / Technologist  
Rakesh

Dr. Prashant Purwar  
MBBS, DCP  
Consultant Pathologist

NAME: MR CHIRAG KALRA  
REF

AGE: 33 / Sex / M  
DATE 13/04/2024

**ECHO ADULT (COLOUR DOPPLER)**

DIMENSIONS	NORMAL	DIMENSIONS	NORMAL
Ao (ed) 32.0 mm	(1.5 cm/m <sup>2</sup> )	IVS (Ed) 11.2 mm	{0.6-1.2cm}
LA (es) 33.0 mm	(1.5 cm/m <sup>2</sup> )	LVPW (Ed) 10.5 mm	{.6-1.1cm}
RVID (ed) Normal	(0.9cm/m <sup>2</sup> )	EF	65.0 % {0.62-0.85}
LVID (ed) 45.0 mm	(2.6-3.4 cm/m <sup>2</sup> )	FS	30.0
LVID (es) 27.0 mm			


**MORPHOLOGICAL DATA**

Mitral Valve	Normal	Interatrial Septum	Normal
Aortic Valve	Normal	Interventricular Septum	Normal
Tricuspid Valve	Normal	Pulmonary Artery	Normal
Pulmonary Valve	Normal	Aorta	Normal
Right Ventricle	Normal	Right Atrium	Normal
Left Ventricle	Normal	Left Atrium	Normal
Pericardium	Normal		

Colour Doppler Normal , NO PAH, IVC NORMAL, LV DIASTOLIC FUNCTION NORMAL

Wall motion Normal

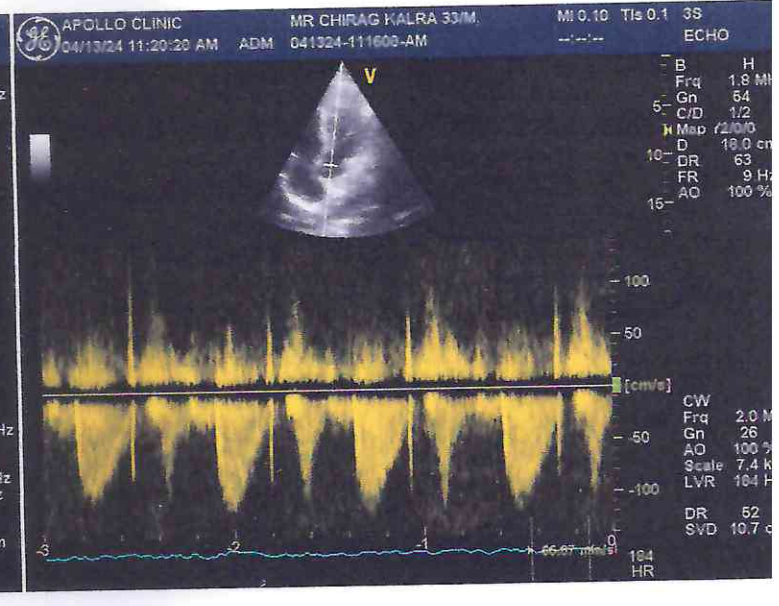
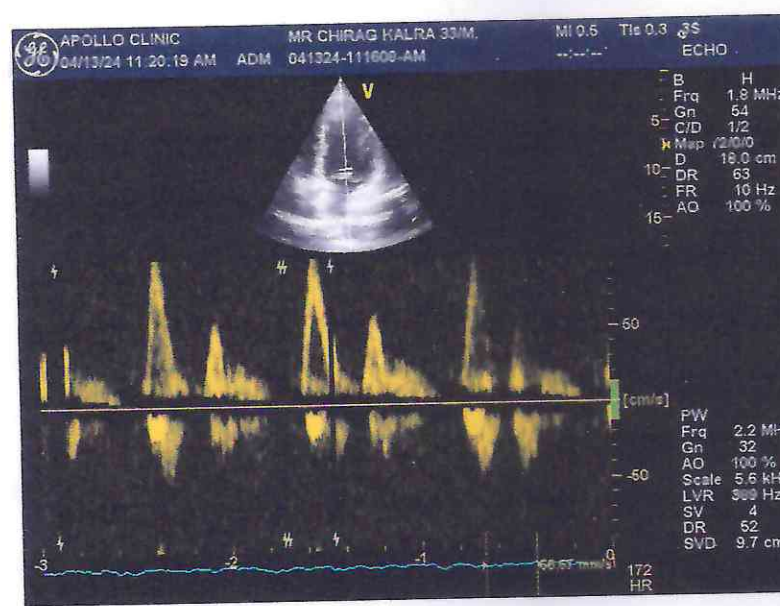
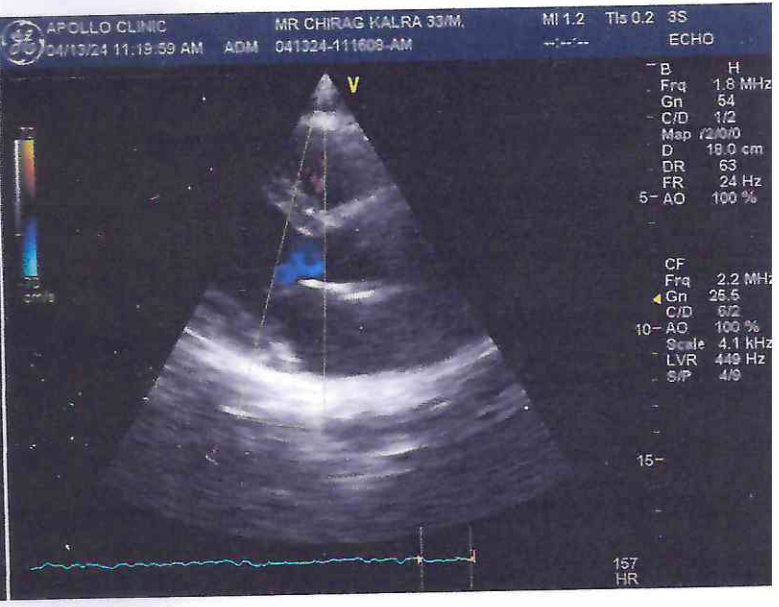
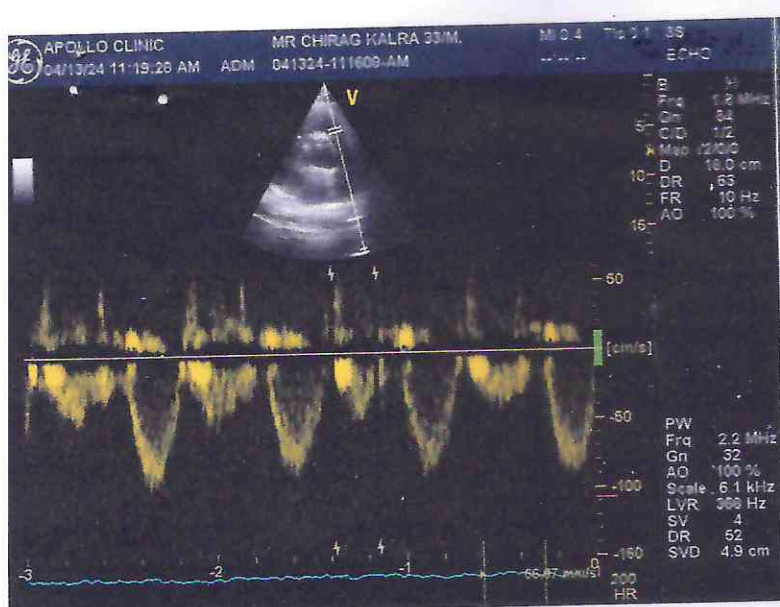
IMPRESSION : NORMAL STUDY

  
DR SEEMA KALE MD  
SEN. (PHYSICIAN)  
THE APOLLO CLINIC  
Rajouri Garden  
Dr. Seema Kale  
MBBS MD  
DMC Reg No-14927

• CLINICAL CORRELATION IS ESSENTIAL FOR FINAL DIAGNOSIS. • IF THE TESTS RESULTS ARE UNEXPECTED PLEASE CONTACT THE LABORATORY.  
• ALL THE CONGENITAL ANAMOLIES IN THE FETUS MAY NOT BE DIAGNOSED IN ULTRASONOGRAPHY. • THIS REPORT IS NOT VALID FOR MEDICOLEGAL PURPOSE.

Licensee : Bharti Medicare Pvt. Ltd. The Apollo Clinic, C-70, Major Sudesh Kumar Marg, Opp. Madhav Park, Near Main Market, Rajouri Garden, New Delhi-110 027  
Phone : (011) 2591 8222 / 8333 / 8444, 9811061009, E-mail : rajourigarden@theapolloclinic.com, Website : www.apolloclinicrajourigarden.com

MSME UAM NO. : DL11E0021531



Patient Name : Chirag Kalra	MR No	: FRAJ0000
Age/Sex : 33Y/M	Visit No	: FRAJOPV
Pres Doctor :	Bill Date	: 13.04.2024
Ref.by :	Report Date	: 13.04.2024

**ULTRASOUND WHOLE ABDOMEN**

**LIVER:** Liver is normal in shape, size and echotexture. No focal intra-hepatic lesion detected. Intra-hepatic biliary radicals are not dilated. Portal vein is normal in calibre.

**GALL BLADDER:** Gall bladder is well visualized. Its wall thickness is normal. No calculus or mass lesion is seen in gall bladder. Common bile duct is normal (not dilated).

**PANCREAS:** Pancreas appears normal in size and echopattern.

**SPLEEN:** Spleen appears normal in size and echopattern.

**KIDNEYS:** Both kidneys are normal in position, size and outline. Cortico-medullary differentiation of both kidneys is maintained. Central sinus echoes are compact. No calculus / hydronephrosis seen.

Visualised parts of retroperitoneum do not show any lymphadenopathy.

**URINARY BLADDER:** Urinary bladder is well distended and shows clear contents.

**PROSTATE:** Prostate is normal in shape, size and echotexture.

No free fluid detected.

**IMPRESSION:- NORMAL STUDY**

To be correlate clinically.

**Dr. Shailza Minocha**  
Consultant Radiologist.

**Disclaimer:** Renal calculi less than 5mm could be missed on an Ultrasound. NCCT KUB is the modality of choice for the same.

• CLINICAL CORRELATION IS ESSENTIAL FOR FINAL DIAGNOSIS. • IF THE TESTS RESULTS ARE UNEXPECTED PLEASE CONTACT THE LABORATORY.  
• ALL THE CONGENITAL ANAMOLIES IN THE FETUS MAY NOT BE DIAGNOSED IN ULTRASONOGRAPHY. • THIS REPORT IS NOT VALID FOR MEDICOLEGAL PURPOSE.

Licensee : Bharti Medicare Pvt. Ltd. The Apollo Clinic, C-70, Major Sudesh Kumar Marg, Opp. Madhav Park, Near Main Market, Rajouri Garden, New Delhi-110 027  
Phone : (011) 2591 8222 / 8333 / 8444, 9811061009, E-mail : rajourigarden@theapolloclinic.com, Website : www.apolloclinicrajourigarden.com

**MSME UAM NO. : DL11E0021531**

Patient Name : Mr.Chirag Kalra	MR No	: FRAJ0000
Age/Sex : 33Y/M	Visit No	: FRAJOPV
Pres Doctor :	Bill Date	: 13.04.2024
Ref.by :	Report Date	: 13.04.2024

### X-RAY CHEST PA VIEW

- Both lungs fields do not show any active parenchymal lesion.
- Both costophrenic angles are normal.
- B/L hila appear normal in size & density.
- Both domes of diaphragm are normal.
- Cardiac silhouette appears normal.
- Visualised soft tissues and bony cage appear normal.

**IMPRESSION:- NORMAL STUDY.**

To be correlate clinically.

  
**Dr. Rahul Gera**  
Consultant Radiologist.

• CLINICAL CORRELATION IS ESSENTIAL FOR FINAL DIAGNOSIS. • IF THE TESTS RESULTS ARE UNEXPECTED PLEASE CONTACT THE LABORATORY.  
• ALL THE CONGENITAL ANOMOLIES IN THE FETUS MAY NOT BE DIAGNOSED IN ULTRASONOGRAPHY. • THIS REPORT IS NOT VALID FOR MEDICOLEGAL PURPOSE.

Licensee : Bharti Medicare Pvt. Ltd. The Apollo Clinic, C-70, Major Sudesh Kumar Marg, Opp. Madhav Park, Near Main Market, Rajouri Garden, New Delhi-110 027  
Phone : (011) 2591 8222 / 8333 / 8444, 📞 9611061009, E-mail : rajourigarden@theapolloclicin.com, Website : www.apolloclicinrajourigarden.com

**MSME UAM NO. : DL11E0021531**