

NAME: Srilant.
 DATE: 29/03/2024

AGE/SEX: 32 YEARS
 REFERRED BY: MediWheel.

PERSONAL HISTORY:

Sleep	Disturbed / Sound	Acidity	
Appetite	Good / Reduced / Increased	Exercise	
Micturition	Burning / Normal	Diet	
Bowel Movement	Regular / Irregular / Constipation	Marital Status	
Water Intake			

PAST HISTORY:

Any allergies		Coronary Heart Disease	
Hypertension		Any Operations/ Surgery	
Diabetes		Treatment/Medication History	
Tuberculosis		Hospitalization	

SOCIAL HISTORY:-

Drinking	
Smoking	

FAMILY HISTORY:

RELATIONSHIP	ALIVE/NOT ALIVE	IF ALIVE GIVE PRESENT STATE OF HEALTH/ IF NOT ALIVE SPECIFY CAUSE OF DEATH
Father		
Mother		
Sister		
Brother		
Wife/Husband		
Children		

FEMALE PATIENTS

Frequency & Regularity of Periods _____ Any Children _____
 Contraception _____ Full Term / Pre mature _____
 Pregnancy / Miscarriage / Termination _____

PHYSICAL EXAMINATION:

Hydration		Joint swelling / Deformity		Nicotine Stains	
Palms		Cyanosis / clubbing		Pallor	
Osler's nodes		Palpation of lymph nodes		Icterus	
Palmar erythema		Edema			
Yellow Skin		Pitting			
		Non Pitting			
		Dependent			

VITAL SIGNS:-

Temperature 96.4 F Basic Measurements
 Respiratory Rate 22 Height 167 cm
 Pulse rate / rhythm 80/min Weight 79.5 kg
 Blood Pressure 130/80 mmHg BMI 28.6

ABDOMINAL EXAMINATION: No Hepatosplenomegaly, No Tenderness.

Inspection		Spleen	
Palpation		Other	
Liver		Tenderness	

NERVOUS SYSTEM: All reflexes and cranial nerves are normal. No sensory / motor deficit detected.

Reflexes		Sensory Nerve	
Cranial Nerve		Motor System	
Sensory Nerve		Others	

MUSCULO SKELETAL SYSTEM: No evident abnormality detected. All movements are normal.

Extremities	
Movements	

CARDIO VASCULAR SYSTEM: Heart Sounds Normal. No other abnormality detected.

HEART SOUNDS:-

Heart Sound 1		Murmur	
Heart Sound 2		Other Findings	

RESPIRATORY SYSTEM: Air entry normal and equal on both sides. No added sounds or other abnormality detected.

Inspection of Thorax		Breathing	
Auscultation		Added Sounds	
Air Entry		Other Findings	


SUGGESTIONS:

NIL

RECOMMENDATION:-

NIL

Dr. Name: _____

 DR (MRS) RAJNESH SINGH
MBBS, DGO
M M C REG. NO. 49217
Meesha Healthcare & Research Pvt. Ltd



Branch :

Ground Floor, 12-C, Moti Mahal, C.S. No.1631, Churchgate, Mumbai-400 020.
Tel. : +91 22 3574 1977 / 93241 87465 / 77100 84304

Patient Name : MR.SRIKANTH REDDY THALLA
Age : 56 YEARS
REF : MEDI WHEEL

ID No : 43488
Sex : MALE
Date : 29.03.2024

2D ECHOCARDIOGRAPHY & COLOR DOPPLER REPORT

DIMENSIONS (M MODE)

LA	34	mm
AO	28	mm
LVID (d)	49	mm
LVID (s)	40	mm
IVS(d)	10	mm
IVS(s)	14	mm
LVPW (d)	10	mm
LVPW(s)	14	mm

2 D ECHOCARDIOGRAPHY & DOPPLER FINDINGS:

ALL CARDIAC CHAMBERS ARE NORMAL IN DIMENSIONS

NO RWMA

LVEF = 60 %

GOOD LV SYSTOLIC FUNCTION

NORMAL LV DIASTOLIC FUNCTION

AORTIC VALVE – NORMAL OPENING.NO AR.NO AS.

NO MR TR AR

MITRAL VALVE – NORMAL IN STRUCTURE AND MOBILITY,

IVC NORMAL IN SIZE AND COLLAPSING WITH RESPIRATION

IAS/IVS INTACT

NO PULMONARY HYPERTENSION

7th Floor, La View, B. J. Marg, Jacob Circle, Mahalaxmi, Mumbai-400 011.
Tel. : +91 22 2305 3534 / 36 / 77100 84305
info@meeshahealth.net | www.meeshahealth.net



Branch :

Ground Floor, 12-C, Moti Mahal, C.S. No.1631, Churchgate, Mumbai-400 020.
Tel. : +91 22 3574 1977 / 93241 87465 / 77100 84304


Patient Name : MR.SRIKANTH REDDY THALLA
Age : 56 YEARS
REF : MEDI WHEEL

ID No : 43488
Sex : MALE
Date : 29.03.2024

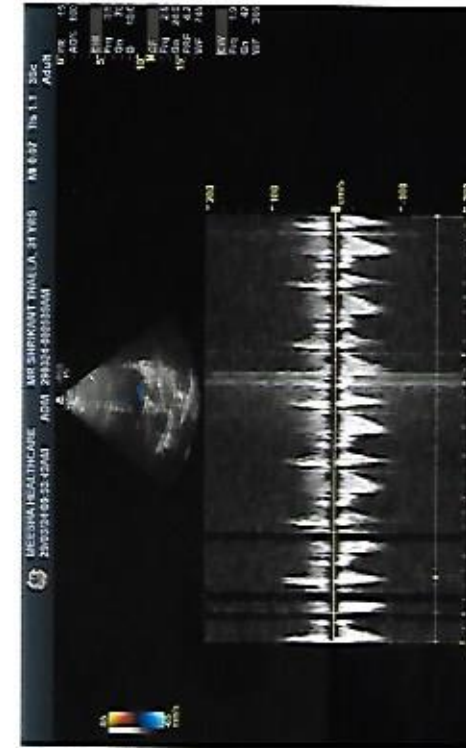
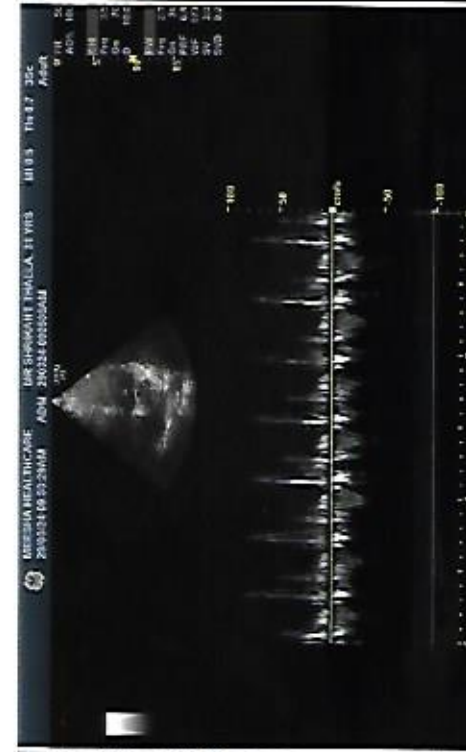
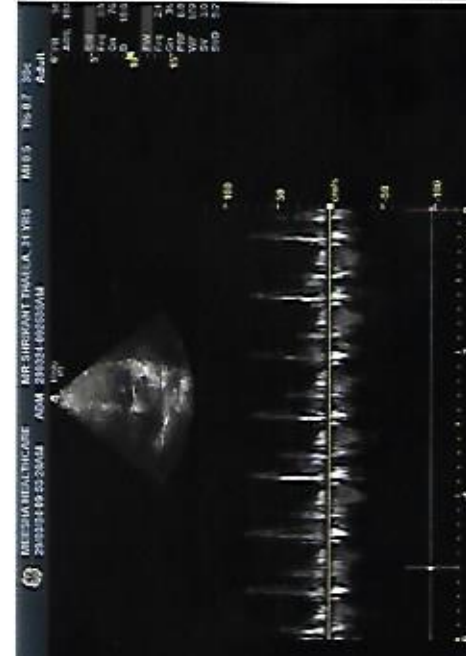
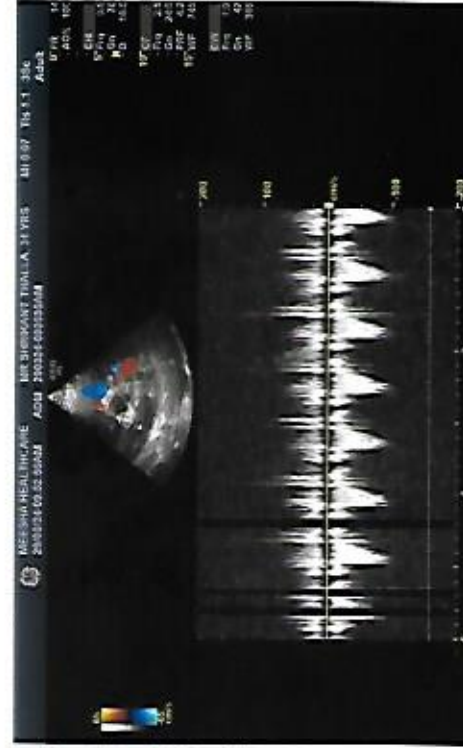
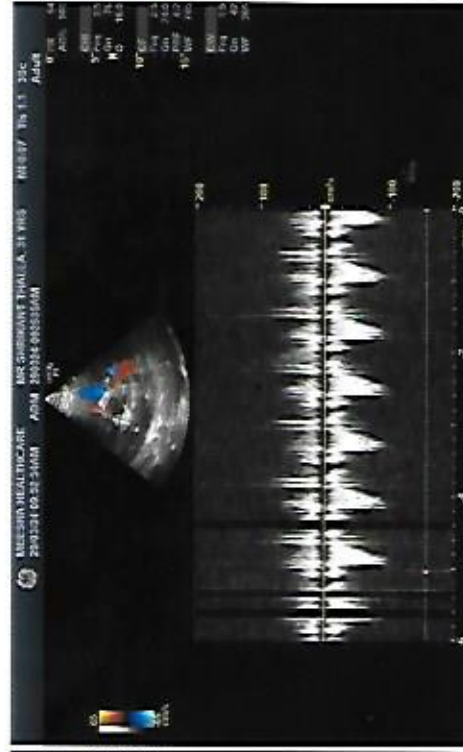
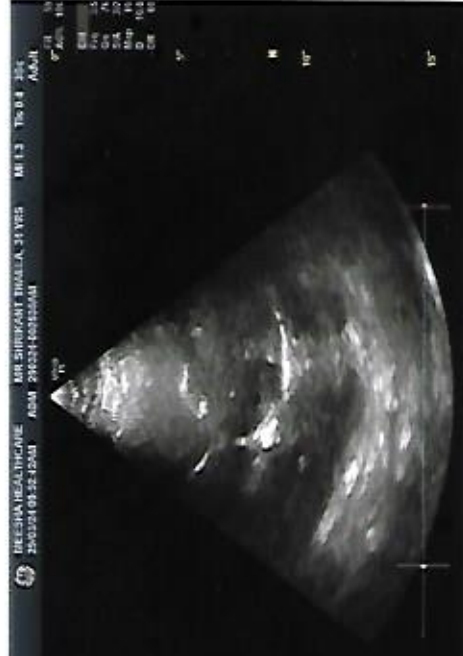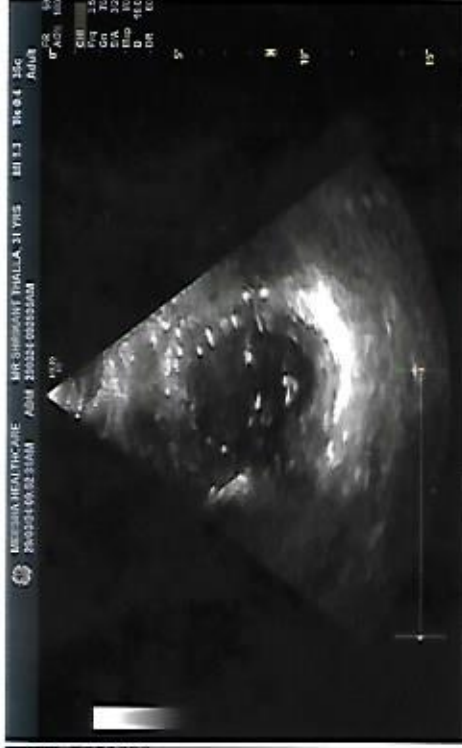
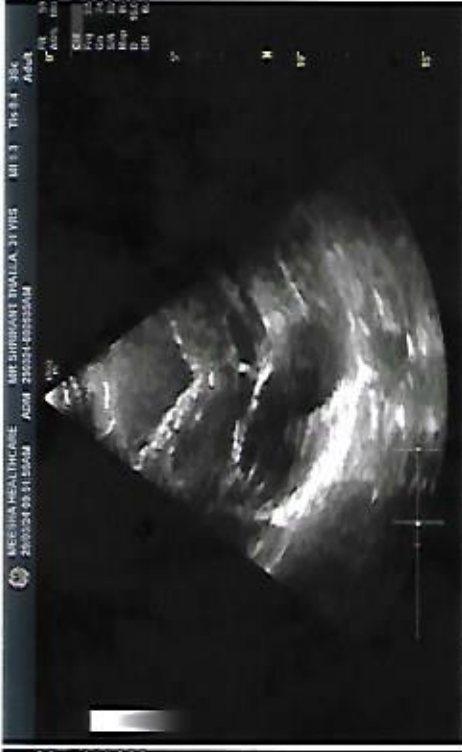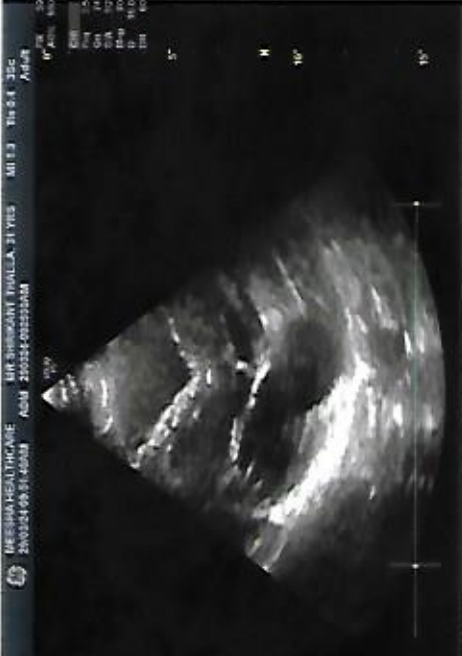NO CLOTS/ VEGETATIONS/EFFUSION.

CONCLUSIONS:

NORMAL STUDY


Dr. YOGESH SHILIMKAR
MBBS, MD (MEDICINE)
DM (CARDIOLOGY)
INTERVENTIONAL CARDIOLOGIST
MMC REG. NO. : 2013040995

Dr. YOGESH SHILIMKAR
MBBS, MD (MED), DM (CARDIOLOGY)
Consultant Interventional Cardiologist



ID: 43488
SHRIKANT REDDY THALLA
Male 31 Years
167cm 79kg

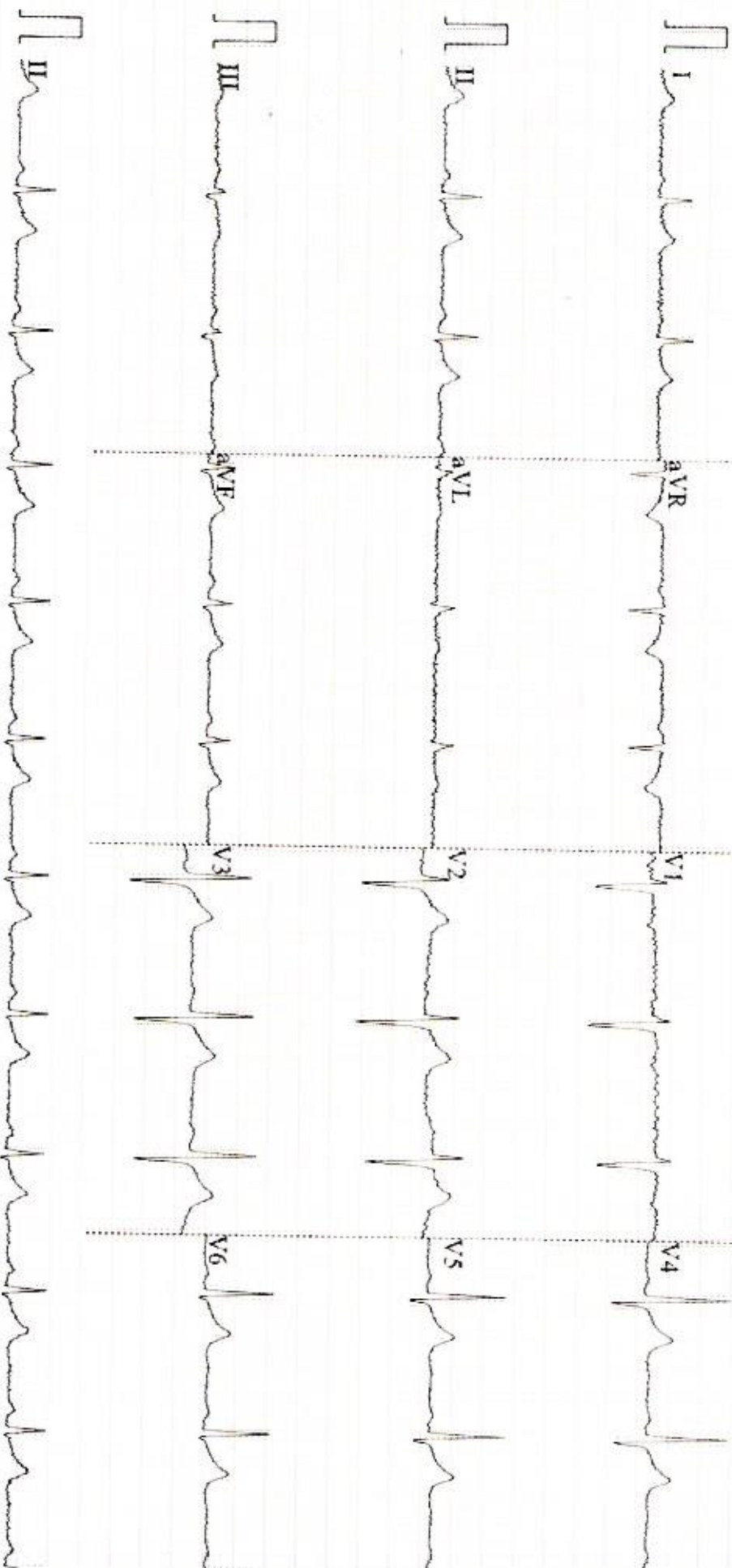
HR : 67 bpm
P : 122 ms
PR : 164 ms
QRS : 88 ms
QT/QTc : 374/398 ms
P/QRS/T : 66/28/54 °
RV5/SV1 : 1.229/0.962 mV

Diagnosis Information:

M. C. REG.

Ref-Phys. : MEDIWHEEL
Report Confirmed by:

DR (MRS) RAJNESH SHI
MBBS, D
M M C REG. NO.49211
Meesha Healthcare & Research Pvt





Branch :

Ground Floor, 12-C, Moti Mahal, C.S. No 1631, Churchgate, Mumbai-400 020.
 Tel. : +91 22 3574 1977 / 93241 87465 / 77100 84304

NAME: - Sikaanth
DATE: - 29/3/24
REFERRED BY: - Mediwheel.

REF No. :- 43488
AGE/SEX: - 32yrs/M

EYE CHECKUP

HISTORY OF EYE RELATED COMPLAINTS: H/O using glasses - many yrs.
HISTORY OF SYSTEMIC ILLNESS :

EXAMINATION		RIGHT	LEFT
Distance vision	Without correction	fc 5-6/ft	fc 5-6/ft
	With correction	6/6	6/6
Near Vision	Without correction	NG	NG
	With correction		
ANTERIOR SEGMENT		mc	mc
LENS		clear	clear
POSTERIOR SEGMENT		MAO	MAO
ROPLAS		MAO	MAO
TENSION		12mmHg	12mmHg
COLOR VISION		MAO	MAO
DAIGNOSIS		(B) Refractive Error	
ADVICE :		(myopia)	
		- Glasses	

	RIGHT				LEFT			
	SPH	CYL	AXIS	Vn	SPH	CYL	AXIS	Vn
DISTANCE	-2.50			6/6	-2.50			6/6
NEAR								

CONCLUSION:

Dr. SMITA DIXIT
 DOMS, FCPS,
 CONSULTANT OPHTHALMOLOGIST,
 Reg. No. 2000 / 05 / 2092.

DR. SMITA DIXIT
DOMS.FC PS (OPHTHALMOLOGY)

Branch :

Ground Floor, 12-C, Moti Mahal, C.S. No.1631, Churchgate, Mumbai-400 020.
 Tel. : +91 22 3574 1977 / 93241 87465 / 77100 84304

THALLA, SHRIKANT

ID: 043488 Age: 31

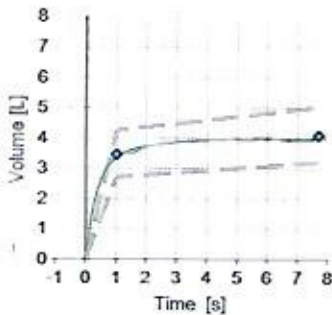
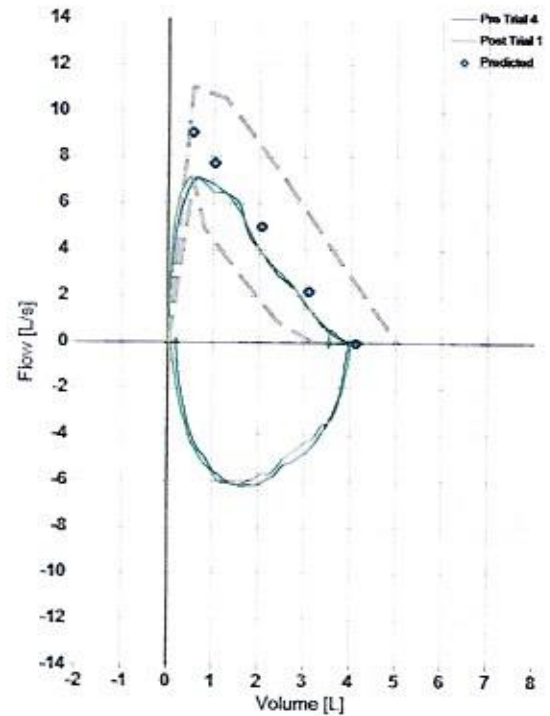
Gender **Male** Height **167 cm**
 Ethnicity **Asian** Weight **79 kg** BMI **28.3**

FVL (ex/in)

Your FEV1 / Predicted: 96 %

Test Date: 29 Mar 24 11:14:48 AM Predicted: ERS (ECC5/EGK5), 1993 * 0.92

Parameter	Pred	Pre Best		Post Best			%Chg
		LLN	Trial 4	%Pred	Trial 1	%Pred	
FVC [L]	4.11	3.19	3.98	97	4.02	98	1
FEV1 [L]	3.49	2.72	3.36	96	3.37	97	0
FEV1/FVC [%]	81.6	69.8	84.4	103	83.7	103	-1
FEF25-75 [L/s]	4.61	2.89	3.64	79	3.59	78	-1
PEF [L/s]	9.07	7.08	7.12	78	7.20	79	1
FET [s]	-	-	6.2	-	5.9	-	-4
FVC [L]	4.11	3.19	3.77	92	3.91	95	4
PIF [L/s]	-	-	6.19	-	6.16	-	-1
Session Quality	Pre	B (FEV1 Var=0.02L (0.7%); FVC Var=0.15L (3.8%))					
	Post	A (FEV1 Var=0.08L (2.4%); FVC Var=0.04L (1.0%))					
System Interpretation	Pre	Normal Spirometry					
	Post	Normal Spirometry					



Comment

Normal flow rates and lung volumes



Kalyan
 for Dr. Sonam Solunke

Branch :

Ground Floor, 12-C, Moti Mahal, C.S. No.1631, Churchgate, Mumbai-400 020.
Tel. : +91 22 3574 1977 / 93241 87465 / 77100 84304

Patient Name : MR. SHRIKANT REDDY THALLA
Age : 31 YEARS
Ref. By : MEDI WHEEL

ID No : 43488
Sex : MALE
Date : 29.03.2024

ULTRASONOGRAPHY OF THE ABDOMEN AND PELVIS :

Liver

Is normal in size, shape and echotexture.
No focal or diffuse lesion is seen.
The biliary tree and portal vein radicals are normal.

Gall bladder

Is physiologically distended and reveals an anechoic lumen .
No gallstone or evidence of cholecystitis is seen.

Pancreas

Reveals a homogenous normal parenchymal echotexture and appears normal in size.
No solid or cystic mass lesion is seen. No pancreatic calcification or duct dilatation is seen.

Spleen

Is normal in size, shape . The parenchymal echotexture is normal.
No focal mass lesion is seen.

Kidneys

The right kidney measures 10.6 x 4.3 cms. The left kidney measures 10.2 x 4.7 cms.
Appear normal in size, shape and reveal normal differentiation of cortex, medulla and central echo complex.
No hydronephrosis, calculus or scarring is seen.

Urinary bladder


Was distended and revealed no intrinsic abnormality.

No para aortic lymphadenopathy or ascites is seen.

Prostate is normal in size and echotexture. It measures 2.6 x 2.6 x 2.6 cms and weights 9.4 gms. No obvious focal mass lesion is seen.

IMPRESSION :

- **No significant abnormality detected.**


DR. PRASHANT VAIDYA
M.B.B.S. DMRE
Reg. No. 2002/02/593
DR. PRASHANT VAIDYA
D.M.R.E
CONSULTANT RADIOLOGIST

