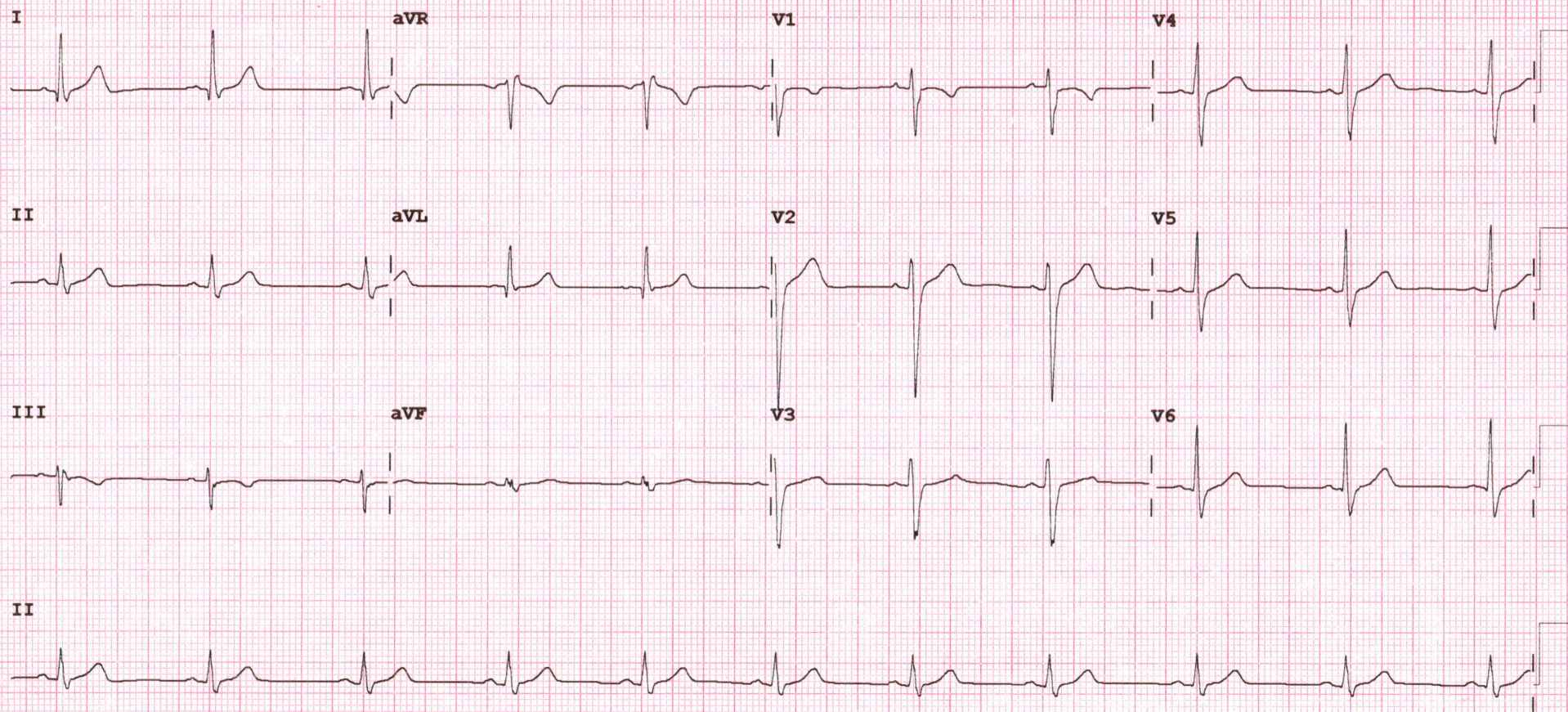


Rate 64
PR 140
QRSD 108
QT 376
QTc 388

--AXIS--

P 45
QRS 0
T 14

12 Lead; Standard Placement



Device:

Speed: 25 mm/sec

Limb: 10 mm/mV

Chest: 10.0 mm/mV

F 50~ 0.50-150 Hz W

PH09

P?



2D-ECHOCARDIOGRAPHY AND COLOR DOPPLER REPORT

NAME: UPDESH MEENA

AGE/SEX:33 YRS/MALE

DATE: 29/03/2024

REF BY:DIRECT

OBSERVATION:

- NORMAL LV SIZE AND NORMAL LV SYSTOLIC FUNCTION. LVEF = 60% (VISUAL).
- NO RWMA AT REST.
- NORMAL LV DIASTOLIC DYSFUNCTION.
- TRIVIAL MR. NO MS.
- NO AR. NO AS.
- TRIVIAL TR. NO PAH.
- NORMAL SIZED LA, RA & RV WITH NORMAL RV SYSTOLIC FUNCTION.
- NORMAL SIZED MPA, RPA & LPA.
- INTACT IAS & IVS.
- NO E/O INTRACARDIAC CLOT/VEGETATION/PE.
- NORMAL IVC.
- NORMAL PERICARDIUM.

LA: 32MM

AO: 29MM

IVS: 11/14MM

LVPW: 10/13MM

LVID: 45/25MM

CONCLUSION:

- NORMAL LV/RV SIZE AND SYSTOLIC FUNCTION.
- NO RWMA AT REST.
- LVEF = 60% (VISUAL).

DR.NIRAV BHALANI
[CARDIOLOGIST]

DR.ARVIND SHARMA
[CARDIOLOGIST]



Savita
Superspeciality Hospital
(A Unit of Solace Healthcare Pvt. Ltd.)

Parivar Char Rasta, Waghodia-Dabhoi Ring Road, Vadodara-390019
0265-2578844 / 2578849 63596 88442
mh@savitahospital.com savitahospital.com



PATIENT NAME: UPDESH MEENA	
AGE/SEX: 33 YRS/F	DATE: Friday, 29 March 2024

CHEST X-RAY (PA)

Both lung fields appear normal.
Both hila appear normal
Bilateral costo-phrenic angles appear grossly clear
Mediastinum and cardiac shadow appear normal
Bony thorax appears unremarkable
No evidence of free gas under domes of diaphragm

IMPRESSION:

- NO SIGNIFICANT ABNORMALITY NOTED IN LUNG FIELDS
- NORMAL CARDIAC SHADOW


DR SHARAD RUNGTA (MD & DNB)
CONSULTANT RADIOLOGIST

Not all pathologies can be detected on ultrasound in each scan. Further radiographic evaluation is suggested if required.



PATIENT NAME: UPDESH MEENA

AGE/SEX: 33 YRS/M

DATE: Friday, 29 March 2024

ULTRASOUND OF ABDOMEN & PELVIS

LIVER appears normal in size and **shows raised parenchymal echogenicity**. No evidence of focal lesion. No evidence of dilated IHBR or portal vein. CBD appears normal.

GALL BLADDER is distended. No e/o wall thickening, pericholecystic edema or calculus within.

VISUALIZED PART OF PANCREAS appears normal. MPD is WNL.

SPLEEN appears normal in size and shows normal parenchymal echogenicity. No evidence of focal lesion.

BOTH KIDNEYS appear normal in size and position.

Show normal cortical echogenicity. Corticomedullary differentiation is maintained.

Left kidney shows 10 mm sized calculus at midpole. No hydronephrosis on either side.

URINARY BLADDER is full. Mucosal surface appears smooth with no e/o obvious wall thickening or calculus within.

PROSTATE appears normal in size. No evidence of focal lesion noted.

BOWEL LOOPS appear normal and show normal peristalsis

No evidence of LYMPHADENOPATHY noted.

No evidence of ASCITES or PLEURAL EFFUSION noted.

IMPRESSION:

- **Non-obstructive left intrarenal calculus.**
- **Grade I Fatty Liver.**

DR SHARAD RUNGTA (MD & DNB)
CONSULTANT RADIOLOGIST

Not all pathologies can be detected on ultrasound in each scan. Further radiographic evaluation is suggested if required.



Savita

Superspeciality Hospital
(A Unit of Solace Healthcare Pvt. Ltd.)

Parivar Char Rasta, Waghodia-Dabhoi Ring Road, Vadodara-390019

☎ 0265-2578844 / 2578849 ✉ mh@savitahospital.com 🌐 savitahospital.com

Patient Name : Updesh Meena

Sample No. : 20240314839



Patient ID : 20240309228

Visit No. : OPD20240329416

Age / Sex : 33y/Male

Cali. Date : 29/03/2024 08:02

Consultant : DR SAURABH JAIN

S. Coll. Date : 29/03/2024 13:19

Ward : -

Report Date : 29/03/2024 15:41

CBC, ESR

Investigation	Result	Normal Value
Hemoglobin :	15.6 gm/dl	13.5 to 18.0 gm/dl
P.C.V. :	46.3 %	42.0 to 52.0 %
M.C.V. :	89.9 fL	78 to 100 fL
M.C.H. :	30.3 pg	27 to 31 pg
M.C.H.C. :	33.7 g/dl	32 to 36 g/dl
RDW :	11.6 %	11.5 to 14.0 %
RBC Count :	5.15 X 10 ⁶ /cumm	4.7 to 6.0 X 10 ⁶ /cumm
Polymorphs :	64 %	38 to 70 %
Lymphocytes :	31 %	15 to 48 %
Eosinophils :	2 %	0 to 6 %
Monocytes :	3 %	3 to 11 %
Basophils :	0 %	0.0 to 1.0 %
Total :	100	< 100 > 100
WBC Count :	5100 /cmm	4000 to 10000 /cmm
Platelets Count :	184000 /cmm	1,50,000 to 4,50,000 /cmm
ESR - After One Hour :	9 mm/hr	1 to 13 mm/hr

Dr. Mehul Desai
M.B.D.C.P
Reg.No.G-9521



Patient Name : Updesh Meena

Sample No. : 20240314839



Patient ID : 20240309228

Visit No. : OPD20240329416

Age / Sex : 33y/Male

Call. Date : 29/03/2024 08:02

Consultant : DR SAURABH JAIN

S. Coll. Date : 29/03/2024 13:20

Ward : -

Report Date : 29/03/2024 15:41

Blood Group

Investigation	Result	Normal Value
BLOOD GROUP :		
ABO	O	
Rh	Positive	

FBS & PPBS

Investigation	Result	Normal Value
Blood Sugar (FBS) :	100 mg/dl	74 - 100 mg/dl
Urine Sugar (FUS) :	Nil	
Blood Sugar (PP2BS) :	128 mg/dl [H]	70 to 120 mg/dl
Urine Sugar (PP2US) :	Nil	

HBA1C

Investigation	Result	Normal Value
Glycosylated Hb :	5.4 %	Near Normal Glycemia : 6 to 7 Excellent Control : 7 to 8 Good Control : 8 to 9 Fair Control : 9 to 10 Poor Control : > 10
Average Plasma Glucose of Last 3 Months :	108.28	

Dr.Mehul Desai
M.B.D.C.P
Reg.No.G-9521



Patient Name : Updesh Meena

Sample No. : 20240314839



Patient ID : 20240309228

Visit No. : OPD20240329416

Age / Sex : 33y/Male

Call. Date : 29/03/2024 08:02

Consultant : DR SAURABH JAIN

S. Coll. Date : 29/03/2024 13:20

Ward : -

Report Date : 29/03/2024 15:41

Lipid Profile

Investigation	Result	Normal Value
Sample :	Fasting	
Sample Type :	Normal	
Cholesterol (Chol) :	175 mg/dl	Low risk : < 200 Moderate risk : 200 - 239 High risk : > or = 240
Triglyceride :	190 mg/dl	Normal : < 200.0 High : 200 - 499 Very High : > or = 500
HDL Cholesterol :	37 mg/dl [L]	Low risk: >or = 60 mg/dL High risk : Up to 35 mg/dL
LDL :	100 mg/dl [L]	131.0 to 159.0(N) < 130.0(L) > 159.0(H)
VLDL :	38 mg/dl [H]	Up to 0 to 34 mg/dl
LDL/HDL Ratio :	2.7	Low risk : 0.5 to 3.0 Moderate risk : 3.0 to 6.0 Elevted level high > 6.0
Total Chol / HDL Ratio :	4.73	Low Risk : 3.3 to 4.4 Average Risk : 4.4 to 7.1 Moderate Risk : 7.1 to 11.0 High Risk : > 11.0
Total Lipids :	702 mg/dl [H]	400 to 700 mg/dl

Note :- Lipemic samples give high triglyceride value and falsely low LDL value.

Dr. Mehul Desai
M.B.D.C.P
Reg.No.G-9521



Patient Name : Updesh Meena

Sample No. : 20240314839



Patient ID : 20240309228

Visit No. : OPD20240329416

Age / Sex : 33y/Male

Call. Date : 29/03/2024 08:02

Consultant : DR SAURABH JAIN

S. Coll. Date : 29/03/2024 13:20

Ward : -

Report Date : 29/03/2024 15:41

RENAL FUNCTION TEST

Investigation	Result	Normal Value
Creatinine :	0.9 mg/dl	0.6 - 1.4 mg/dl
Urea :	22 mg/ dl	13 - 45 mg/dl
Uric Acid :	4.5 mg/dl	3.5 - 7.2 mg/dl
Calcium :	9 mg/dl	8.5 - 10.5

Dr.Mehul Desai
M.B.D.C.P
Reg.No.G-9521



Patient Name : Updesh Meena	Sample No. : 20240314839
Patient ID : 20240309228	
Age / Sex : 33y/Male	Visit No. : OPD20240329416
Consultant : DR SAURABH JAIN	Call. Date : 29/03/2024 08:02
Ward : -	S. Coll. Date : 29/03/2024 13:20
	Report Date : 29/03/2024 15:41

LFT (Liver Function Test)

Investigation	Result	Normal Value
Total Bilirubin :	0.8 mg/dl	0.2 to 1.0 mg/dl
Direct Bilirubin :	0.4 mg/dl	0.0 to 0.2 mg/dl
Indirect Bilirubin :	0.4 mg/dl	0.0 to 0.8 mg/dl
AST (SGOT) :	31 U/L	5 to 34 U/L
ALT (SGPT) :	27 U/L	0 to 55 U/L
Total Protein (TP) :	7 g/dL	6.4 to 8.3, g/dl
Albumin (ALB) :	4.3 g/dl	3.5 to 5.2 g/dl
Globulin :	2.7 g/dl	2.3 to 3.5 g/dl
A/G Ratio :	1.59	
Alkaline Phosphatase (ALP) :	92 U/L	40 to 150 U/L
GAMMA GT. :	18 U/L	7 to 35 U/L

Dr.Mehul Desai
M.B.D.C.P
Reg.No.G-9521



Patient Name : Updesh Meena

Sample No. : 20240314839



Patient ID : 20240309228

Visit No. : OPD20240329416

Age / Sex : 33y/Male

Call. Date : 29/03/2024 08:02

Consultant : DR SAURABH JAIN

S. Coll. Date : 29/03/2024 13:20

Ward : -

Report Date : 29/03/2024 15:41

Urine R/M

Investigation	Result	Normal Value
Quantity - :	20 ml	
Colour - :	Pale Yellow	
Reaction (pH) :	5.0	4.6-8.0
Turbidity :	Clear	
Deposit :	Absent	Absent
Sp.Gravity :	1.020	1.005-1.010
Protein :	Absent	Absent
Glucose :	Absent	Absent
Bile Salts :	Absent	Absent
Bile pigments :	Absent	Absent
Ketones :	Absent	Absent
Urobilinogen :	Absent	
Blood :	Absent	Absent
Pus Cells :	2-4 /hpf	0-5/hpf
Red Blood Cells :	0-1 /hpf	Absent
Epithelial Cells :	4-6 /hpf	

Dr.Mehul Desai
M.B.D.C.P
Reg.No.G-9521



Unipath Specialty Laboratory (Baroda) LLP - Platinum Complex, Opp. HDFC Bank, Nr. Radha Krishna char rasta, Akota, Vadodara - 390020
 Phone: 0265-2334437 / 2326100 | Mobile: 7228800500 / 8155028222 | Email: info.baroda@unipathllp.in
 Home Visit / OPD Reception : 9998724579



TEST REPORT

Reg. No. : 40301017430 Reg. Date : 29-Mar-2024 12:27 Collected On : 29-Mar-2024 12:27
 Name : Mr. UPDESH MEENA Approved On : 29-Mar-2024 14:27
 Age : 33 Years Gender : Male Ref. No. : Dispatch At :
 Ref. By : Tele No. :
 Location : SAVITA SUPERSPECIALTY HOSPITAL @ WAGHODIYA ROAD

Test Name	Results	Units	Bio. Ref. Interval
THYROID FUNCTION TEST			
T3 (triiodothyronine) <i>Method:CLIA</i>	1.05	ng/mL	0.6 - 1.81
T4 (Thyroxine) <i>Method:CLIA</i>	10.00	µg/dL	4.5 - 12.6
TSH (ultra sensitive) <i>Method:CLIA</i>	2.987	µIU/mL	0.55 - 4.78
Sample Type:Serum			

Comments:
 Thyroid stimulating hormone (TSH) is synthesized and secreted by the anterior pituitary in response to a negative feedback mechanism involving concentrations of FT3 (free T3) and FT4 (free T4). Additionally, the hypothalamic tripeptide, thyrotropin-releasing hormone (TRH), directly stimulates TSH production. TSH stimulates thyroid cell production and hypertrophy, also stimulate the thyroid gland to synthesize and secrete T3 and T4. Quantification of TSH is significant to differentiate primary (thyroid) from secondary (pituitary) and tertiary (hypothalamus) hypothyroidism. In primary hypothyroidism, TSH levels are significantly elevated, while in secondary and tertiary hypothyroidism, TSH levels are low.

TSH levels During Pregnancy :

- First Trimester : 0.1 to 2.5 µIU/mL
- Second Trimester : 0.2 to 3.0 µIU/mL
- Third trimester : 0.3 to 3.0 µIU/mL

Reference : Carl A.Burtis,Edward R.Ashwood,David E.Bruns. Tietz Textbook of Clinical Chemistry and Molecular Diagnostics. 5th Eddition. Philadelphia: WB Saunders,2012:2170

----- End Of Report -----

This is an electronically authenticated report.

Test done from collected sample.

Printed On: 29-Mar-2024 14:27

We are open 24 x 7 & 365 days

Dr. Vishal Jhaveri
 M.B.B.S, D.C.P
 Reg. G-13041
 LLP Identification Number: AAN-8932
 Page 1 of 1



Examination by Ophthalmologist

Name: UPDESH MEENA

Reg. No: 20240309228

Age/ Sex: 33/MALE

DOE: 29/03/2024

Nil

Medical History:

Nil

Examination of Eye:

Right

LEFT

External Examination:

} curv

Anti seg Examination:

Schiot Tonometry IOP:

Fundus:

Without Glass Distant Vision: 6/6 6/6

Near Vision: N6 N6

With Glass Distant Vision: - -

Near Vision: - -

Colour Vision (With Ishihara Chart): curv

Impression:

curv

Advice:

Signature: _____



adv

Syp

Liv 52

2 tsf

BDS

x 1 month

- repeat LFT, Lipid profile
after 6 months.



Examination by Physicia

Name: UPDESH MEENA

Reg. No: 20240309228

Age/ Sex: 33/MALE

DOE: 29/03/2024

Physical Examination

Height: 183 cm Weight: 84 kg BMI: 25.08

Temperature: _____ Pulse: 52 BP: 124/80

Chief Complaints:

SPO2 - 99%
No active complain.

Past History:

NA.

Examination:

General Examination:

Systemic Examination:

Investigation:


RBS 100mg/dl

ECG WNL

Others _____

Advice: Dietary Modification, Exercise 45min/day.

Signature _____



J.S. Patil