

910030108  
 MR VIVEKANANDAN V  
 45 Years  
 Male

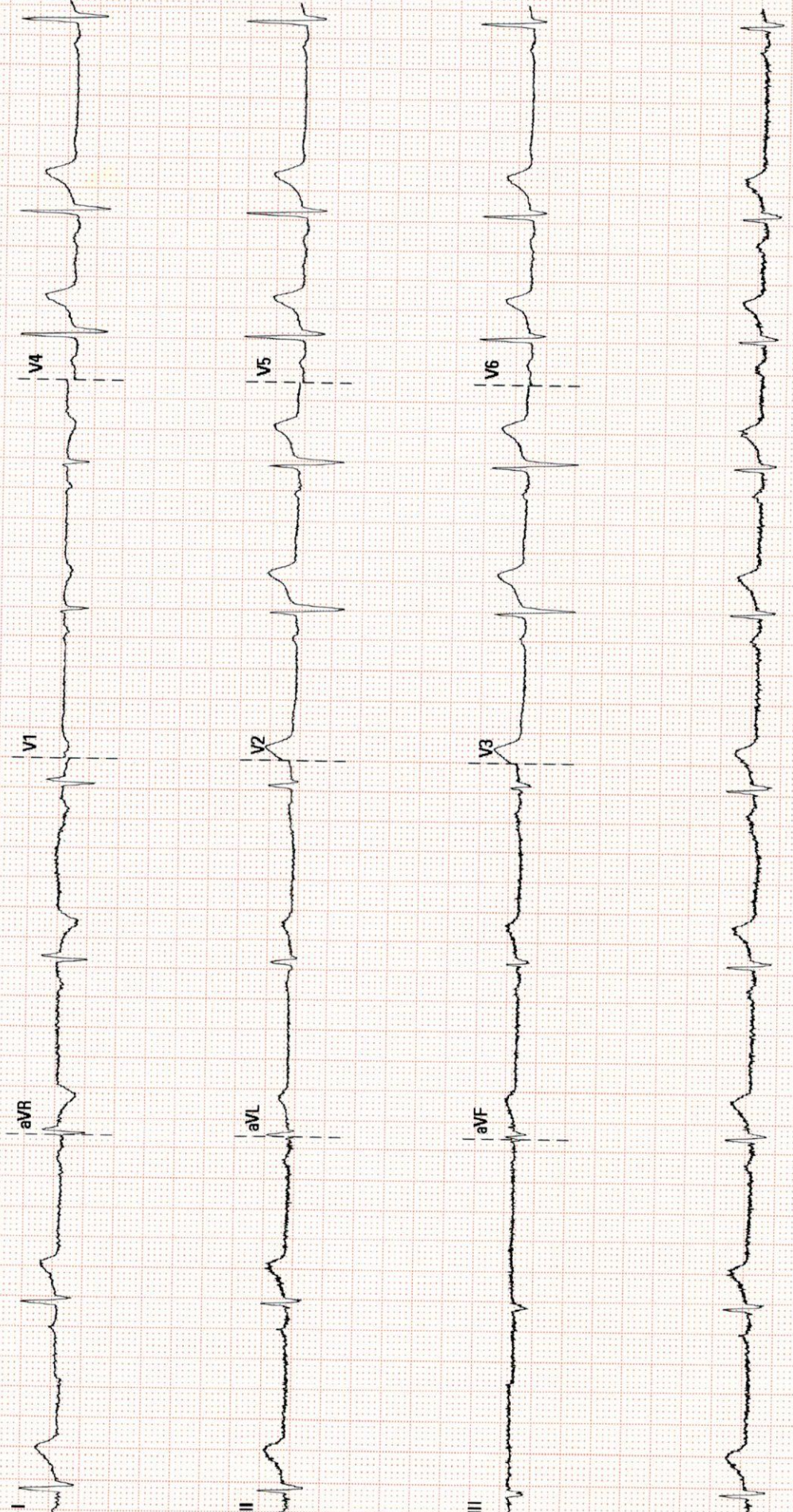
2024-03-28 09:09:08 AM

Vent. Rate 55 bpm  
 PR Interval 190 ms  
 QRS Duration 86 ms  
 QT/QTc Interval 384/375 ms  
 P/QRS/T Axes 34/-5/28 deg  
 QTc:Hodges

Sinus rhythm with PAC(s)  
 Borderline ECG

Unconfirmed Diagnosis

*Sin Brad* ✓





# PRASHANTH HOSPITALS

Name	: VIVEKANANDAN, V	UHID	: 910030108
Sex / Age	: M / 45Y	Accession NO	: 9121184889
Study Date	: 28/3/2024, 11:38:24 am	Report Date	: 28/3/2024, 11:46:39 am
Ref Dr.	: DR. GOPALASWAMY G		

## DEPARTMENT OF CARDIOLOGY

### INVESTIGATION: ECHO

#### LV MEASUREMENTS

AO	26 mm	IVS d/s	08/10 mm
LA	35 mm	LVPW d/s	07/09 mm
LVID (ED)	44 mm	EF	69 %
LVID (ES)	27 mm	FS	39 %

#### MORPHOLOGICAL DATA

MITRAL VALVE :	
AML	: NORMAL
PML	: NORMAL
CHORDAE	: NORMAL
AORTIC VALVE	: NORMAL
TRICUSPID VALVE	: NORMAL
PULMONARY VALVE	: NORMAL
ATRIA	: NORMAL
RIGHT VENTRICLE	: NORMAL FUNCTION (TAPSE : 2.0 cm)
INTER ATRIAL SEPTUM	: INTACT
INTER VENTRICULAR SEPTUM	: INTACT
AORTA	: NORMAL
PULMONARY ARTERY	: NORMAL
PERICARDIUM	: NORMAL

#### DOPPLER DATA :

MITRAL VALVE	: NORMAL E/A RATIO AT MITRAL INFLOW
	TRIVIAL MR E : 81 cm/s, A : 57 cm/s
	E/E' : 6.5 , S' : 9.5 cm/s
AORTIC VALVE	: NO AR, NO AS, VEL : 111 cm/s
PULMONARY VALVE	: NO PR, NO PS, VEL : 111 cm/s
TRICUSPID VALVE	: TRIVIAL TR / NO PAH / TRPG: 18 mmHg



# PRASHANTH HOSPITALS

Name	: VIVEKANANDAN, V	UHID	: 910030108
Sex / Age	: M / 45Y	Accession NO	: 9121184889
Study Date	: 28/3/2024, 11:38:24 am	Report Date	: 28/3/2024, 11:46:39 am
Ref Dr.	: DR. GOPALASWAMY G		

## IMPRESSION

- ❖ NO REGIONAL WALL MOTION ABNORMALITY
- ❖ NORMAL LV SYSTOLIC AND DIASTOLIC FUNCTION (LVEF: 69 %)
- ❖ NORMAL RIGHT VENTRICLE FUNCTION (TAPSE: 2.0 cm )
- ❖ NO PERICARDIAL EFFUSION
- ❖ NO EVIDENCE OF CLOT OR VEGETATION

DONE BY :KALPANA.M  
SR.ECHO TECHNOLOGIST

**Dr. Sivakumar**  
MBBS.MD.,DNB.,FNB  
Sr. Consultant Interventional Cardiologist  
Reg. No: 68984



# PRASHANTH HOSPITALS

Name	: VIVEKANANDAN, V	UHID	: 910030108
Sex / Age	: M / 45Y	Accession NO	: 180053134
Study Date	: 28/3/2024, 9:29:29 am	Report Date	: 28/3/2024, 3:26:48 pm
Ref Dr.	: DR. G . GOPALASWAMY		

## CHEST X-RAY

Trachea and both main bronchi are normal.

Cardiac silhouette and cardiothoracic ratio are normal

Bilateral lung fields are clear. No focal lesion seen.

The cardiophrenic and costophrenic angles are free.

Both hemi diaphragms appear normal.

Bony thorax appears normal.

### IMPRESSION:

No significant abnormality detected.

Dr. NARMADHA, MBBS., DMRD  
CONSULTANT RADIOLOGIST  
REG NO: 93293



# PRASHANTH HOSPITALS

Patient Name	Mr. Vivekanandan V	Age / Sex	45 Y/ M
Patient ID	910030108	Visit No.	1
Ref. By	Dr. G.Gopaldaswamy	Visit Date	28.03.2024

## USG Complete Abdomen

### Upper Abdomen:

Liver normal in size measures 11.8 cm and filled with homogeneous parenchymal echoes. No abscess or mass lesion in the liver. No dilatation of intrahepatic biliary radicals seen. Gall bladder walls and lumen appeared normal. No calculi seen. Common duct appeared normal. No calculi seen. Portal vein and Pancreas appeared normal. Spleen measured 10.2 cm and appeared normal. No free fluid seen in the hepatorenal pouch.

### KUB

RT. Kidney measures 10.9 x 5.9 cm. Cortex appears normal. Cortico medullary differentiation is maintained. Pelvicalyceal system is not dilated. No calculus is seen. Right ureter is not dilated.

LT. Kidney measures 10.8 x 4.6 cm. Cortex appears normal. Cortico medullary differentiation is maintained. Pelvicalyceal system is not dilated. No calculus is seen. Left ureter is not dilated.

Urinary Bladder is normal in contour. No intra luminal echoes are seen. No calculus or diverticulum is seen.

Prostate: Appears normal in size and measures 2.9 x 3.9 x 2.6 cm ( Vol = 15.3 cc ). It shows homogenous echogenicity. No intravesical extension.

Retroperitoneum: Aorta and IVC appears normal. No obvious para aortic lymphadenopathy. No free fluid in peritoneal cavity. Pleural spaces appeared normal.

### Impression:

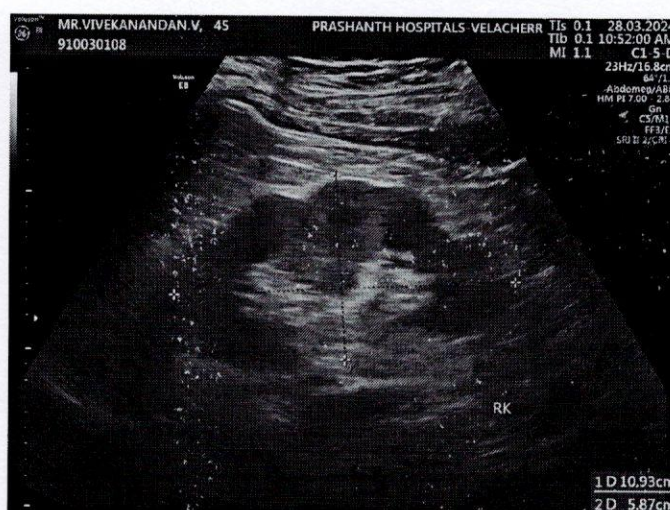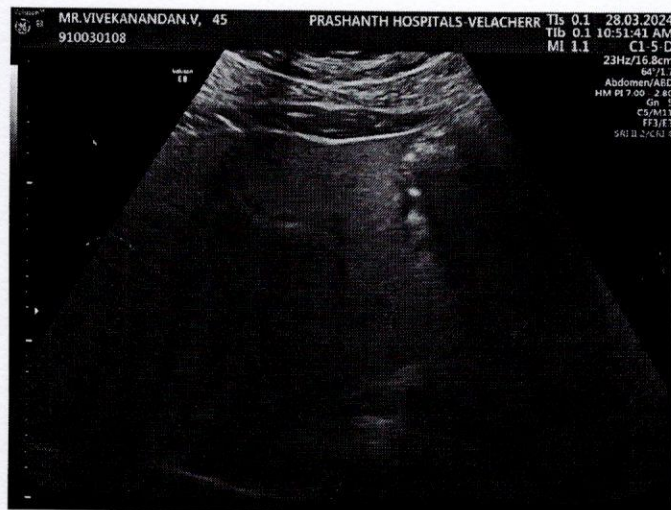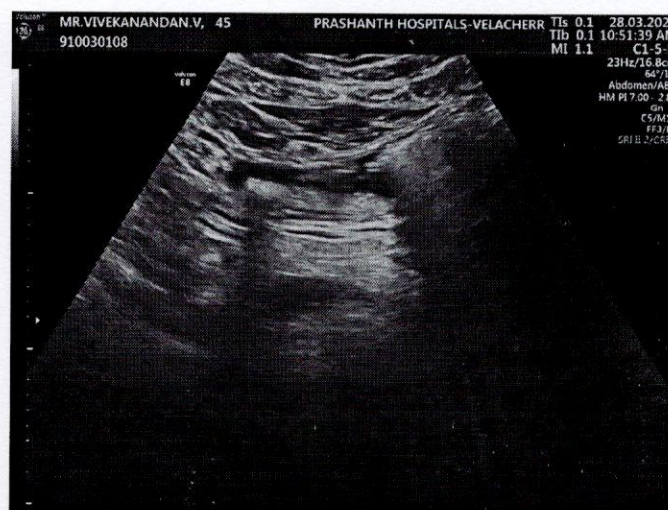
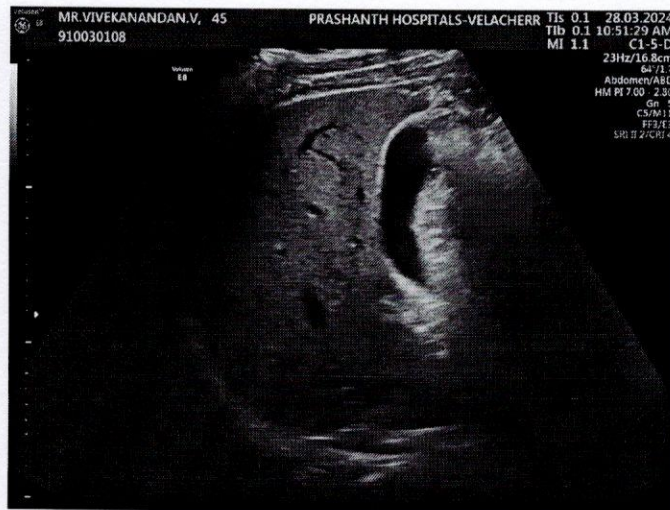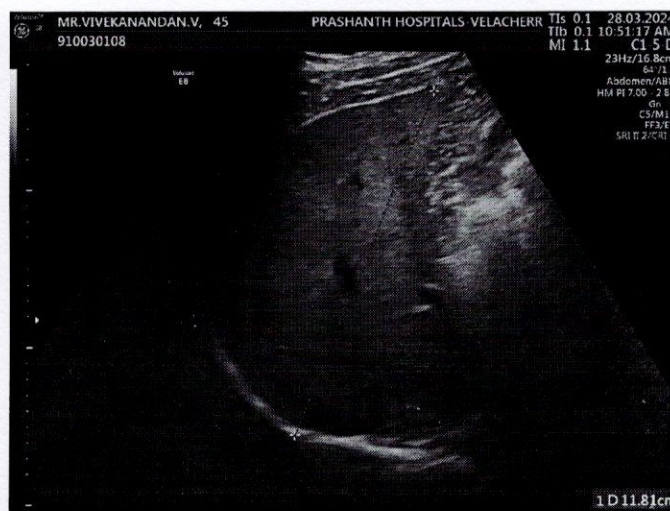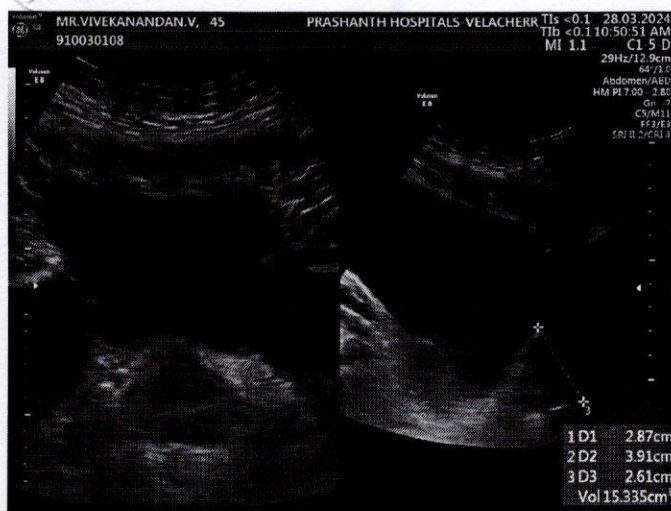- No significant abnormality detected in the visualized organs.

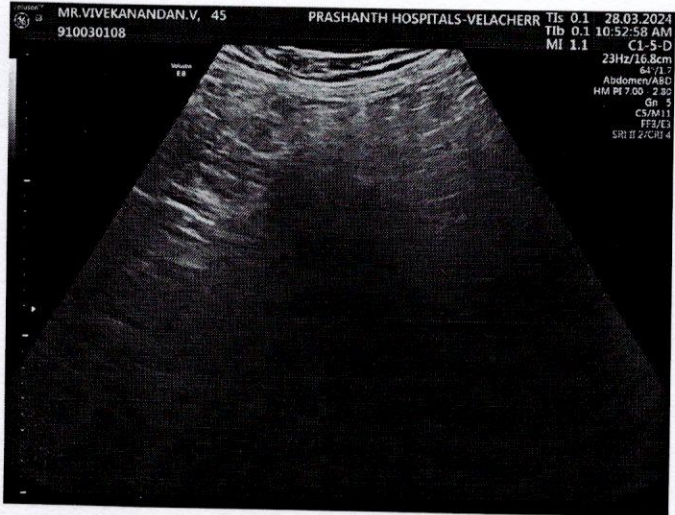
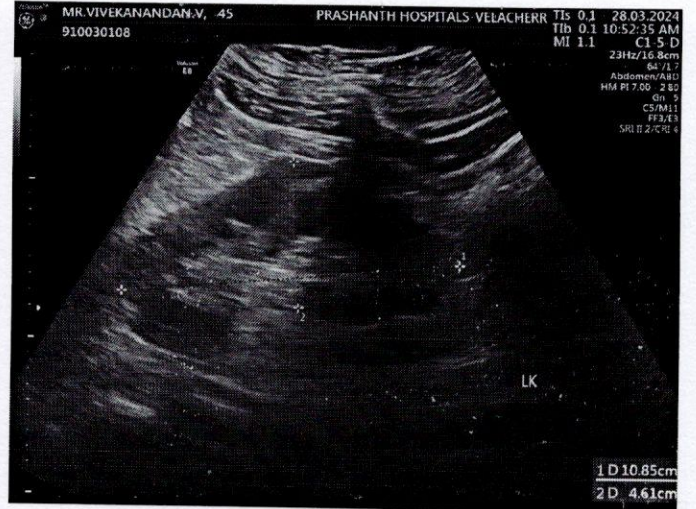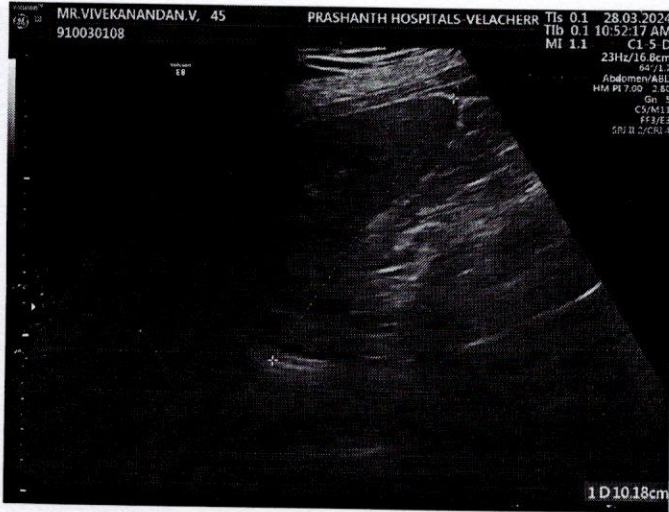
Dr. Narmadha, DMRD  
Consultant Radiologist  
Reg no : 93293

**Note:** This investigation has its own limitation. Hence sonographic findings should be correlated with clinical features and with further investigations. Not for medico legal purpose.

**A Unit of PRASHANTH FERTILITY RESEARCH CENTRE PVT. LTD.**

No. 26 & 26A, Velachery Main Road, Velachery, Chennai - 600 042. ☎ +91 93 8099 8099







# PRASHANTH HOSPITALS

## EYE CHECK-UP REPORT

NAME : Mr. Vinakaranan V

DATE : 28/3/24

AGE /SEX : 45/M

UHID NUM : 910030108

Chief complaints : Regular eye check up

Past history : —

Systemic Diseases : —

### DISTANCE VISION :

WITH OUT GLASS : 6/6, N6<sup>st</sup> 6/6, N8

WITH GLASS : — —

COLOR VISION :  NORMAL /  ABNORMAL

### GLASS PRESCRIPTION :

EYE	SPH	CYL	AXIS	V/A	SPH	CYL	AXIS	V/A
DISTANCE	± Plano	—	—	6/6	± Plano	—	—	6/6
ADD	+ 1.50	—	—	N6	+ 1.50	—	—	N6

ANTERIOR SEGMENT :

CORNEA & LENS : BE WNL

REMARK : CONTINUE WITH SAME GLASSE

ROUTINE CHECK UP AFTER 6/12 MONTH ✓

FUNDUSCOPY ONCE A YEAR

  
OPTOMETRIST