




भारत सरकार
Government of India

भारतीय विशिष्ट पहचान प्राधिकरण
Unique Identification Authority of India

नामांकन क्रम/ Enrolment No.: 0000/00587/41769

To
इंद्रप्रीत सिंह
Inderpreet Singh
C/O Jasbir Singh
I-5
New gobind pura
Krishna Nagar
East Delhi Delhi - 110051
9873757399

Signature Not Verified
Digitally signed by I.S.
UNIQUE IDENTIFICATION
AUTHORITY OF INDIA GS
Date: 2023.05.26 08:27:16
UTC



आपका आधार क्रमांक / Your Aadhaar No. :

7110 1378 4136

VID : 9185 1634 9855 7904

मेरा आधार, मेरी पहचान



भारत सरकार
Government of India



Issue Date: 14/11/2011



इंद्रप्रीत सिंह
Inderpreet Singh
जन्म तिथि/DOB: 27/08/1988
पुरुष/ MALE

7110 1378 4136

VID : 9185 1634 9855 7904

मेरा आधार, मेरी पहचान

MALIK RADIX HEALTH CARE PVT. LTD.

C-217, C-218, Nirman Vihar,
Delhi-110092

Ph.: 011-49287456, 011-61381379

Regd. No. 607

Scanned with CamScanner



Echocardiogram Report

Patient Name	MR. INDERPREET SINGH
Date of Test	09/04/2024
Age	35YRS/MALE
Ref. by	MEDIWHEEL

Dimensions	Result	Normal Range
AO (ed)	3.3 cm	(2.1 -3.7cm)
LA (es)	3.6 cm	(2.1 -3.7cm)
RVID (ed)	2.4 cm	(1.1-3.0cm)
LVID (ed)	4.6 cm	(3.6 – 5.5 cm)
LVID (es)	2.4 cm	(2.3-3.9cm)
IVS (ed)	1.0 cm	(0.6 – 1.2 cm)
LVPW (ed)	1.0 cm	(0.6 – 1.2 cm)
EF	60 %	
FS	30 %	(28 % - 42 %)

Impression

NO REGIONAL WALL MOTION ABNORMALITY SEEN.


LVEF= 60 %

NORMAL CHAMBERS DIMENSIONS.

NORMAL MIP

NORMAL COLOR FLOW.

NO INTRA CARDIAC CLOT/MASS/ VEGETATION/PERICARDIAL EFFUSION SEEN.


 Dr. Nishant Tyagi
 (M.D. Medicine. DNB Cardiology)
 (Consultant Non – Invasive Cardiologist)

Facilities Available

- Multispeciality Hospital - 24 Hours Emergency - X-Ray/ ECG/ Ultrasound/ CT Scan - Dental- Fully Equipped Operation Theatre
- Fully Functional Lab - 24/7 Casualty/ ICU-Nursery 24/7 Pharmacy - Labour Room - All Speciality OPD - Laproscopic Surgery - ECHO - Plastic Surgery

MAC600 1.02

ID: 9873757399

9-Apr-2024 10:57:10

ID: 9873757399

I

aVR

V1

V4

V4

II

aVL

V2

V5

V5

III

aVF

V3

V6

V6

IV

Auto gain applied

0.16-20Hz

25.0 mm/s

10.0||5.0 mm/mV

50Hz

93 bpm

± by 2.5s + 1 rhythm ld

̄̄̄

Indenpreet Singh

35years Male

Vent. rate 93 bpm

QRS duration 80 ms

QT/QTc 346/430 ms

PR interval 130 ms

P duration 100 ms

RR interval 645 ms

P-R-T axes 44 18 43

MAC600 1.02

12SL™ v239

Malik Radix HealthCare.

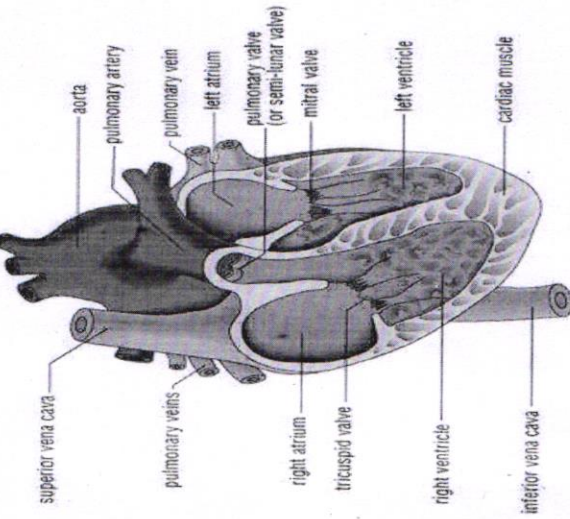
ELECTROCARDIOGRAM

Name: MR. INDERPREET SINGH

Age & Sex: 35YR/ MALE

Ref By: MEDIWHEEL

Date: 09/04/2024



ECG FINDINGS:

Rate 93 bpm Rhythm Sinus Mechanism Normal

Axis Normal P Wave Normal PR Interval 0.13/Sec

QRS Complex Normal QT Interval Normal Q Wave Normal

ST Segment Normal T Wave Normal

Conclusion Sinus Rhythm, Normal Axis, To be correlate.

Doctors Signature  **Dr. SHEIKH NAZIM AHMED**
M.D. "Physician"
PGDCC
DMC-46499



LAB REPORT

Reg. Date	09/04/2024	Patient Id	2404090002	DOB.	27/08/1988
Name	MR. INDERPREET SINGH	Gender	M	Perm. ID	
Age	35 Yrs. 7 Mn. 13 Day	Panel	MEDIWHEEL	Reported	09/04/2024 16:58:48
Ref. By	MEDIWHEEL				

Test Name	Result	Units	Ref. Range
MEDIWHEEL ANNUAL PLUS			

HAEMATOLOGY

COMPLETE HAEMOGRAM

HAEMOGLOBIN (HB%) 14.9 gm/dl 13 - 18

TOTAL LEUCOCYTE COUNT (TLC) 6,400 /cumm 4000 - 11000

DIFFERENTIAL LEUCOCYTE COUNT (DLC)

NEUTROPHIL 64 % 40 - 80

LYMPHOCYTE 31 % 28 - 55

MONOCYTE 04 % 02 - 10

EOSINOPHIL 01 % 01 - 06

BASOPHIL 00 % 0 - 0

ESR (WESTEGREN'S METHOD) 10 mm/Ist hr. 0 - 10

R B C COUNT 5.09 Millions/cmm 4.247 - 5.4

P.C.V / HAEMATOCRIT 47.3 % 40 - 54

M C V 92.9 fl. 80 - 100

M C H 29.3 Picogram 27.0 - 31.0

M C H C 31.5 gm/dl 33 - 37

PLATELET COUNT 1.67 Lakh/cu mm 1.50 - 4.50

BLOOD GROUP ABO " O "

RH TYPING Positive

BLOOD SUGAR FASTING 86.25 mg/dl 70 - 100

THYROID PROFILE

Free T3 ELFA 3.14 ng/ml 02 - 04

Free T4 ELFA 1.17 ug/dl 0.8 - 2.7

TSH Serum/ELFA 3.690 uIU/ml

Checked by : _____
Page 1 Contd...2

If test results are alarming or unexpected, patient is advised to contact the laboratory immediately for possible remedial action.

Facilities Available

- Multispeciality Hospital - 24 Hours Emergency - X-Ray/ ECG/ Ultrasound/ CT Scan - Dental- Fully Equipped Operation Theatre
- Fully Functional Lab - 24/7 Casualty/ ICU-Nursery 24/7 Pharmacy - Labour Room - All Speciality OPD - Laproscopic Surgery - ECHO - Plastic Surgery



LAB REPORT

Reg. Date	09/04/2024	Patient Id	2404090002	DOB.	27/08/1988
Name	MR. INDERPREET SINGH	Gender	M	Perm. ID	
Age	35 Yrs. 7 Mn. 13 Day	Panel	MEDIWHEEL	Reported	09/04/2024 16:58:48
Ref. By	MEDIWHEEL				

Test Name	Result	Units	Ref. Range
			0.25 - 5.50 uIU/ml

Interpretation

Clinical Use

- Diagnose Hypothyroidism and Hyperthyroidism
- Monitor T4 replacement or T4 suppressive Therapy
- Quantify TSH levels in the subnormal range

Increased Levels : Primary Hypothyroidism Subclinical Hypothyroidism, TSH dependent, Thyroid Hormone Resistance.

Decreased Levels : Grave's Disease, Autonomous Thyroid Hormone Secretion, TSH Deficiency

LIPID PROFILE

TOTAL CHOLESTEROL	201.90	mg/dL	130.0 - 200.0 (<200)
TRIGLYCERIDES	224.90	mg/dL	80.5 - 150.0 (<150)
H D L CHOLESTEROL DIRECT	57.71	mg/dL	35.0 - 60.0 (<40->59)
V L D L	45.0	mg/dL	4.0 - 30. (23-45)
L D L CHOLESTEROL	99.2	mg/dL	50.0 - 150.0 (50-150)
TOTAL CHOLESTEROL / HDL RATIO	3.5		3.3 - 5.1
LDL / HDL CHOLESTEROL RATIO	1.7		1.5 - 3.5

LIVER FUNCTION TEST (LFT)

BILIRUBIN TOTAL	1.85	mg/dl	0.2 - 1.2
CONJUGATED (D. BILIRUBIN)	0.22	mg/dl	0.00 - 0.3
UNCONJUGATED (I.D.BILIRUBIN)	1.63	mg/dl	0.2 - 0.9

Checked by : _____
Page 2 Contd...3

If test results are alarming or unexpected, patient is advised to contact the laboratory immediately for possible remedial action.

Facilities Available

- Multispeciality Hospital - 24 Hours Emergency - X-Ray/ ECG/ Ultrasound/ CT Scan - Dental- Fully Equipped Operation Theatre
- Fully Functional Lab - 24/7 Casualty/ ICU-Nursery 24/7 Pharmacy - Labour Room - All Speciality OPD - Laproscopic Surgery -
ECHO - Plastic Surgery



LAB REPORT

Reg. Date	09/04/2024	Patient Id	2404090002	DOB.	27/08/1988
Name	MR. INDERPREET SINGH	Gender	M	Perm. ID	
Age	35 Yrs. 7 Mn. 13 Day	Panel	MEDIWHEEL	Reported	09/04/2024 16:58:48
Ref. By	MEDIWHEEL				

Test Name	Result	Units	Ref. Range
SGOT / AST	23.90	IU/L	0 - 35
SGPT / ALT	40.5	IU/L	0 - 35
ALKALINE PHOSPHATASE	72.30	U/L	64 - 306
TOTAL PROTEIN	7.05	gm/dl	6.0 - 8.3
ALBUMIN	4.42	gm/dl	3.2 - 5.0
GLOBULIN	2.63	gm/dl	2.5 - 5.6
A/G RATIO	1.68		0.9 - 2.0
GAMMA GT	27.50	IU/L	0.0 - 45.0
SERUM CREATININE	0.80	mg/dl	0.7 - 1.4
SERUM URIC ACID	5.35	mg/dl	3.4 - 7.0
BLOOD UREA NITROGEN (BUN)	8.21	mg/dl	6.0 - 21.0
BUN/CREAT RATIO	10.26	mg/dl	10 - 20

Urine Routine Examination

PHYSICAL EXAMINATION

QUANTITY	50	ml.	
COLOUR	Pale Yellow		Pale Yellow
TRANSPARENCY	Clear		
SPECIFIC GRAVITY	1.015		
PH	6.0		

CHEMICAL EXAMINATION

ALBUMIN	Nil
SUGAR	Nil

MICROSCOPIC EXAMINATION

PUS CELLS	1-2	/HPF
RBC'S	Nil	/HPF
CASTS	Nil	

Checked by : _____
Page 3 Contd...4

If test results are alarming or unexpected, patient is advised to contact the laboratory immediately for possible remedial action.

Facilities Available

- Multispeciality Hospital - 24 Hours Emergency - X-Ray/ ECG/ Ultrasound/ CT Scan - Dental- Fully Equipped Operation Theatre
- Fully Functional Lab - 24/7 Casualty/ ICU-Nursery 24/7 Pharmacy - Labour Room - All Speciality OPD - Laproscopic Surgery - ECHO - Plastic Surgery



LAB REPORT

Reg. Date	09/04/2024	Patient Id	2404090002	DOB.	27/08/1988
Name	MR. INDERPREET SINGH	Gender	M	Perm. ID	
Age	35 Yrs. 7 Mn. 13 Day	Panel-	MEDIWHEEL	Reported	09/04/2024 16:58:48
Ref. By	MEDIWHEEL				

Test Name	Result	Units	Ref. Range
CRYSTALS	NIL		
EPITHELIAL CELLS	1-2	/HPF	
BACTERIA	Nil		
OTHERS	Nil		

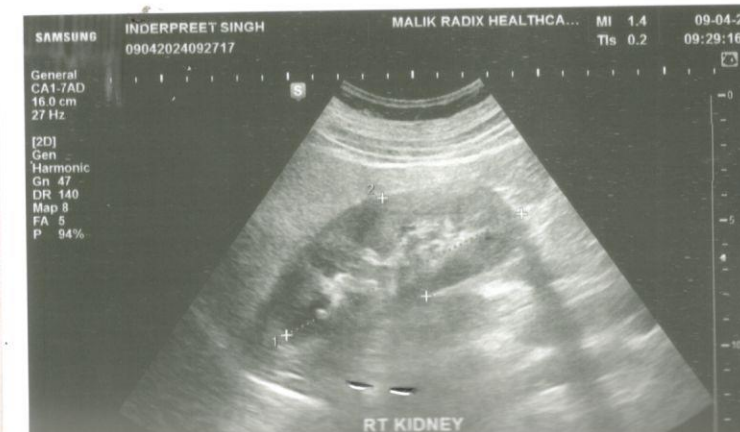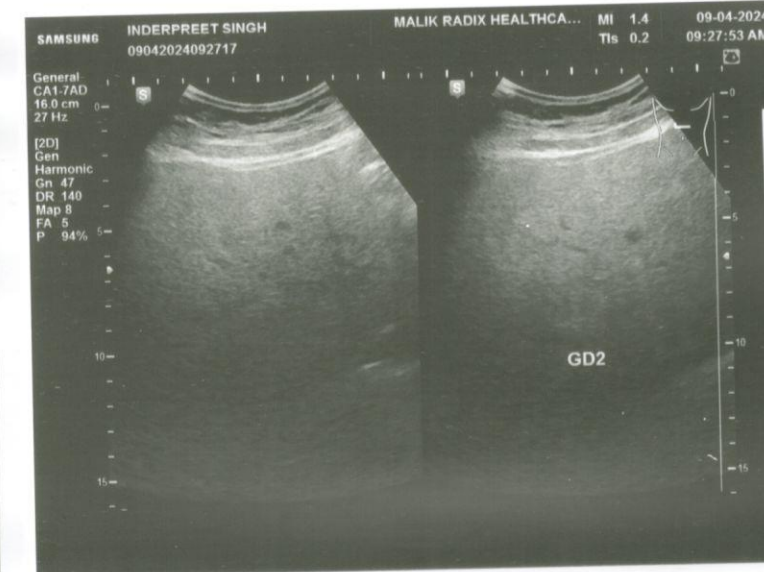
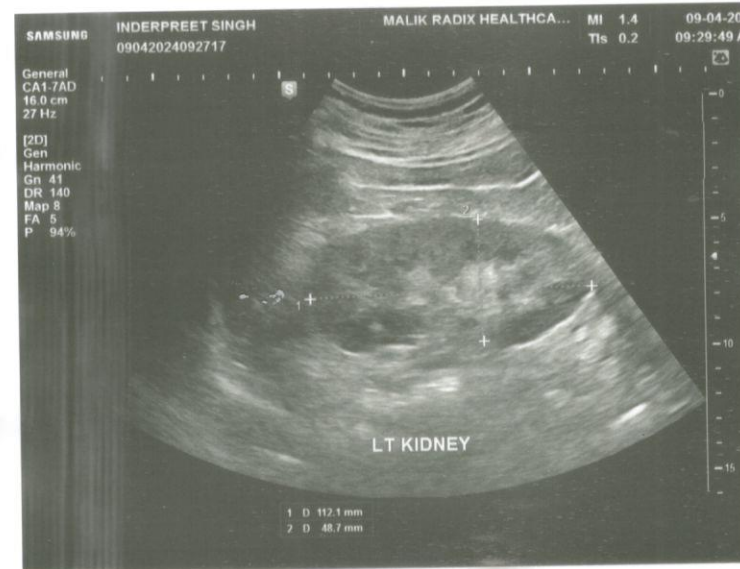
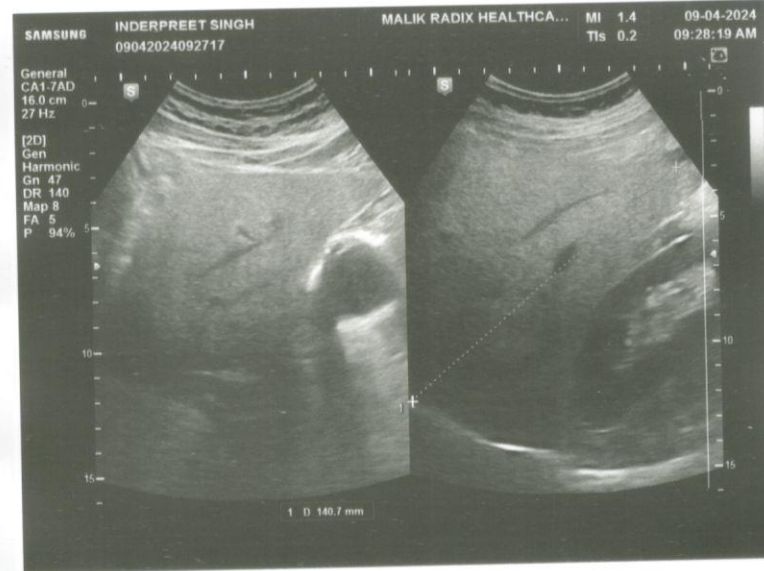
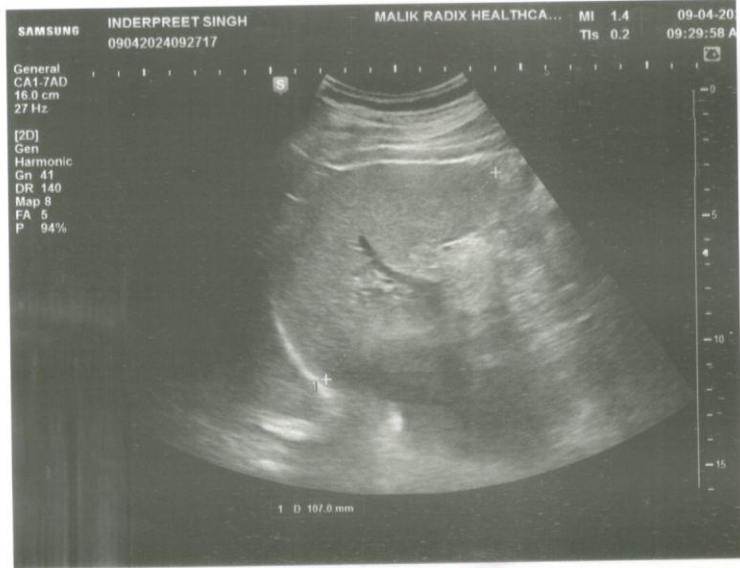
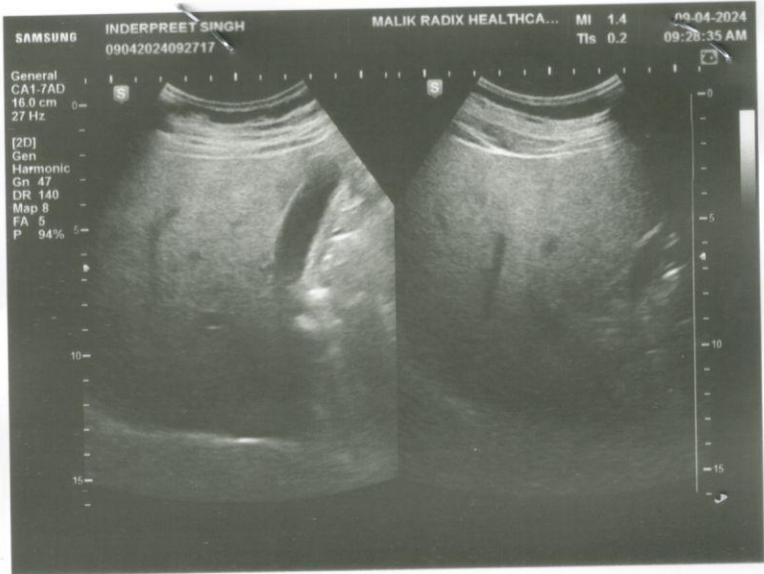
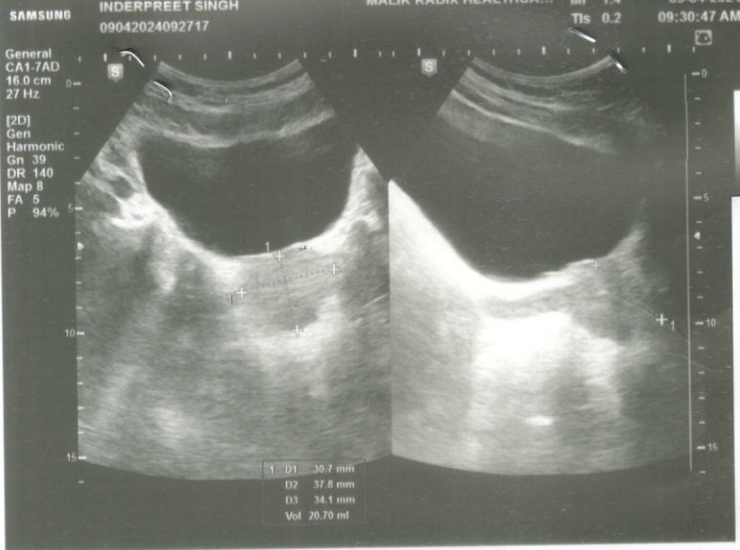
Dr. Reema Dahiya
DR. REEMA DAHIYA
 M.B.B.S, MD (Path)
 Checked by: Radix Healthcare Pvt. Ltd.
 C-217, C-218, Vikas Marg, Nirman Vihar,
 Delhi-92

DR. MEENU AGGARWAL
 M.B.B.S, MD (Path.)

If test results are alarming or unexpected, patient is advised to contact the laboratory immediately for possible remedial action.

Facilities Available

- Multispeciality Hospital - 24 Hours Emergency - X-Ray/ ECG/ Ultrasound/ CT Scan - Dental- Fully Equipped Operation Theatre
- Fully Functional Lab - 24/7 Casualty/ ICU-Nursery 24/7 Pharmacy - Labour Room - All Speciality OPD - Laproscopic Surgery - ECHO - Plastic Surgery



RADIX
HEALTH
care



Malik Radix Healthcare

C/217, C/218, Vikas Marg, Nirman Vihar, New Delhi-110092
A Unit of Malik Radix Healthcare
Toll Free - 1800-120-5457
Whatsapp No. - 9811550650
E-mail: info@radixhealthcare.org
Website: www.radixhealthcare.org



NAME	MR. INDERPREET SINGH	AGE	35 YRS/M
REFD. BY.	HEALTH CHECK UP	DATE	09.04.24

Ultrasound Examination of Whole Abdomen & Pelvis:

Liver: Liver appears normal in size (14.0 cm) with normal outlines and shows increased parenchymal echotexture. No focal SOL is seen in liver. IHBR & portal radicles are normal.

Gallbladder: Gallbladder is well distended. No evidence of cholecystitis or cholelithiasis seen. Common bile duct is normal in course & caliber.

Pancreas: Pancreas shows normal size, outlines & echotexture. No focal lesion is seen. MPD is not dilated.

Spleen: Spleen shows normal size (10.7 cm), outline & echotexture.

Kidneys: Kidneys show normal size, shape, position & echotexture. No calculus/ hydronephrosis or SOL is seen in kidneys. Cortico- medullary differentiation and cortical thickness is normal on both sides.

Right kidney measures -10.5 x 4.3 cm

Left kidney measures -11.2 x 4.8 cm

Great abdominal vessels are normal.

No ascites seen.

No para-aortic lymph nodes seen.

Urinary bladder Urinary bladder is well distended. Walls and lumen appear normal.

Prostate is normal in size (20.7 cc) with normal outline and echotexture. No focal lesion is seen.

IMPRESSION:

Grade II Fatty Liver

Dr Shreyash Tiwary MD (Rad- diag)

Regn. No. DMC 85802

RADIOLOGIST :

Facilities Available

- Multispeciality Hospital - 24 Hours Emergency - X-Ray/ ECG/ Ultrasound/ CT Scan - Dental - Fully Equipped Operation Theatre
- Fully Functional Lab - 24/7 Casualty/ ICU-Nursery 24/7 Pharmacy - Labour Room - All Speciality OPD - Laproscopic Surgery -