

**DAKSH HOSPITAL**

396 - 397, Gandhi Nagar, Scheme No. 8, ALWAR - 301001

Ref. No.

Date.....

**MEDICAL EXAMINATION REPORT**  
Mediwheel (BOB)

Name: Mr. Bijendra Kumar Garg

Age: 37 yrs

Sex: Male

Date: 13/04/2024

**General Physical Examination**Height : 171 cm  
Pulse : 78 mt  
Respiration : 18/mtWeight : 107 kg  
BP : 120/80 mm/hg  
BMI : 36.6 kg/m<sup>2</sup>**Systemic Exam:-**

Normal

**Dental Check up:-**

Normal

**Eye check-up:-**

Normal

**Skin Check up:-**


Normal

**ENT Check up:-**

Normal

**Impression:-**

- obesity (Bmi 36.6 kg)
- fatty liver, oT/APT 57/67.

**Recommendation:-**Life style modification  
wt reduction
  
 Dr. Mukesh Kumar Gupta  
 MD Gen. Medicine  
 Reg. No 5423/16262

**डॉ० मुकेश गुप्ता**  
**M.D.F.C.C.S.**  
 फिजिशियन एवं मधुमेह रोग विशेषज्ञ  
 दक्ष हॉस्पिटल, अलवर  
 रजि० नं०-5423/16262

## Results

Run Date 13/04/2024 10:09:58 AM

Operator DAKSH

Last Name

Sample ID 4

First Name MR BIJENDRA

Department

Gender Male

Age

Physician DR. MUKESH GUPTA M.D

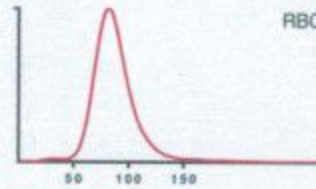
Patient ID AUTO\_PID20879

Type Man

Date of birth

Sample comments

				Range
RBC	5.12	*	10 <sup>6</sup> /μL	3.80 - 5.50
HGB	13.9		g/dL	13.0 - 17.0
HCT	44.9	*	%	39.0 - 52.0
MCV	87.6	*	μm <sup>3</sup>	76.0 - 100.0
MCH	27.2		pg	26.0 - 34.0
MCHC	31.0	L	g/dL	32.0 - 35.0
RDW-CV	18.3	H	%	11.0 - 16.0
RDW-SD	62.5	H	μm <sup>3</sup>	37.0 - 49.0



### Recommended actions


Slide review

### Susp. Pathologies

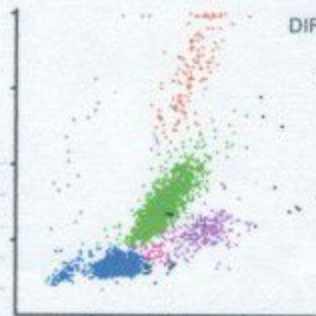
Anisocytosis

Macroplatelets

				Range
PLT	199	*	10 <sup>3</sup> /μL	150 - 450
PCT	0.28	*	%	0.15 - 0.40
MPV	13.9	H*	μm <sup>3</sup>	8.0 - 11.0
PDW	34.6	H*	μm <sup>3</sup>	11.0 - 22.0
P-LCC	114		10 <sup>3</sup> /μL	44 - 140
P-LCR	57.1	h	%	18.0 - 50.0



			Range		Range
WBC	5.79		10 <sup>3</sup> /μL	3.50 - 10.00	
	#		Range	%	Range
NEU	2.63		1.60 - 7.00	45.6	40.0 - 75.0
LYM	2.74		1.00 - 3.00	47.6	20.0 - 45.0
MON	0.11	l	0.20 - 0.80	1.8	2.0 - 10.0
EOS	0.21		0.00 - 0.50	3.6	1.0 - 6.0
BAS	0.08		0.00 - 0.15	1.4	0.0 - 1.0
LIC	0.02		0.00 - 0.10	0.4	0.0 - 1.0



*Dr. R.S. Gupta*  
**Dr. R.S. GUPTA**  
 MD (Pathology) (MAHE)  
 RMC No. 7924/19778

13/04/2024 10:11:10 AM

Printed by : DAKSH

S/N 107YOXH04136

1

Doctor

TECHNOLOGIST

All investigation have their own limitations regarding the sensitivity & specificity of individual assay procedures, Isolated laboratory investigations never confirm the final diagnosis of the disease. They only help in arriving at a diagnosis in conjunction with clinical presentation and other related investigations. Report is not valid for medico-legal purpose subject to ALWAR jurisdiction only.



Date :-13/04/2024

Name :- MR.BIJENRA KUMAR GUPTA

Age & Sex :- 37 Yrs/ male

Refd. :- Dr Mukesh Gupta M.D.

	TEST NAME	RESULT	REFERENCE RANGE	
	ESR	10	00 -20 mm/hrs	
	Blood Group & Rh Factor	O " POSITIVE		
	HbA1C	5.0	4 - 5.6%	
	Blood Sugar (R)	106.1	< 140mg/dl	
	Blood Sugar (PP)	-	< 140 mg/dl	
	Urine Sugar (F)	NIL	-	
	Urine Sugar (PP)	-	-	
<b>LIVER</b>	S.Bilirubin Total	0.95	0.30 - 1.20 mg/dl	
	S.Bilirubin Direct	0.20	0.10 - 0.30 mg/dl	
	S.Bilirubin Indirect	0.75	0.30 - 0.90 mg/dl	
	S.G.O.T.	57	> 37 u/l	
	S.G.P.T.	67	> 40 u/l	
	S.Alk. Phosp.	276	80 - 306 u/l	
	G.G.T.	32	5 -40 u/l	
	Total Protein	7.0	6.5 - 8.5 gm/dl	
	Albumin	4.0	3.8 - 5.4 gm/dl	
	Globulin	3.0	2.3 - 3.5 gm/dl	
	A/G Ratio	1.3	-	
	AST/ALT Ratio	0.8	-	
<b>KIDNEY</b>	Blood Urea	37.5	15 -45 mg/dl	
	S.Creatinine	0.94	0.60 - 1.30 mg/dl	
	BUN	18	6 -24 mg/dl	
	S.Uric Acid	5.2	M 3.1 - 7.0, F 2.5 - 5.6 mg/dl	
	BUN/Creatinine Ratio	1.1	-	
<b>LIPID PROFILE</b>	Total Cholesterol	165.1	Up to 200 mg/dl	
	S.HDL	43.1	30 - 70 mg/dl	
	S.LDL	85.1	Up to 170 mg/dl	
	S.VLDL	37.1	5.0 - 40 mg/dl	
	S. Triglycerides	185.1	Up to 170 mg/dl	
	LDL/HDL Ratio	1.9	-	
	Total Cholesterol/ HDL Ratio	3.8	-	
<b>THYROID</b>	T3	102.1	40 - 181 ng/dl	
	T4	7.8	4.6 - 10.5 µg/dl	
	TSH	4.43	0.30 - 5.0 mIU/l	
	<b>URINE EXAMINATION</b>		<i>Microscopic Examination:</i>	
<b>General/Chemical Examination:</b>	Colour	Pale Yellow	RBC	Absent
	Reaction	Acidic	WBC	2-3
	Specific Gravity	QNS	Epithelial Cells	0-1
	Appearance	Clear	Cast	Absent
	Albumin	Nil	Crystal	Absent
	Sugar	Nil	Spermatozoa	Absent
			Amorphous Sediments	Absent
			Other	Absent
<b>X-RAY CHEST</b>	NORMAL STUDY			
	<b>STOOL EXAMINATION</b>		<i>Microscopic Examination:</i>	
<b>General/ Chemical Examination:</b>			RBC	-
	Colour	-	WBC	-
	Consistency	-	Ova & Parasites	-

*R.S.G.*  
**Dr. R.S. GUPTA**  
 MD (Pathology) (MAHE)  
 RMC No. 7924/19778  
 Doctor

**TECHNOLOGIST**

All investigation have their own limitations regarding the sensitivity & specificity of individual assay procedures. Isolated laboratory investigations never confirm the final diagnosis of the disease. They only help in arriving at a diagnosis in conjunction with clinical presentation and other related investigations. Report is not valid for medico-legal purpose subject to ALWAR jurisdiction only.





# दक्ष हॉस्पिटल

396, गाँधी नगर स्कीम नं.8, अलवर (राज०) ☎ 0144-2703340

## Sonography / 2D Echo Cardiography / Doppler Report

### 2D/ ECHO REPORT

Name: - Mr Brijendra Kumar Age: - 37 Yrs Date: - 13-Apr-24

Reg. No.: - Alw/2009/04  
BOB health checkup

PROCEDURES: M-MODE/2D/DOPPLER/COLOR/CONTRASTB.A.S. M<sup>2</sup>

MEASUREMENT:		DOPPLER:			
		NORMAL		NORMAL (cm/sec.)	
AOD	27	(20- 37mm)	MV 1.0	(0.8- 1.3)	MR No
LA	26	(19- 40mm)	AV 1.8	(1.2- 1.8)	AR No
AVO	17	(12- 25mm)	TV 0.6	(0.3- 0.8)	TR No
RVDd.	18	(03- 09mm)	PV 0.8	(0.7- 1.1)	PR No
LVDd	53.7	(37- 56mm)	MITRAL VALVE-		
LVDs	29	(22- 40mm)	AML		Normal
IVS d	9.7	(06- 12mm)	PML		Normal
IVS s	16.8		AORTIC VALVE		
PWd	7.8	(05- 10mm)			Normal
LV FUNCTION		TV & PV are normal.			
M- E- S Separation		<0.9cm			
Minor		24.42%			
LV Ejection Fraction	77%	65 +/- 12%			

POOR ECHO WINDOW  
MITRAL E>A  
LV WALL MOTION: NO RWMA  
ALL CARDIAC CHAMBERS ARE NORMAL  
ALL VALVES ARE NORMAL  
NO CLOT, VEGETATION, PERICARDIAL EFFUSION

Adv: - Follow up/ review at higher center for confirmation

Note:- Please Correlate clinically. Due to technical limitations as well as inaccuracies inherent in the laboratory and statistical analysis of biological process. Diagnostic accuracy of ECHO is up to 95% only.  
Report is not valid for medico-legal purpose.

DR. MUKESH GUPTA

Dr. Mukesh Kumar Gupta

Physician & Sonologist

RM 5423/16262



भ्रूण लिंग परीक्षण की शिकायत  
104 टोल फ्री सेवा पर भी की

जा सकती है। भ्रूण लिंग परीक्षण की शिकायत 104 टोल फ्री सेवा पर भी की जा सकती है।



# दक्ष हॉस्पिटल

396, गाँधी नगर स्कीम नं.8, अलवर (राज०) ☎ 0144-2703340

## Sonography / 2D Echo Cardiography / Doppler Report

Name: MR. BRIJENDRA KUMAR /M/37 YRS

Date: 13-Apr-24

BOB HEALTH CHECK UP

### U.S.G. OF ABDOMEN & PELVIS

#### LIVER

Liver is **14.8 cm with mild increase echogenicty**. Intra hepatic biliary radicals are not dilated. No evidence of focal or diffuse lesion.

#### GALL BLADDER

Gall bladder is normal dilated. Lumen clear. Wall thickness normal. CBD normal

#### PANCREAS

Pancreas is normal in size, shape & echo-texture.

#### SPLEEN

8.2 cm in size with normal shape & echo- texture.

#### BOTH KIDNEY

Both kidney normal shape, size & echo texture. CMD maintained

PROSTATE is normal shape, size (14gm) & echo texture..

URINARY BLADDER is partially distended, visualized lumen appear clear.

**Thick abdominal wall.**

Impression:- Grade I fatty liver.

Please correlate clinically. USG accuracy is 95 % due to technical limitations as well as inaccuracies inherent in the laboratory and statistical analysis biological process.

This report is not valid for medico-legal cases.

  
DR. MUKESH GUPTA  
SONOLOGIST  
Dr. Mukesh Kumar Gupta  
Physician & Sonologist  
RM 5423/16262



"भ्रूण लिंग परीक्षण की शिकायत  
104 टोल फ्री सेवा पर भी की  
जा सकती है"

भ्रूण लिंग परीक्षण की शिकायत 104 टोल फ्री सेवा पर भी की जा सकती है।



06-04-2024 02:43:29 PM

ID: bijenda

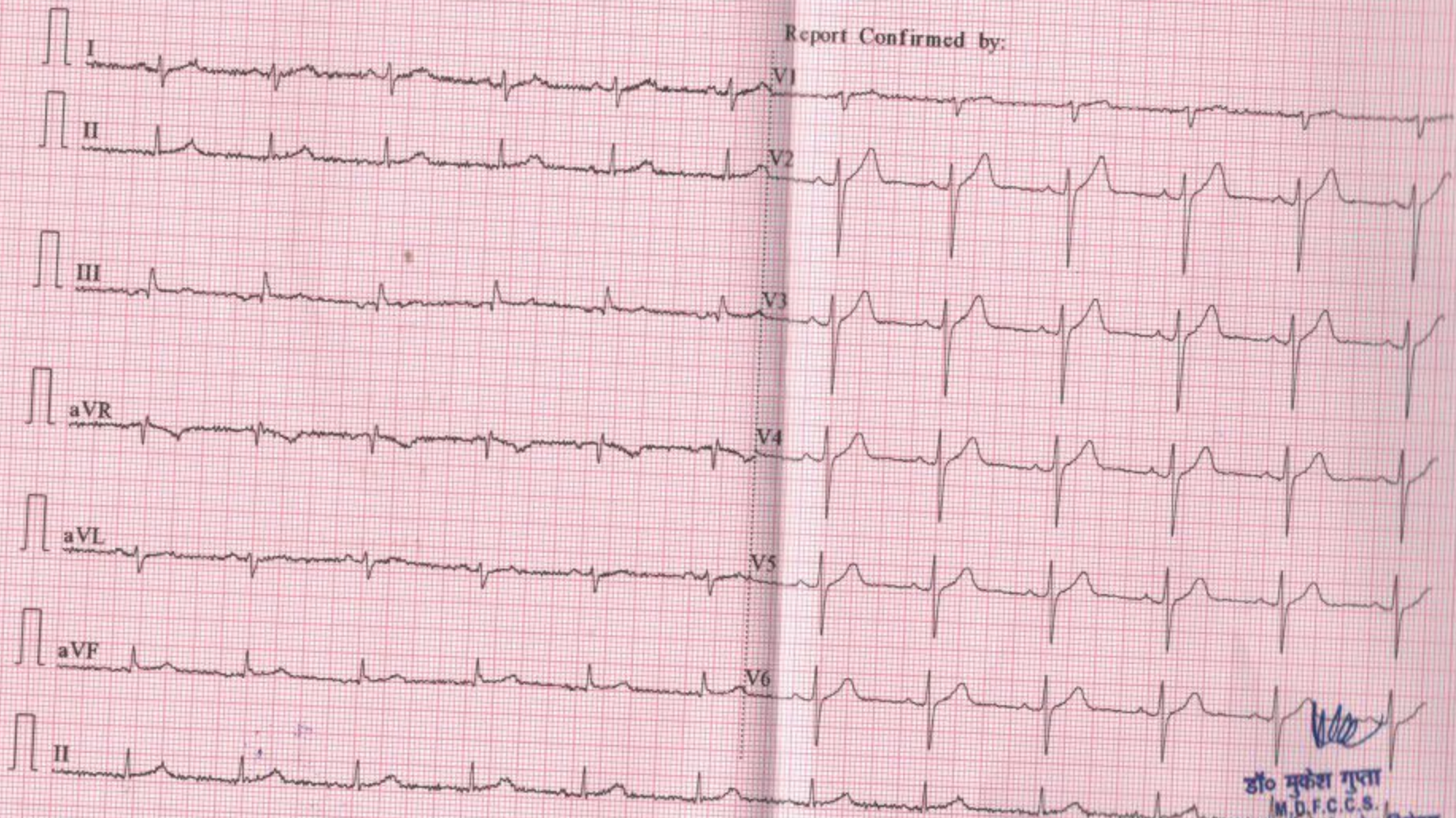
CARDIART

male Years

HR	:	71	bpm
P	:	107	ms
PR	:	157	ms
QRS	:	84	ms
QT/QTc	:	361/394	ms
P/QRS/T	:	-11/94/36	°
RV5/SV1	:	0.644/0.269	mV

Diagnosis Information:  
Sinus Rhythm  
Right Axis Deviation

Report Confirmed by:



डॉ० मुकेश गुप्ता  
M.D.F.C.C.S.  
फिजिशियन एवं प्रोथेज रीपेय विशेषज्ञ  
श्री. श्री. अस्पताल, अजमेर



R

