

Transport Department Government of Delhi
Licence to Drive Vehicles Throughout India

Licence No. : DL-1320100052656 (P) B1
 Name : SHUBHAM SINGHAL
 S/W/D : PARDEEP KUMAR SINGHAL
 DOB : 15/08/1991 BG: U
 Address :
 299/OLD POST OFFICE STREET
 CIRCULAR ROAD SHAHDARA DELHI
 110032

Authorization to Drive Date of Issue
 M.CYL. 24/04/2010
 LMV-NT 24/04/2010

Issue Date : 24/04/2010
 Validity : 23/04/2030
 Inv Carr No : NA

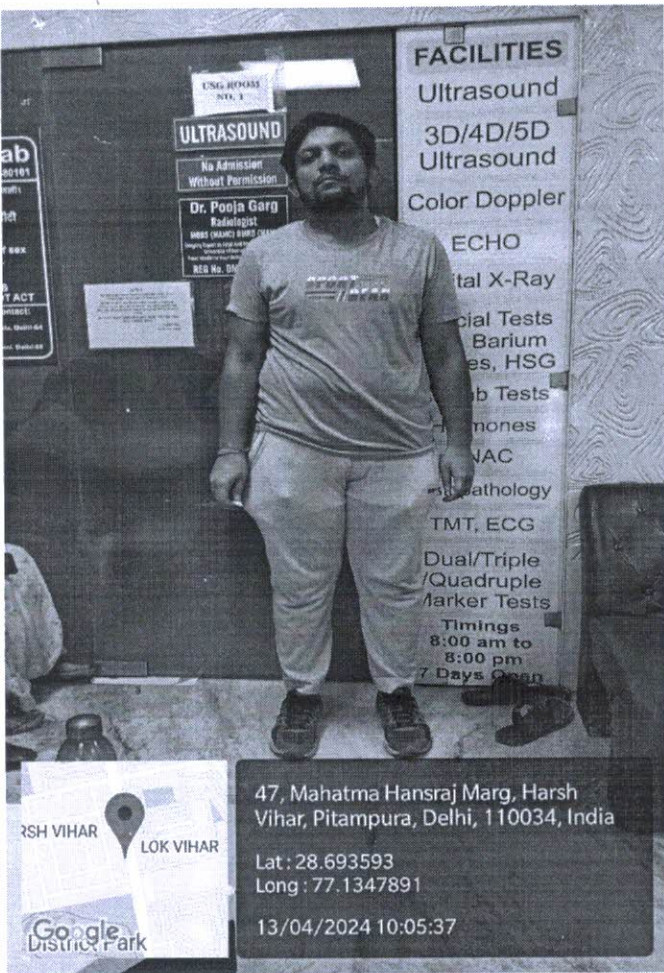
Shubham
 (Holder's Signature)

[Signature]
 Issuing Authority (EZ-II)

Shubham

ONEPLUS ULTRASOUND LAB
 47 Harsh Vihar, Pitam Pura,
 Delhi-110034
 Ph. 011-42480101, 9590913051
 E-mail onepplus@gmail.com

[Signature]
Dr. NITIL AGARWAL
 MBBS, MD
 Regn. No. DMC-R-1436



Shubham

ONEPLUS ULTRASOUND LAB
47 Harsh Vihar Pitampura,
Delhi-110034
Ph. 011-42480101, 9599913051
E-mail onepusul@gmail.com

Dr. MITHAGAL
M.D., M.S., MD
Regn. No. DMC-R-1436



OnePLUS
Ultrasound Lab
— QUALITY FIRST... ALWAYS! —

Dr. Nitin Agarwal

Pathologist & Director
MBBS, MD, FAGE
Ex. Chief of Lab
Dr. Lal Path labs.

Dr. Pooja (Garg) Agarwal

Radiologist & Director
MBBS (MAMC) DMRD (MAMC)
Imaging Expert In Fetal And Maternal Medicine,
University of Barcelona, Spain
Fetal Medicine Foundation (UK) Accreditation

18/04/2024

TO
oneplus ultrasound lab

Dear Sir/Madam

I do not want to give my school for school test

Yours Sincerely

Shubham Singhhal

9958353315

ONEPLUS ULTRASOUND LAB
47 Harsh Vihar, Pitam Pura,
Delhi-110034
Ph. 011-42480101, 9599913051
E-mail onepusul@gmail.com

Dr. NITIN AGARWAL
MBBS, MD
Regn. No. DMC-R-1436

47, Harsh Vihar, Pitampura, Delhi-34 ☎ 011-4248 0101, 9599913051

✉ Email: onepusul@gmail.com 🌐 www.oneplusul.in

- Clinical correlation is essential for final diagnosis. • If test results are unsatisfactory please contact personally or on phone.
- This report is for perusal of doctors only. • All disputes are subject to Delhi jurisdiction only. • Not for medico legal case.
- All congenital anomalies in a foetus may not be diagnosed in routine obstetric ultrasound.



NAME	:Mr. SHUBHAM SINGHAL	Barcode No	:10169516
AGE/GENDER	:32 YRS/Male	SPECIMEN DATE	:13/Apr/2024 09:30AM
PATIENT ID	:133950	SPECIMEN RECEIVED	:13/Apr/2024 09:58AM
REFERRED BY	:Dr. MEDIWHEEL	REPORT DATE	:13/Apr/2024 03:46PM
CENTRE NAME	:ONEPLUS ULTRASOUND LAB	LAB NO.	:012404130015

Test Name	Result	Unit	Ref. Range
-----------	--------	------	------------

HAEMATOLOGY

MediWheel Health checkup < 40 Male

Sample Type:EDTA Blood

ESR

Modified Westergrens Method

10

mm in 1st hr

upto 10.4

Comments:

Increased

- In most infections, anaemias, injection of foreign proteins, auto-immune disorders, conditions accompanied by hyperglobunemia and hypercholesterolaemia.
- A rising ESR suggests a progressive disease.

Decreased

- In polycythemia, congestive heart failure.

Glycosylated Hemoglobin (HbA1c)

HPLC

5.5

%

Non Diabetic adults <5.7
Prediabetic (at risk) 5.7-6.4
Diabetes >6.4

Estimated average blood glucose (eag)

CALCULATED

111

Reference range (mg/dl):

90 - 120:Excellent control, 121 - 150:Good Control, 151 - 180:Average Control, 181 - 210:Action Suggested

>211:Panic value

Dr. NITIN AGARWAL

MBBS, MD

Regn. No. DMC-R-1436

DR. NITIN AGARWAL
MBBS,MD(PATHOLOGIST)

Checked By.



OnePLUS

Ultrasound Lab

QUALITY FIRST... ALWAYS!

Dr. Nitin Agarwal

Pathologist & Director
MBBS, MD, FAGE
Ex. Chief of Lab
Dr. Lal Path labs.

Dr. Pooja (Garg) Agarwal

Radiologist & Director
MBBS (MAMC) DMRD (MAMC)
Imaging Expert In Fetal And Maternal Medicine,
University of Barcelona, Spain
Fetal Medicine Foundation (UK) Accreditation



NAME	:Mr. SHUBHAM SINGHAL	Barcode No	:10169516
AGE/GENDER	:32 YRS/Male	SPECIMEN DATE	:13/Apr/2024 09:30AM
PATIENT ID	:133950	SPECIMEN RECEIVED	:13/Apr/2024 09:58AM
REFERRED BY	:Dr. MEDIWHEEL	REPORT DATE	:13/Apr/2024 03:46PM
CENTRE NAME	:ONEPLUS ULTRASOUND LAB	LAB NO.	:012404130015

Test Name	Result	Unit	Ref. Range
-----------	--------	------	------------

HAEMATOLOGY

BLOOD GROUP (ABO)

Forward and Reverse grouping (Slide & Tube)

B

Rh typing

POSITIVE

NOTE :

- * Apart from major A,B,H antigens which are used for ABO grouping and Rh typing, many minor blood group antigens exist. Agglutination may also vary according to titre of antigen and antibody.
- * So before transfusion, reconfirmation of blood group as well as cross-matching is needed.
- * Presence of maternal antibodies in newborns, may interfere with blood grouping.
- * Auto agglutination (due to cold antibody, falciparum malaria, sepsis, internal malignancy etc.) may also cause erroneous result.

Checked By.

Dr. NITIN AGARWAL
MBBS, MD

Regn. No. DMC-K-1436

DR. NITIN AGARWAL
MBBS,MD(PATHOLOGIST)



NAME	:Mr. SHUBHAM SINGHAL	Barcode No	:10169516
AGE/GENDER	:32 YRS/Male	SPECIMEN DATE	:13/Apr/2024 09:30AM
PATIENT ID	:133950	SPECIMEN RECEIVED	:13/Apr/2024 09:58AM
REFERRED BY	:Dr. MEDIWHEEL	REPORT DATE	:13/Apr/2024 03:46PM
CENTRE NAME	:ONEPLUS ULTRASOUND LAB	LAB NO.	:012404130015

Test Name	Result	Unit	Ref. Range
-----------	--------	------	------------

HAEMATOLOGY

CBC

Haemoglobin Non cyanide Hb analysis	14.7	g/dl	13.0-17.0
Total Leucocyte Count Electrical Impedance	7800	/cumm	4000-10000
Differential leucocyte count			
Neutrophils Electrical Impedance & Microscopic	40.7	%	40-80
Lymphocyte Electrical Impedance & Microscopic	52.50	%	20-40
Monocytes Electrical Impedance & Microscopic	4.00	%	2-10
Eosinophils Electrical Impedance & Microscopic	2.0	%	1-6
Basophils Electrical Impedance & Microscopic	0.8	%	0-2
RBC Count Electrical Impedance	5.00	million/cumm	4.5 - 5.5
Hematocrit(PCV) Flow Cytometry	44.9	%	40-50
MCV Calculated	90.8	fl	83-101
MCH Calculated	29.7	pg	27-32
MCHC Calculated	32.7	g/dL	31.5-34.5
RDW-CV Calculated	14.4	%	11.4-14.0
Platelet count Electrical Impedance	416000	/cumm	150000-410000

BIOCHEMISTRY

Sample Type:Fluoride F

Blood sugar fasting GOD-POD	80	mg/dl	70-100 mg/dl
---------------------------------------	----	-------	--------------

Checked By.

DR. NITIN AGARWAL
MBBS, MD
Reg. No. DMC-R-1436
DR. NITIN AGARWAL
MBBS,MD(PATHOLOGIST)



OnePLUS Ultrasound Lab

QUALITY FIRST... ALWAYS!



NABL
MC - 6036

Dr. Nitin Agarwal

Pathologist & Director
MBBS, MD, FAGE
Ex. Chief of Lab
Dr. Lal Path labs.

Dr. Pooja (Garg) Agarwal

Radiologist & Director
MBBS (MAMC) DMRD (MAMC)
Imaging Expert In Fetal And Maternal Medicine,
University of Barcelona, Spain
Fetal Medicine Foundation (UK) Accreditation



NAME	:Mr. SHUBHAM SINGHAL	Barcode No	:10169516
AGE/GENDER	:32 YRS/Male	SPECIMEN DATE	:13/Apr/2024 09:30AM
PATIENT ID	:133950	SPECIMEN RECEIVED	:13/Apr/2024 09:58AM
REFERRED BY	:Dr. MEDIWHEEL	REPORT DATE	:13/Apr/2024 03:46PM
CENTRE NAME	:ONEPLUS ULTRASOUND LAB	LAB NO.	:012404130015

Test Name	Result	Unit	Ref. Range
Sample Type:Serum			
Bun (blood urea nitrogen) Calculated	12.10	mg/dl	8.9-21.6
Uric Acid, serum Uricase- PAP	4.6	mg/dl	3.5-7.2
Creatinine, serum Enzymatic	0.8	mg/dl	0.71-1.16
LFT(LIVER FUNCTION TEST)			
Bilirubin Total Modified tab	0.52	mg/dl	0.2-1.1
Bilirubin Conjugated Diazotied sulfanilic acid	0.23	mg/dL	0.11-0.42
Bilirubin Unconjugated Calculated	0.29	mg/dl	up to 0.7
SGOT (AST) Tris buffer	51	U/L	0-46
SGPT (ALT) Tris buffer	111	U/L	0-49
Alkaline phosphatase Amp buffer	94	U/L	40-129
GAMMA.GT Szasz Method	29	U/L	10-45
Total Protein Biuret	7.2	gm/dl	6.60 - 8.70
Albumin serum BCG	4.1	g/dL	3.0-5.2
Globulin Calculated	3.10	gm/dl	1.8-3.4
Albumin/Globulin Ratio Calculated	1.32		1.10 - 2.50
LIPID PROFILE			
Cholesterol CHOD-PAP	185	mg/dl	50-200
Triglycerides GPO-PAP	143	mg/dL	25-150
HDL Cholesterol Selective Inhibition	46	mg/dL	40 - 60

Checked By.

DR. NITIN AGARWAL
MBBS, MD
Reg. No. DMC-R-1436

DR. NITIN AGARWAL
MBBS,MD(PATHOLOGIST)

Page 4 of 8

47, Harsh Vihar, Pitampura, Delhi-34 ☎ 011-4248 0101, 9599913051

✉ Email: oneplusul@gmail.com 🌐 www.oneplusul.in

- Clinical correlation is essential for final diagnosis. • If test results are unsatisfactory please contact personally or on phone.
- This report is for perusal of doctors only. • All disputes are subject to Delhi jurisdiction only. • Not for medico legal case.
- All congenital anomalies in a foetus may not be diagnosed in routine obstetric ultrasound.



NAME	:Mr. SHUBHAM SINGHAL	Barcode No	:10169516
AGE/GENDER	:32 YRS/Male	SPECIMEN DATE	:13/Apr/2024 09:30AM
PATIENT ID	:133950	SPECIMEN RECEIVED	:13/Apr/2024 09:58AM
REFERRED BY	:Dr. MEDIWHEEL	REPORT DATE	:13/Apr/2024 03:46PM
CENTRE NAME	:ONEPLUS ULTRASOUND LAB	LAB NO.	:012404130015

Test Name	Result	Unit	Ref. Range
LDL cholesterol Calculated	110	mg/dL	<100
VLDL cholesterol Calculated	28.6	mg/dL	5-40
Cholesterol/HDL Ratio Calculated	4.0		Low Risk 3.3-4.97 Average Risk 4.4-7.1 Moderate Risk 7.1-11.0 High Risk >11.0
LDL/HDL Ratio Calculated	2.4		0 - 3.55

LDL Cholesterol	Total Cholesterol	HDL Cholesterol
<100 Optimal	<200 Desirable	<40 Low
100-129 Near optimal	200-239 Borderline high	>60 High
130-159 Borderline high	>240 High	
160-189 High		
>190 Very high		

According to NCEP, ATP-III Guidelines

	BUN/Creatinine ratio		
UREA UREASE-GLDH	26.00	mg/dl	15-45
Bun (blood urea nitrogen) Calculated	12.15	mg/dl	8.9-21.6
CREATININE ENZYMATIC	0.80	mg/dl	0.30-1.10
Bun/Creatinine Ratio Calculated	15.19		10.0 - 20.0

Checked By.

DR. NITIN AGARWAL
MBBS, MD
Reg. No. DMC-R-1436
DR. NITIN AGARWAL
MBBS,MD(PATHOLOGIST)



OnePLUS

Ultrasound Lab

QUALITY FIRST... ALWAYS!

Dr. Nitin Agarwal

Pathologist & Director
MBBS, MD, FAGE
Ex. Chief of Lab
Dr. Lal Path labs.

Dr. Pooja (Garg) Agarwal

Radiologist & Director
MBBS (MAMC) DMRD (MAMC)
Imaging Expert In Fetal And Maternal Medicine,
University of Barcelona, Spain
Fetal Medicine Foundation (UK) Accreditation



NAME	:Mr. SHUBHAM SINGHAL	Barcode No	:10169516
AGE/GENDER	:32 YRS/Male	SPECIMEN DATE	:13/Apr/2024 09:30AM
PATIENT ID	:133950	SPECIMEN RECEIVED	:13/Apr/2024 09:58AM
REFERRED BY	:Dr. MEDIWHEEL	REPORT DATE	:13/Apr/2024 03:46PM
CENTRE NAME	:ONEPLUS ULTRASOUND LAB	LAB NO.	:012404130015

Test Name	Result	Unit	Ref. Range
-----------	--------	------	------------

ENDOCRINOLOGY

THYROID PROFILE(T3,T4,TSH)

Triiodothyronine total [t3] ECLIA	0.95	ng/dl	0.52-1.9
Thyroxine total [t4] ECLIA	7.60	µg/dl	4.4 - 10.8
TSH (Thyroid Stimulating Hormone) Enzyme linked fluorescent assay	3.70	µIU/ml	0.25-5.0

AGE WISE VARIATION IN TSH

AGE	TSH(µIU/ml)	AGE	TSH(µIU/ml)
1-4 weeks	1.00 - 19.0	16-20 yrs	0.25 - 5.0
1-12 mths	1.70 - 9.1	21 - 80 yrs	0.25 - 5.0
1-5 yrs	0.80 - 8.2	I st trimester	0.25 - 5.0
6-10 yrs	0.25 - 5.0	II nd trimester	0.50 - 5.0
11-15 yrs	0.25 - 5.0	III rd trimester	0.4 - 6.0

Reference ranges - Interpretation of Diagnostic tests - (Jacques Wallach)

1. Primary hypothyroidism is accompanied by depressed serum T3 and T4 values and elevated serum TSH level.
2. Primary hyperthyroidism is accompanied by elevated serum T3 and T4 levels along with depressed TSH values.
3. Slightly elevated T3 levels may be found in pregnancy and estrogen therapy, while depressed levels may be encountered in severe illness, renal failure and during therapy with drugs like propranolol and propyl thiouracil.
4. Although elevated TSH levels are nearly always indicative of primary hypothyroidism, and may be seen in secondary thyrotoxicosis

Dr. NITIN AGARWAL
MBBS, MD
Reg. No. DMC-R-1436

DR. NITIN AGARWAL
MBBS,MD(PATHOLOGIST)

Checked By.



NAME	:Mr. SHUBHAM SINGHAL	Barcode No	:10169516
AGE/GENDER	:32 YRS/Male	SPECIMEN DATE	:13/Apr/2024 09:30AM
PATIENT ID	:133950	SPECIMEN RECEIVED	:13/Apr/2024 09:58AM
REFERRED BY	:Dr. MEDIWHEEL	REPORT DATE	:13/Apr/2024 03:46PM
CENTRE NAME	:ONEPLUS ULTRASOUND LAB	LAB NO.	:012404130015

Test Name	Result	Unit	Ref. Range
-----------	--------	------	------------

CLINICAL PATHOLOGY

URINE ROUTINE (Strip/microscopy)

Sample Type:Urine

Physical examination

Colour	PALE YELLOW	PALE YELLOW
Transparency	CLEAR	CLEAR
Sp.gravity	1.015	1.005-1.030
BROMOTHYMOL BLUE		
pH	6.00	5.0-8.0
Double Indicators Test		
Reaction	ACIDIC	ACIDIC

Chemical examination

Urine protein	NIL	NIL
Protein Ionization		
Urine sugar	NIL	NIL
Oxidation Reaction		
Bilirubin, urine	NEGATIVE	NEGATIVE
Urobilinogen	NORMAL	NORMAL
P-Aminobenzoic Acid and Phenazopyridine Reaction		
Ketones	NEGATIVE	NEGATIVE
Acetoacetate and Dichlorobenzene Reaction		

Microscopic examination

Pus cells.	1-2	/HPF	0-2
Microscopy			
Epithelial cells	1-2	/HPF	NIL
Microscopy			
R.B.C.	NIL	/HPF	NIL
Microscopy			
Casts	NIL	/HPF	NIL
Microscopy			
Crystals	NIL	/HPF	NIL
Microscopy			
Bacteria	NIL	/HPF	NIL
Microscopy			

Checked By.



DR. NITIN AGARWAL
MBBS,MD(PATHOLOGIST)



OnePLUS
Ultrasound Lab

QUALITY FIRST... ALWAYS!



NABL
MC - 6036

Dr. Nitin Agarwal

Pathologist & Director
MBBS, MD, FAGE
Ex. Chief of Lab
Dr. Lal Path labs.

Dr. Pooja (Garg) Agarwal

Radiologist & Director
MBBS (MAMC) DMRD (MAMC)
Imaging Expert In Fetal And Maternal Medicine,
University of Barcelona, Spain
Fetal Medicine Foundation (UK) Accreditation



NAME	:Mr. SHUBHAM SINGHAL	Barcode No	:10169516
AGE/GENDER	:32 YRS/Male	SPECIMEN DATE	:13/Apr/2024 09:30AM
PATIENT ID	:133950	SPECIMEN RECEIVED	:13/Apr/2024 09:58AM
REFERRED BY	:Dr. MEDIWHEEL	REPORT DATE	:13/Apr/2024 03:46PM
CENTRE NAME	:ONEPLUS ULTRASOUND LAB	LAB NO.	:012404130015

Test Name	Result	Unit	Ref. Range
Others.	NIL	NIL	NIL

*** End Of Report ***

Checked By.

Dr. NITIN AGARWAL
MBBS, MD.
Reg. No. DMC-R-1436
DR. NITIN AGARWAL
MBBS,MD(PATHOLOGIST)

Page 8 of 8

47, Harsh Vihar, Pitampura, Delhi-34 ☎ 011-4248 0101, 9599913051

✉ Email: oneplusul@gmail.com 🌐 www.oneplusul.in

- Clinical correlation is essential for final diagnosis. • If test results are unsatisfactory please contact personally or on phone.
- This report is for perusal of doctors only. • All disputes are subject to Delhi jurisdiction only. • Not for medico legal case.
- All congenital anomalies in a foetus may not be diagnosed in routine obstetric ultrasound.

Name	:Mr.SHUBHAM SINGHAL	Age/Sex	:32 YRSMale
Refer By	:Dr. MEDIWHEEL	Lab No:	:012404130015
Date	:13-04-2024	Patient ID	:133950

ULTRASOUND EXAMINATION----WHOLE ABDOMEN

Liver is enlarged in size (17.1 cm) and normal in outline with altered echopattern. Diffuse increase in echogenicity of liver parenchyma is noted, suggestive of fatty infiltration (grade I). No abscess or mass lesion seen. Hepatic veins, portal vein, IVC and aorta are normal. Intrahepatic biliary radicles are not dilated. CBD is normal in caliber.

Gall bladder is well distended with anechoic lumen. Wall thickness is normal.

Both kidneys are normal in size, shape, position, outline and echopattern. Corticomedullary differentiation is maintained. No pelvicalyceal dilation or calculus or mass lesion is seen.

Spleen is normal in size (11.4 cm) and echotexture. No mass lesion seen.

Pancreas is normal in size, outline and echotexture.

Urinary bladder is normal in shape and position. No evidence of intravesical stone or mass seen.


Prostate is normal in size, shape and echopattern.

Prostate measures 4.4 x 3.1 x 2.8 cm. **Weight of prostate is 20.3 grams.**

No abnormal bowel wall thickening seen in right iliac fossa.

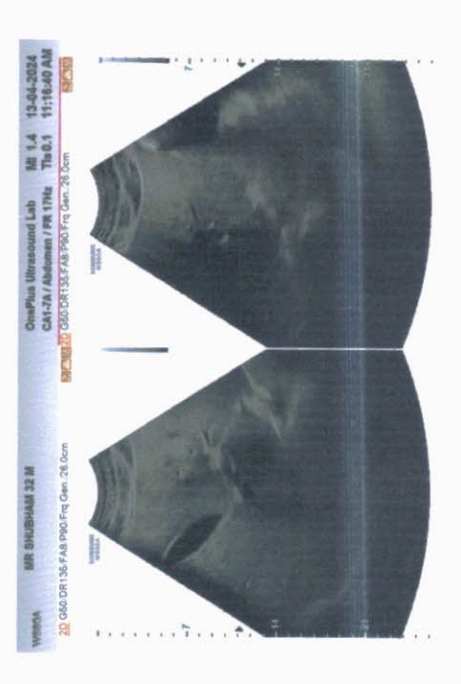
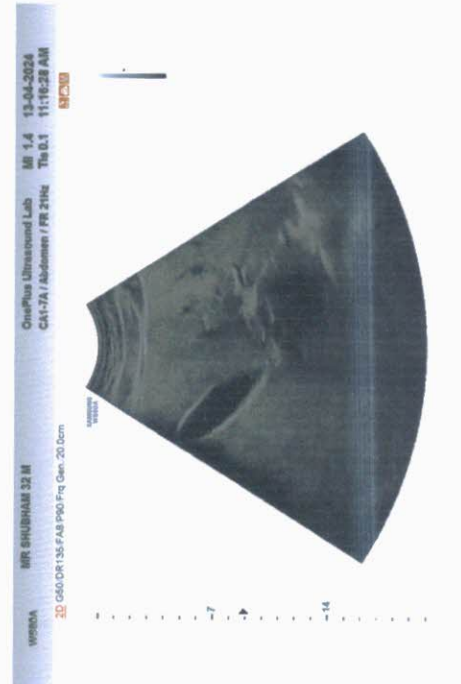
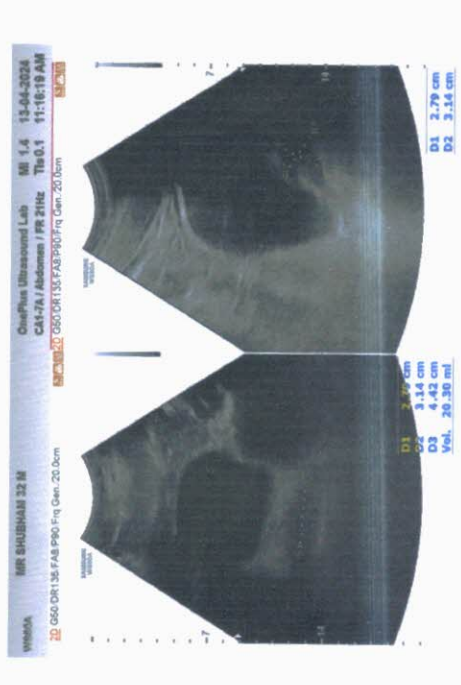
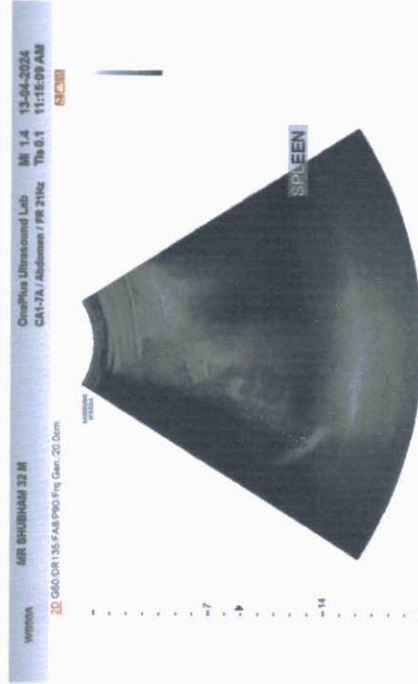
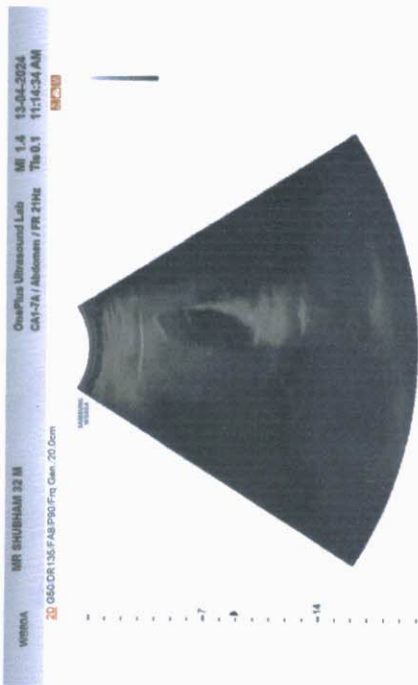
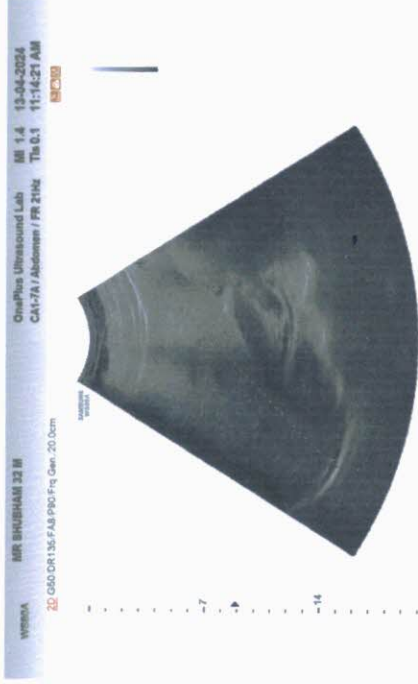
No free fluid seen anywhere in abdomen.

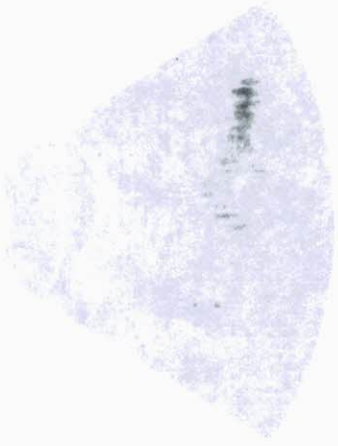IMPRESSION: Fatty infiltration of liver (grade I) with hepatomegaly.


DR. RASHMI BANSAL
RADIOLOGIST
REG NO- DMC/R/10067


Dr. RASHMI BANSAL
Radiologist
Reg. No. DMC/R/10067

Ultrasound Image Report





Handwritten text, possibly a date or label, in purple ink.





OnePLUS
Ultrasound Lab
— QUALITY FIRST... ALWAYS! —

Dr. Nitin Agarwal

Pathologist & Director
MBBS, MD, FAGE
Ex. Chief of Lab
Dr. Lal Path labs.

Dr. Pooja (Garg) Agarwal

Radiologist & Director
MBBS (MAMC) DMRD (MAMC)
Imaging Expert In Fetal And Maternal Medicine
University of Barcelona, Spain
Fetal Medicine Foundation (UK) Accreditation

Name	:Mr.SHUBHAM SINGHAL	Age/Sex	:32 YRSMale
Refer By	:Dr. MEDIWHEEL	Lab No:	:012404130015
Date	:13-04-2024	Patient ID	:133950

X-ray-Chest PA view

Bony cage and soft tissues are normal.

Cardiothoracic ratio is normal.

Mediastinum is normal.

Both hila are normal.

Both costophrenic angles are clear.

Both domes of diaphragm are normal.

Lung fields are clear. No parenchymal lesion seen.

IMPRESSION: Normal Study.

DR. POOJA GARG
RADIOLOGIST
REG NO – DMC/R/03398

Dr. POOJA GARG
M.B.B.S., D.M.R.D
Reg No DMC/R/03398
Radiologist

47, Harsh Vihar, Pitampura, Delhi-34 ☎ 011-4248 0101, 9599913051

✉ Email: oneplusul@gmail.com 🌐 www.oneplusul.in

- Clinical correlation is essential for final diagnosis. • If test results are unsatisfactory please contact personally or on phone.
- This report is for perusal of doctors only. • All disputes are subject to Delhi jurisdiction only. • Not for medico legal case.
- All congenital anomalies in a foetus may not be diagnosed in routine obstetric ultrasound.

ONEPLUS ULTRASOUND LAB

47, HARSH VIHAR, PITAMPURA, DELHI- 110034

Mr. SHUBHAM SINGHAL

Age : 32M

Ref. by : MEDIWHEEL

Indication 1 :

Indication 2 :

Indication 3 :

COMMENTS : Sinus Rhythm.

ID : 2551

HWF : 17/6/105

Recorded : 13-4-2024 9:37

Medication 1 :

Medication 2 :

Medication 3 :

BPM : 90

BP : 122/84

P Axis : 62 deg

QRS Axis : 74 deg

T Axis : 43 deg

P duration : 130 msec

PR duration : 186 msec

QRS duration : 113 msec

QT interval : 310 msec

QTc interval : 362 msec

Raw E.C.G.(Seq)

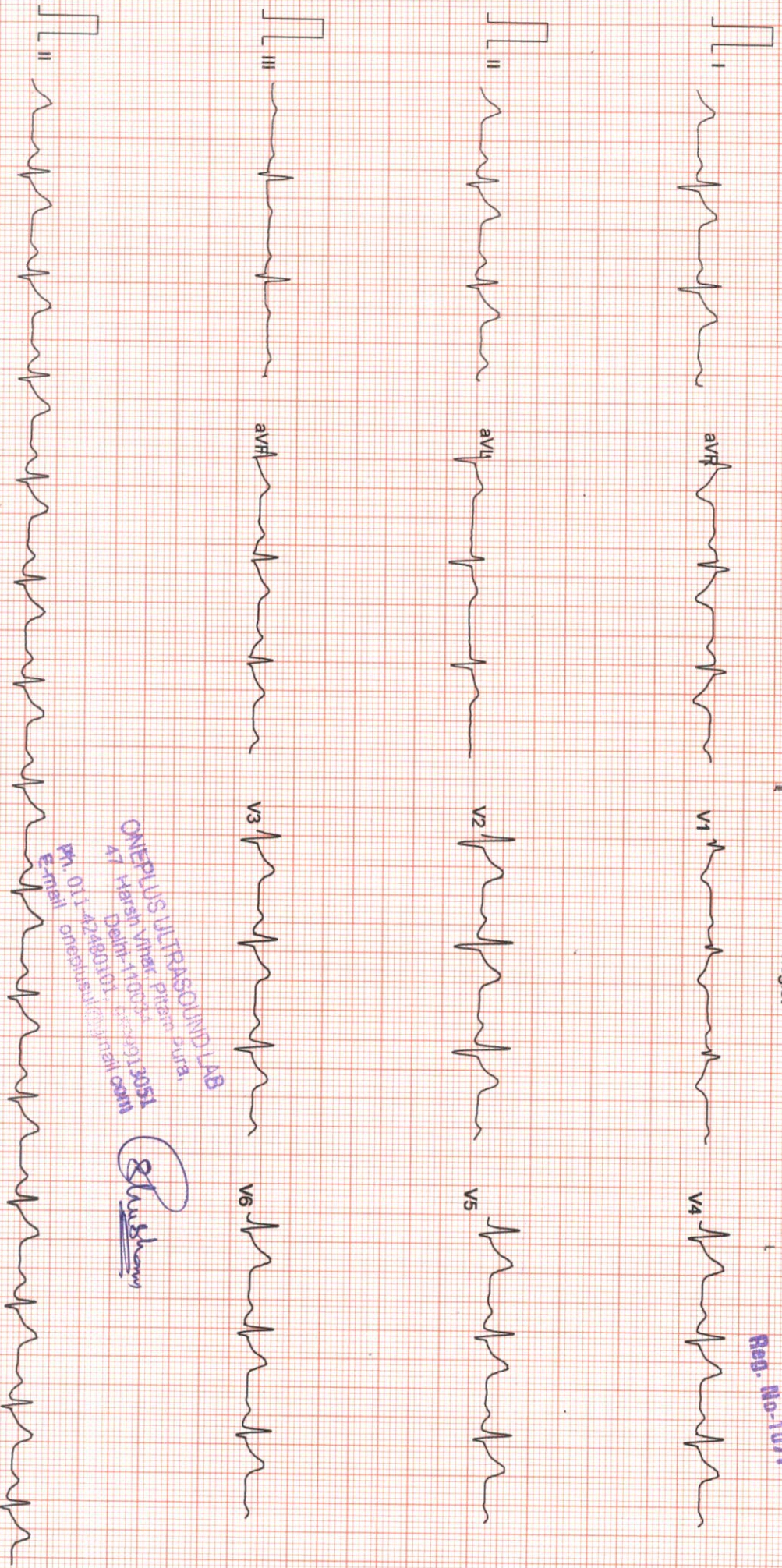
Unconfirmed Report Reviewed By:

Cardiologist

Dr. *[Signature]*

MBBS, MD

Reg. No. 1071



ONEPLUS ULTRASOUND LAB
47 Harsh Vihar Pitampura
Delhi-110034
Ph. 011-42480101
E-mail onepplusultrasoundlab@gmail.com
T: 139013901390

[Signature]

Filtered

25mm/sec 10mm/mV

CardiCom, INDIA

ONEPLUS ULTRASOUND LAB

47, HARSH VIHAR PITAMPURA DELHI 110034

Mr. SHUBHAM SINGHAL

ID : 999
 HWM : 176/105
 Recorded : 13-4-2024 9:41

Age/Sex : 32/M
 Ref by : MEDIWHEEL
 Indication 1 :
 Indication 2 :
 Indication 3 :

TREADMILL TEST SUMMARY REPORT
 Protocol : BRUCE
 History :
 Medication 1 :
 Medication 2 :
 Medication 3 :

PHASE	PHASE TIME	STAGE TIME	SPEED (km./hr.)	GRADE (%)	H.R. (BPM)	B.P. (mmHg)	RPP X100	II	ST LEVEL (mm) V2	V5	METS
SUPINE											
STANDING											
STAGE 1	2:59	2:59	2.70	10.00	102	134/86	136	1.3	1.5	1.3	4.80
STAGE 2	5:59	2:59	4.00	12.00	113	146/88	164	1.2	1.4	1.3	7.10
STAGE 3	8:59	2:59	5.40	14.00	132	160/90	211	1.0	0.9	1.1	10.00
STAGE 4	10:59	1:59	6.70	16.00	150	172/92	258	0.7	0.2	0.5	12.66
PEAK EXER	11:07	2:07			163	172/92	280	-0.1	0.8	1.0	
RECOVERY	2:59	2:59	0.00	0.00	91	128/86	116	0.9	0.4	0.6	12.84

RESULTS

Exercise Duration : 11:07 Minutes
 Max Heart Rate : 163 bpm 86 % of target heart rate 188 bpm
 Max Blood Pressure : 172/92 mmHg
 Max Work Load : 12.84 METS
 Reason of Termination :

Negative for ischaemic changes.

Dr. Ravinder
 MBBS, MD
 Cardiologist
 Reg. No. 10101

Shubham

ONEPLUS ULTRASOUND LAB
 47 Harsh Vihar Pitampura
 Delhi-110034
 Ph. 011-42480101 9599213051
 e-mail: oneplusultrasound@gmail.com

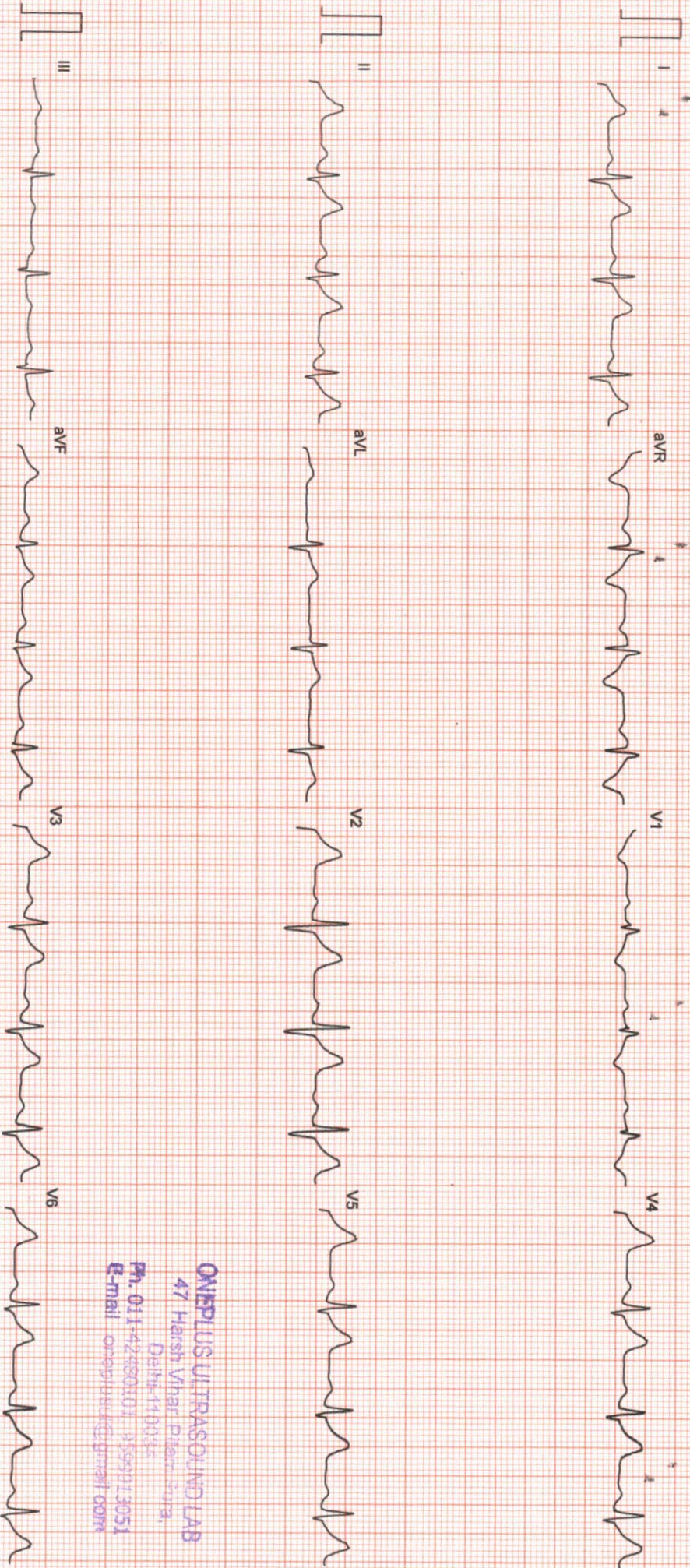
ONEPLUS ULTRASOUND LAB

SUPINE
PRETEST

ST @ 10mm/mV
80ms PostJ

Mr. SHUBHAM SINGHAL
I.D. : 999
AGE/SEX : 32/M
RECORDED : 13-4-2024 9:41
RATE : 90 BPM
B.P. : 122/84 mmHg

RAW E.C.G.



ONEPLUS ULTRASOUND LAB
47 Harsh Vihar, Phase 2, Gurgaon,
Delhi-122015
Ph. 011-42230101, 3599113051
E-mail: onepplus@jagmail.com

Filtered

25mm/sec 10mm/mV

CardiCom, INDIA Ph.:091-731-2620740, TeleFax:091-731-2431214

ONEPLUS ULTRASOUND LAB


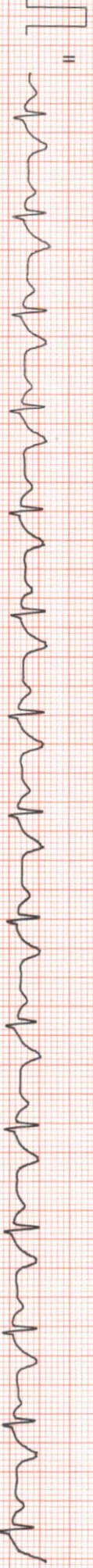
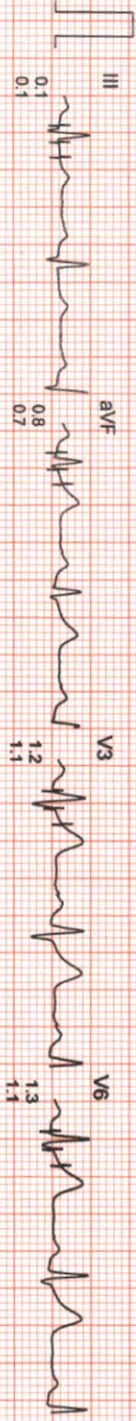
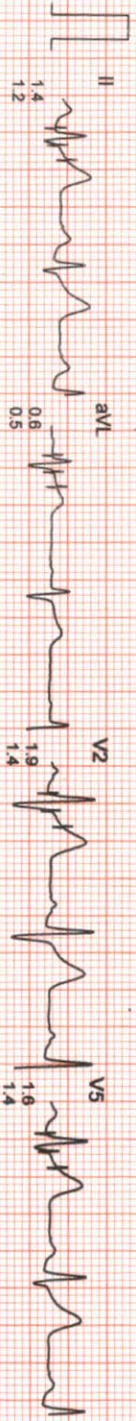
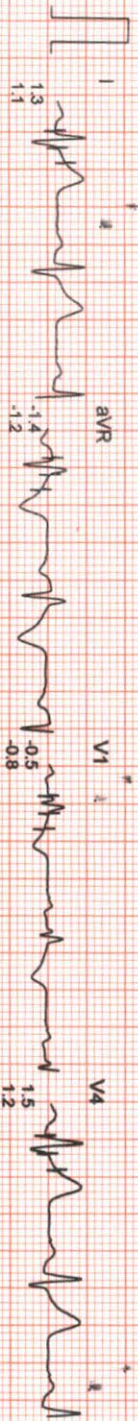
STANDING
PRETEST

ST @ 10mm/mV
80ms PostJ

Mr. SHUBHAM SINGHAL
I.D. : 999
AGE/SEX : 32M
RECORDED : 13-4-2024 9:41

RATE : 90 BPM
B.P. : 122/84 mmHg

LINKED MEDIAN



ONEPLUS ULTRASOUND LAB
41 Harsidh Vihar Phase 2, Faridkot
Delhi-110038
Ph: 011-42680011, 426813051
E-mail: oneplusultrasound@gmail.com

Mr. SHUBHAM SINGHAL

ID : 999

AGE/SEX : 32M

RECORDED : 13-4-2024 9:41

RATE : 102 BPM

B.P. : 134/86 mmHg

ONEPLUS ULTRASOUND LAB

BRUCE

EXERCISE 1

PHASE TIME : 2:59

STAGE TIME : 2:59

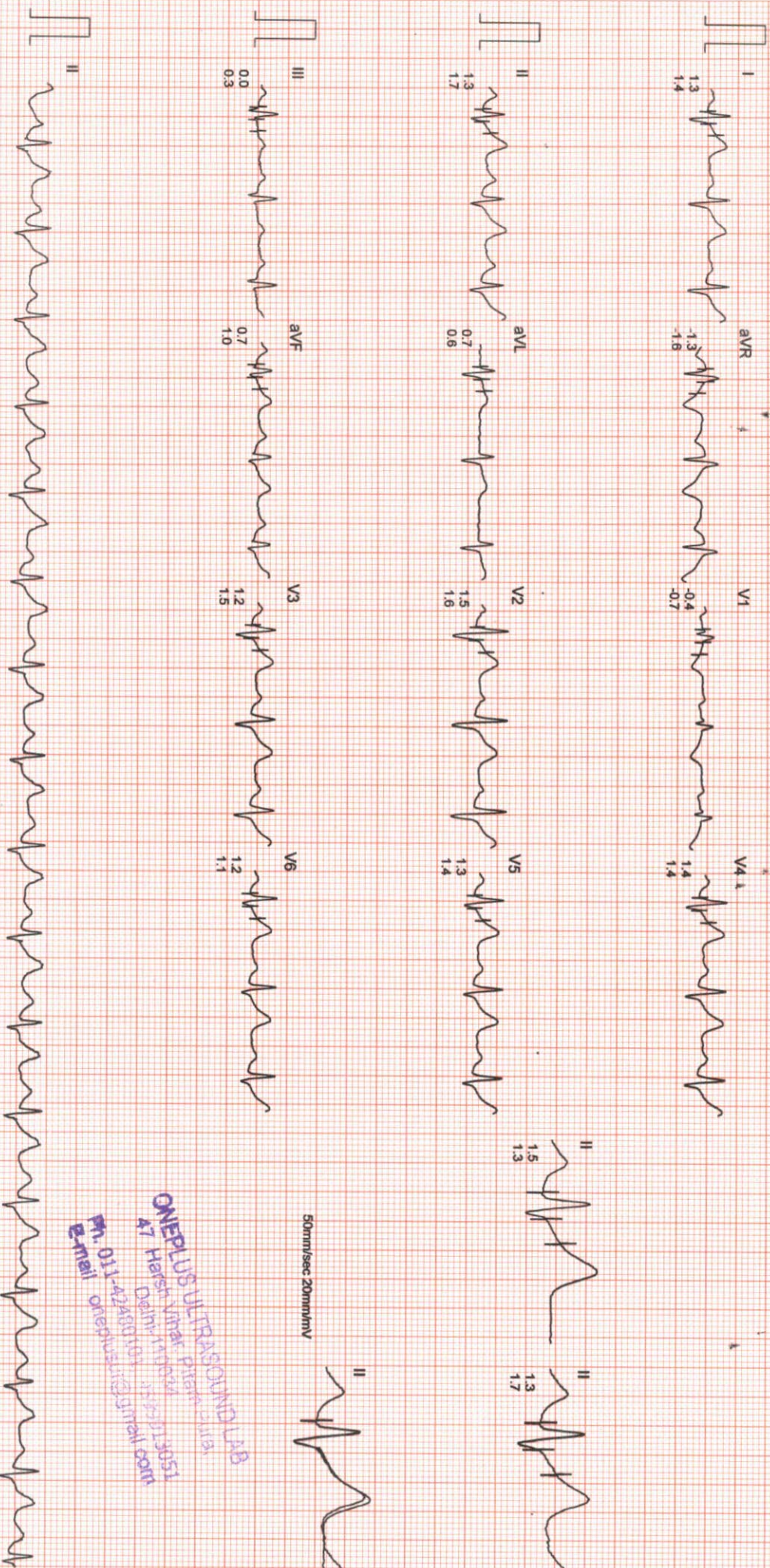
ST @ 10mm/mV

80ms PostJ

SPEED : 2.7 Km./Hr.

GRADE : 10.0 %

LINKED MEDIAN



ONEPLUS ULTRASOUND LAB
 47 Harsini Vihar, Preet Vihar, Delhi-110027
 Ph: 011-42480101, 42480102
 Email: onepplus@oneplusultrasound.com

ONEPLUS ULTRASOUND LAB

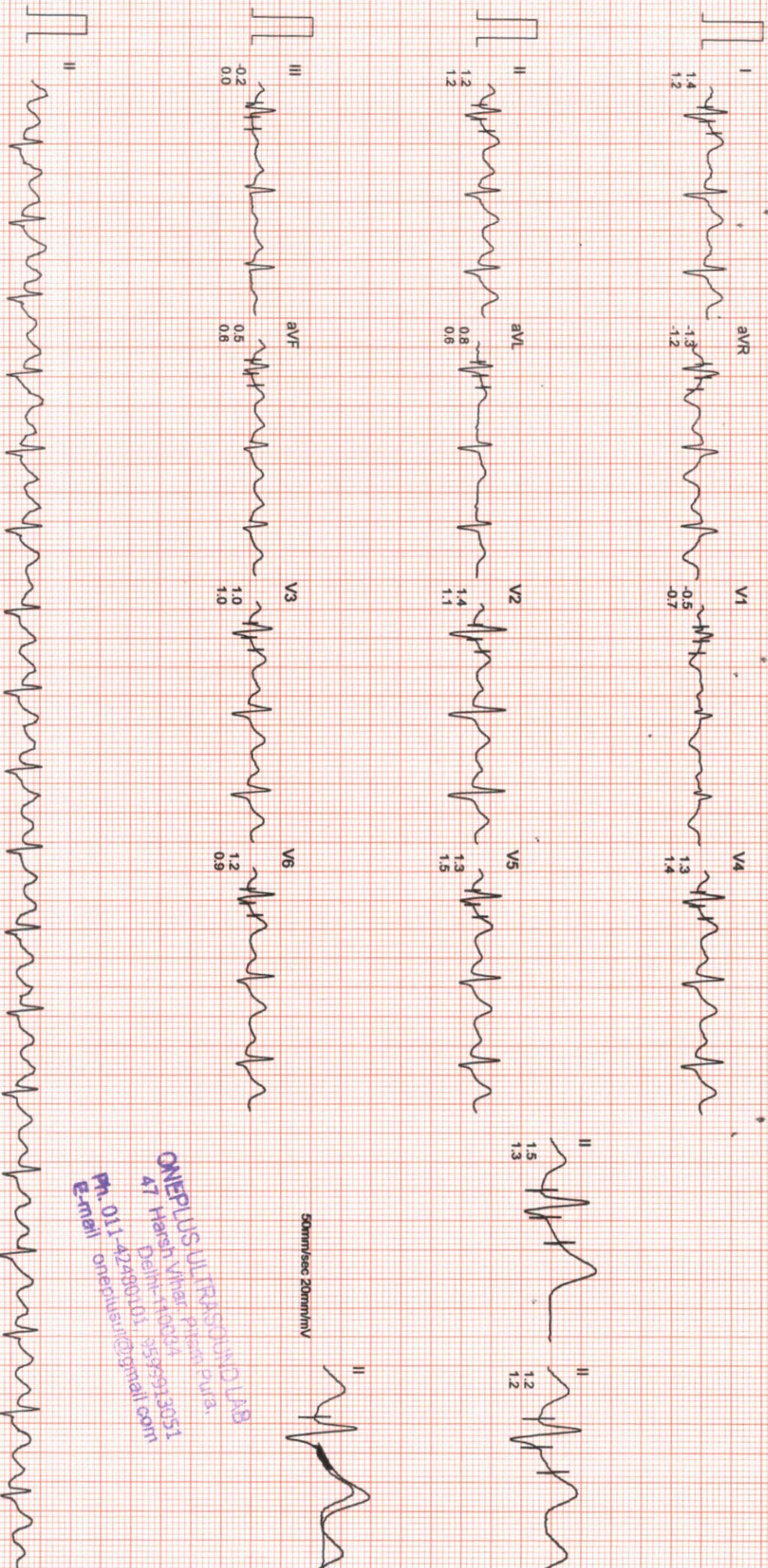
Mr. SHUBHAM SINGHAL
I.D. : 999
AGE/SEX : 32/M
RECORDED : 13-4-2024 9:41

RATE : 113 BPM
B.P. : 146/88 mmHg

BRUCE
EXERCISE 2
PHASE TIME : 5:59
STAGE TIME : 2:59

ST @ 10mm/mV
80ms PostJ
SPEED : 4.0 Km./Hr.
GRADE : 12.0 %

LINKED MEDIAN



50mm/sec 20mm/mV

ONEPLUS ULTRASOUND LAB
47 Hareli Vihar, Prayagraj, UP
Delhi-110014, 9539913351
Ph: 011-42490101, 9539913351
Email: onepplus@oneplusultrasound.com

Filtered

Computer Corrected Baseline

25mm/sec 10mm/mV

CardiCom, INDIA Ph.: 091-731-2620740, Tele/Fax: 091-731-2431214

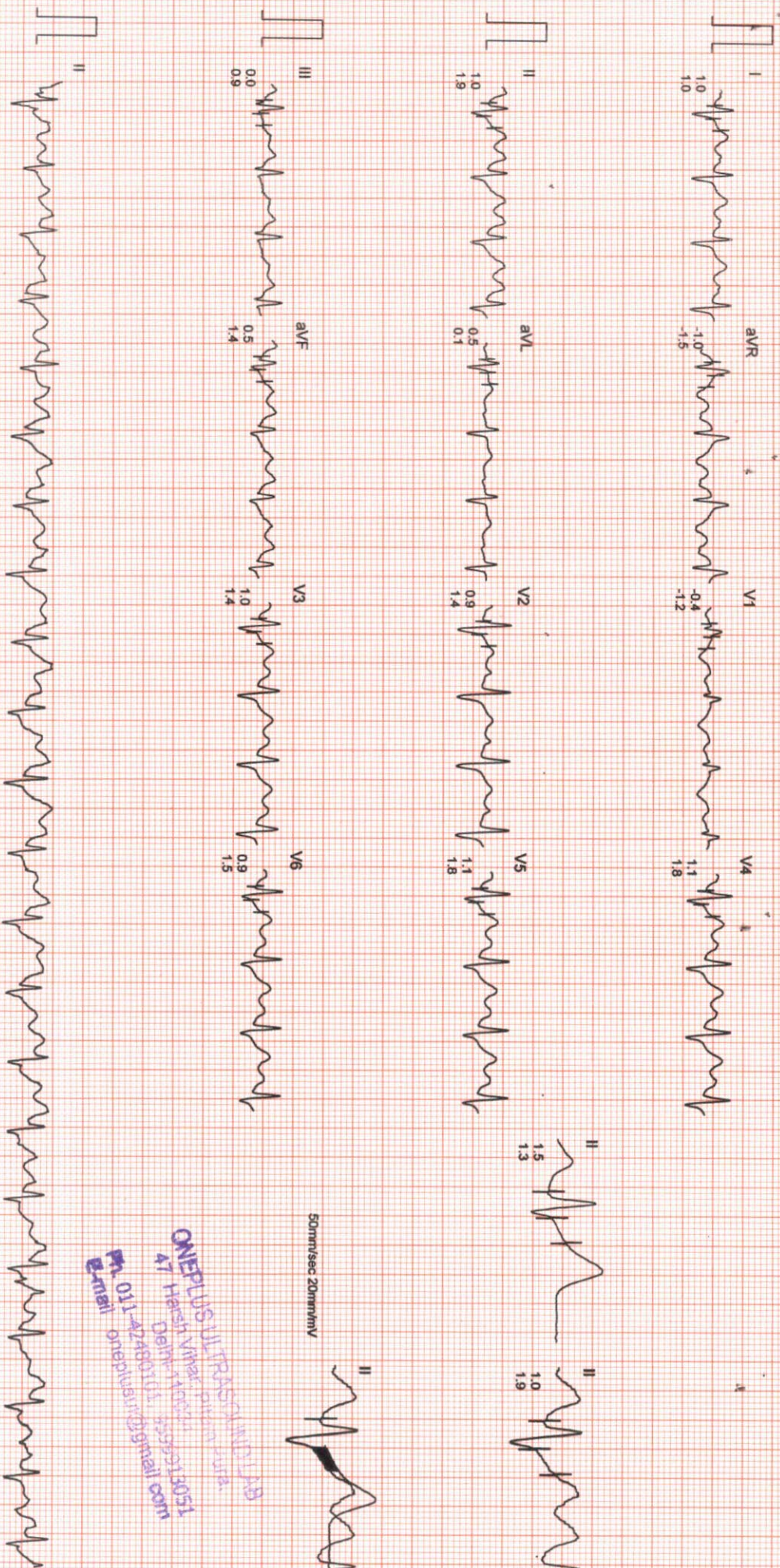
ONEPLUS ULTRASOUND LAB

Mr. SHUBHAM SINGHAL
I.D. : 999
AGE/SEX : 32/M
RECORDED : 13-4-2024 9:41

RATE : 132 BPM
B.P. : 160/90 mmHg

BRUCE
EXERCISE 3
PHASE TIME : 8:59
STAGE TIME : 2:59

ST @ 10mm/mV
80ms PostU
SPEED : 5.4 Km./Hr.
GRADE : 14.0 %
LINKED MEDIAN



ONEPLUS ULTRASOUND LAB
47 Heerthi Vihar, Sector 14
Delhi - 110016, India
Ph: 011-42449001, 42449002
Email: oneplusultrasound@gmail.com
TELEORT 150971
LUCC

ONEPLUS ULTRASOUND LAB

Mr. SHUBHAM SINGHAL

I.D. : 999

AGE/SEX : 32/M

RECORDED : 13-4-2024 9:41

RATE : 163 BPM

B.P. : 172/92 mmHG

BRUCE

PEAK EXER

PHASE TIME : 11:07

STAGE TIME : 2:07

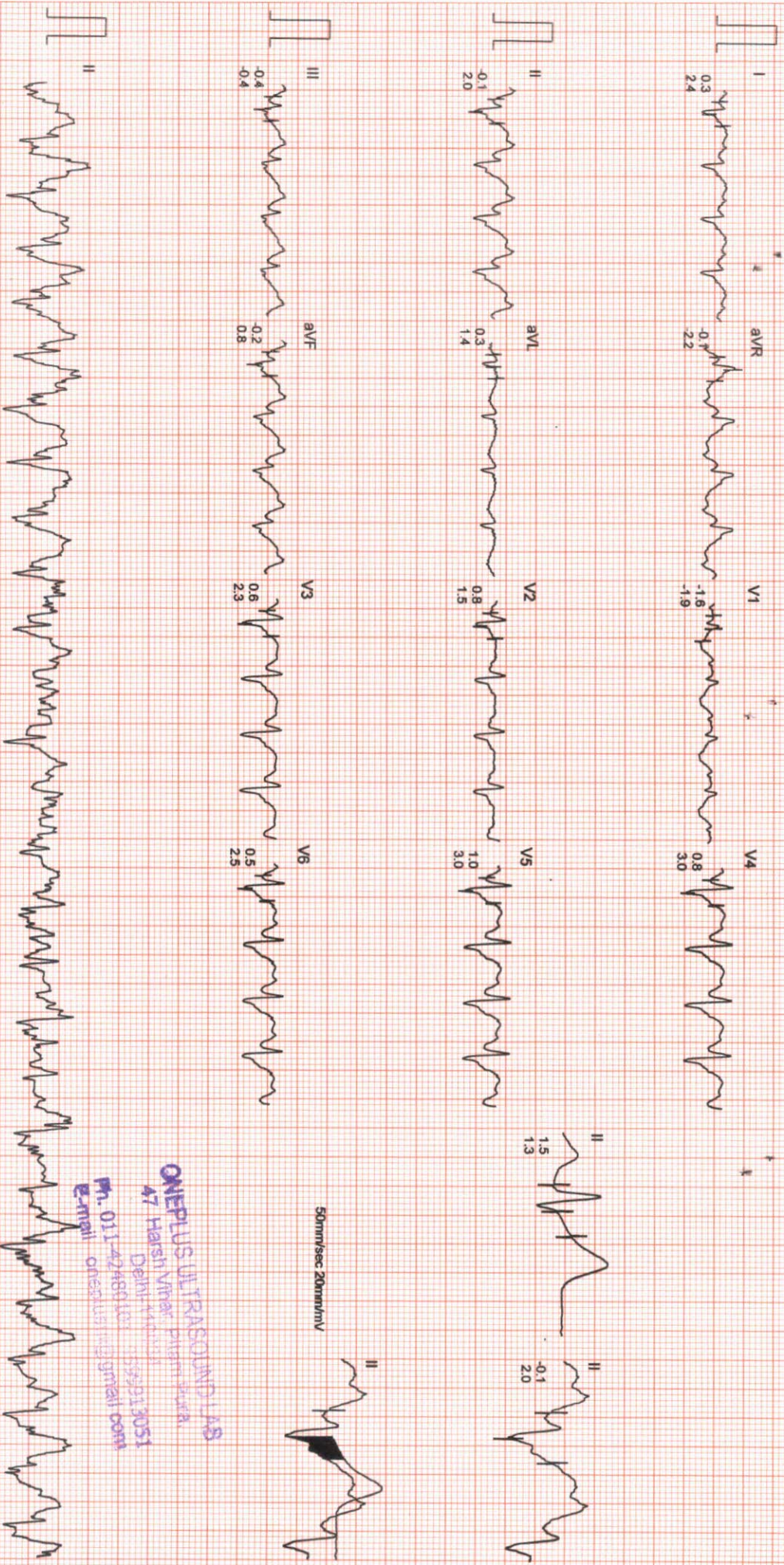
ST @ 10mm/mV

80ms PostJ

SPEED : 6.7 Km./Hr.

GRADE : 16.0 %

LINKED MEDIAN



50mm/sec 20mm/mV

ONEPLUS ULTRASOUND LAB
47 Harsh Vihar, Piliam Bkura,
Dehr. Adarsh
Ph. 011-42480103 359213051
E-mail: onepus@rediffmail.com

Filtered

Computer Corrected Baseline

25mm/sec 10mm/mV

CardiCom, INDIA Ph.:091-731-2620740, TeleFax:091-731-2431214

ONEPLUS ULTRASOUND LAB

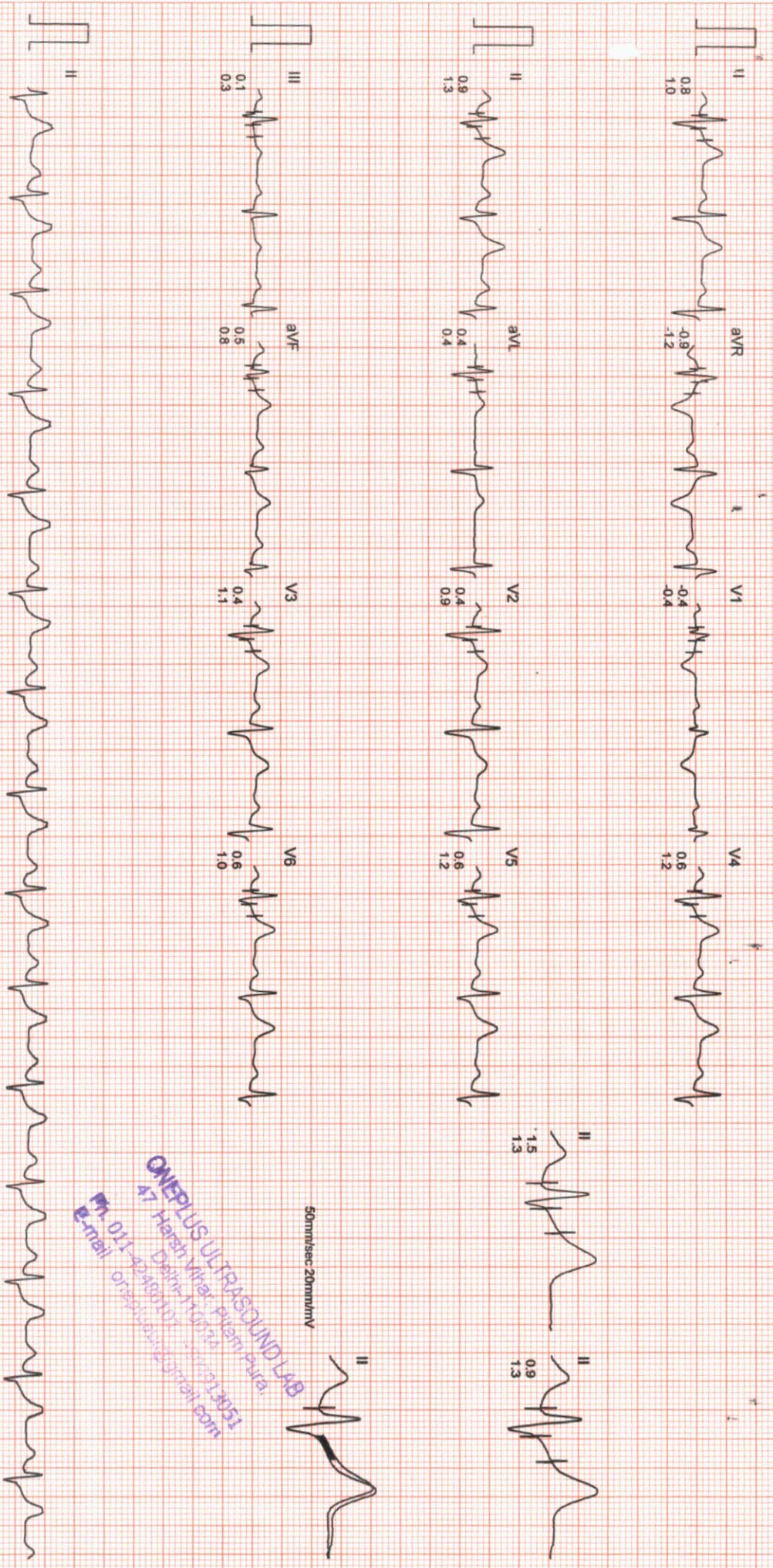
Mr. SHUBHAM SINGHAL
I.D. : 999
AGE/SEX : 32/M
RECORDED : 13-4-2024 9:41

RATE : 91 BPM
B.P. : 128/86 mmHg

BRUCE
RECOVERY
PHASE TIME : 2:59

ST @ 10mm/mV
80ms PostJ
SPEED : 0.0 Km./Hr.
GRADE : 0.0 %

LINKED MEDIAN









50mm/Sec 20mm/mV

ONEPLUS ULTRASOUND LAB
47 Harsh Vihar, Pitam Pura,
Delhi-110074
Ph: 011-42480107, 262323051
E-mail: oneplusultrasound@gmail.com
www.oneplusultrasound.com

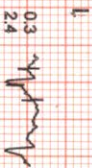
ONEPLUS ULTRASOUND LAB

STAGE	0.0Kmph 0.0%	90 bpm B.P. 122/84 80ms Postu	STANDING	0.0Kmph 0.0%	90 bpm B.P. 122/84 80ms Postu	STAGE 1	2.39 2:59 2.7Kmph 10.0%	102 bpm B.P. 134/86 80ms Postu	STAGE 2	5:39 2:59 4.0Kmph 12.0%	113 bpm B.P. 148/88 80ms Postu	STAGE 3	8:59 2:59 5.4Kmph 14.0%	132 bpm B.P. 160/90 80ms Postu	PEAK EXERCISE	11:07 2:07 6.7Kmph 16.0%	163 bpm B.P. 172/92 80ms Postu	RECOVERY	2:39 0.0Kmph 0.0%	91 bpm B.P. 128/86 80ms Postu
SUPINE	0.0Kmph 0.0%	90 bpm B.P. 122/84 80ms Postu	STANDING	0.0Kmph 0.0%	90 bpm B.P. 122/84 80ms Postu	STAGE 1	2.39 2:59 2.7Kmph 10.0%	102 bpm B.P. 134/86 80ms Postu	STAGE 2	5:39 2:59 4.0Kmph 12.0%	113 bpm B.P. 148/88 80ms Postu	STAGE 3	8:59 2:59 5.4Kmph 14.0%	132 bpm B.P. 160/90 80ms Postu	PEAK EXERCISE	11:07 2:07 6.7Kmph 16.0%	163 bpm B.P. 172/92 80ms Postu	RECOVERY	2:39 0.0Kmph 0.0%	91 bpm B.P. 128/86 80ms Postu



ONEPLUS ULTRASOUND LAB
 Dr. Harsh Vithal Patil
 Dr. Manoj Kumar
 Dr. Pratik Kumar
 Ph. 0111-42489101, 9399913053
 Email: oneplusultrasound@gmail.com

STANDING
0.0Kmph
0.0%
90 bpm
B.P. 122/84
80ms PostU



STANDING


0.0Kmph
0.0%
90 bpm
B.P. 122/84
80ms PostU



PEAK EXERCISE


11:07
2:07
6.7Kmph
16.0%
183 bpm
B.P. 172/92
80ms PostU

STANDING



STANDING


0.0Kmph
0.0%
90 bpm
B.P. 122/84
80ms PostU



PEAK EXERCISE

11:07
2:07
6.7Kmph
16.0%
183 bpm
B.P. 172/92
80ms PostU

STANDING



STANDING


0.0Kmph
0.0%
90 bpm
B.P. 122/84
80ms PostU



PEAK EXERCISE

11:07
2:07
6.7Kmph
16.0%
183 bpm
B.P. 172/92
80ms PostU

STANDING



STANDING


0.0Kmph
0.0%
90 bpm
B.P. 122/84
80ms PostU



PEAK EXERCISE

11:07
2:07
6.7Kmph
16.0%
183 bpm
B.P. 172/92
80ms PostU

STANDING



STANDING


0.0Kmph
0.0%
90 bpm
B.P. 122/84
80ms PostU



PEAK EXERCISE


11:07
2:07
6.7Kmph
16.0%
183 bpm
B.P. 172/92
80ms PostU

STANDING



STANDING

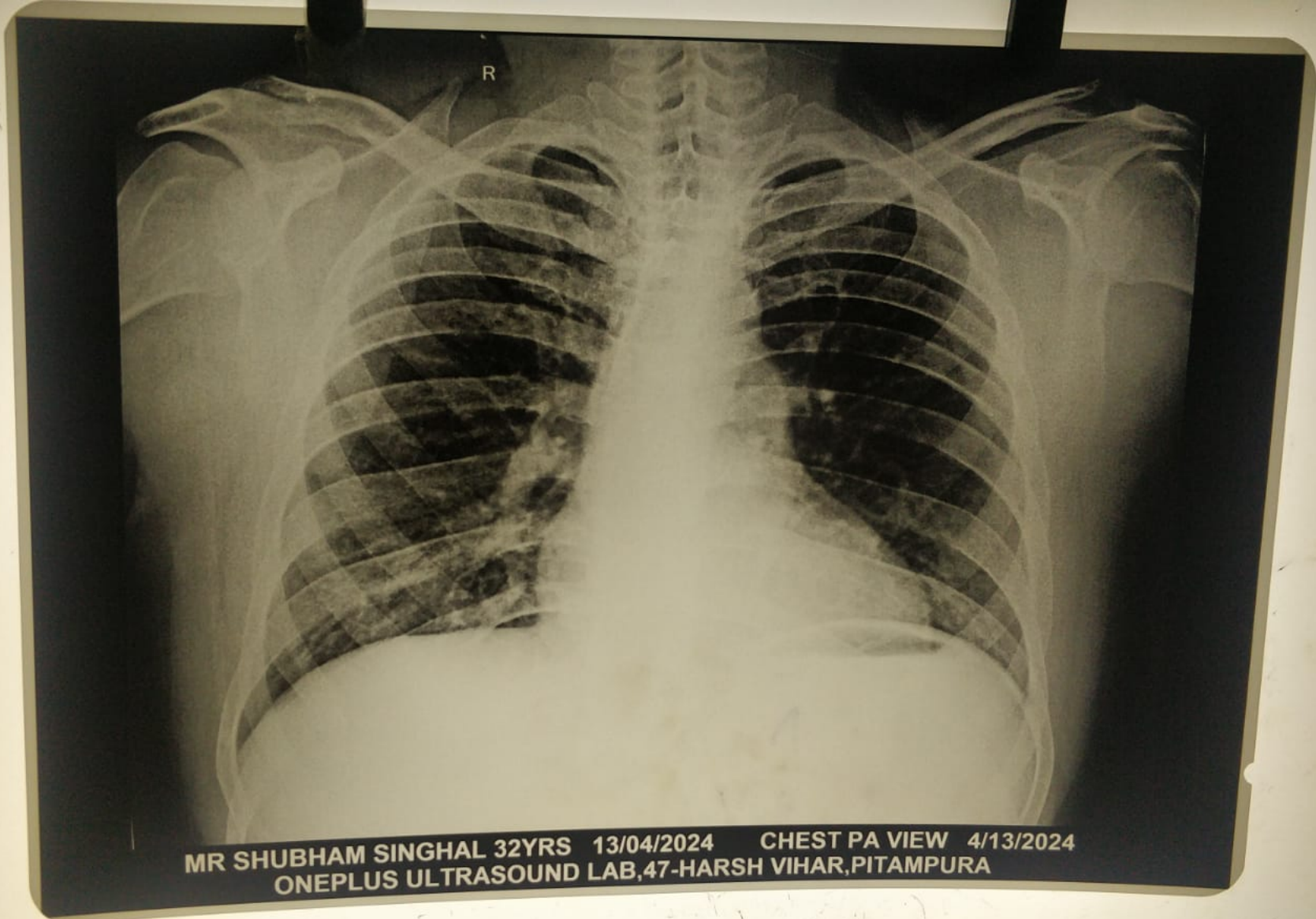
0.0Kmph
0.0%
90 bpm
B.P. 122/84
80ms PostU



PEAK EXERCISE

11:07
2:07
6.7Kmph
16.0%
183 bpm
B.P. 172/92
80ms PostU

ONEPLUS ULTRASOUND LAB
47 Harsikumar Street, Anna,
Delwar, 107
Ph: 011-47260111
Email: onepplusultrasoundlab@gmail.com



MR SHUBHAM SINGHAL 32YRS 13/04/2024 CHEST PA VIEW 4/13/2024
ONEPLUS ULTRASOUND LAB, 47-HARSH VIHAR, PITAMPURA