

Patient Name : Mr. KUSHWAHA KUNDAN

Age/Gender : 41 Y/M

UHID/MR No. : CBAS.0000090911

OP Visit No : CBASOPV98493

Sample Collected on :

Reported on : 25-12-2023 12:11

LRN# : RAD2189570

Specimen :

Ref Doctor : SELF

Emp/Auth/TPA ID : 303584

DEPARTMENT OF RADIOLOGY

X-RAY CHEST PA

Both lungs fields appears normal and shows normal bronchovascular markings.

Bilateral hila appears normal.

Cardiac silhouette appears normal.


Both costophrenic and cardiophrenic angles are clear.

Both diaphragms are normal in position and contour.

Thoracic wall and soft tissues appear normal.

IMPRESSION:

No obvious abnormality seen in the present study.



Dr. V K PRANAV VENKATESH
MBBS,MD
Radiology

Patient Name : Mr. KUSHWAHA KUNDAN

Age/Gender : 41 Y/M

UHID/MR No. : CBAS.0000090911

OP Visit No : CBASOPV98493

Sample Collected on :

Reported on : 29-12-2023 11:31

LRN# : RAD2189570

Specimen :

Ref Doctor : SELF

Emp/Auth/TPA ID : 303584

DEPARTMENT OF RADIOLOGY

ULTRASOUND - WHOLE ABDOMEN

Liver:appears enlarged in size (18.5 cm)and increased in echotexture. No focal lesion is seen. Portal vein and Common Bile Duct appear normal.No dilatation of the intrahepatic biliary radicals.

Gall bladder is well distended. No evidence of calculus. Wall thickness appears normal. No evidence of periGB collection. No evidence of focal lesion is seen.

Spleen appears normal. No focal lesion seen. Splenic vein appears normal.

Pancreas appears normal in echo-pattern. No focal/mass lesion/calcification. No evidence of peripancreatic free fluid or collection. Pancreatic duct appears normal.

Right kidney appear normal in size 12.0x1.3 cm,shape and echopattern. Cortical thickness and Cortico-medullary differentiation are maintained.

Left kidney appear normal in size 12.0x1.5 cm,shape and echopattern. Cortical thickness and Cortico-medullary differentiation are maintained.

Urinary Bladder is well distended and appears normal. No evidence of any wall thickening or abnormality. No evidence of any intrinsic or extrinsic bladder abnormality detected.

Prostate is normal in size (volume 24 cc)and echo texture.

- No thickened or tender bowel loops. No mass lesion. No ascites / pleural effusion.


IMPRESSION:-

FATTY HEPATOMEGALY.

Suggested clinical correlation.

(The sonography findings should always be considered in correlation with the clinical and other investigation finding where applicable.) It is only a professional opinion, Not valid for medico legal purpose.

Customer Pending Tests
ent,fitness by gp,diet,usg,dental pending

Name : Mr. KUSHWAHA KUNDAN Address : BLR Plan : ARCOFEMI MEDIWHEEL MALE AHC CREDIT PAN INDIA OP AGREEMENT	Age : 41 Y Sex : M	UHID :CBAS.0000090911  OP Number :CBASOPV98493 Bill No :CBAS-OCR-59962 Date : 25.12.2023 08:55
-------------------------------------------------------------------------------------------------------------------------------------------------	-----------------------------------------	--------------------------------------------------------------------------------------------------------------------------------------------------------------------------------------------------------------------------

Sno	Service Type/ServiceName	Department
1	ARCOFEMI - MEDIWHEEL - FULL BODY ANNUAL PLUS ABOVE 50Y MALE - 2D ECHO - PAN INDIA - FY2324	
✓ 1	URINE GLUCOSE(FASTING)	
✓ 2	GAMMA GLUTAMYL TRANSFERASE (GGT)	
✓ 3	PROSTATIC SPECIFIC ANTIGEN (PSA TOTAL)	
✓ 4	HbA1c, GLYCATED HEMOGLOBIN	
✓ 5	2D ECHO <i>R5</i>	5 Room
✓ 6	LIVER FUNCTION TEST (LFT)	
✓ 7	X-RAY CHEST PA	4 Room
✓ 8	GLUCOSE, FASTING	
✓ 9	HEMOGRAM + PERIPHERAL SMEAR	
10	ENT CONSULTATION - <i>Skip</i>	
11	FITNESS BY GENERAL PHYSICIAN	
12	DIET CONSULTATION - <i>Alfa Report</i>	
✓ 13	COMPLETE URINE EXAMINATION	
✓ 14	URINE GLUCOSE(POST PRANDIAL)	
✓ 15	PERIPHERAL SMEAR	
✓ 16	ECG	
✓ 17	BLOOD GROUP ABO AND RH FACTOR	
✓ 18	LIPID PROFILE	
✓ 19	BODY MASS INDEX (BMI)	
20	OPHTHAL BY GENERAL PHYSICIAN	
✓ 21	RENAL PROFILE/RENAL FUNCTION TEST (RFT/KFT)	
22	ULTRASOUND - WHOLE ABDOMEN	
✓ 23	THYROID PROFILE (TOTAL T3, TOTAL T4, TSH)	
24	DENTAL CONSULTATION <i>R/o</i>	
✓ 25	GLUCOSE, POST PRANDIAL (PP), 2 HOURS (POST MEAL)	

Physio - 6

*HH -> 174cm
 WT -> 95kg
 Hip -> 99cm
 W.D -> 106cm
 B.P -> 120/88
 PR -> 98*

ECHOCARDIOGRAPHY REPORT

Name: MR KUSHWAHA KUMAR Age: 41 YEARS GENDER: MALE

Consultant: Dr.VISHAL KUMAR.H. Date : 25/12/2023

Findings

2D Echo cardiography

Chambers

- Left Ventricle: Normal, No RWMA'S,
- Left Atrium: Normal
- Right Ventricle: Normal
- Right Atrium: Normal

Septa

- IVS: Intact
- IAS: Intact

Valves

- Mitral Valve: Normal
- Tricuspid Valve: Normal
- Aortic Valve: Tricuspid, Normal Mobility
- Pulmonary Valve: Normal

Great Vessels

- Aorta: Normal
- Pulmonary Artery: Normal

Pericardium: Normal

Doppler echocardiography

FUSED

Mitral Valve	E	0.97	m/sec	A	0.58	m/sec	No MR
Tricuspid Valve	E	0.51	m/sec	A	0.32	m/sec	No TR
Aortic Valve	Vmax	1.24	m/sec				No AR
Pulmonary Valve	Vmax	0.83	m/sec				No PR
astolic Dysfunction							

MODE MEASUREMENTS

Parameter	Observed Value	Normal Range	
A Aorta	2.7	2.6-3.6	cm
L left Atrium	3.6	2.7-3.8	cm
A Aortic Cusp Separation	1.6	1.4-1.7	cm
II IVS - Diastole	1.0	0.9-1.1	cm
L left Ventricle-Diastole	4.5	4.2-5.9	cm
P Posterior wall-Diastole	0.9	0.9-1.1	cm
I IVS-Systole	1.1	1.3-1.5	cm
LL left Ventricle-Systole	2.9	2.1-4.0	cm
P Posterior wall-Systole	1.2	1.3-1.5	cm
E Ejection Fraction	60	≥ 50	%
F Fractional shortening	30	≥ 20	%
R Right Ventricle	2.6	2.0-3.3	cm

Impression -

- Normal Sized Cardiac Chambers
- No RWMA,S
- normal LV and RV Systolic Function, LVEF 60%
- Normal valves
- No Pericardial Effusion/Vegetation/Clot

DR. VISHAL KUMAR .H

CLINICAL CARDIOLOGIST

Mr Kundan Kumar Nilam 90911 25/12/23

EYE CHECK UP REPORT

Vision Acuity $\left\{ \begin{array}{l} 3/60 \rightarrow 6/6 \\ 3/60 \rightarrow 6/6 \end{array} \right.$

Near Vision $\left\{ \begin{array}{l} N6 \\ \text{e.g.lan} \\ N6 \end{array} \right.$

Digital IOP $\left\{ \begin{array}{l} \text{20} \\ \text{20} \end{array} \right.$

Colour Vision $\left\{ \begin{array}{l} \text{Normal} \\ \text{Normal} \end{array} \right.$

• Fundus: Normal @ study

• Ant. Segment :- normal

• Media: normal

• Pupil: normal

BE Hi-Myopia, fully corrected by glasses.

KHS

Fwd: Health Check up Booking Confirmed Request(bobE3033),Package Code-PKG10000367, Beneficiary Code-256444

Kundan Kushwaha <kundan.kushwaha0@gmail.com>

Mon 12/25/2023 8:33 AM

To:Basavanagudi Apolloclinic <basavanagudi@apolloclinic.com>

Regards

Kundan Kumar Kushwaha

Bank of Baroda

Byrasandra

9329611020

From: Mediwheel <wellness@mediwheel.in>

Sent: Sunday, December 24, 2023 3:34:10 PM

To: kundan.kushwaha0@gmail.com <kundan.kushwaha0@gmail.com>

Cc: customercare@mediwheel.in <customercare@mediwheel.in>

Subject: Health Check up Booking Confirmed Request(bobE3033),Package Code-PKG10000367, Beneficiary Code-256444

011-41195959

Dear **Kundan Kumar kushwaha,**

We are pleased to confirm your health checkup booking request with the following details.

Booking Date : 18-12-2023

Hospital Package Name : Mediwheel Full Body Annual Plus Above 50 Male

Patient Package Name : Mediwheel Full Body Health Checkup Male Above 40

Name of Diagnostic/Hospital : Apollo Clinic

Address of Diagnostic/Hospital- Apollo Clinic, # 99, Bull Temple Road , Next to Ramakrishna mutt, Basavanagudi - 560019

City : Bangalore

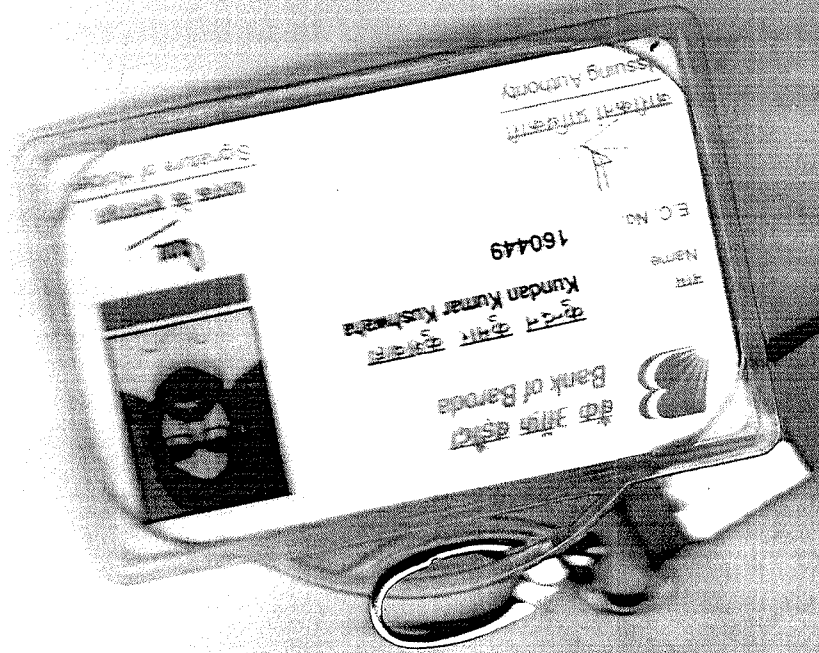State :

Pincode : 560019

Appointment Date : 25-12-2023

Confirmation Status : Booking Confirmed

Preferred Time : 9:00am-9:00pm



भारतीय रिज़र्व
Issuing Authority

E-Cash ID
NAME

160449

कुंदन कुमार कुशवाहा
Kundan Kumar Kushwaha

बैंक ऑफ बरौडा
Bank of Baroda

