



Shubham Imaging & ALC Diagnostic Center

ISO 9001:2015 Certified Center

(A Unit of P. K. Arogyam Health & Wellness Center)

E-95, P.C. Colony, Near Sai Netryalaya Transformer, Kankarbagh, Patna - 20

✉ : alcdiagnostics@gmail.com

🌐 : www.pkarogayamhealthcheckup.com

☎ : 7050037694, 9153988577

OPINION MUST BE CORRELATES WITH CLINICALLY & OTHER INVESTIGATION FOR FINAL DIAGNOSIS. NOT FOR MEDICO LEGAL PURPOSE

PATIENT NAME : EJAZ KHAN

PATIENT ID: 2841

COL DATE : 24/02/2024 REPORTING DATE: 24/02/2024 AGE SEX : 35 YRS/M

REF.BY : DR. / MEDIWHEEL

TEST NAME	RESULT	Unit	REF.RANGE
BLOOD SUGAR (F)	86.0 mg/dl		70 - 110 mg/dl
BLOOD SUGAR (PP)	104.0 mg/dl		70 - 140 mg/dl
LIPID PROFILE:-			
TOTAL CHOLESTROL	249.5 mg/dl		130 -250 mg/dl
TRIGLYCERIDE	158.1 mg/dl		50 -160 mg/dl
HDL CHOLESTROL	54.0 mg/dl		30 - 60 mg/dl
LDL CHOLESTROL	163.9 mg/dl		80 -130 mg/dl
VLDL CHOLESTROL	31.6 mg/dl		15 - 40 mg/dl
T.CH./HDL RATIO	4.6 : 1		Upto 5 :1
LDL /HDL RATIO	3.0 : 1		2 - 4:1

ATC
24/04/2024

ESTB BY:-

Consultant Radiologist

Dr. P. K. Tiwari
MD, M.Sc (Radio Imaging)
Ph.D (Alt Nuclear Medicine)
Consultant Imagonologist

Dr. S. Kumar
MD, (Pat)
Consultant Pathologist

Dr. Abhishek Kumar
MBBS, MD
Consultant Neuropatho Physiologist

Dr. Kumari Suman
MBBS, DGO, MD
Consultant (TVS & HSG Specialist)

Dr. A. K. Singh
MBBS, PGDMCH
Consultant Radiologist & Sonologist

PRINTING MISTAKE SHOULD BE REPORTED BACK IMMEDIATELY / यहाँ जन्म से पहले भ्रुण का लिंग जाँच नहीं होता है।



Shubham Imaging & ALC Diagnostic Center

ISO 9001:2015 Certified Center

(A Unit of P. K. Arogyam Health & Wellness Center)

E-95, P.C. Colony, Near Sai Netryalaya Transformer, Kankarbagh, Patna - 20

✉ : alcdiagnostics@gmail.com

🌐 : www.pkarogayamhealthcheckup.com

☎ : 7050037694, 9153988577

OPINION MUST BE CORRELATES WITH CLINICALLY & OTHER INVESTIGATION FOR FINAL DIAGNOSIS. NOT FOR MEDICO LEGAL PURPOSE

PATIENT NAME : EJAZ KHAN

PATIENT ID: 2841

COL DATE : 24/06/2024 REPORTING DATE: 24/06/2024 AGE SEX:- 35 YRS/M

REF.BY : DR. / MEDIWHEEL .

TEST NAME	RESULT	Unit	REF.RANGE
LFT:-			
SGPT	39.1 IU/L		5 - 40 IU/L
SGOT	32.3 IU/L		5 - 40 IU/L
ALKALINE PHOSPHATASE	99.7 IU/L		M - 53 - 165 IU/L F - 42 - 136 IU/L.
TOTAL PROTIN	7.9 g/dl		6.0 - 8.7 g/dl
SERUM ALBUMIN	5.0 g/dl		3.5 - 5.4 g/dl
SERIUM GLUBLINE	2.9 g/dl		2.3 - 3.6 g/dl
AG RATIO	1.7: 1		1.0 - 2.3 g/dl
BILIRUBIN			
TOTAL	0.74 mg/dl		0.1 - 1.1 mg/dl
DIRECT	0.32 mg/dl		0.0 - 0.32 mg/dl
INDIRECT	0.42 mg/dl		0.0 - 0.78 mg/dl
GGTP(GGT)	24.6 iu/L		8 - 38 iu/L
KFT/RFT			
URIC ACID	4.9 mg/dl		3.2 - 7.0 mg/dl
SERUM CREATNINE	0.8 mg/dl		0.6 - 1.5 mg/dl
BLOOD URIA	32.6 mg/dl		5 - 45 mg/dl
BLOOD URIA NITROZEN(BUN).	15.2 mg/dl		5 - 23 mg/dl

ESTB BY:-

Consultant Radiologist

Dr. P. K. Tiwari

MD, M.Sc (Radio Imaging)
Ph.D (Alt Nuclear Medicine)
Consultant Imaginationologist

Dr. S. Kumar

MD, (Pat)
Consultant Pathologist

Dr. Abhishek Kumar

MBBS, MD
Consultant Neuropatho Physiologist

Dr. Kumari Suman

MBBS, DGO, MD
Consultant (TVS & HSG Specialist)

Dr. A. K. Singh

MBBS, PGDMCH
Consultant Radiologist & Sonologist

ALC
24/06/2024

PRINTING MISTAKE SHOULD BE REPORTED BACK IMMEDIATELY / यहाँ जन्म से पहले भ्रूण का लिंग जाँच नहीं होता है।



Shubham Imaging & ALC Diagnostic Center

ISO 9001:2015 Certified Center

(A Unit of P. K. Arogyam Health & Wellness Center)

E-95, P.C. Colony, Near Sai Netryalaya Transformer, Kankarbagh, Patna - 20

✉ : alcdiagnostics@gmail.com

🌐 : www.pkarogayamhealthcheckup.com

☎ : 7050037694, 9153988577

OPINION MUST BE CORRELATES WITH CLINICALLY & OTHER INVESTIGATION FOR FINAL DIAGNOSIS. NOT FOR MEDICO LEGAL PURPOSE

PATIENT NAME : EJAZ KHAN

PATIENT ID: 2841

COL DATE : 24/02/2024

REPORTING DATE: 24/02/2024

AGE SEX:- 35 YRS/M

REF.BY : DR. / MEDIWHEEL .

TEST NAME	RESULT	Unit	REF.RANGE
ESR	10 mm/hr		<20 mm/hr
CBC			
Total W.B.C. Count	10,500 /cumm		4,000 - 11,000 /cumm
R B C COUNT	4.82 Million/ CUmm		4 - 7 Million/ CUmm
Platelets count	1.64 Lakh/ cumm		1.5 - 5.0 Lakh/ cumm
Differential Count of W.B.C.			
Neutrophils	71%		40 -70%
Lymphocytes	21 %		25 - 40%
Eosinophils	06 %		01 - 05%
Mnonocytes	02 %		00 - 02%
Basophiles	00 %		00 - 0%
HAEMOGLOBIN	15.0 gm/dl (102.7 %)		14.6 gm/dl = 100%
PCV	42.5 %		35 - 47 %
MCV	88.2 fl		76 - 96 fl
MCH	30.1 pg		29 - 35 pg
MCHC	35.2 %		30 - 38 %

ATC
24/02/2024

ESTB BY:-

Consultant Radiologist

Dr. P. K. Tiwari
MD, M.Sc (Radio Imaging)
Ph.D (AlI Nuclear Medicine)
Consultant Imagonologist

Dr. S. Kumar
MD, (Pat)
Consultant Pathologist

Dr. Abhishek Kumar
MBBS, MD
Consultant Neuropatho Physiologist

Dr. Kumari Suman
MBBS, DGO, MD
Consultant (TVS & HSG Specialist)

Dr. A. K. Singh
MBBS, PGDMCH
Consultant Radiologist & Sonologist

PRINTING MISTAKE SHOULD BE REPORTED BACK IMMEDIATELY / यहाँ जन्म से पहले भ्रुण का लिंग जाँच नहीं होता है।



Shubham Imaging & ALC Diagnostic Center

ISO 9001:2015 Certified Center

(A Unit of P. K. Arogyam Health & Wellness Center)

E-95, P.C. Colony, Near Sai Netryalaya Transformer, Kankarbagh, Patna - 20

✉ : alcdiagnostics@gmail.com

🌐 : www.pkarogayamhealthcheckup.com

☎ : 7050037694, 9153988577

OPINION MUST BE CORRELATES WITH CLINICALLY & OTHER INVESTIGATION FOR FINAL DIAGNOSIS. NOT FOR MEDICO LEGAL PURPOSE

PATIENT NAME : EJAZ KHAN

PATIENT ID: 2841

COL DATE

: 24/02/2024 REPORTING DATE: 24/02/2024

AGE SEX : 35 YRS/M

REF.BY

: DR./ MEDIWHEEL.

GLYCOSYLATED HEMOGLOBIN

TEST NAME	RESULT	Unit	REF.RANGE
HbA1c	4.1 %		Below 5.7 % : Normal 5.7 – 6.4 % : Prediabetic > = 6.5 % : Diabetic
AVERAGE PLASMA GLUCOSE	100.0 mg/dl		90 – 120 mg/dl : Good Control 121– 150 mg/dl : Fair Control 151- 180 mg/dl: Unsatisfactory Control >180 mg/dl : Poor Control

ESTB BY:-

Dr. P. K. Tiwari
MD, M.Sc (Radio Imaging)
Ph.D (Alt Nuclear Medicine)
Consultant Imagonologist

Dr. S. Kumar
MD, (Pat)
Consultant Pathologist

Dr. Abhishek Kumar
MBBS, MD
Consultant Neuropatho Physiologist

Dr. Kumari Suman
MBBS, DGO, MD
Consultant (TVS & HSG Specialist)

Dr. A. K. Singh
MBBS, PGDMCH
Consultant Radiologist & Sonologist


Consultant Radiologist

PRINTING MISTAKE SHOULD BE REPORTED BACK IMMEDIATELY / यहाँ जन्म से पहले भ्रण का लिंग जाँच नहीं होता है।



Shubham Imaging & ALC Diagnostic Center

ISO 9001:2015 Certified Center

(A Unit of P. K. Arogyam Health & Wellness Center)

E-95, P.C. Colony, Near Sai Netryalaya Transformer, Kankarbagh, Patna - 20

✉ : alcdiagnostics@gmail.com

🌐 : www.pkarogyamhealthcheckup.com

☎ : 7050037694, 9153988577

OPINION MUST BE CORRELATES WITH CLINICALLY & OTHER INVESTIGATION FOR FINAL DIAGNOSIS. NOT FOR MEDICO LEGAL PURPOSE

PATIENT NAME : EJAZ KHAN

PATIENT ID: 2841

COL DATE : 24/02/2024 REPORTING DATE: 24/02/2024 AGE SEX : 35 YRS/M

REF.BY : DR. / MEDIWHEEL.

TEST NAME	RESULT	Unit	REF.RANGE
-----------	--------	------	-----------

BLOOD GROUP	: 'O'		
-------------	-------	--	--

Rh Typing	: POSITIVE		
-----------	------------	--	--

Note: Do always cross – matching before blood transfusion

[Signature]
24/02/2024

Consultant Radiologist

ESTB BY:-

Dr. P. K. Tiwari
MD, M.Sc (Radio Imaging)
Ph.D (Alt Nuclear Medicine)
Consultant Imagiologist

Dr. S. Kumar
MD, (Pat)
Consultant Pathologist

Dr. Abhishek Kumar
MBBS, MD
Consultant Neuropathology Physiologist

Dr. Kumari Suman
MBBS, DGO, MD
Consultant (TVS & HSG Specialist)

Dr. A. K. Singh
MBBS, PGDMCH
Consultant Radiologist & Sonologist

PRINTING MISTAKE SHOULD BE REPORTED BACK IMMEDIATELY / यहाँ जन्म से पहले भ्रूण का लिंग जाँच नहीं होता है।



Shubham Imaging & ALC Diagnostic Center

ISO 9001:2015 Certified Center

(A Unit of P. K. Arogyam Health & Wellness Center)

E-95, P.C. Colony, Near Sai Netryalaya Transformer, Kankarbagh, Patna - 20

✉ : alcdiagnostics@gmail.com

🌐 : www.pkarogayamhealthcheckup.com

☎ : 7050037694, 9153988577

OPINION MUST BE CORRELATES WITH CLINICALLY & OTHER INVESTIGATION FOR FINAL DIAGNOSIS. NOT FOR MEDICO LEGAL PURPOSE

PATIENT NAME : EJAZ KHAN

PATIENT ID: 2841

COL DATE : 24/02/2024

REPORTING DATE: 24/02/2024

AGE SEX : 35 YRS/M

REF.BY : DR. / MEDIWHEEL..

ROUTINE EXAMINATION OF URINE

PHYSICAL EXAMINATION

Quantity	30 ml	Colour....	Strow
Appearance...	Clear	Sediment ...	Nil
Specific gravity....	1.010		

CHEMICAL EXAMINATION

Reaction	6.0	Nitrite.....	Not done
Sugar	Nil	Bile Pigment ...	Not done
Albumin	Nil	Urobilinogen....	Not done
Excess of Phosphate....	Nil	Chile.....	Not done
Bile Salt	Not Done	Acetone...	Not done

MICROSCOPIC EXAMINATION

Erythrocytes....	Nil	Casts	Nil
Leucocytes	1-3 / HPE	Crystals....	Nil
Epith. Cell	A, Few	Others	Nil

ESTB BY:-


Consultant Radiologist

Dr. P. K. Tiwari
MD, M.Sc (Radio Imaging)
Ph.D (Alt Nuclear Medicine)
Consultant Imagonologist

Dr. S. Kumar
MD, (Pat)
Consultant Pathologist

Dr. Abhishek Kumar
MBBS, MD
Consultant Neuropatho Physiologist

Dr. Kumari Suman
MBBS, DGO, MD
Consultant (TVS & HSG Specialist)

Dr. A. K. Singh
MBBS, PGDMCH
Consultant Radiologist & Sonologist

PRINTING MISTAKE SHOULD BE REPORTED BACK IMMEDIATELY / यहाँ जन्म से पहले भ्रुण का लिंग जाँच नहीं होता है।



Shubham Imaging & ALC Diagnostic Center

ISO 9001:2015 Certified Center

(A Unit of P. K. Arogyam Health & Wellness Center)

E-95, P.C. Colony, Near Sai Netryalaya Transformer, Kankarbagh, Patna - 20

✉ : alcdiagnostics@gmail.com

🌐 : www.pkarogyamhealthcheckup.com

☎ : 7050037694, 9153988577

OPINION MUST BE CORRELATES WITH CLINICALLY & OTHER INVESTIGATION FOR FINAL DIAGNOSIS. NOT FOR MEDICO LEGAL PURPOSE

PATIENT NAME : EJAZ KHAN

PATIENT ID: 2841

COL DATE : 24/02/2024 REPORTING DATE: 24/02/2024 AGE SEX : 35 YRS/M

REF.BY : DR. / MEDIWHEEL.

Investigation	Result	Normal Range
Total Triiodothyronin T3	1.53 ng/mL	0.80 - 2.00 µ ng/mL
Total Thyroxin T4	10.41 ug/mL	5.10 - 14.10 ug/dL
Serum TSH	1.43 µg/mL	0.27 - 4.20 µg/mL

THYROID DISORDER (>: Increase: < Decrease: n Normal

1. T3(n) T4(n) TSH(n) :EUTHYROID STATE:
2. T3(>) T4(>) TSH(<): HYPERTHYROIDISM:
3. T3(<)T4(<) TSH(>): HYPOTHYROIDISM:
4. T3(n)T4(n) TSH(>) : SUB-CLINICAL HYPO-THYROIDISM:
5. T3(n)T4(n) TSH(<): SUB-CLINICAL HYPER-THYROIDISM:
6. T3(>) T4(n) TSH(<): T3 THYROTOXICOSIS:

Total T3/T4 level is dependent on Level:

So determination of free T3/T4is a better MARKER of Thyroid Function.

*FREE T3/T4 ESTIMATION FACILITY IS AVAILABALE ON REQUEST.:


Consultant Radiologist

ESTB BY:-

Dr. P. K. Tiwari
MD, M.Sc (Radio Imaging)
Ph.D (Alt Nuclear Medicine)
Consultant Imagiologist

Dr. S. Kumar
MD, (Pat)
Consultant Pathologist

Dr. Abhishek Kumar
MBBS, MD
Consultant Neuropatho Physiologist

Dr. Kumari Suman
MBBS, DGO, MD
Consultant (TVS & HSG Specialist)

Dr. A. K. Singh
MBBS, PGDMCH
Consultant Radiologist & Sonologist

PRINTING MISTAKE SHOULD BE REPORTED BACK IMMEDIATELY / यहाँ जन्म से पहले भ्रुण का लिंग जाँच नहीं होता है।



Shubham Imaging & ALC Diagnostic Center

ISO 9001:2015 Certified Center

(A Unit of P. K. Arogyam Health & Wellness Center)

E-95, P.C. Colony, Near Sai Netryalaya Transformer, Kankarbagh, Patna - 20

✉ : alcdiagnostics@gmail.com

🌐 : www.pkarogayamhealthcheckup.com

☎ : 7050037694, 9153988577

OPINION MUST BE CORRELATES WITH CLINICALLY & OTHER INVESTIGATION FOR FINAL DIAGNOSIS. NOT FOR MEDICO LEGAL PURPOSE

Pt. Name :- **EJAZ KHAN**
Ref. By :- **DR./MEDIWHEEL**

Date:- **24-Feb-24**
Age / Sex - **35 Yrs. M.**

REAL TIME U.S.G. OF WHOLE ABDOMEN Thanks for your kind referral

(Report.)

- LIVER** :- Measures 16.19 cm. Mild Enlarged in shape , size and echo texture fatty change seen in liver parenchyma. I.H.B.R. are not dilated.
Hepatic veins are normal. No SOL seen.
- G.BL. :- Lumen is echo free. Wall thickness appears normal.
- C.B.D. :- Measures 3.5 mm in diameter with echo free lumen. No calculi or mass seen.
- P.V. :- Measures 7.7 mm in diameter. Appears normal. No thrombus seen.
- PANCREAS :- Normal in shape, size and echo texture. No calcification mass seen.
- SPLEEN :- Measures 10.64 cm. Normal in shape, size and echo texture.
No SOL seen.
- KIDNEY :- Both kidney shows normal shape, size & echotexture. C.M.D.intact.
P.C.S. are not dilated. No calculi, cyst or hydronephrosis seen on either side
Right Kidney :- Measures 10.74 X 4.50 cm.
Left Kidney :- Measures 10.49 X 4.25 cm.
- URETER :- Not dilated. No apparent calculi seen.
- U.BLADDER:- Shows normal in outline with echo free lumen. No calculi or mass seen.
Pre void – 310 ml. Post void – is in significant
- PROSTATE :- Measures 15 gms.(approx). Appears Normal in size, shape, and echo texture.
No calcification , mass ,growth seen. capsule is intact.
- R.I.F. :- Son graphically no appendicular mass or collection seen.
- OTHERS :- No Ascites . no Lymph Adenopathy. No pleural effusion seen on either side .

IMPRESSION

- **Mild Hepatomegaly With fatty liver G-I.**
- **Adv:- Further work up other investigation .**
Otherwise son graphically normal scan. of rest organs

ESTB BY:-

Consultant Radiologist

Dr. P. K. Tiwari
MD, M.Sc (Radio Imaging)
Ph.D (AI Nuclear Medicine)
Consultant Imaginologist

Dr. S. Kumar
MD, (Pat)
Consultant Pathologist

Dr. Abhishek Kumar
MBBS, MD
Consultant Neuropatho Physiologist

Dr. Kumari Suman
MBBS, DGO, MD
Consultant (TVS & HSG Specialist)

Dr. A. K. Singh
MBBS, PGDMCH
Consultant Radiologist & Sonologist

PRINTING MISTAKE SHOULD BE REPORTED BACK IMMEDIATELY / यहाँ जन्म से पहले भ्रूण का लिंग जांच नहीं होता है।



Shubham Imaging & ALC Diagnostic Center

ISO 9001:2015 Certified Center

(A Unit of P. K. Arogyam Health & Wellness Center)

E-95, P.C. Colony, Near Sai Netryalaya Transformer, Kankarbagh, Patna - 20

✉ : alcdiagnostics@gmail.com

🌐 : www.pkarogayamhealthcheckup.com

☎ : 7050037694, 9153988577

OPINION MUST BE CORRELATES WITH CLINICALLY & OTHER INVESTIGATION FOR FINAL DIAGNOSIS. NOT FOR MEDICO LEGAL PURPOSE

Pt. Name :- **EJAZ KHAN**
Ref. By :- **DR./MEDIWHEEL**

Date:- **24-Feb-24**
Age / Sex -**35 Yrs. M.**

Thanks for your kind referral

X-RAY CHEST (P.A.VIEW)

The lungs on the either side show equal translucency.

The peripheral pulmonary vasculature is normal.

No focal lung lesion is seen.

The pleural spaces are normal.

Both hila are normal in size, have equal density and bear normal relationship.

The heart and trachea are central in position and no mediastinal abnormality is visible.

The cardiac size is normal.

The domes of the diaphragms are normal in position, and show smooth outline.

IMPRESSION

- NO EVIDENCE OF PULMONARY OR CARDIAC PATHOLOGY IS NOTED.

ESTB BY:-

Dr. P. K. Tiwari
MD, M.Sc (Radio Imaging)
Ph.D (AI Nuclear Medicine)
Consultant Imagiologist

Dr. S. Kumar
MD, (Pat)
Consultant Pathologist

Dr. Abhishek Kumar
MBBS, MD
Consultant Neuropatho Physiologist

Dr. Kumari Suman
MBBS, DGO, MD
Consultant (TVS & HSG Specialist)

Dr. A. K. Singh
MBBS, PGDMCH
Consultant Radiologist & Sonologist

Consultant Radiologist

PRINTING MISTAKE SHOULD BE REPORTED BACK IMMEDIATELY / यहाँ जन्म से पहले भ्रूण का लिंग जाँच नहीं होता है।



Shubham Imaging & ALC Diagnostic Center

ISO 9001:2015 Certified Center

(A Unit of P. K. Arogyam Health & Wellness Center)

E-95, P.C. Colony, Near Sal Notryalaya Transformer, Kankarbagh, Patna - 20

✉ : alcdiagnostics@gmail.com

🌐 : www.pkarogyamhealthcheckup.com

☎ : 7050037694, 9153988577

OPINION MUST BE CORRELATES WITH CLINICALLY & OTHER INVESTIGATION FOR FINAL DIAGNOSIS. NOT FOR MEDICO LEGAL PURPOSE

ECHOCARDIOGRAPHY & COLOR DOPPLER REPORT

Patient's Name : Mr. EJAZ KHAN

Age/Sex : 35 Yrs /M

Ref. by : DR./ MEDIWHEEL

Date : 24-Feb-24

ECHOCARDIOGRAPHIC WINDOW: Fair 2D & M MODE ECHOCARDIOGRAPHY

Left ventricle

EDD:	28	mm (20 - 28 mm / m ²)	ESD:	21	mm (13 - 21 mm / m ²)
IVS:	11	mm (6 - 11 mm)	PW:	8	mm (6 - 11 mm)
Ejection fraction:		60% (61 ± 8%)	FS:	35	% (34 - 44 %)
IVS:	Intact		LV clot		Absent

Left atrium/ Aorta 35/31 mm

Right ventricle Normal

Right atrium Normal

Pericardium Normal with no pericardial effusion

2D:

Normal LA/LV Size and normally contracting left ventricle. No RWMA, concentric LVH

Mitral valve

AML/ PML: Normal

Tricuspid valve Normal

Aortic valve Normal

Pulmonary valve Normal

Continuous & Pulse Wave Doppler study

Valve	Velocity (m/sec)			Gradient (mmHg)			Valve area (PHT Method)	Regurg.
	Peak	Mean	EDV	Peak	Mean	EDG		
Mitral	E=07 A=0.6			2.3	2.0			Nil
Tricuspid	E=0.5 A=0.3			1.9	0.2			Nil
Aortic	1.12			5.0	2.5			Nil
Pulmonary	0.9			3.5	1.7			Nil

ESTB BY:-

Consultant Radiologist

Dr. P. K. Tiwari
MD, M.Sc (Radio Imaging)
Ph.D (Art Nuclear Medicine)
Consultant Imagionologist

Dr. S. Kumar
MD, (Pat)
Consultant Pathologist

Dr. Abhishek Kumar
MBBS, MD
Consultant Neuropatho Physiologist

Dr. Kumari Suman
MBBS, DGO, MD
Consultant (TVS & HSG Specialist)

Dr. A. K. Singh
MBBS, PGDMCH
Consultant Radiologist & Sonologist

PRINTING MISTAKE SHOULD BE REPORTED BACK IMMEDIATELY / यहाँ जन्म से पहले भ्रूण का लिंग जाँच नहीं होता है।



Shubham Imaging & ALC Diagnostic Center

ISO 9001:2015 Certified Center

(A Unit of P. K. Arogyam Health & Wellness Center)

E-95, P.C. Colony, Near Sai Netryalaya Transformer, Kankarbagh, Patna - 20

✉ : alcdiagnostics@gmail.com

🌐 : www.pkarogyamhealthcheckup.com

☎ : 7050037694, 9153988577

OPINION MUST BE CORRELATES WITH CLINICALLY & OTHER INVESTIGATION FOR FINAL DIAGNOSIS. NOT FOR MEDICO LEGAL PURPOSE

Colour Flow Imaging

No TR, No MR/PR, No AR

No flow shunt

COMMENTS :

- ◆ Normal size all chamber
- ◆ Normal LV filling Pressure
- ◆ No RWMA
- ◆ Normal LV systolic function
- ◆ Grade I LV diastolic dysfunction.
- ◆ Global LVEF = 60%
- ◆ All cardiac valves are normal
- ◆ No PAH, Mild concentric LVH
- ◆ No MS / TS / AS / PS / PR
- ◆ No clot / vegetation / pericardial effusion.

IMPRESSION:

All chambers are normal

No RWMA, No PAH

Grade I LV diastolic dysfunction.

Normal LV systolic function, LVEF – 65%

Please correlate clinically


DR. SANDEEP KUMAR MBBS MD

ESTB BY:-

Consultant Radiologist

Dr. P. K. Tiwari

MD, M.Sc (Radio Imaging)
Ph.D (Alt Nuclear Medicine)
Consultant Imagonologist

Dr. S. Kumar

MD, (Pat)
Consultant Pathologist

Dr. Abhishek Kumar

MBBS, MD
Consultant Neuropatho Physiologist

Dr. Kumari Suman

MBBS, DGO, MD
Consultant (TVS & HSG Specialist)

Dr. A. K. Singh

MBBS, PGDMCH
Consultant Radiologist & Sonologist

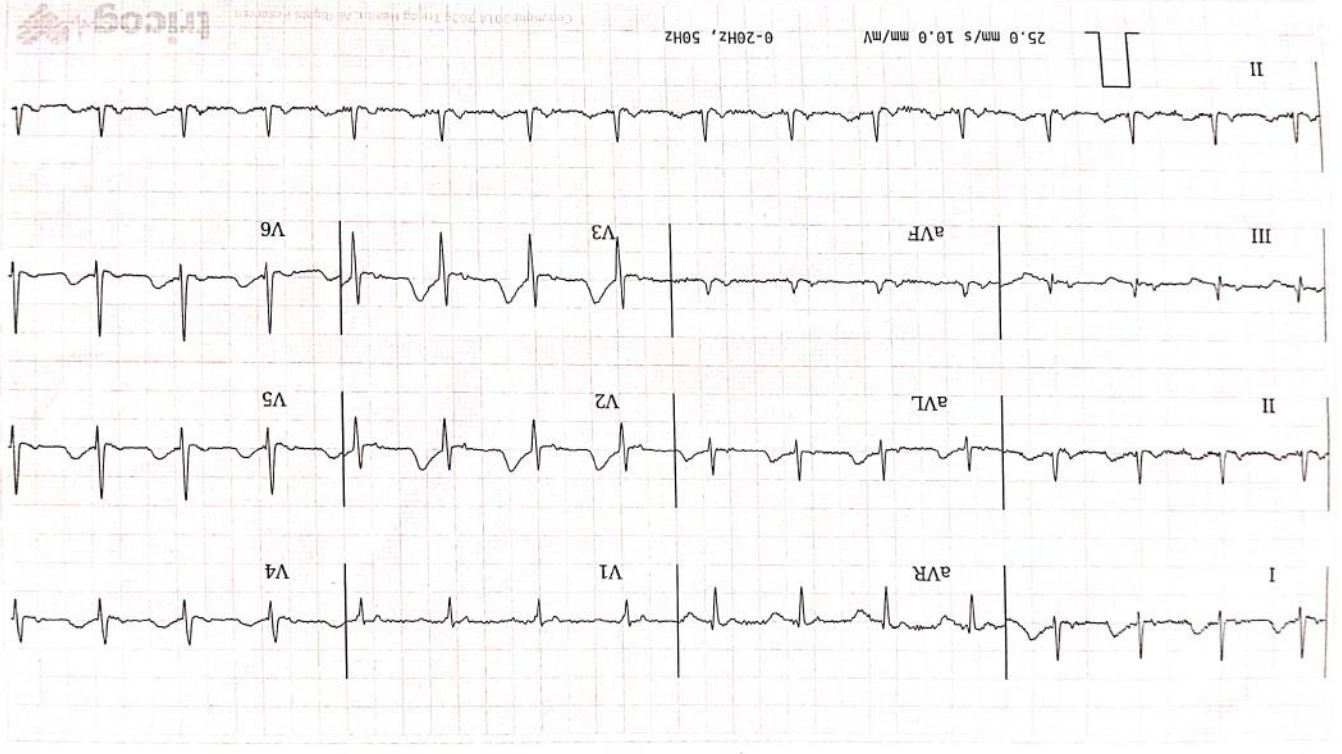
PRINTING MISTAKE SHOULD BE REPORTED BACK IMMEDIATELY / यहाँ जन्म से पहले भ्रूण का लिंग जाँच नहीं होता है।



Disclaimer: Analysis in this report is based on ECG alone and should only be used as an adjunct to clinical history, symptoms and results of other invasive and non-invasive tests and must be interpreted by a qualified physician.

ECG Within Normal Limits: Sinus Rhythm. Please correlate clinically.

AR: 96bpm VR: 96bpm QRS: 78ms QT: 306ms QTcB: 387.06ms PRI: 142ms P-R-T: 59° 34° NA



Age / Gender: 35/Male
Patient ID: 2841
Patient Name: Ejaz Khan

Date and Time: 24th Feb 24 10:28 AM

PK AROGYAM