



# GD Hospital

## गीतादेवी हॉस्पिटल

Hospital Reg. No. NH/1985/JUN-2016



- हृदय रोग विशेषज्ञ
- किडनी एवं मूत्र रोग विशेषज्ञ (यूरो सर्जन)
- आई.सी.यू. एवं क्रिटिकल ट्रीमा केयर
- जनरल एवं लेप्रोथोकोपिक सर्जन
- नाक, कान, गला रोग विशेषज्ञ
- ऑक्युपेशनल थैरापिस्ट/फिजियोथैरापिस्ट
- न्यूरोसर्जन
- महिला रोग विशेषज्ञ
- प्लास्टिक सर्जन
- डायलिसिस सुविधा
- जनरल फिजिशियन
- ओगल एवं मैक्सिलोफेशियल सर्जन

EPlycode 171907

PT. Name	: MR..PROLAY KUMAR MONDAL	Date	: 23-11-2023
F/H Name	: HARE KRISHNA MONDALI	OPD NO	: 6
Age / Gender	: 39 Y / M	Mobile No	: 8892147042
UHID No	: 23-10283	Fees	: 0.00
Consultant	: DEVENDRA VAISHNAV	Bill No	: 23-31487
Department	: ANESTHESIOLOGY		
Doctor Reg No	: MP-10124		
Address	: ,RAJ BAG,RATLAM		

1. Height	2. Weight	3. BMI	4. Build	5. Pulse Rate/min	6. Blood Pressure
Cms	Kgs		Normal	89	140/100
176	88.60	28.04	Under weight	SPQ-99	
			Over weight	7. Respiratory Rate/min	

8. Visual Acuity Whether he/she falls in the category of visually impaired

Eye	Vision	9. Dental /Oral Hygiene
Right	6/6	
Left	6/6	

Rx  
 X-ray - done  
 blood sample - done  
 ECG - done  
 Urine R - done  
 M - done  
 Cx - Done  
 LFR

Rt and cavity - and teeth  
 are normal - some  
 Jimmy after RPR  
 Done  
 Rt has no any fresh  
 some an nitols  
 at RPR 130/90mg R-791m SPQ-984.  
 T. ok.  
 SIE - crs - Carious noted.  
 cre. SIE were RPR - BSR (P)  
 Rt were fit on with nitol.  
 and SIE Examination  
 no no - enhance mess

USG advice

10. Conclusion:	
11. Recommendations:	Tests
	Diet

पता : 80 फीट रोड, रत्नपुरी, रतलाम  
 +91 9752450505, 9111013321  
 info@gdhospitals.com  
 www.gdhospitals.com

सभी प्रमुख बीमा कंपनियों से केश लैस उपचार की सुविधा उपलब्ध है  
 नोट : कृपया अपॉईटमेन्ट हेतु हेल्प लाईन नं. पर संपर्क करें।  
 रविवार को मेडिकल इमरजेंसी होने पर ही आवें।  
 पुनः दिखाने के लिये रविवार छोड़कर आवें।

आई.सी.यू. सुविधा उपलब्ध  
 डॉक्टर को दिखाने के 7 दिन बाद शुल्क मान्य रहेगा।

R

Take Diastone.



1 Pcs — X 1 month.

Take Urinax 0.4mg

1 ms. — X 1 month

Plenty of liquid.

1  
Q

<b>Name</b> : MR. PROLAY KUMAR MONDAL	<b>UHID.No</b> : 23-10283	<b>IPD/OPD</b> : OPD
<b>Age/Sex</b> : 39 Y / M	<b>Accession No.</b> : 20231123023	<b>Category</b> : MEDIWHEEL
<b>Consultant</b> : DEVENDRA VAISHNAV	<b>Bill / IPD No.</b> : 23-31569	
 <b>Registration No</b>		 <b>Accession No</b>

**HAEMATOLOGY REPORT**

Sample Collected: 23-Nov-2023 3:48 PM  
 Sample Type: EDTA BLOOD



Test Name	Results	Unit	Biological Reference Range
Haemoglobin	15.3	gm/dl	12-16
Total Red Blood Count	5.66	Millions/cumm	3.5-5.5
Haematocrite	46.0	%	36.0-51.0
MCV	81.27	fl	77-95
MCH	27.03	pg	26-32
MCHC	33.26	g/dl	30-36
Total Leukocyte Count	5600	cells/cumm	4,000-11,000
Neutrophils	54	%	40-70
Lymphocytes	40	%	20-45
Eosinophils	02	%	2.0-6.0
Monocytes	04	%	2.0-8.0
Basophils	00	%	0-0.1%
Platelet	2.31	lakhs/cmm	1.5-4.5
Erythrocyte Sedimentation Rate			
ESR	09	mm	0-9
BLOOD GROUP			
ABO	A		
Rh TYPE	POSITIVE		

Remarks :

  
 DR. LEKHRAJ PATIDAR

• Home Collection Facility Available •

Note : Diagnostic test have technical limitation. | For technical disparity repeated examination are required.  
 No legal liability is accepted. | Clinical correlation is requested. This test is not valid for medico-legal purpose.

Name : MR. PROLAY KUMAR MONDAL	UHID.No : 23-10283	IPD/OPD: OPD
Age/Sex : 39 Y / M	Accession No. : 20231123023	Category : MEDIWHEEL
Consultant : DEVENDRA VAISHNAV	Bill / IPD No. : 23-31569	
		
Registration No		Accession No

## BIOCHEMISTRY

Sample Collected: 23-Nov-2023 3:48 PM

Sample Type: SERUM

Test Name	Results	Unit	Biological Reference Range
<b>LIPID PROFILE.</b>			
TOTAL CHOLESTROL	189.2	mg/dl	0-200
TRIGLYCERIDES.	161.0	mg/dl	0-150
CHOLESTEROL HDL	49.06	mg/dl	35-85
CHOLESTEROL LDL	107.94	mg/dl	0-130
CHOLESTEROL VLDL	32.20	mg/dl	10-30
TOTAL CHOLESTEROL HDL RATIO	3.86	%	3-4.4
CHOLESTEROL LDL CHOLESTEROL HDL RATIO	2.20	%	0.1-3.0
<b>LIVER FUNCTION TEST (LFT)</b>			
Serum Bilirubin (Total)	0.82	mg/dl	0.1-1.0
Serum Bilirubin (Direct)	0.39	mg/dl	0.0-0.2
Serum Bilirubin (Indirect)	0.43	mg/dl	0.0-0.8
SGOT (AST)	21.29	U/L	9-40
SGPT (ALT)	18.73	U/L	9-40
Alkaline Phosphatase	147.0	U/L	100-250
Total Protein	6.72	g/dL	6.3-8.2
Albumin	3.68	g/dl	3.5-5.0
Globulin	3.04	g/dl	0-5
Albumin Globulin Ratio	1.21	Ratio	1.0-2.3
BLOOD SUGAR (FASTING)	91.20	mg/dl	70 - 110
BLOOD UREA NITROGEN	13.90	mg/dl	5-25
Serum Creatinine	0.89	mg/dl	0.70-1.40
Uric Acid	4.20	mg/dl	2.0-7.0

Remarks :

DR. LEKHRAJ PATIDAR

• Home Collection Facility Available •

Note : Diagnostic test have technical limitation. | For technical disparity repeated examination are required.  
No legal liability is accepted. | Clinical correlation is requested. This test is not valid for medico-legal purpose.

# GD Pathology

## जी.डी. पथोलॉजी

Reg. No. CL/1058/AUG-2020



gdpathologylab@gmail.com

www.gdhospitals.com

80 Feet Road, Ratnapuri, Ratlam (M.P.)

97524-50505, 91110-13321

Name :MR. PROLAY KUMAR MONDAL	UHID. No. :23-10283	IPD/OPD Status :OPD
Age/Sex :39 Y/Male	Lab No. :20231123023	consultant :Dr.DEVENDRA VAISHNAV
Ref. Dr.	Receipt no : 23-31569	Location/Bed.No : ,

Collected at:23/11/2023 15:48:00

Report Gen at:



### BIOCHEMISTRY



Accession No

Registration No

SAMPLE TYPE : EDTA BLOOD

Investigations	Result	Unit	Biological Reference Interval
HbA1C (GLYCOSYLATED Hb )	5.10	%	4.0- 6.0 %

#### HbA1C

HbA1C

4.0-6.0%

Good control 6-7%

Fair control 7-8%

Poor control >8%

#### Estimated Blood Glucose (ABG)

97-126 mg/dl

126-154 mg/dl

154-183 mg/dl

183 mg/dl

TECHNOLOGIST

• Home Collection Facility Available •

Dr. LEKHRAJ RATIDAR

Note : Diagnostic test have technical limitation. | For technical disparity repeated examination are required. No legal liability is accepted. | Clinical correlation is requested. This test is not valid for medico-legal purpose.



Name	:MR. PROLAY KUMAR MONDAL	UHID. No.	:23-10283	IPD/OPD Status	:OPD
Age/Sex	:39 Y/Male	Lab No.	:20231123023	consultant	:Dr.DEVENDRA VAISHNAV
Ref. Dr.		Receipt no	: 23-31569	Location/Bed.No	;

Collected at:23/11/2023 15:48:00



Accession No

### HAEMATOLOGY REPORT

Report Gen at:



Registration No

SAMPLE TYPE : SERUM

Investigations	Result	Unit	Biological Reference Interval
T3 (Total Triiodothyronine)	1.39	nmol/L	1.23-3.07
T4 (Total Thyroxine)	112.6	nmol/L	66-181
TSH (Thyroid Stimulating Hormone)	3.60	mIU/L	0.30-4.2

TECHNOLOGIST

• Home Collection Facility Available •

Dr. LEKHRAJ PATIDAR

Note : Diagnostic test have technical limitation. | For technical disparity repeated examination are required.  
No legal liability is accepted. | Clinical correlation is requested. This test is not valid for medico-legal purpose.

# GD Pathology



जी.डी. पथोलॉजी

Reg. No. CL/1058/AUG-2020



gdpathologylab@gmail.com  
www.gdhospitals.com  
80 Feet Road, Ratnapuri, Ratlam (M.P.)  
97524-50505, 91110-13321

Name : MR. PROLAY KUMAR MONDAL	UHID.No : 23-10283	IPD/OPD: OPD
Age/Sex : 39 Y / M	Accession No. : 20231123023	Category : MEDIWHEEL
Consultant : DEVENDRA VAISHNAV	Bill / IPD No. : 23-31569	

Registration No  Accession No 

## CLINICAL PATHOLOGY

Sample Collected: 23-Nov-2023 3:48 PM

Sample Type: URINE,

Test Name	Results	Unit	Biological Reference Range
<b>PHYSICAL EXAMINATION.</b>			
QUANTITY	30ML		
COLOUR.	PALE YELLOW	-	-
APPEARANCE	CLEAR	-	-
PH	ACIDIC		
SPECIFIC GRAVITY	1.020		
<b>CHEMICAL EXAMINATION.</b>			
Urine Sugar	NIL	-	NIL
Urine Albumin	NIL		
BS/BP	ABSENT		ABSENT
KETONE.	ABSENT		ABSENT
<b>MICROSCOPIC EXAMINATION.</b>			
PUS CELLS	3-5	/hpf	0-4
EPITHELIAL CELLS	2-4	/HPF	0-2
RBC,	NIL	/HPF	0-2
CASTS	ABSENT	-	-
CRYSTALS	ABSENT	/HPF	-
BACTERIA	ABSENT		
YEAST	ABSENT		

Remarks :

DR. LEKHRAJ PATIDAR

• Home Collection Facility Available •

Note : Diagnostic test have technical limitation. | For technical disparity repeated examination are required.  
No legal liability is accepted. | Clinical correlation is requested. This test is not valid for medico-legal purpose.



**Arihant  
Pathology Laboratory**



Scan QR code to check  
report authenticity

**sterling  
ACCURIS**  
Pathology lab that cares

Passport No :

**LABORATORY TEST REPORT**



Patient Information	Sample Information	Client/Location Information
Name : Mr Pralay Kumar	Lab Id : 112312501078	Client Name : G Y Foundation@Ratlam
Sex/Age : Male / 39 Y	Registration on : 23-Nov-2023 17:44	Location :
Ref. Id :	Collected at : non SAWPL	Approved on : 24-Nov-2023 12:37 Status : Final
Ref. By : Dr Devendra Vaishnav	Collected on : 23-Nov-2023 17:44	Printed On : 24-Nov-2023 12:57
	Sample Type : Serum	Process At : 1. NRL SAWPL Gujarat Ahmedabad Paldi

**Biochemistry**

Test	Result	Unit	Biological Ref. Interval
<b>GGT</b> <i>L-glytamyf-p-nitroanilide</i>	21.0	U/L	15 - 73

----- End Of Report -----

*Dr*

**Dr. Purvish Darji**  
MD(Path)

**Dr. Sanjeev Shah**  
MD Path

**Dr.Yash Shah**  
MD Path



**Sterling Accuris Pathology Laboratory**

Laboratory: (Arihant Pathology Laboratory), 15, Ved Vyas Colony, Ratlam, Madhya Pradesh 457001  
Ph.: 07412-297458

info.ratlam@sterlingaccuris.com | Website: www.sterlingaccuris.com | Follow us on:

This is an Electronically Authenticated Report.

Page 1 of 1



Download Accuris App



Facility: MRI, CT SCAN, 4D Sonography, Colour Doppler

<b>PT NAME</b>	<b>MR. PROLAY KUMAR</b>	<b>AGE /SEX/</b>	<b>39YEAR / MALE</b>
<b>REF BY</b>	<b>DR. DEVENDRA VAISHNAV GD HOSPITAL, RATLAM</b>	<b>DATE</b>	<b>23/11/2023</b>

**ULTRASOUND WHOLE ABDOMEN**

**Liver** is normal in size (12.7cm) and shows raised echotexture. Hepatic venous system appear normal. No focal lesion is seen. Intra and extra hepatic biliary radicles are not dilated. Portal vein and CBD are normal in caliber.

**Gall bladder** is normal in size & shape. Its lumen is echofree and nonlithiastic.

**Pancreas** is normal in size outline & echo pattern.

**Spleen** is normal in size (9.5cm) and echo pattern.

**Right kidney** is normal in size (10.6x4.9cm), shape and echogenicity with smooth outline. Central pelvicalyceal sinus and corticomedullary ratio are normal. No calculus seen.

**Left kidney** is normal in size (10.4x5.5cm), shape and echogenicity with smooth outline. Central pelvicalyceal sinus and corticomedullary ratio are normal. A calculus of size measuring approx.. 4.5mm noted at lower pole calyx.

**Urinary bladder** is normal in shape & contour. Its wall is normal. Both V.U.J. are clear.

**Prostate** is normal in size (2.6x2.9x2.3cm, 9.7cc), shape echotexture & contour. IVC and abdominal aorta are normal in calibre. No evidence of intra-abdominal lymphadenopathy. No evidence of ascites is seen.

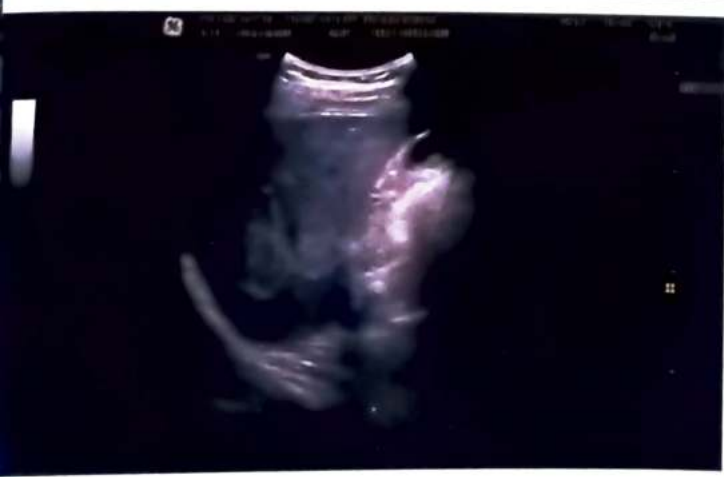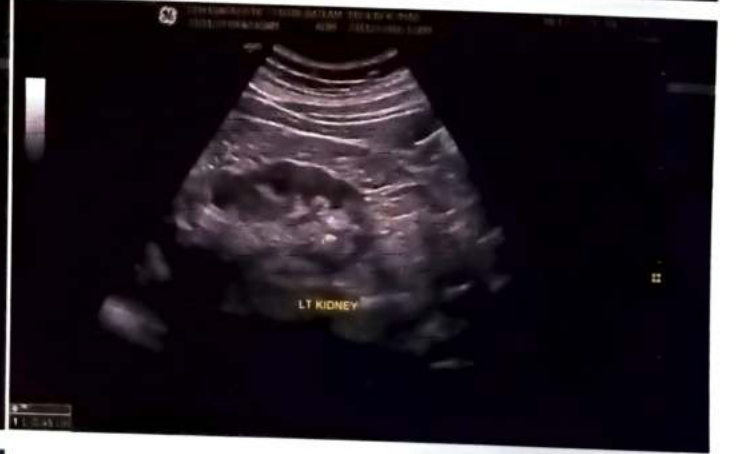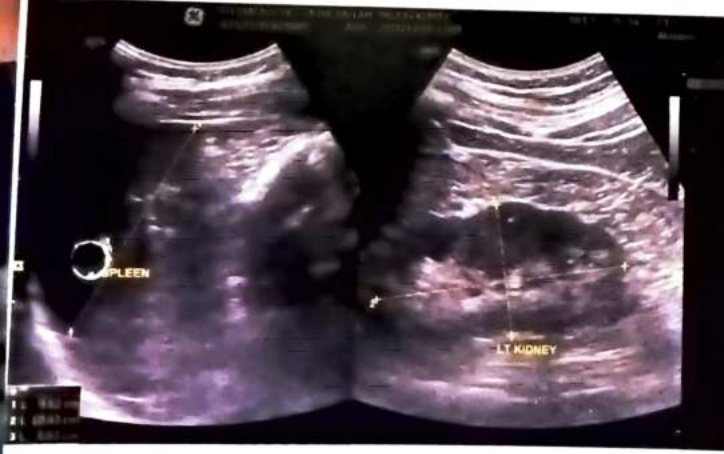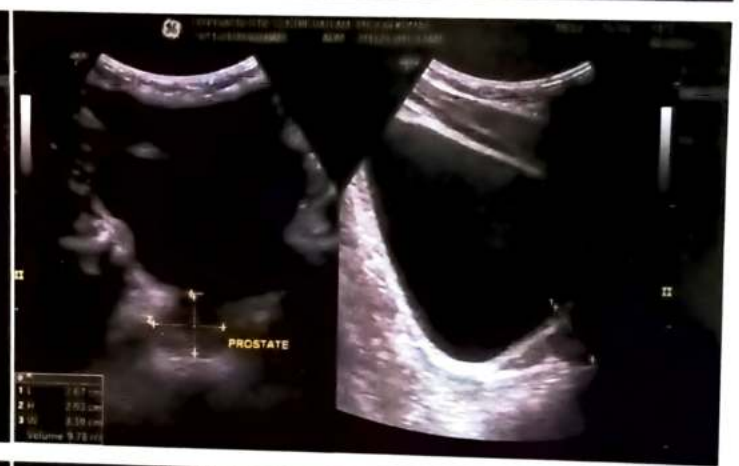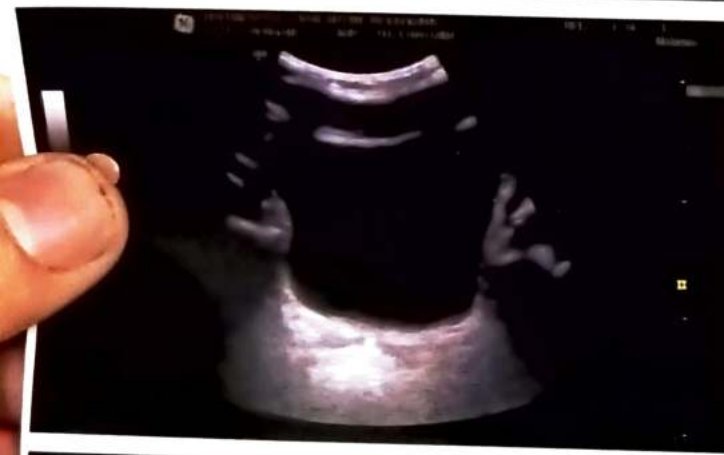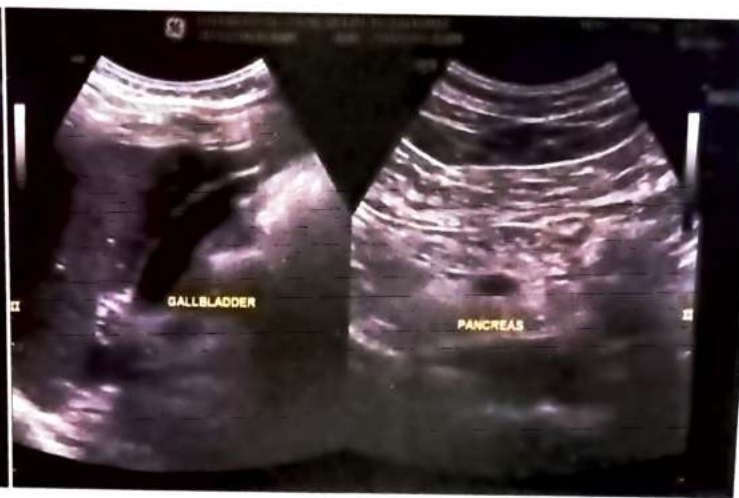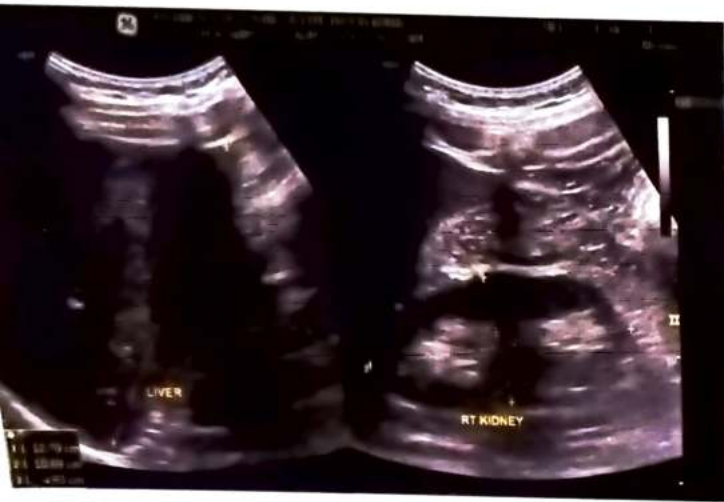**IMPRESSION: Ultrasound whole abdomen study show:**

- > Grade I fatty liver.
- > Left renal calculus.

**Advice: Clinical correlation and further evaluation.**

**DR. ANUGRAH PATERIA**  
(Radiologist)

It is a professional opinion, not valid for medico legal purpose.



**GD Hospital**

**गीतादेवी हॉस्पिटल**

Hospital Reg. No. NH/1985/JUN-2016



info@gdhospitals.com  
www.gdhospitals.com



+91-97524 50505  
+91-91110 13321



80 Feet Road, Ratnapuri,  
Ratlam (M.P.) 457001

Date: 23/11/2023

Patient Name:- : Prolay kumar Mondal 39 year male

## X-RAY-CHEST (PA VIEW)

### FINDINGS:-

**Bilateral lung fields are normal,**

The pleural spaces are normal.

Both hila are normal in size have equal density and bear normal relations

The heart and trachea are central in position and no mediastinal abnormal

No mediastinal abnormality visible

The cardiac size is normal.

The domes of diaphragm are normal in position and show smooth outline.

### IMPRESSION:-

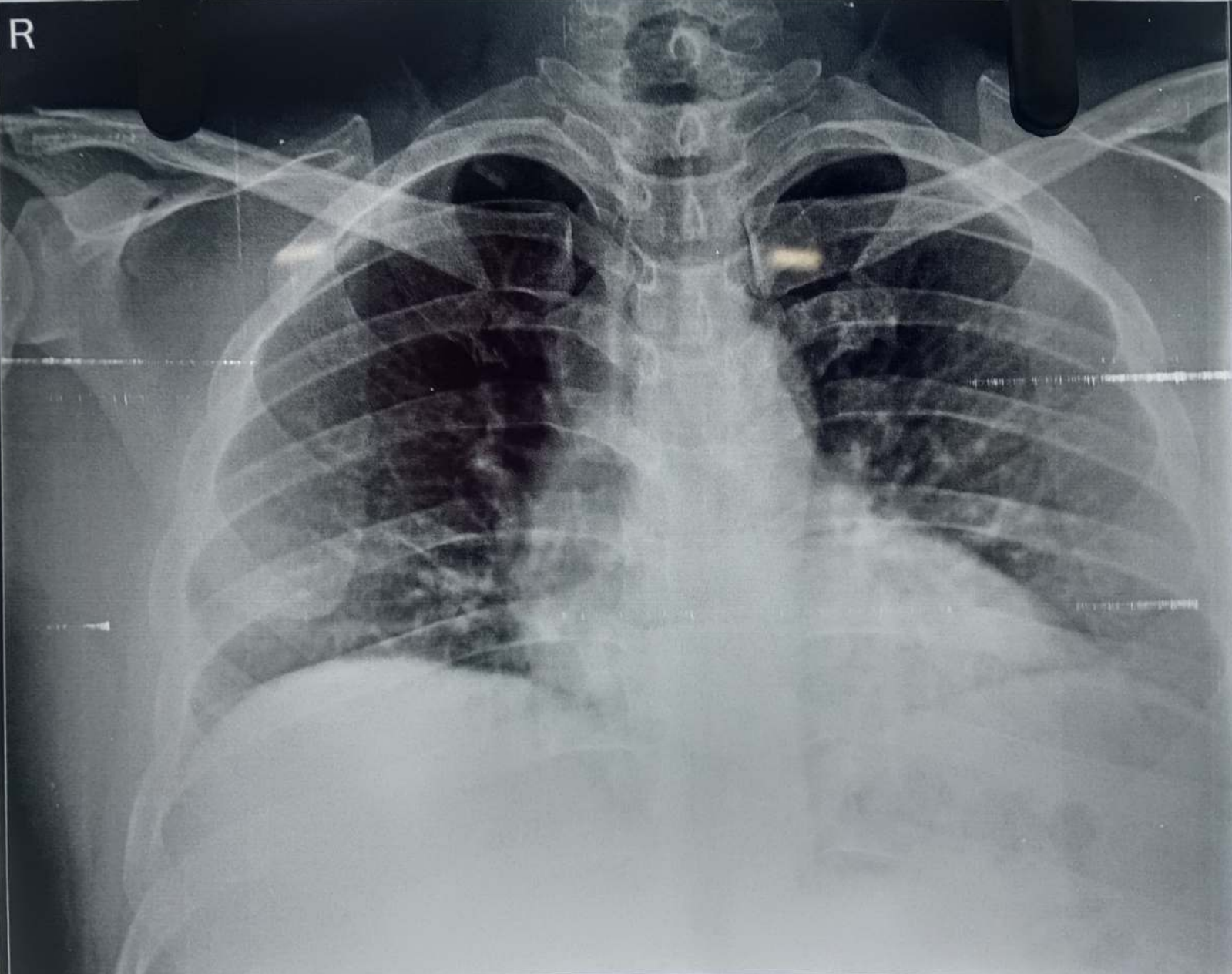
No significant abnormality seen

  
DR. AMUGRAH PATERIA

MBBS, MD

Consultant Radiologist.

R



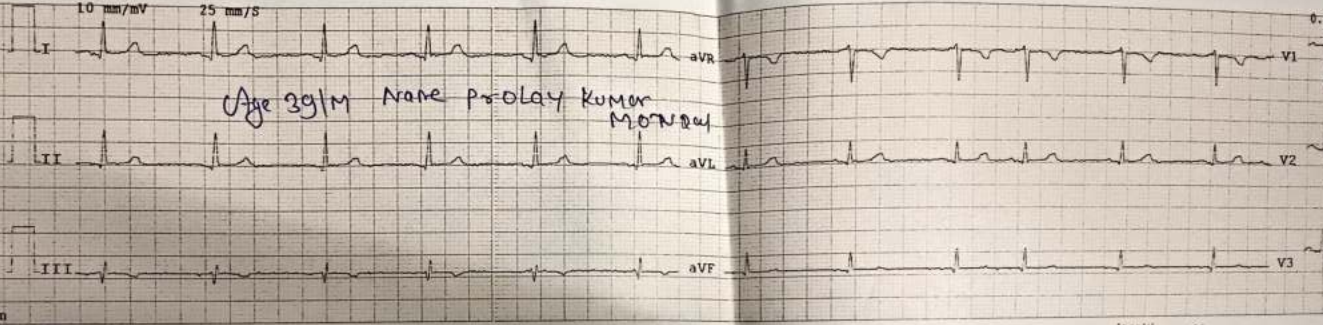
MR PROLAY KUMAR 39Y 23-10283 CHEST PA 23/11/2023  
GD HOSPITAL 80FEET ROAD RATNPURI, RATLAM PH:9111013321

ID :  
Name :  
Age : Years  
Gender :  
BP : (mmHg)  
Weight : Kgs  
Date : 23/11/23  
12:41 PM  
Note :

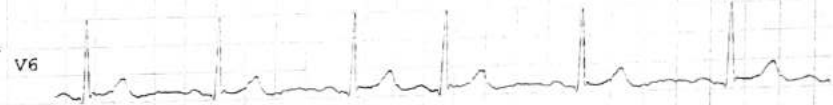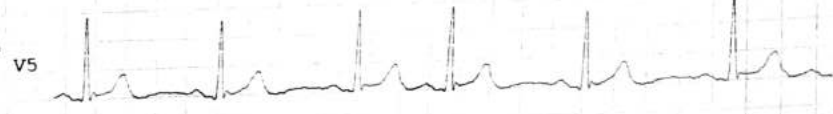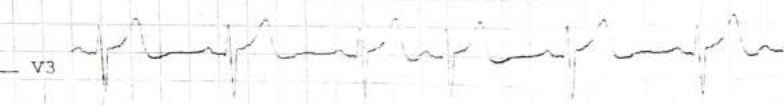
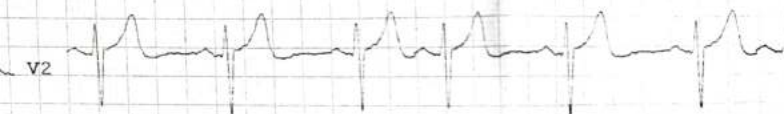10 mm/mV  
25 mm/s

Age 39/M Name Pralay Kumar  
MONDAY

VESTA 3011  
(Ver 3.15.33)  
www.rmsindia.com



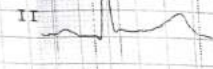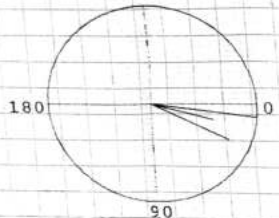
0.05-35 Hz 50 Hz



APR 10  
10

P \_\_\_\_\_  
 QRS \_\_\_\_\_  
 T \_\_\_\_\_

20mm/mV  
 50mm/S



AXIS (degr)

P	QRS	T
7	26	14

Parameters

HR : 67 BPM

QRS DUR : 85 mS

QT INT : 364 mS

QTc INT : 385 mS

PR INT : 138 mS

RR INT : 895 mS

QT/QTc : 94 %

QT/RR : 40 %

RV5/SV1 : 1.21/0.82 mV

Adult Interpretation Report:

Sinus Rhythm

Normal Sinus Rhythm ECG

Note: Results may be clinically correlated

Dr.



# GD Hospital

## गीतादेवी हॉस्पिटल

Hospital Reg. No. NH/1985/JUN-2016



Info@gdhospitals.com  
www.gdhospitals.com



+91-97524 50505  
+91-91110 13321



80 Feet Road, Ratnapuri,  
Ratlam (M.P.) 457001

Date **23/11/2023**.....

### ECHO REPORT

Name:- : MR. PROLAY KUMAR MONDAL AGE 39 Y SEX - MALE

- All cardiac chambers are normal in size.
- All cardiac valves are normal.
- Aortic root & PA are normal.
- No RWMA.
- Normal LV systolic function (LVEF 65%)
- IAS & IVS are intact.
- Pericardium is normal.
- No clot /Thrombus / Vegetation.

#### **DOPPLER:**

- No significant gradient across all valves .
- Normal flow across all valves.

#### **IMPRESSION**

- No RWMA
- Normal LV systolic function
- LVEF 65%

  
**DR. BHARAT KUMRAWAT**

**MD MEDICINE**