



GD Hospital

गीतादेवी हॉस्पिटल

Hospital Reg. No. NH/1985/JUN-2016



- हृदयी रोग विशेषज्ञ
- किडनी एवं मूत्र रोग विशेषज्ञ (यूरो सर्जन)
- आइ.सी.यू. एवं क्रिटिकल ट्रॉमा केयर
- जनरल एवं लेप्रोस्कोपिक सर्जन
- नाक, कान, गला रोग विशेषज्ञ
- ऑक्युपेशनल थैरिपिस्ट/फिजियोथैरिपिस्ट
- न्यूरोसर्जन
- महिला रोग विशेषज्ञ
- प्लास्टिक सर्जन
- डायलिसिस सुविधा
- जनरल फिजिशियन
- ओरल एवं मैक्सिलोफेशियल सर्जन

☎ : 9752450505, 9111013321 ✉ : info@gdhospitals.com 🌐 : www.gdhospitals.com

PT. Name : Mrs..KIRTI GARG
 F/H Name : ROHAN PANDEY
 Age / Gender : 39 Y / F
 UHID No : 23-10292
 Consultant : DEVENDRA VAISHNAV
 Department : ANESTHESIOLOGY
 Doctor Reg No : MP-10124
 Address : ,MANGAL MURTI RECYDENCY,RATLAM

Date : 23-11-2023
 OPD NO : 11
 Mobile No : 8588968410
 Fees : 0.00
 Bill No : 23-31508

1. Height	2. Weight	3. BMI	4. Build	5. Pulse	6. Blood Pressure
Cms	Kgs			Rate/min	
166	68.9 kg	25	Normal	74	120/78
			Under weight	SpO ₂ 95%	186/114
			Over weight	7. Respiratory Rate/min	

8. Visual Acuity Whether he/she falls in the category of visually impaired

Eye	Vision	9. Dental /Oral Hygiene
Right	Abnormal	
Left	Abnormal	

Rx .
 Blood sample - Done ✓
 Urine CA - Done ✓
 X-ray - Done ✓
 ECG - Done ✓
 Eye - Done ✓

PT complaining for health checkup
 PT Have no complaints
 all Blood Report are normal

Pap smw - Done

GD HOSPITAL
 80 Feet Road Ratnapuri, Ratlam
 Reg.-NH1985/JUN/2016

10. Conclusion:		
11. Recommendations:	Tests	Diet

Facility: MRI, CT SCAN, 4D Sonography, Colour Doppler

PT. NAME	MRS. KIRTI GARG	AGE /SEX/	39YEARS /FEMALE
REF. BY	DR. DEVENDRA VAISHNAV	DATE	13/12/2023

ULTRASOUND WHOLE ABDOMEN

Liver is normal in size (12.3cm) and echotexture. Hepatic venous system appear normal. No focal lesion is seen. Intra and extra hepatic biliary radicles are not dilated. Portal vein and CBD are normal in caliber.

Gall bladder is normal in size & shape. Its lumen is echofree and nonlithiastic.

Pancreas is normal in size outline & echo pattern.

Spleen is normal in size (8.3cm) and echo pattern.

Right kidney is normal in size (10.1x3.9cm), shape and echogenicity with smooth outline. Central pelvicalyceal sinus and corticomedullary ratio are normal. No calculus seen.

Left kidney is normal in size (9.7x3.8cm), shape and echogenicity with smooth outline. Central pelvicalyceal sinus and corticomedullary ratio are normal. No calculus seen.

Urinary bladder is normal in shape & contour. Its wall is normal. Both V.U.J. are clear.

Uterus is anteverted, appears normal in size (**measures 8.5x3.8x4.2CM**) and shape. Myometrial echotexture appears normal. No focal lesion seen. Cervix appears normal.

Endometrium is thin echogenic.

Both ovaries are normal in size, shape & echotexture. Bilateral ovaries are showing dominant follicle.

No adnexal mass or cyst is seen. No free fluid is seen in pouch of douglas.

IVC and abdominal aorta are normal in caliber .No evidence of intra abdominal lymphadenopathy. No evidence of ascites is seen.

The visualised bowel loops appears to be normal.

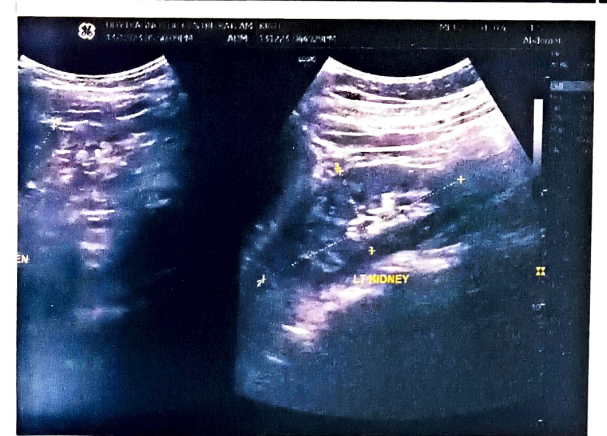
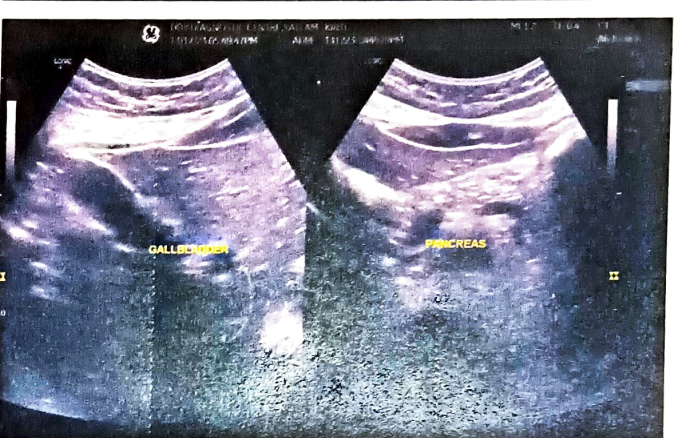
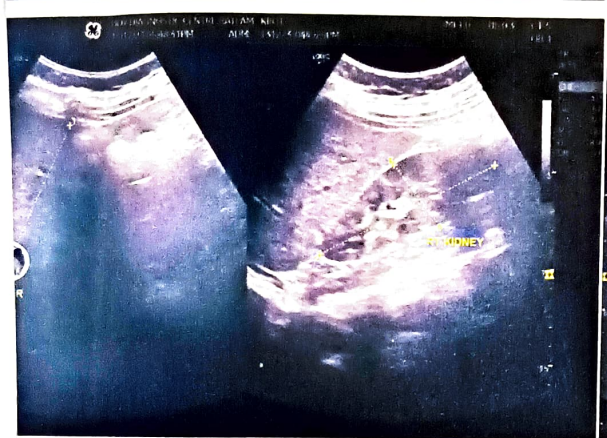
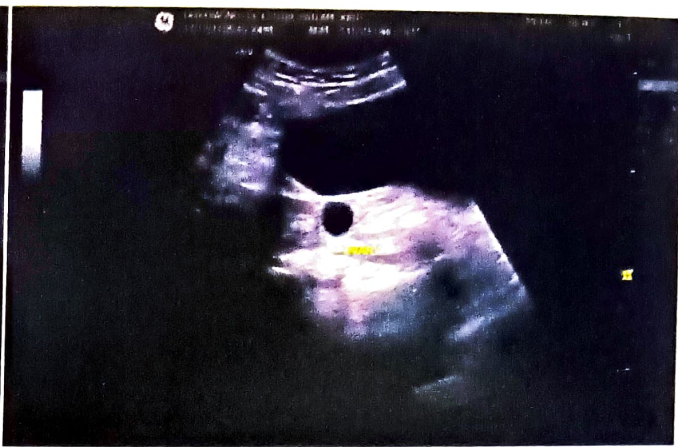
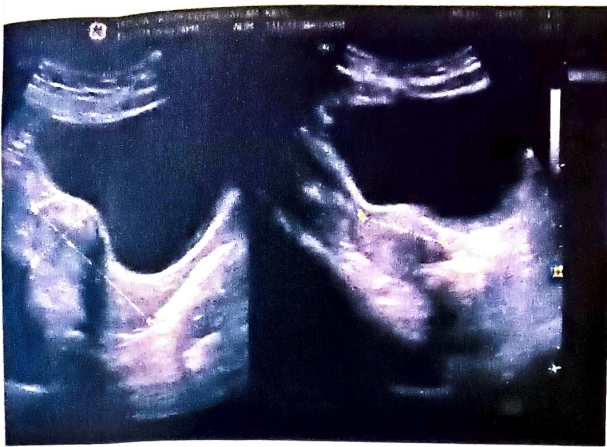
IMPRESSION: Ultrasound whole abdomen study shows:

No significant abnormality seen in present scan.

DR ANU GRAH PATERIA
(Radiologist)

It is a professional opinion, not valid for medico legal purpose.

DDY DIAGNOSTIC CENTRE, RATLAM.





GD Hospital

गीतादेवी हॉस्पिटल

Hospital Reg. No. NH/1985/JUN-2016



info@gdhospitals.com
www.gdhospitals.com



+91-97524 50505
+91-91110 13321



80 Feet Road, Ratnapuri,
Ratlam (M.P.) 457001

Date :

23/11/2023

Patient Name:- : Kirti Garg 39year female

X-RAY-CHEST (PA VIEW)

FINDINGS:-

Bilateral lung fields are normal,

The pleural spaces are normal.

Both hila are normal in size have equal density and bear normal relations

The heart and trachea are central in position and no mediastinal abnormal


No mediastinal abnormality visible

The cardiac size is normal.

The domes of diaphragm are normal in position and show smooth outline.

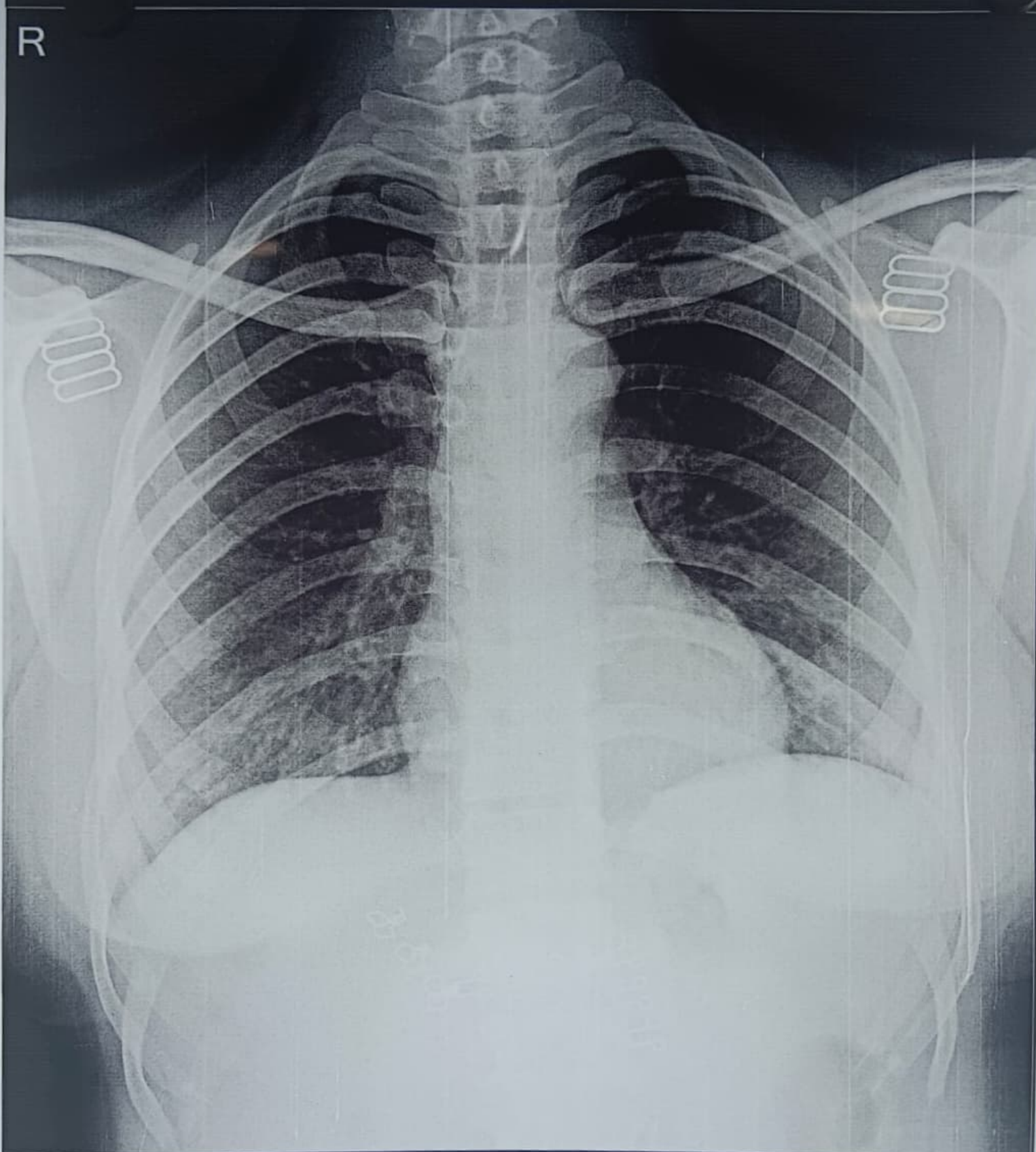
IMPRESSION:-

No significant abnormality seen


DR. ANUGRAH PATERIA
MBBS, MD

Consultant Radiologist.

R



MRS KIRTI GARG 39Y 23-10294 CHEST PA 23/11/2023
GD HOSPITAL 80FEET ROAD RATNPURI, RATLAM PH:9111013321

ID :

10 mm/mV 25 mm/S

Name :

Age : Years

Gender :

BP : (mmHg)

Weight: Kgs

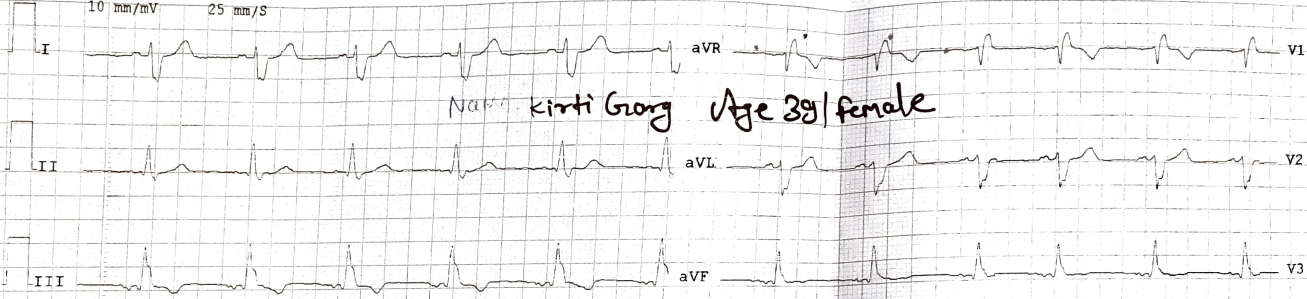
Date : 23/11/23
02:41 PM

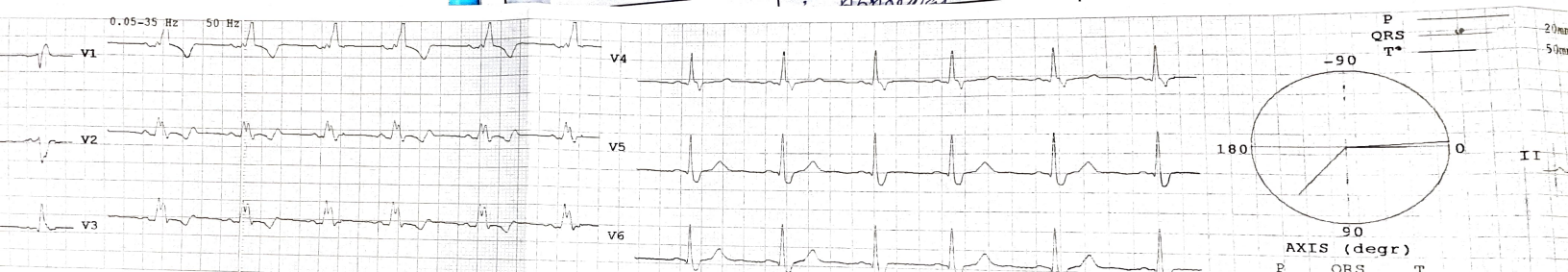
Note :

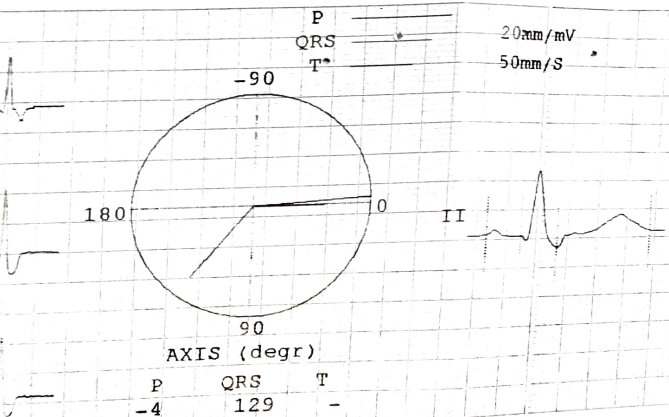
VESTA 301i
(Ver 3.15.33)

www.rmsindia.com

Name: Kirti Garg Age 39 / female







Parameters

HR	: 68	BPM
QRS DUR	: 116	mS
QT INT	: 434	mS
QTc INT	: 462	mS
PR INT	: 112	mS
RR INT	: 882	mS
QT/QTc	: 93	%
QT/RR	: 49	%
RV5/SV1	: 0.91/0.68	mV

Adult Interpretation Report:

Right Axis Deviation
 Right ventricular Hypertrophy
 Borderline Conditions in:
 - PR Interval

Abnormal ECG

Note: Results may be clinically correlated

Dr.

Arrow CC



GD Hospital

गीतादेवी हॉस्पिटल

Hospital Reg. No. NH/1985/JUN-2016



info@gdhospitals.com
www.gdhospitals.com



+91-97524 50505
+91-91110 13321



80 Feet Road, Ratnapuri,
Ratlam (M.P.) 457001

10/12/2023

Date :

ECHO REPORT

Name : Mrs. KIRTI GARG AGE 39Y SEX - FEMALE

-All cardiac chambers are normal in size.

-All cardiac valves are normal.

-Aortic root & PA are normal.

-No RWMA.

-Normal LV systolic function (LVEF 62%)

-IAS & IVS are intact.

-Pericardium is normal.

-No clot /Thrombus / Vegetation.

DOPPLER:

-No significant gradient across all valves .

-Normal flow across all valves.

IMPRESSION

-No RWMA

-Normal LV systolic function

-LVEF 62%


DR. BHARAT KUMRAWAT
MD MEDICINE

Name : Mrs. KIRTI GARG	UHID.No : 23-10292	IPD/OPD : OPD
Age/Sex : 39 Y / F	Accession No. : 20231123030	Category : MEDIWHEEL
Consultant : DEVENDRA VAISHNAV	Bill / IPD No. : 23-31581	


Registration No


Accession No

HAEMATOLOGY REPORT

Sample Collected: 23-Nov-2023 2:27 PM

Sample Type: EDTA BLOOD

Test Name	Results	Unit	Biological Reference Range
Haemoglobin	13.2	gm/dl	12-16
Total Red Blood Count	4.94	Millions/cumm	3.5-5.5
Haematocrite	40.4	%	36.0-51.0
MCV	81.78	fl	77-95
MCH	26.72	pg	26-32
MCHC	32.67	g/dl	30-36
Total Leukocyte Count	8400	cells/cumm	4,000-11,000
Neutrophils	67	%	40-70
Lymphocytes	28	%	20-45
Eosinophils	01	%	2.0-6.0
Monocytes	04	%	2.0-8.0
Basophils	00	%	0-0.1%
Platelet	2.13	lakhs/cmm	1.5-4.5
Erythrocyte Sedimentation Rate			
ESR	18	mm	0-20
BLOOD GROUP			
ABO	A		
Rh TYPE	POSITIVE		

Remarks :

DR. LEKHRAJ PATIDAR

• Home Collection Facility Available •

Note : Diagnostic test have technical limitation. | For technical disparity repeated examination are required.
 No legal liability is accepted. | Clinical correlation is requested. This test is not valid for medico-legal purpose.

sensitivity
the laboratory
p in arriving at

GD Pathology

जी.डी. पथोलॉजी

Reg. No. CL/1058/AUG-2020



✉ gdpathologylab@gmail.com
🌐 www.gdhospitals.com
📍 80 Feet Road, Ratnapuri, Ratlam (M.P.)
☎ 97524-50505, 91110-13321

Name : Mrs. KIRTI GARG	UHID.No : 23-10292	IPD/OPD: OPD
Age/Sex : 39 Y / F	Accession No. : 20231123030	Category : MEDIWHEEL
Consultant : DEVENDRA VAISHNAV	Bill / IPD No. : 23-31581	



Registration No



Accession No

BIOCHEMISTRY

Sample Collected: 23-Nov-2023 2:27 PM

Sample Type: SERUM

Test Name	Results	Unit	Biological Reference Range
LIPID PROFILE.			
TOTAL CHOLESTROL	215.9	mg/dl	0-200
TRIGLYCERIDES.	134.5	mg/dl	0-150
CHOLESTEROL HDL	56.03	mg/dl	35-85
CHOLESTEROL LDL	132.97	mg/dl	0-130
CHOLESTEROL VLDL	26.90	mg/dl	10-30
TOTAL CHOLESTEROL HDL RATIO	3.85	%	3-4.4
CHOLESTEROL LDL CHOLESTEROL HDL RATIO	2.37	%	0.1-3.0
LIVER FUNCTION TEST (LFT)			
Serum Bilirubin (Total)	0.72	mg/dl	0.1-1.0
Serum Bilirubin (Direct)	0.39	mg/dl	0.0-0.2
Serum Bilirubin (Indirect)	0.33	mg/dl	0.0-0.8
SGOT (AST)	19.71	U/L	9-40
SGPT (ALT)	21.83	U/L	9-40
Alkaline Phosphatase	189.2	U/L	100-250
Total Protein	6.89	g/dL	6.3-8.2
Albumin	3.72	g/dl	3.5-5.0
Globulin	3.17	g/dl	0-5
Albumin Globulin Ratio	1.17	Ratio	1.0-2.3
BLOOD SUGAR (FASTING)	108.4	mg/dl	70 - 110
BLOOD UREA NITROGEN	13.60	mg/dl	5-25
Serum Creatinine	0.79	mg/dl	0.70-1.40
Uric Acid	4.20	mg/dl	2.0-7.0

Remarks :

DR. LEKHRAJ PATIDAR

• Home Collection Facility Available •

Note : Diagnostic test have technical limitation. | For technical disparity repeated examination are required.
No legal liability is accepted. | Clinical correlation is requested. This test is not valid for medico-legal purpose.

GD Pathology

जी.डी. पेथोलॉजी

Reg. No. CL/1058/AUG-2020



gdpathologylab@gmail.com
www.gdhospitals.com
80 Feet Road, Ratnapuri, Ratlam (M.P.)
97524-50505, 91110-13321

Name :Mrs. KIRTI GARG	UHID. No. :23-10292	IPD/OPD Status :OPD
Age/Sex :39 Y/Female	Lab No. :20231123030	consultant :Dr.DEVENDRA VAISHNAV
Ref. Dr.	Receipt no : 23-31581	Location/Bed.No ;

Collected at:23/11/2023 14:27:00

Report Gen at:



BIOCHEMISTRY



Registration No

Accession No

SAMPLE TYPE : EDTA BLOOD

Investigations	Result	Unit	Biological Reference Interval
HbA1C (GLYCOSYLATED Hb)	5.80	%	4.0- 6.0 %

HbA1C

HbA1C

4.0-6.0%

Good control 6-7%

Fair control 7-8%

Poor control >8%

Estimated Blood Glucose (ABG)

97-126 mg/dl

126-154 mg/dl

154-183 mg/dl

183 mg/dl

TECHNOLOGIST

• Home Collection Facility Available •

Dr. LEKHRAJ PATIDAR

Note : Diagnostic test have technical limitation. | For technical disparity repeated examination are required.
No legal liability is accepted. | Clinical correlation is requested. This test is not valid for medico-legal purpose.

GD Pathology

जी.डी. पथोलॉजी

Reg. No. CL/1058/AUG-2020



PESHCO 2020 - 2960

gdpathologylab@gmail.com

www.gdhospitals.com

80 Feet Road, Ratnapuri, Ratlam (M.P.)

97524-50505, 91110-13321

Name : Mrs. KIRTI GARG	UHID. No. : 23-10292	IPD/OPD Status : OPD
Age/Sex : 39 Y/Female	Lab No. : 20231123030	consultant : Dr.DEVENDRA VAISHNAV
Ref. Dr.	Receipt no : 23-31581	Location/Bed.No : ,

Collected at: 23/11/2023 14:27:00

Report Gen at:



HAEMATOLOGY REPORT



Registration No

Accession No

SAMPLE TYPE : SERUM

Investigations	Result	Unit	Biological Reference Interval
T3 (Total Triiodothyronine)	3.05	nmol/L	1.23-3.07
T4 (Total Thyroxine)	170.9	nmol/L	66-181
TSH (Thyroid Stimulating Hormone)	0.20	mIU/L	0.30-4.2

TECHNOLOGIST

• Home Collection Facility Available •

Dr. LEKHRAJ PATIDAR

Note : Diagnostic test have technical limitation. | For technical disparity repeated examination are required.
No legal liability is accepted. | Clinical correlation is requested. This test is not valid for medico-legal purpose.

GD Pathology

जी.डी. पथोलॉजी

Reg. No. CL/1058/AUG-2020



✉ gopathologylab@gmail.com
🌐 www.gdhospitals.com
📍 80 Feet Road, Ratnapuri, Rattlam (M.P.)
☎ 97524-50505, 91110-13321

Name : Mrs. KIRTI GARG	UHID. No. : 23-10292	IPD/OPD Status : OPD
Age/Sex : 39 Y/Female	Lab No. : 20231123030	consultant : Dr. DEVENDRA VAISHNAV
Ref. Dr.	Receipt no : 23-31581	Location/Bed.No :

Collected at: 23/11/2023 14:27:00

Report Gen at:



CLINICAL PATHOLOGY



Accession No

Registration No

SAMPLE TYPE : URINE,

Investigations	Result	Unit	Biological Reference Interval
PHYSICAL EXAMINATION.			
QUANTITY	25ML		
COLOUR.	PALE YELLOW	-	-
APPEARANCE	CLEAR	-	-
PH	ACIDIC		
SPECIFIC GRAVITY	1.015		
CHEMICAL EXAMINATION.			
Urine Sugar	NIL	-	NIL
Urine Albumin	NIL		
BS/BP	ABSENT		ABSENT
KETONE.	ABSENT		ABSENT
MICROSCOPIC EXAMINATION.			
PUS CELLS	2-4	/hpf	0-4
EPITHELIAL CELLS	1-3	/HPF	0-2
RBC,	NIL	/HPF	0-2
CASTS	ABSENT	-	-
CRYSTALS	ABSENT	/HPF	-
BACTERIA	ABSENT		
YEAST	ABSENT		

TECHNOLOGIST

• Home Collection Facility Available •

Dr. LEKHRAJ PATIDAR

Note : Diagnostic test have technical limitation. | For technical disparity repeated examination are required.
No legal liability is accepted. | Clinical correlation is requested. This test is not valid for medico-legal purpose.



**Arihant
Pathology Laboratory**



Scan QR code to check
report authenticity



MC-2202

**sterling
ACCURIS**
Pathology lab that cares

Passport No :

LABORATORY TEST REPORT



Patient Information	Sample Information	Client/Location Information
Name : Ms Kirti Garg	Lab Id : 112312501084	Client Name : G Y Foundation@Ratlam
Sex/Age : Female / 39 Y	Registration on : 23-Nov-2023 17:47	Location :
Ref. Id :	Collected at : non SAWPL	Approved on : 24-Nov-2023 12:37 Status : Final
Ref. By : Dr Devendra Vaishnav	Collected on : 23-Nov-2023 17:47	Printed On : 24-Nov-2023 12:37
	Sample Type : Serum	Process At : 1. NRL SAWPL Gujarat Ahmedabad Paldi

Biochemistry

Test	Result	Unit	Biological Ref. Interval
GGT <small>L-y-Glytamyl-p-nitroanilide</small>	26.0	U/L	12 - 43

----- End Of Report -----

Dr. Purvish Darji

Dr. Purvish Darji
MD(Path)

Dr. Sanjeev Shah
MD Path

Dr.Yash Shah
MD Path



Sterling Accuris Pathology Laboratory

Laboratory: (Arihant Pathology Laboratory), 15, Ved Vyas Colony, Ratlam, Madhya Pradesh - 457001
Ph.: 07412-297458

info.ratlam@sterlingaccuris.com | Website: www.sterlingaccuris.com | Follow us on:

This is an Electronically Authenticated Report.

Tests marked with # are referred tests

Page 1 of 1



Download Accuris App