

PT. Name : MR..VIRENDRA GOUR Date : 23-11-2023  
F/H Name : RAM MANOHAR GOUR OPD NO : 3  
Age / Gender : 40 Y / M  
UHID No : 23-10280 Mobile No : 8238096941  
Consultant : DEVENDRA VAISHNAV Fees : 0.00  
Department : ANESTHESIOLOGY Bill No : 23-31484  
Doctor Reg No : MP-10124  
Address : ,ALKAPURI ,RATLAM

1. Height	2. Weight	3. BMI	4. Build	5. Pulse Rate/min	6. Blood Pressure
Cms	Kgs		Normal	88/m SpO2 - 98%	110/70
			Under weight <input checked="" type="checkbox"/>	7. Respiratory Rate/min	22/m
			Over weight		
8. Visual Acuity Whether he/she falls in the category of visually impaired					
Eye	Vision			9. Dental /Oral Hygiene	
Right	6/5			WNL	
Left	6/5 as ab.				

Rx

α-Ray → Done  
Bloodtest - Done Urine - Done  
ECG - Done  
No pt may not any fresh cell  
stroke on vitals -  
BP - 120/80 mm Hg SpO2 - 95% T - 37°C  
CNS - Conscious, oriented, no focal signs  
RT - RTA (R) RT - soft  
NO NO - chronic illness  
CXR - NAD - ECG - NAD  
SPEECH - NAD

Sample Done

**GD HOSPITAL**  
80, Feet Road, Ratnapuri, Ratlam  
Reg.-NH1985/JUN/2016  
Rohini ID-8900080354630

10. Conclusion:	
11. Recommendations:	Tests <span style="float: right;">Diet</span>

Name : MR. VIRENDRA GOUR	UHID.No : 23-10280	IPD/OPD: OPD
Age/Sex : 40 Y / M	Accession No. : 20231123021	Category : MEDIWHEEL
Consultant : DEVENDRA VAISHNAV	Bill / IPD No. : 23-31563	



Registration No



Accession No

## HAEMATOLOGY REPORT

Sample Collected: 23-Nov-2023 4:04 PM

Sample Type: EDTA BLOOD

Test Name	Results	Unit	Biological Reference Range
Haemoglobin	15.0	gm/dl	12-16
Total Red Blood Count	4.66	Millions/cumm	3.5-5.5
Haematocrite	43.8	%	36.0-51.0
MCV	93.99	fl	77-95
MCH	32.19	pg	26-32
MCHC	34.25	g/dl	30-36
Total Leukocyte Count	8300	cells/cumm	4,000-11,000
Neutrophils	60	%	40-70
Lymphocytes	34	%	20-45
Eosinophils	02	%	2.0-6.0
Monocytes	04	%	2.0-8.0
Basophils	00	%	0-0.1%
Platelet	3.06	lakhs/cmm	1.5-4.5
Erythrocyte Sedimentation Rate			
ESR	14	mm	0-9
BLOOD GROUP			
ABO	A		
Rh TYPE	POSITIVE		

Remarks :

  
DR. LEKHRAJ PATIDAR

• Home Collection Facility Available •

Note : Diagnostic test have technical limitation. | For technical disparity repeated examination are required.  
No legal liability is accepted. | Clinical correlation is requested. This test is not valid for medico-legal purpose.

Name : MR. VIRENDRA GOUR	UHID.No : 23-10280	IPD/OPD: OPD
Age/Sex : 40 Y / M	Accession No. : 20231123021	Category : MEDIWHEEL
Consultant : DEVENDRA VAISHNAV	Bill / IPD No. : 23-31563	



Registration No



Accession No

### BIOCHEMISTRY

Sample Collected: 23-Nov-2023 4:04 PM

Sample Type: SERUM

Test Name	Results	Unit	Biological Reference Range
<b>LIPID PROFILE.</b>			
TOTAL CHOLESTROL	139.8	mg/dl	0-200
TRIGLYCERIDES.	107.9	mg/dl	0-150
CHOLESTEROL HDL	49.50	mg/dl	35-85
CHOLESTEROL LDL	68.72	mg/dl	0-130
CHOLESTEROL VLDL	21.58	mg/dl	10-30
TOTAL CHOLESTEROL HDL RATIO	2.82	%	3-4.4
CHOLESTEROL LDL CHOLESTEROL HDL RATIO	1.39	%	0.1-3.0
<b>LIVER FUNCTION TEST (LFT)</b>			
Serum Bilirubin (Total)	0.79	mg/dl	0.1-1.0
Serum Bilirubin (Direct)	0.36	mg/dl	0.0-0.2
Serum Bilirubin (Indirect)	0.43	mg/dl	0.0-0.8
SGOT (AST)	15.98	U/L	9-40
SGPT (ALT)	18.23	U/L	9-40
Alkaline Phosphatase	145.6	U/L	100-250
Total Protein	7.34	g/dL	6.3-8.2
Albumin	4.26	g/dl	3.5-5.0
Globulin	3.08	g/dl	0-5
Albumin Globulin Ratio	1.38	Ratio	1.0-2.3
BLOOD SUGAR (FASTING)	106.8	mg/dl	70 - 110
BLOOD UREA NITROGEN	15.60	mg/dl	5-25
Serum Creatinine	0.79	mg/dl	0.70-1.40
Uric Acid	4.89	mg/dl	2.0-7.0

Remarks :



DR. LEKHRAJ PATIDAR

• Home Collection Facility Available •

Note : Diagnostic test have technical limitation. | For technical disparity repeated examination are required.  
No legal liability is accepted. | Clinical correlation is requested. This test is not valid for medico-legal purpose.

of sensitivity care  
by the laboratory.

# GD Pathology

## जी.डी. पथोलॉजी

Reg. No. CL/1058/AUG-2020



gdpathologylab@gmail.com  
www.gdhospitals.com  
80 Feet Road, Ratnapuri, Ratlam (M.P.)  
97524-50505, 91110-13321

Name :MR. VIRENDRA GOUR	UHID. No. :23-10280	IPD/OPD Status :OPD
Age/Sex :40 Y/Male	Lab No. :20231123021	consultant :Dr.DEVENDRA VAISHNAV
Ref. Dr.	Receipt no : 23-31563	Location/Bed.No ;,

Collected at:23/11/2023 16:04:00

Report Gen at:



### HAEMATOLOGY REPORT



Accession No

Registration No

SAMPLE TYPE : SERUM

Investigations	Result	Unit	Biological Reference Interval
T3 (Total Triiodothyronine)	2.64	nmol/L	1.23-3.07
T4 (Total Thyroxine)	177.4	nmol/L	66-181
TSH (Thyroid Stimulating Hormone)	3.56	mIU/L	0.30-4.2

TECHNOLOGIST

• Home Collection Facility Available •

Dr. LEKRAJ PATIDAR

Note : Diagnostic test have technical limitation. | For technical disparity repeated examination are required.  
No legal liability is accepted. | Clinical correlation is requested. This test is not valid for medico-legal purpose.

# GD Pathology

## जी.डी. पथोलॉजी

Reg. No. CL/1058/AUG-2020



- gdpathologylab@gmail.com
- www.gdhospitals.com
- 80 Feet Road, Ratnapuri, Ratlam (M.P.)
- 97524-50505, 91110-13321

Name :MR. VIRENDRA GOUR	UHID. No. :23-10280	IPD/OPD Status :OPD
Age/Sex :40 Y/Male	Lab No. :20231123021	consultant :Dr.DEVENDRA VAISHNAV
Ref. Dr.	Receipt no : 23-31563	Location/Bed.No : ,

Collected at:23/11/2023 16:04:00

Report Gen at:



### BIOCHEMISTRY



Accession No

Registration No

SAMPLE TYPE : EDTA BLOOD

Investigations	Result	Unit	Biological Reference Interval
HbA1C (GLYCOSYLATED Hb )	5.80	%	4.0- 6.0 %

#### HbA1C

HbA1C

4.0-6.0%

Good control 6-7%

Fair control 7-8%

Poor control >8%

#### Estimated Blood Glucose (ABG)

97-126 mg/dl

126-154 mg/dl

154-183 mg/dl

183 mg/dl

TECHNOLOGIST

• Home Collection Facility Available •

Dr. LEKHRAJ PATIDAR

Note : Diagnostic test have technical limitation. | For technical disparity repeated examination are required.  
No legal liability is accepted. | Clinical correlation is requested. This test is not valid for medico-legal purpose.

<b>Name</b> : MR. VIRENDRA GOUR	<b>UHID.No</b> : 23-10280	<b>IPD/OPD:</b> OPD
<b>Age/Sex</b> : 40 Y / M	<b>Accession No.</b> : 20231123021	<b>Category</b> : MEDIWHEEL
<b>Consultant</b> : DEVENDRA VAISHNAV	<b>Bill / IPD No.</b> : 23-31563	



**Registration No**



**Accession No**

**CLINICAL PATHOLOGY**

Sample Collected: 23-Nov-2023 4:04 PM

Sample Type: URINE,

Test Name	Results	Unit	Biological Reference Range
<b>PHYSICAL EXAMINATION.</b>			
QUANTITY	25ML		
COLOUR.	PALE YELLOW	-	-
APPEARANCE	CLEAR	-	-
PH	ACIDIC		
SPECIFIC GRAVITY	1.015		
<b>CHEMICAL EXAMINATION.</b>			
Urine Sugar	NIL	-	NIL
Urine Albumin	NIL		
BS/BP	ABSENT		ABSENT
KETONE.	ABSENT		ABSENT
<b>MICROSCOPIC EXAMINATION.</b>			
PUS CELLS	2-4	/hpf	0-4
EPITHELIAL CELLS	1-2	/HPF	0-2
RBC,	NIL	/HPF	0-2
CASTS	ABSENT	-	-
CRYSTALS	ABSENT	/HPF	-
BACTERIA	ABSENT		
YEAST	ABSENT		

Remarks :

  
**DR. LEKHRAJ PATIDAR**

• Home Collection Facility Available •

Note : Diagnostic test have technical limitation. | For technical disparity repeated examination are required.  
 No legal liability is accepted. | Clinical correlation is requested. This test is not valid for medico-legal purpose.



**Arihant  
Pathology Laboratory**



Scan QR code to check  
report authenticity

**sterling  
ACCURIS**  
Pathology lab that cares

Passport No :

**LABORATORY TEST REPORT**



Patient Information	Sample Information	Client/Location Information
Name : Mr Virendra Gaur	Lab Id : 112312501076	Client Name : G Y Foundation@Ratlam
Sex/Age : Male / 40 Y	Registration on : 23-Nov-2023 17:43	Location :
Ref. Id :	Collected at : non SAWPL	Approved on : 24-Nov-2023 12:38 Status : Final
Ref. By : Dr Devendra Vaishnav	Collected on : 23-Nov-2023 17:43	Printed On : 24-Nov-2023 13:06
	Sample Type : Serum	Process At : 1. NRL SAWPL Gujarat Ahmedabad Pakdi

**Biochemistry**

Test	Result	Unit	Biological Ref. Interval
GGT <i>L-glytamyl-p-nitroanilide</i>	17.0	U/L	15 - 73

----- End Of Report -----

*Dr. Purvish Darji*

**Dr. Purvish Darji**  
MD(Path)

**Dr. Sanjeev Shah**  
MD Path

**Dr. Yash Shah**  
MD Path



**Sterling Accuris Pathology Laboratory**

Laboratory: (Arihant Pathology Laboratory), 15, Ved Vyas Colony, Ratlam, Madhya Pradesh - 457001

Ph.: 07412-297458

info.ratlam@sterlingaccuris.com | Website: www.sterlingaccuris.com | Follow us on:



This is an Electronically Authenticated Report.

tests marked with # are referred tests

Page 1 of 1



Download Accuris App



# GD Hospital

## गीतादेवी हॉस्पिटल

Hospital Reg. No. NH/1985/JUN-2016



info@gdhospitals.com  
www.gdhospitals.com



+91-97524 50505  
+91-91110 13321



80 Feet Road, Ratnapuri,  
Ratlam (M.P.) 457001

Date : .....

23/11/2023

Patient Name:- : Virendra Gour Age 40 year male

### X-RAY-CHEST (PA VIEW)

#### FINDINGS:-

**Bilateral lung fields are normal,**

The pleural spaces are normal.

Both hila are normal in size have equal density and bear normal relations

The heart and trachea are central in position and no mediastinal abnormal

No mediastinal abnormality visible

The cardiac size is normal.

The domes of diaphragm are normal in position and show smooth outline.

#### IMPRESSION:-

No significant abnormality seen

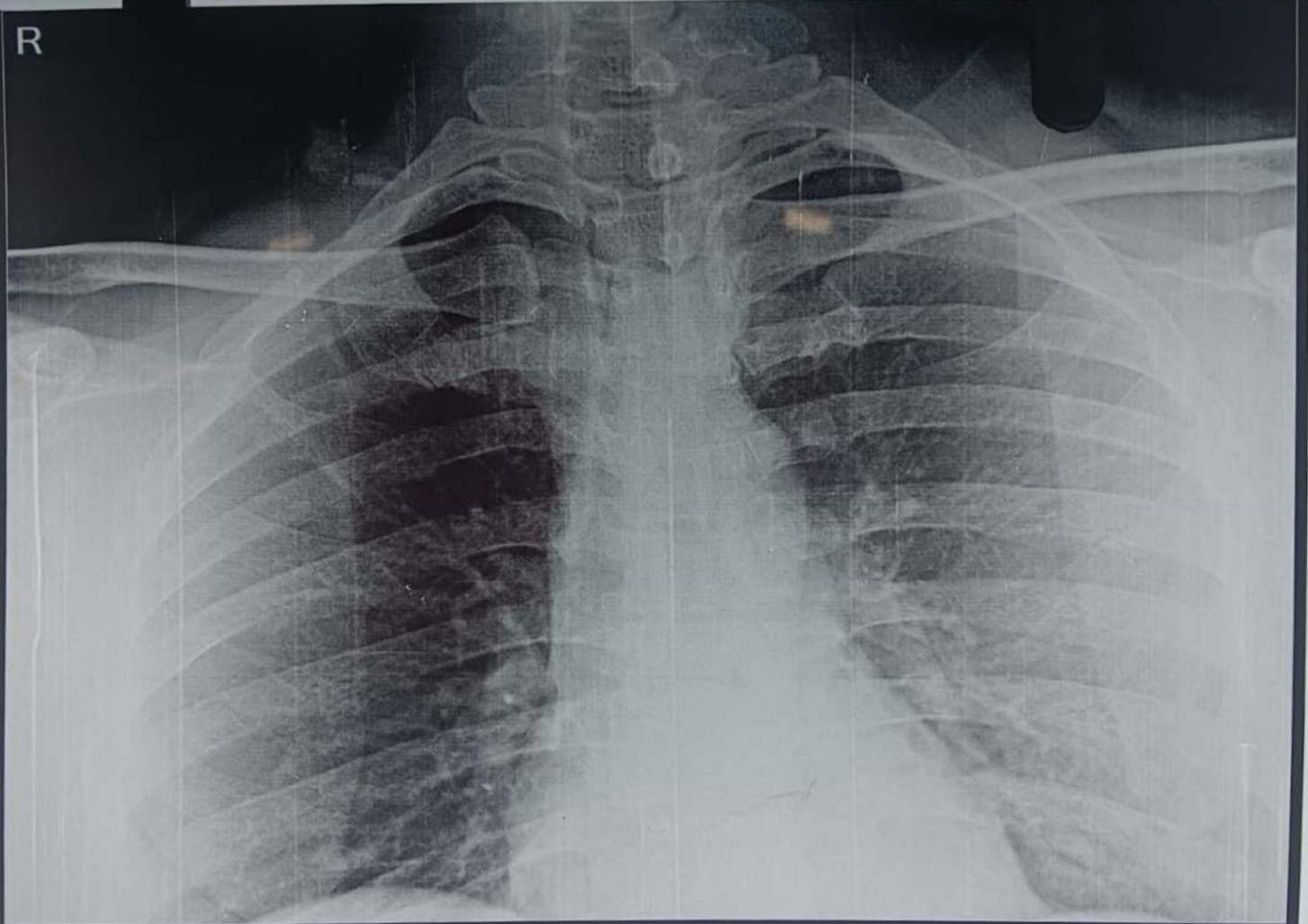
  
DR. ANUGRAH PATERIA

MBBS, MD

Consultant Radiologist.



R



MR VIRENDRA GOUR 40Y 23-10280 CHEST PA 23/11/2023  
GD HOSPITAL 80FEET ROAD RATNPURI, RATLAM PH:9111013321

ID :  
Name :  
Age : Years  
Gender :


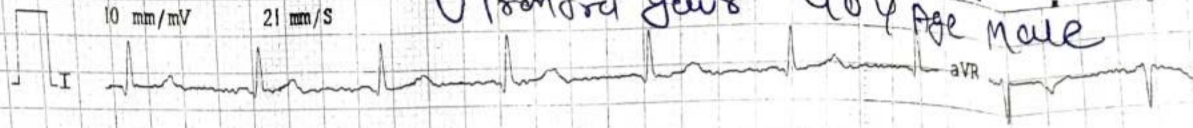
BP :  
(mmHg)  
Weight: Kgs

Date : 23/11/23  
12:10 PM  
Note :

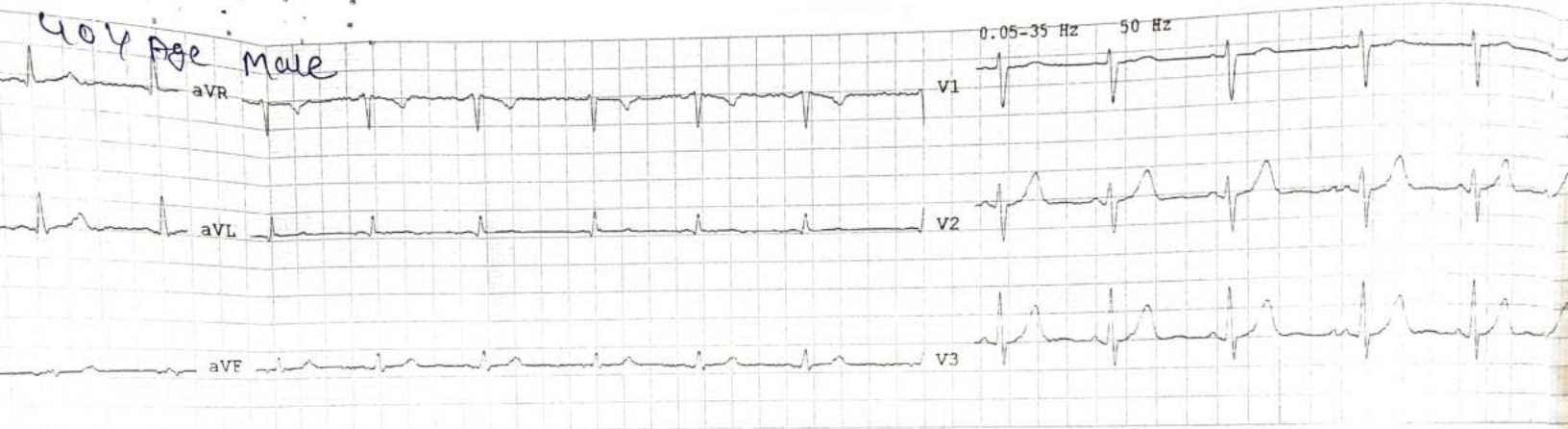VESTA 3011  
(Ver 3.15.33)  
www.rmsindia.com

10 mm/mV 21 mm/S

Vishendra gears 40 Y Age Male



40 Y Age Male



0.05-35 Hz 50 Hz

aVR

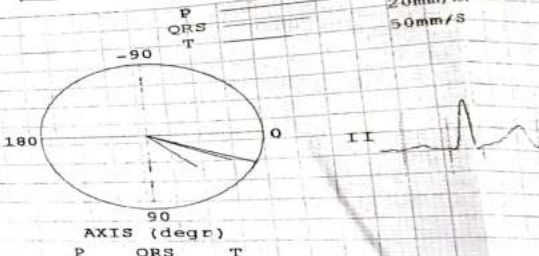
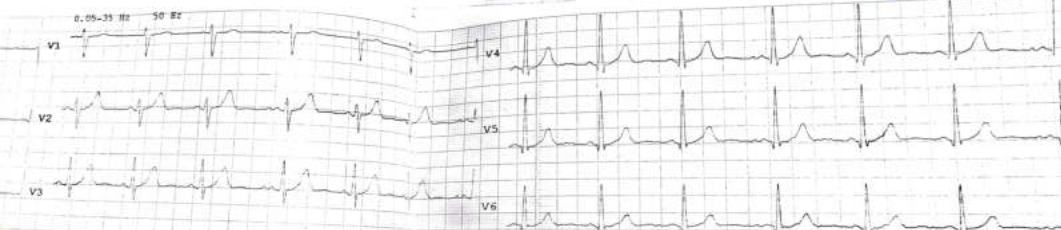
V1

aVL

V2

aVF

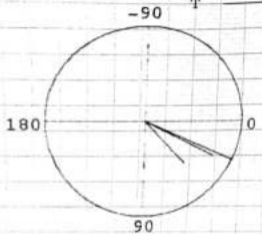
V3



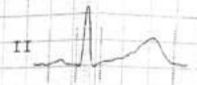50mm/S

P  
QRS  
T

20mm/mV  
50mm/S



P	QRS	T
23	26	46



Parameters	
HR	: 77 BPM
QRS DUR	: 95 ms
QT INT	: 372 ms
QTc INT	: 422 ms
PR INT	: 122 ms
RR INT	: 779 ms
QT/QTc	: 88 %
QT/RR	: 47 %
RV5/SV1	: 1.38/0.62 mV

Adult Interpretation Report:  
Sinus Rhythm  
Normal Sinus Rhythm ECG

(Physician Comments)

Dr.

Note: Results may be clinically correlated



Date 23/11/2023.....

**ECHO REPORT**

Name:- : MR. VIRENDRA GOUR AGE 40 Y SEX - MALE

-All cardiac chambers are normal in size.

-All cardiac valves are normal.

-Aortic root & PA are normal.

-No RWMA.

-Normal LV systolic function (LVEF 58%)

-IAS & IVS are intact.

-Pericardium is normal.

-No clot /Thrombus / Vegetation.

**DOPPLER:**

-No significant gradient across all valves .

-Normal flow across all valves.

**IMPRESSION**

-No RWMA

-Normal LV systolic function

-LVEF 58%

  
DR. BHARAT KUMRAWAT

MD MEDICINE

<b>PT NAME</b>	<b>MR. VIRENDRA GOUR</b>	<b>AGE /SEX/</b>	<b>40YEAR / MALE</b>
<b>REF BY</b>	<b>DR. DEVENDRA VAISHNAV GD HOSPITAL, RATLAM</b>	<b>DATE</b>	<b>23/11/2023</b>

**ULTRASOUND WHOLE ABDOMEN**

**Liver** is normal in size (14.2cm) and shows raised echotexture. Hepatic venous system appear normal. No focal lesion is seen. Intra and extra hepatic biliary radicles are not dilated. Portal vein and CBD are normal in caliber.

**Gall bladder** is normal in size & shape. Its lumen is echofree and nonlithiastic.

**Pancreas** is normal in size outline & echo pattern.

**Spleen** is normal in size (11.9cm) and echo pattern.

**Right kidney** is normal in size (9.4x4.7cm), shape and echogenicity with smooth outline. Central pelvicalyceal sinus and corticomedullary ratio are normal. No calculus seen.

**Left kidney** is normal in size (10.6x4.3cm), shape and echogenicity with smooth outline. Central pelvicalyceal sinus and corticomedullary ratio are normal. No calculus seen.

**Urinary bladder** is normal in shape & contour. Its wall is normal. Both V.U.J. are clear.

**Prostate** is normal in size (3.3x3.2x3.0cm, 17.2cc), shape echotexture & contour. IVC and abdominal aorta are normal in calibre. No evidence of intra-abdominal lymphadenopathy. No evidence of ascites is seen.

**IMPRESSION:** Ultrasound whole abdomen study show:

➤ Grade I fatty liver.

Advice: Clinical correlation and further evaluation.

**DR ANURAH PATERIA**  
(Radiologist)

It is a professional opinion, not valid for medico legal purpose.

