

CP NSO 78981

PT. Name : MR..NITIN SOLANKI Date : 23-11-2023  
 F/H Name : GOPAL SOLANKI OPD NO : 4  
 Age / Gender : 40 Y / M  
 UHID No : 23-10281 Mobile No : 7772988588  
 Consultant : DEVENDRA VAISHNAV Fees : 0.00  
 Department : ANESTHESIOLOGY Bill No : 23-31485  
 Doctor Reg No : MP-10124  
 Address : ,27 VIDHIYA VIHAR COLONY,RATLAM

1. Height	2. Weight	3. BMI	4. Build	5. Pulse 52/min	6. Blood Pressure 120/80
Cms	Kgs		Normal	98/1	
172	76	25.7	Under weight		
			Over weight	7. Respiratory Rate/min	

8. Visual Acuity Whether he/she falls in the category of visually impaired

Eye	Vision	9. Dental /Oral Hygiene
Right	6/6.	
Left	6/6	

Rx  
 X-Ray → Done  
 blood sample - Done (uric acid)  
 ECG - Done  
 Eye Done  
 Absolute fit  
 → No - pt has no any medical complaints.  
 pt shows a vital sign  
 vitals - BP - 120/80 mm Hg, HR - 89/min, SpO2 - 96%, T - 37.5°C  
 S1 - clear, S2 - clear, no murmurs, no rales, no crackles.  
 RR - 18/min, PA - soft.  
 eye vision - clear, cornea - clear, pupil - normal, fundus - normal  
 same as done 10/10 - who has done

Sent to Done

10. Conclusion:	
11. Recommendations:	Tests Diet

NAME: Nitin Solanki Age 40 year/male

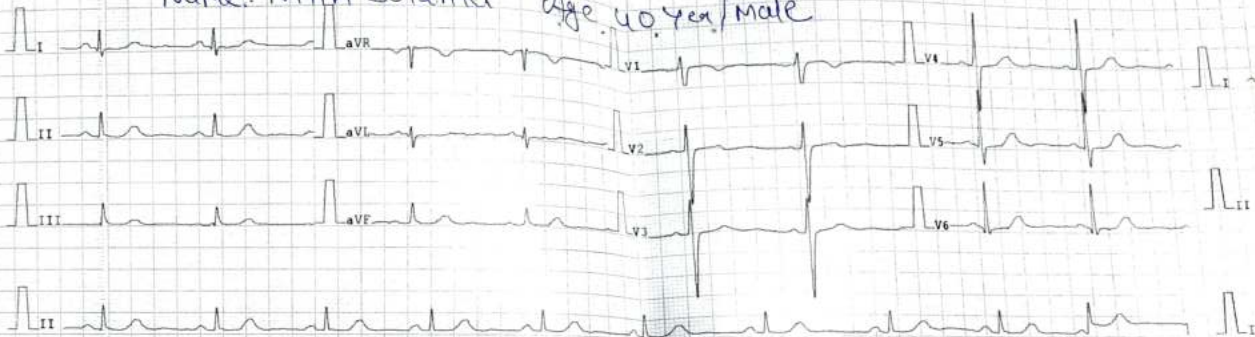PATIENT INFORMATION:-

ID:- 23 CASE:-  
NAME:-  
AGE:- GENDER:- SMOKER:-  
HEIGHT:- cms WEIGHT:- K9.  
DOCTOR:- DR BHARAT KUMRAWAT  
REF:-  
DATE/TIME:- 23/11/2023 08:08:33

ECG SETTINGS:-

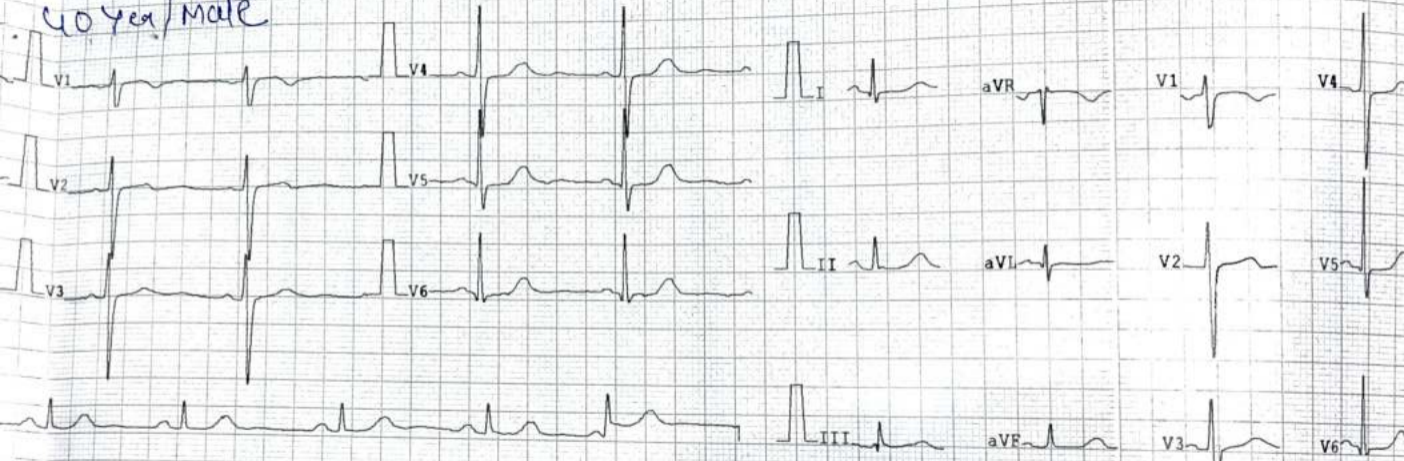PRINTING MODE:- AUTO 3+1  
GAIN (mm/mV):- 10  
SPEED (mm/Sec):- 25  
FILTER (Hz):- 0.05 - 35  
NOTCH/BLC:- ON/ON  
RHYTHM LEAD:- II

ALLENGERS PISCES 103 (VER:- 5.04 PH)



ARROW CE

40 Yea/Male



OBSERVATIONS :-

HEART RATE	58 bpm
R-R	1026 ms
P-R	134 ms
P-DUR	92 ms
QRS	92 ms
T-DUR	208 ms
ST DUR	136 ms
QT	436 ms
QTc	433 ms
P AXIS	49 °
R AXIS	73 °
T AXIS	62 °
ST AXIS	129 °

REMARKS :-

→ D&W

OBSERVATIONS

INTERPRETATION

HEART RATE 58 bpm  
R-R 1026 ms  
P-R 134 ms  
P DUR 92 ms  
QRS 92 ms  
T DUR 208ms  
ST DUR 136 ms  
QT 436 ms  
QTc 433 ms  
P AXIS 49 °  
R AXIS 73 °  
T AXIS 62 °  
ST AXIS 129 °

SINUS RHYTHM WITH ABERRANTLY CONDUCTED SUPRAVENTRICULAR COMPLEXES

*Handwritten signature*

REMARKS:



Date : .....

27/11/2023

## ECHO REPORT

Name:- : Nitin Solanki AGE 40 Y SEX - MALE

-All cardiac chambers are normal in size.

-All cardiac valves are normal.

-Aortic root & PA are normal.

-No RWMA.

-Normal LV systolic function (LVEF 62%)

-IAS & IVS are intact.

-Pericardium is normal.

-No clot /Thrombus / Vegetation.

### **DOPPLER:**

-No significant gradient across all valves .

-Normal flow across all valves.

### **IMPRESSION**

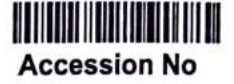-No RWMA

-Normal LV systolic function

-LVEF 62%

  
**DR. BHARAT KUMRAWAT**  
**MD MEDICINE**

Name : MR. NITIN SOLANKI	UHID.No : 23-10281	IPD/OPD: OPD
Age/Sex : 40 Y / M	Accession No. : 20231123022	Category : MEDIWHEEL
Consultant : DEVENDRA VAISHNAV	Bill / IPD No. : 23-31567	



## HAEMATOLOGY REPORT

Sample Collected: 23-Nov-2023 3:57 PM

Sample Type: EDTA BLOOD

Test Name	Results	Unit	Biological Reference Range
Haemoglobin	15.9	gm/dl	12-16
Total Red Blood Count	5.30	Millions/cumm	3.5-5.5
Haematocrite	47.4	%	36.0-51.0
MCV	89.43	fl	77-95
MCH	30.00	pg	26-32
MCHC	33.54	g/dl	30-36
Total Leukocyte Count	5300	cells/cumm	4,000-11,000
Neutrophils	58	%	40-70
Lymphocytes	34	%	20-45
Eosinophils	03	%	2.0-6.0
Monocytes	05	%	2.0-8.0
Basophils	00	%	0-0.1%
Platelet	2.66	lakhs/cmm	1.5-4.5
Erythrocyte Sedimentation Rate			
ESR	12	mm	0-9
BLOOD GROUP			
ABO	B		
Rh TYPE	POSITIVE		

Remarks :

DR. LEKHRAJ PATIDAR

• Home Collection Facility Available •

Note : Diagnostic test have technical limitation. | For technical disparity repeated examination are required.  
No legal liability is accepted. | Clinical correlation is requested. This test is not valid for medico-legal purpose.

Sensitivity and  
the laboratory  
at



# GD Pathology

## जी.डी. पथोलॉजी

Reg. No. CL/1058/AUG-2020



gdpathologylab@gmail.com  
www.gdhospitals.com  
80 Feet Road, Ratnapuri, Ratlam (M.P.)  
97524-50505, 91110-13321

Name : MR. NITIN SOLANKI	UHID.No : 23-10281	IPD/OPD: OPD
Age/Sex : 40 Y / M	Accession No. : 20231123022	Category : MEDIWHEEL
Consultant : DEVENDRA VAISHNAV	Bill / IPD No. : 23-31567	

Registration No

Accession No

### BIOCHEMISTRY

Sample Collected: 23-Nov-2023 3:57 PM

Sample Type: SERUM

Test Name	Results	Unit	Biological Reference Range
<b>LIPID PROFILE.</b>			
TOTAL CHOLESTROL	188.1	mg/dl	0-200
TRIGLYCERIDES.	132.4	mg/dl	0-150
CHOLESTEROL HDL	48.50	mg/dl	35-85
CHOLESTEROL LDL	113.12	mg/dl	0-130
CHOLESTEROL VLDL	26.48	mg/dl	10-30
TOTAL CHOLESTEROL HDL RATIO	3.88	%	3-4.4
CHOLESTEROL LDL CHOLESTEROL HDL RATIO	2.33	%	0.1-3.0
<b>LIVER FUNCTION TEST (LFT)</b>			
Serum Bilirubin (Total)	0.89	mg/dl	0.1-1.0
Serum Bilirubin (Direct)	0.42	mg/dl	0.0-0.2
Serum Bilirubin (Indirect)	0.47	mg/dl	0.0-0.8
SGOT (AST)	21.89	U/L	9-40
SGPT (ALT)	24.69	U/L	9-40
Alkaline Phosphatase	140.8	U/L	100-250
Total Protein	6.89	g/dL	6.3-8.2
Albumin	3.74	g/dl	3.5-5.0
Globulin	3.15	g/dl	0-5
Albumin Globulin Ratio	1.19	Ratio	1.0-2.3
BLOOD SUGAR (FASTING)	89.10	mg/dl	70 - 110
BLOOD UREA NITROGEN	12.60	mg/dl	5-25
Serum Creatinine	0.72	mg/dl	0.70-1.40
Uric Acid	3.92	mg/dl	2.0-7.0

Remarks :

DR. LEKHRAJ PATIDAR

• Home Collection Facility Available •

Note : Diagnostic test have technical limitation. | For technical disparity repeated examination are required.  
No legal liability is accepted. | Clinical correlation is requested. This test is not valid for medico-legal purpose.

...s of sensitivity  
...ved by the laboratory  
...only help in arriving at

# GD Pathology

## जी.डी. पथोलॉजी

Reg. No. CL/1058/AUG-2020



gdpathologylab@gmail.com  
www.gdhospitals.com  
80 Feet Road, Ratnapuri, Ratlam (M.P.)  
97524-50505, 91110-13321

Name :MR. NITIN SOLANKI	UHID. No. :23-10281	IPD/OPD Status :OPD
Age/Sex :40 Y/Male	Lab No. :20231123022	consultant :Dr.DEVENDRA VAISHNAV
Ref. Dr.	Receipt no : 23-31567	Location/Bed.No ;,

Collected at:23/11/2023 15:57:00

Report Gen at:



### BIOCHEMISTRY



Accession No

Registration No

SAMPLE TYPE : EDTA BLOOD

Investigations	Result	Unit	Biological Reference Interval
HbA1C (GLYCOSYLATED Hb )	5.98	%	4.0- 6.0 %

HbA1C

HbA1C

4.0-6.0%

Good control 6-7%

Fair control 7-8%

Poor control >8%

Estimated Blood Glucose (ABG)

97-126 mg/dl

126-154 mg/dl

154-183 mg/dl

183 mg/dl

TECHNOLOGIST

• Home Collection Facility Available •

Dr. LEKHRAJ PATIDAR

Note : Diagnostic test have technical limitation. | For technical disparity repeated examination are required.  
No legal liability is accepted. | Clinical correlation is requested. This test is not valid for medico-legal purpose.



# GD Pathology

## जी.डी. पेथोलॉजी


Reg. No. CL/1058/AUG-2020



gdpathologylab@gmail.com  
www.gdhospitals.com  
80 Feet Road, Ratnapuri, Ratlam (M.P.)  
97524-50505, 91110-13321

Name :MR. NITIN SOLANKI	UHID. No. :23-10281	IPD/OPD Status :OPD
Age/Sex :40 Y/Male	Lab No. :20231123022	consultant :Dr.DEVENDRA VAISHNAV
Ref. Dr.	Receipt no : 23-31567	Location/Bed.No :-

Collected at:23/11/2023 15:57:00



Accession No

### HAEMATOLOGY REPORT

Report Gen at:



Registration No

SAMPLE TYPE : SERUM

Investigations	Result	Unit	Biological Reference Interval
T3 (Total Triiodothyronine)	2.60	nmo/L	1.23-3.07
T4 (Total Thyroxine)	150.8	nmo/L	66-181
TSH (Thyroid Stimulating Hormone)	4.10	mIU/L	0.30-4.2

TECHNOLOGIST

• Home Collection Facility Available •

Dr. LEKHRAJ PATIDAR

Note : Diagnostic test have technical limitation. | For technical disparity repeated examination are required.  
No legal liability is accepted. | Clinical correlation is requested. This test is not valid for medico-legal purpose.

# GD Pathology

जी.डी. पेथोलॉजी

Reg. No. CL/1058/AUG-2020



gdpathologylab@gmail.com  
www.gdhospitals.com  
80 Feet Road, Ratnapuri, Ratlam (M.P.)  
97524-50505, 91110-13321

Name : MR. NITIN SOLANKI	UHID.No : 23-10281	IPD/OPD: OPD
Age/Sex : 40 Y / M	Accession No. : 20231123022	Category : MEDIWHEEL
Consultant : DEVENDRA VAISHNAV	Bill / IPD No. : 23-31567	



Registration No



Accession No

## CLINICAL PATHOLOGY

Sample Collected: 23-Nov-2023 3:57 PM

Sample Type: URINE,


Test Name	Results	Unit	Biological Reference Range
<b>PHYSICAL EXAMINATION.</b>			
QUANTITY	25ML		
COLOUR.	PALE YELLOW	-	-
APPEARANCE	CLEAR	-	-
PH	ACIDIC		
SPECIFIC GRAVITY	1.015		
<b>CHEMICAL EXAMINATION.</b>			
Urine Sugar	NIL	-	NIL
Urine Albumin	NIL		
BS/BP	ABSENT		ABSENT
KETONE.	ABSENT		ABSENT
<b>MICROSCOPIC EXAMINATION.</b>			
PUS CELLS	1-3	/hpf	0-4
EPITHELIAL CELLS	2-4	/HPF	0-2
RBC,	NIL	/HPF	0-2
CASTS	ABSENT	-	-
CRYSTALS	ABSENT	/HPF	-
BACTERIA	ABSENT		
YEAST	ABSENT		

Remarks :

DR. LEKHRA PATIDAR

• Home Collection Facility Available •

Note : Diagnostic test have technical limitation. | For technical disparity repeated examination are required.  
No legal liability is accepted. | Clinical correlation is requested. This test is not valid for medico-legal purpose.



Scan QR code to check report authenticity



MC-2202

Passport No :

**LABORATORY TEST REPORT**



Patient Information	Sample Information	Client/Location Information
Name : Mr Nitin	Lab Id : 112312501077	Client Name : G Y Foundation@Ratlam
Sex/Age : Male / 40 Y	Registration on : 23-Nov-2023 17:44	Location :
Ref. Id :	Collected at : non SAWPL	Approved on : 24-Nov-2023 12:47 Status : Final
Ref. By : Dr Devendra Vaishnav	Collected on : 23-Nov-2023 17:44	Printed On : 24-Nov-2023 12:48
	Sample Type : Serum	Process At : 1. NRL SAWPL Gujarat Ahmedabad Paidi

**Biochemistry**

Test	Result	Unit	Biological Ref. Interval
GGT <small>L-y-Glytamyl-p-nitroanilide</small>	23.0	U/L	15 - 73


----- End Of Report -----

*Dr. Purvish Darji*

**Dr. Purvish Darji**  
MD(Path)

**Dr. Sanjeev Shah**  
MD Path

**Dr. Yash Shah**  
MD Path





Date: 23/11/2023

Patient Name:- : Nitin solanki Age 40 year male

**X-RAY-CHEST (PA VIEW)**

**FINDINGS:-**

**Bilateral lung fields are normal,**

The pleural spaces are normal.

Both hila are normal in size have equal density and bear normal relations

The heart and trachea are central in position and no mediastinal abnormal

No mediastinal abnormality visible

The cardiac size is normal.

The domes of diaphragm are normal in position and show smooth outline.

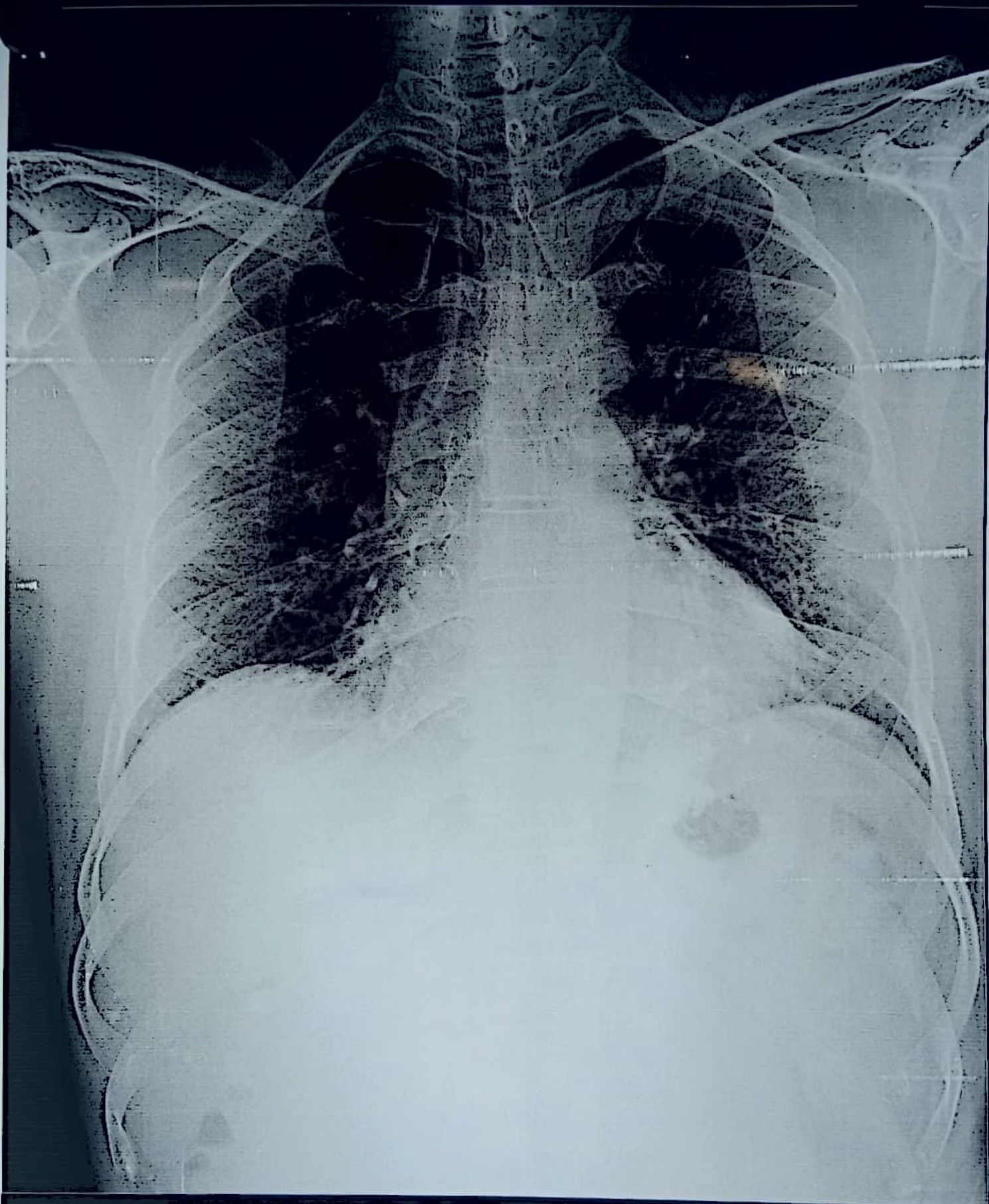
**IMPRESSION:-**

No significant abnormality seen

  
DR. ANUGRAH PATERIA

MBBS, MD

Consultant Radiologist.



MR NITIN SOLANKI 40Y 23-10281 CHEST PA 23/11/2023  
GD HOSPITAL 80FEET ROAD RATNPURI, RATLAM PH:9111013321

PT NAME	MR. NITIN SOLANKI	AGE /SEX/	40YEAR / MALE
REF BY	DR. DEVENDRA VAISHNAV GD HOSPITALRATLAM	DATE	27/11/2023

**ULTRASOUND WHOLE ABDOMEN**

**Liver** is normal in size **12.2cm** and however showing raised echotexture. Hepatic venous system appear normal. No focal lesion is seen. Intra and extra hepatic biliary radicles are not dilated. Portal vein and CBD are normal in caliber.

**Gall bladder** is normal in size & shape. Its lumen is echofree and nonlithiastic.

**Pancreas** is normal in size outline & echo pattern.

**Spleen** is normal in size and echo pattern.

**Right kidney** is normal in size, **(11.1X4.0cm)** shape and echogenicity with smooth outline. Central pelvicalyceal sinus and corticomedullary ratio are normal. No calculus seen.

**Left kidney** is normal in size, **(10.2x4.4cm)** shape and echogenicity with smooth outline. Central pelvicalyceal sinus and corticomedullary ratio are normal. No calculus seen.

**Urinary bladder** is normal in shape & contour. Its wall is normal. Both V.U.J. are clear.

**Prostate** is normal in size **(2.7x2.9x3.9cm)**, shape echotexture & contour. IVC and abdominal aorta are normal in calibre. No evidence of intra-abdominal lymphadenopathy. No evidence of ascites is seen.

**IMPRESSION:** Ultrasound whole abdomen study show:

➤ **Great I fatty liver**

**Advice:** LFT Correlation and further evaluation.

**DR. ANUGRAH PATERIA**  
(Radiologist)

It is a professional opinion, not valid for medico legal purpose.

DDY DIAGNOSTIC CENTRE, RATLAM.

