



- हृदयी रोग विशेषज्ञ
- किडनी एवं मूत्र रोग विशेषज्ञ (यूरो सर्जन)
- आई.सी.यू. एवं क्रिटिकल ट्रॉमा केयर
- जनरल एवं लेप्रोप्योपिक सर्जन
- नाक, कान, गला रोग विशेषज्ञ
- ऑक्युपेशनल थैरपिस्ट/फिजियोथैरपिस्ट
- न्यूरोसर्जन
- महिला रोग विशेषज्ञ
- प्लास्टिक सर्जन
- डायलिसिस सुविधा
- जनरल फिजिशियन
- ओरल एवं मैक्सिलोफेशियल सर्जन

PT. Name : MR..ABHISHEK TOMAR Date : 23-11-2023  
 F/H Name : ANURAG SINGH TOMAR OPD NO : 7  
 Age / Gender : 36 Y / M Mobile No : 9131027271  
 UHID No : 23-10285 Fees : 0.00  
 Consultant : DEVENDRA VAISHNAV Bill No : 23-31489  
 Department : ANESTHESIOLOGY  
 Doctor Reg No : MP-10124  
 Address : GALI NO 4, KASTURBA NAGAR RATLAM, RATLAM

1. Height	2. Weight	3. BMI	4. Build	5. Pulse Rate/min	6. Blood Pressure
Cms	Kgs		Normal		
170	88.2	28.1	Under weight	70	180/98
			Over weight		

8. Visual Acuity Whether he/she falls in the category of visually impaired

Eye	Vision	9. Dental /Oral Hygiene
Right	0.5	Check before teeth in in
Left	0.5	

Rx

Blood sample - done ✓  
 X-ray - Done ✓  
 ECG - done ✓  
 Urine R - done ✓  
 Urine H - done ✓

10. Conclusion: —

11. Recommendations:

Tests: —  
 Diet: —

OTC  
 E - 20  
 T - 20

24-11-2023  
 20-130000  
 CVI - 512  
 AS - 3597  
 CNS - consult

GD HOSPITAL  
 80, Feet Road, Ratnapuri, Ratlam  
 Reg.-NH1985/JUN/2016  
 Rohini ID-8900080354630

पता : 80 फीट रोड, रत्नपुरी, रतलाम

+91 9752450505, 9111013321

info@gdhospitals.com

www.gdhospitals.com

सभी प्रमुख बीमा कंपनियों से केश लेंस उपचार की सुविधा उपलब्ध है

नोट : कृपया अपॉइंटमेंट हेतु हेल्प लाईन नं. पर संपर्क करें।  
 रविवार को मेडिकल इमरजेंसी होने पर ही आवें।  
 पुनः दिखाने के लिये रविवार छोड़कर आवें।

आई.सी.यू. सुविधा उपलब्ध

डॉक्टर को दिखाने के 7 दिन बाद शुल्क माग्य रहेगा।

Name : MR. ABHISHEK TOMAR	UHID.No : 23-10285	IPD/OPD: OPD
Age/Sex : 36 Y / M	Accession No. : 20231123025	Category : MEDIWHEEL
Consultant : DEVENDRA VAISHNAV	Bill / IPD No. : 23-31571	



Registration No



Accession No

## HAEMATOLOGY REPORT

Sample Collected: 23-Nov-2023 3:21 PM

Sample Type: EDTA BLOOD

Test Name	Results	Unit	Biological Reference Range
Haemoglobin	15.5	gm/dl	12-16
Total Red Blood Count	5.89	Millions/cumm	3.5-5.5
Haematocrite	49.3	%	36.0-51.0
MCV	83.70	fl	77-95
MCH	26.32	pg	26-32
MCHC	31.44	g/dl	30-36
Total Leukocyte Count	8800	cells/cumm	4,000-11,000
Neutrophils	60	%	40-70
Lymphocytes	34	%	20-45
Eosinophils	02	%	2.0-6.0
Monocytes	04	%	2.0-8.0
Basophils	00	%	0-0.1%
Platelet	2.76	lakhs/cmm	1.5-4.5
Erythrocyte Sedimentation Rate			
ESR	08	mm	0-9
BLOOD GROUP			
ABO	A		
Rh TYPE	POSITIVE		

Remarks :

DR. LEKHRAJ PATIDAR

• Home Collection Facility Available •

Note : Diagnostic test have technical limitation. | For technical disparity repeated examination are required.  
No legal liability is accepted. | Clinical correlation is requested. This test is not valid for medico-legal purpose.

Name : MR. ABHISHEK TOMAR	UHID.No : 23-10285	IPD/OPD: OPD
Age/Sex : 36 Y / M	Accession No. : 20231123025	Category : MEDIWHEEL
Consultant : DEVENDRA VAISHNAV	Bill / IPD No. : 23-31571	



Registration No



Accession No

**BIOCHEMISTRY**

Sample Collected: 23-Nov-2023 3:21 PM

Sample Type: SERUM

Test Name	Results	Unit	Biological Reference Range
<b>LIPID PROFILE.</b>			
TOTAL CHOLESTROL	186.6	mg/dl	0-200
TRIGLYCERIDES.	145.7	mg/dl	0-150
CHOLESTEROL HDL	51.60	mg/dl	35-85
CHOLESTEROL LDL	105.86	mg/dl	0-130
CHOLESTEROL VLDL	29.14	mg/dl	10-30
TOTAL CHOLESTEROL HDL RATIO	3.62	%	3-4.4
CHOLESTEROL LDL CHOLESTEROL HDL RATIO	2.05	%	0.1-3.0
<b>LIVER FUNCTION TEST (LFT)</b>			
Serum Bilirubin (Total)	0.79	mg/dl	0.1-1.0
Serum Bilirubin (Direct)	0.31	mg/dl	0.0-0.2
Serum Bilirubin (Indirect)	0.48	mg/dl	0.0-0.8
SGOT (AST)	26.18	U/L	9-40
SGPT (ALT)	21.30	U/L	9-40
Alkaline Phosphatase	144.1	U/L	100-250
Total Protein	6.72	g/dL	6.3-8.2
Albumin	3.84	g/dl	3.5-5.0
Globulin	2.88	g/dl	0-5
Albumin Globulin Ratio	1.33	Ratio	1.0-2.3
BLOOD SUGAR (FASTING)	99.50	mg/dl	70 - 110
BLOOD UREA NITROGEN	13.09	mg/dl	5-25
Serum Creatinine	0.95	mg/dl	0.70-1.40
Uric Acid	3.20	mg/dl	2.0-7.0

Remarks :

DR. LAKHRAJ PATIDAR

• Home Collection Facility Available •

Note : Diagnostic test have technical limitation. | For technical disparity repeated examination are required. No legal liability is accepted. | Clinical correlation is requested. This test is not valid for medico-legal purpose.

# GD Pathology

## जी.डी. पेथोलॉजी

Reg. No. CL/1058/AUG-2020



gdpathologylab@gmail.com  
www.gdhospitals.com  
80 Feet Road, Ratnapuri, Ratlam (M.P.)  
97524-50505, 91110-13321

Name :MR. ABHISHEK TOMAR	UHID. No. :23-10285	IPD/OPD Status :OPD
Age/Sex :36 Y/Male	Lab No. :20231123025	consultant :Dr.DEVENDRA VAISHNAV
Ref. Dr.	Receipt no : 23-31571	Location/Bed.No :,

Collected at:23/11/2023 15:21:00



Accession No

### BIOCHEMISTRY

Report Gen at:



Registration No

SAMPLE TYPE : EDTA BLOOD

Investigations	Result	Unit	Biological Reference Interval
HbA1C (GLYCOSYLATED Hb )	5.39	%	4.0- 6.0 %

#### HbA1C

HbA1C

4.0-6.0%

Good control 6-7%

Fair control 7-8%

Poor control >8%

#### Estimated Blood Glucose (ABG)

97-126 mg/dl

126-154 mg/dl

154-183 mg/dl

183 mg/dl

TECHNOLOGIST

• Home Collection Facility Available •

Dr. LEKHRAJ PATIDAR

Note : Diagnostic test have technical limitation. | For technical disparity repeated examination are required.  
No legal liability is accepted. | Clinical correlation is requested. This test is not valid for medico-legal purpose.

# GD Pathology

## जी.डी. पेथोलॉजी

Reg. No. CL/1058/AUG-2020



gdpathologylab@gmail.com  
www.gdhospitals.com  
80 Feet Road, Ratnapuri, Ratlam (M.P.)  
97524-50505, 91110-13321

Name :MR. ABHISHEK TOMAR	UHID. No. :23-10285	IPD/OPD Status :OPD
Age/Sex :36 Y/Male	Lab No. :20231123025	consultant :Dr.DEVENDRA VAISHNAV
Ref. Dr.	Receipt no : 23-31571	Location/Bed.No :,

Collected at:23/11/2023 15:21:00

Report Gen at:



### HAEMATOLOGY REPORT



Accession No

Registration No

SAMPLE TYPE : SERUM

Investigations	Result	Unit	Biological Reference Interval
T3 (Total Triiodothyronine)	1.36	nmol/L	1.23-3.07
T4 (Total Thyroxine)	104.8	nmol/L	66-181
TSH (Thyroid Stimulating Hormone)	2.78	mIU/L	0.30-4.2

TECHNOLOGIST

• Home Collection Facility Available •

Dr. LEKHRAJ PATIDAR

Note : Diagnostic test have technical limitation. | For technical disparity repeated examination are required.  
No legal liability is accepted. | Clinical correlation is requested. This test is not valid for medico-legal purpose.

Name : MR. ABHISHEK TOMAR  
Age/Sex : 36 Y / M  
Consultant : DEVENDRA VAISHNAV

UHID.No : 23-10285  
Accession No. : 20231123025  
Bill / IPD No. : 23-31571

IPD/OPD: OPD  
Category : MEDIWHEEL



Registration No



Accession No

### CLINICAL PATHOLOGY

Sample Collected: 23-Nov-2023 3:21 PM

Sample Type: URINE,

Test Name	Results	Unit	Biological Reference Range
<b>PHYSICAL EXAMINATION.</b>			
QUANTITY	30ML		
COLOUR.	PALE YELLOW	-	-
APPEARANCE	CLEAR	-	-
PH	ACIDIC		
SPECIFIC GRAVITY	1.010		
<b>CHEMICAL EXAMINATION.</b>			
Urine Sugar	NIL	-	NIL
Urine Albumin	NIL		
BS/BP	ABSENT		ABSENT
KETONE.	ABSENT		ABSENT
<b>MICROSCOPIC EXAMINATION.</b>			
PUS CELLS	3-5	/hpf	0-4
EPITHELIAL CELLS	2-4	/HPF	0-2
RBC,	NIL	/HPF	0-2
CASTS	ABSENT	-	-
CRYSTALS	ABSENT	/HPF	-
BACTERIA	ABSENT		
YEAST	ABSENT		

Remarks :

DR. LEKHRAJ PATIDAR

• Home Collection Facility Available •

Note : Diagnostic test have technical limitation. | For technical disparity repeated examination are required.  
No legal liability is accepted. | Clinical correlation is requested. This test is not valid for medico-legal purpose.



**Arihant**  
Pathology Laboratory



Scan QR code to check  
report authenticity



MC-2202

**sterling**  
**ACCURIS**  
Pathology lab that cares

**LABORATORY TEST REPORT**



Passport No :

Patient Information	Sample Information	Client/Location Information
<b>Name</b> : Mr Abhishek Tomar <b>Sex/Age</b> : Male / 38 Y <b>Ref. Id</b> : <b>Ref. By</b> : Dr Devendra Vaishnav	<b>Lab Id</b> : 112312501080 <b>Registration on</b> : 23-Nov-2023 17:45 <b>Collected at</b> : non SAWPL <b>Collected on</b> : 23-Nov-2023 17:45 <b>Sample Type</b> : Serum	<b>Client Name</b> : G Y Foundation@Ratlam <b>Location</b> : <b>Approved on</b> : 24-Nov-2023 12:37 <b>Status</b> : Final <b>Printed On</b> : 24-Nov-2023 12:37 <b>Process At</b> : 1. NRL SAWPL Gujarat Ahmedabad Paldi

**Biochemistry**

Test	Result	Unit	Biological Ref. Interval
<b>GGT</b> <i>L-y-Glytamyl-p-nitroanilide</i>	22.0	U/L	15 - 73

----- End Of Report -----

*Dr. Purvish Darji*

**Dr. Purvish Darji**  
MD(Path)

**Dr. Sanjeev Shah**  
MD Path

**Dr. Yash Shah**  
MD Path



**Sterling Accuris Pathology Laboratory**  
Laboratory: (Arihant Pathology Laboratory), 15, Ved Vyas Colony, Ratlam, Madhya Pradesh-477001  
Ph.: 07412-297458

This is an Electronically Authenticated Report.

Not to be used for any other referred tests

info.ratlam@sterlingaccuris.com | Website: www.sterlingaccuris.com | Follow us on:

Page 1 of 1



Download Accuris App



Date **27/11/2023**.....

## ECHO REPORT

Name:- : MR. Abhishek Tomer AGE 36 Y SEX - MALE

- All cardiac chambers are normal in size.
- All cardiac valves are normal.
- Aortic root & PA are normal.
- No RWMA.
- Normal LV systolic function (LVEF 57%)
- IAS & IVS are intact.
- Pericardium is normal.
- No clot /Thrombus / Vegetation.

### **DOPPLER:**

- No significant gradient across all valves .
- Normal flow across all valves.

### **IMPRESSION**

- No RWMA
- Normal LV systolic function
- LVEF 57%

  
**DR. BHARAT KUMRAWAT**  
**MD MEDICINE**





# GD Hospital

## गीतादेवी हॉस्पिटल

Hospital Reg. No. NH/1985/JUN-2016



info@gdhospitals.com  
www.gdhospitals.com



+91-97524 50505  
+91-91110 13321



80 Feet Road, Ratnapur,  
Ratlam (M.P.) 457001

Date : .....

23/11/2023

Patient Name:- : Abhishek Tomer 36 year male

### X-RAY-CHEST (PA VIEW)

#### FINDINGS:-

**Bilateral lung fields are normal,**

The pleural spaces are normal.

Both hila are normal in size have equal density and bear normal relations

The heart and trachea are central in position and no mediastinal abnormal

No mediastinal abnormality visible

The cardiac size is normal.

The domes of diaphragm are normal in position and show smooth outline.

#### IMPRESSION:-

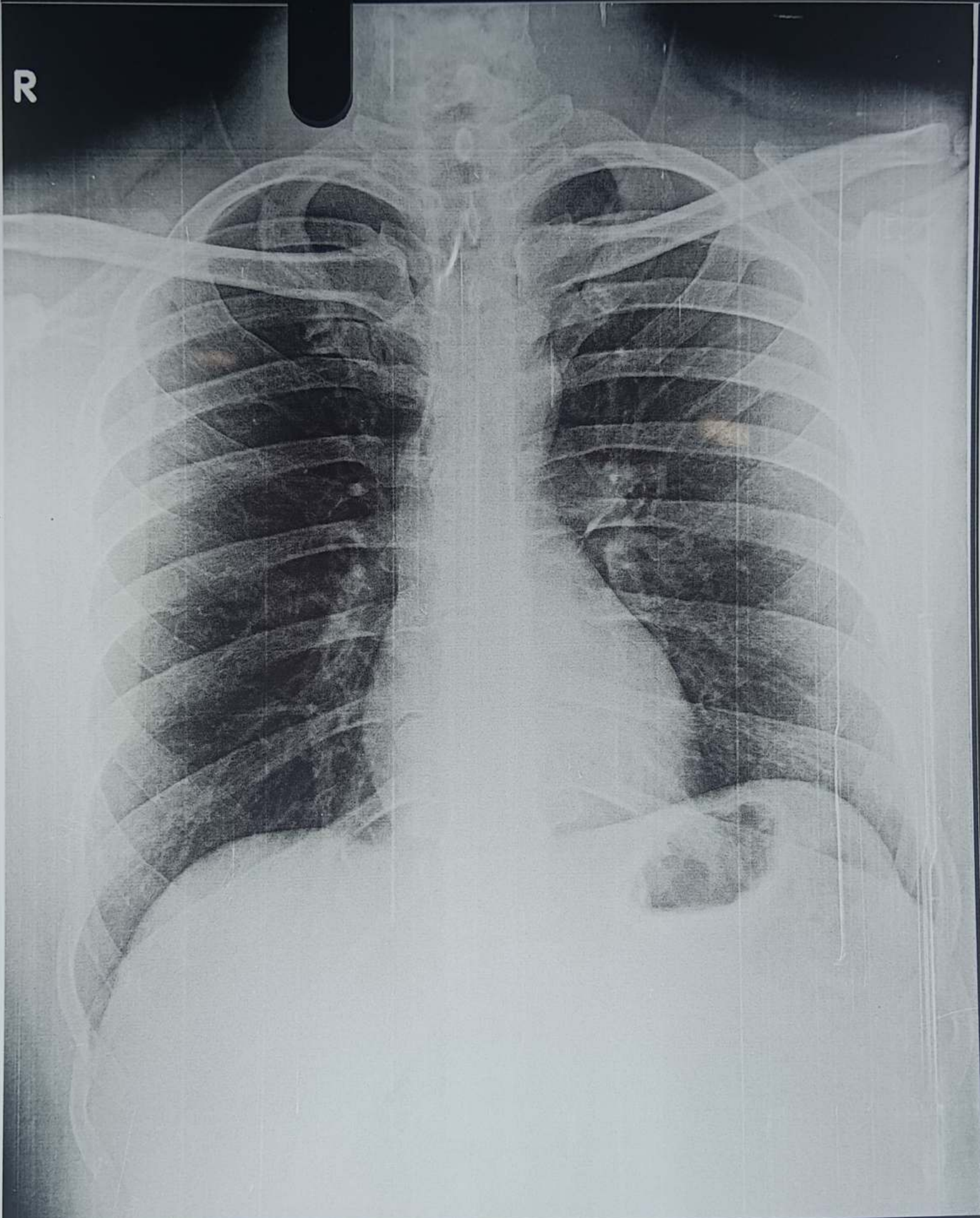
No significant abnormality seen

  
DR. ANUGRAH PATERIA

MBBS, MD

Consultant Radiologist.

R



MR ABHISHEK TOMAR 36Y 23-10285 CHEST PA 23/11/2023  
GD HOSPITAL 80FEET ROAD RATNPURI, RATLAM PH:9111013321

PT NAME	MR. ABHISHEK TOMAR	AGE /SEX/	36YEAR / MALE
REF BY	DR. DEVENDRA VAISHNAV	DATE	23/11/2023

**ULTRASOUND WHOLE ABDOMEN**

**Liver** is normal in size (13cm) and echotexture. Hepatic venous system appear normal. No focal lesion is seen. Intra and extra hepatic biliary radicles are not dilated. Portal vein and CBD are normal in caliber.

**Gall bladder** is normal in size & shape. Its lumen is echofree and nonlithiastic.

**Pancreas** is normal in size outline & echo pattern.

**Spleen** is normal in size (7.8cm) and echo pattern.

**Right kidney** is normal in size (9.6x3.5cm), shape and echogenicity with smooth outline. Central pelvicalyceal sinus and corticomedullary ratio are normal. No calculus seen.

**Left kidney** is normal in size (9.0x4.4cm), shape and echogenicity with smooth outline. Central pelvicalyceal sinus and corticomedullary ratio are normal. No calculus seen.

**Urinary bladder** is normal in shape & contour. Its wall is normal. Both V.U.J. are clear.

**Prostate** is normal in size (3.1x3.1x2.9cm, 15.4cc), showing few parenchymal calcifications.

IVC and abdominal aorta are normal in calibre. No evidence of intra-abdominal lymphadenopathy. No evidence of ascites is seen.

**IMPRESSION:** Ultrasound whole abdomen study show:

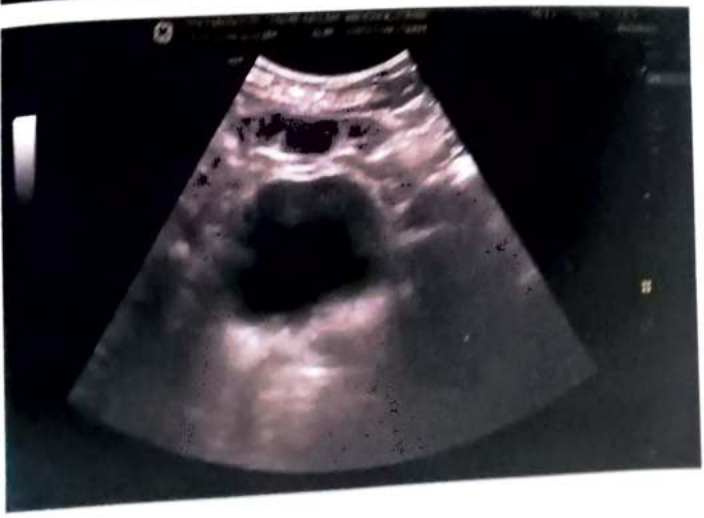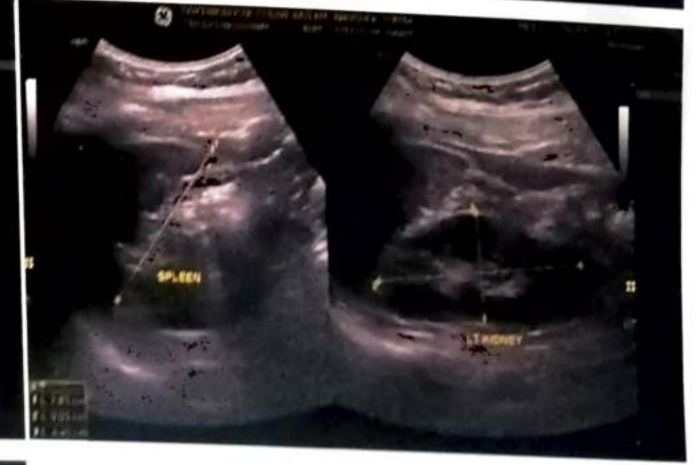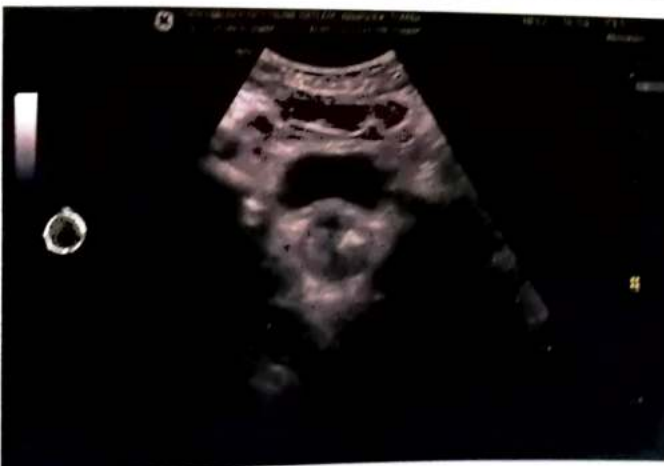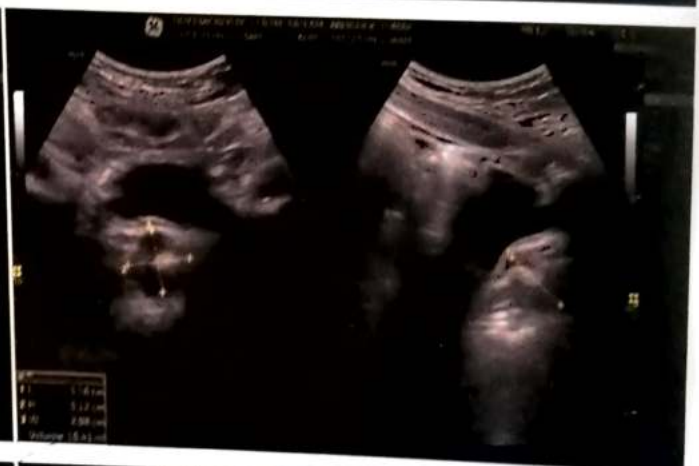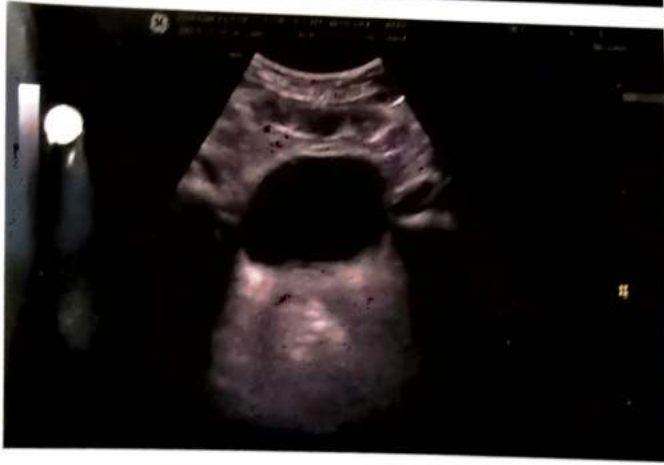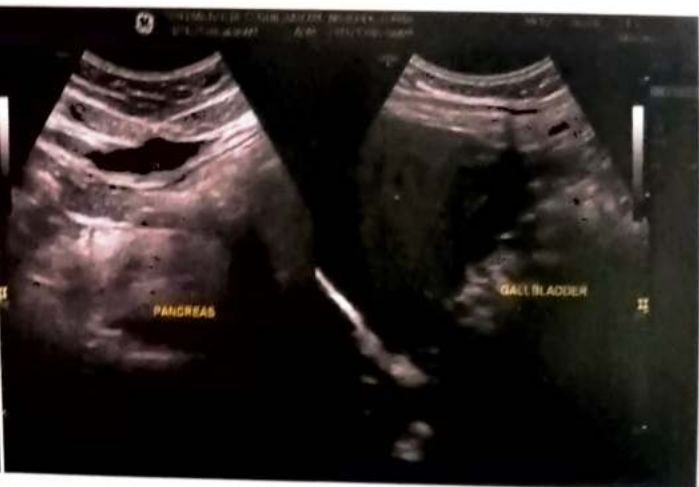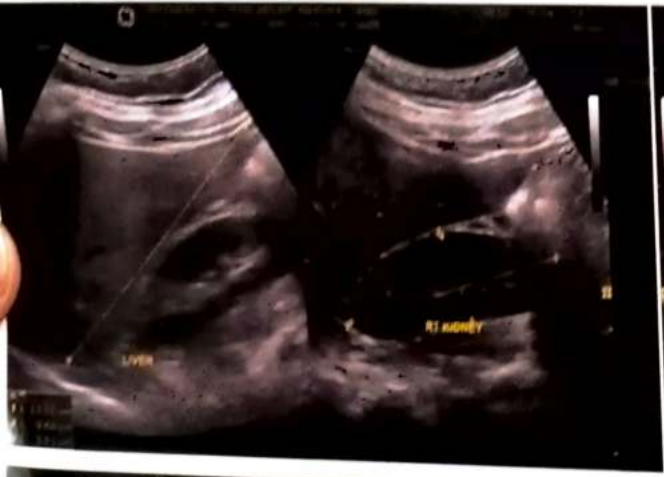- Prostate is showing few parenchymal calcifications.

**Advice:** Clinical correlation and further evaluation.

**DR ANUGRAH PATERIA**  
(Radiologist)

It is a professional opinion, not valid for medico legal purpose.

# DDY DIAGNOSTIC CENTRE, RATLAM.

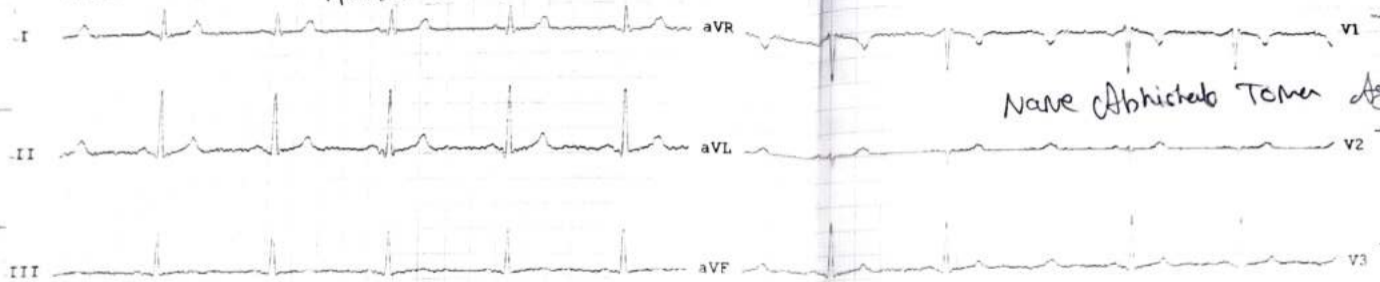


10 mm/mV 25 mm/S

Abhishade TOMAR

0.05

ID :  
Name :  
Age : Years  
Gender :  
BP : (mmHg)  
Weight: Kgs  
Date : 23/11/23  
12:46 PM  
Note :



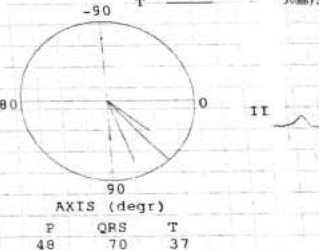
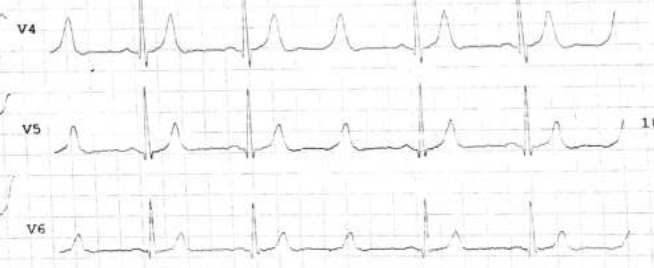
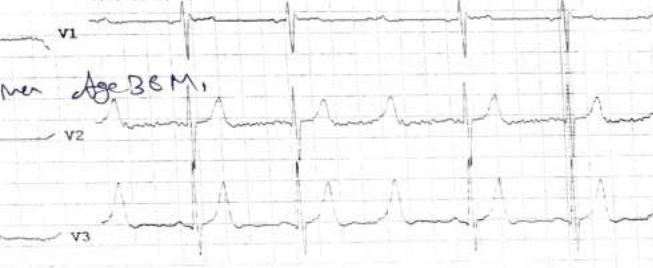Name Abhishade TOMAR Age

0.05-35 Hz 50 Hz

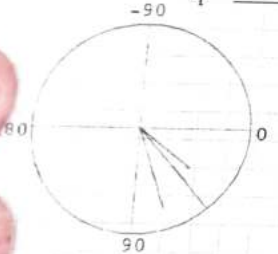
P  
QRS  
T

24mm/mV  
50mm/s

Man Age 38 M

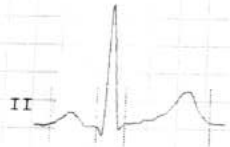


P \_\_\_\_\_  
 QRS \_\_\_\_\_ 20mm/mV  
 T \_\_\_\_\_ 50mm/S



AXIS (degr)

P	QRS	T
48	70	37



Parameters

HR : 67 BPM  
 QRS DUR : 93 mS  
 QT INT : 386 mS  
 QTc INT : 408 mS  
 PR INT : 152 mS  
 RR INT : 895 mS  
 QT/QTc : 94 %  
 QT/RR : 43 %  
 RV5/SV1 : 1.36/0.74 mV

Adult Interpretation Report:

Sinus Rhythm  
 Normal Sinus Rhythm ECG

(Physician

Dr.

Note: Results may be clinically correlated