



Name : Mrs. PUSPA SONOWAL (31 /F)

Address : KHARGULI, GUWAHATI, KAMRUP(M), ASSAM, INDIA

Date : 27/01/2024

# AHC MEDICAL SUMMARY

Examined by: Dr .PRABIN KUMAR SAIKIA

UHID : AHLG2.0000036834

Package : MediWheel Full Body Health Check up-Female below 40Yrs

AHC No : APHCAH20929



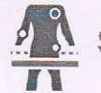## CHIEF COMPLAINTS

Package Name: MediWheel Full Body Health  
Check up-Female below 40Yrs  
PCOS 2016 ON HOME0  
Anxiety  
Irregular periods



## DRUG ALLERGY

NO KNOWN ALLERGY :27/01/2024



## SYSTEMIC REVIEW

### Cardiovascular system

- Nil Significant

### Respiratory system

- Nil Significant

### Oral and dental

- Nil Significant

### Gastrointestinal system

Appetite - normal; Abdominal pain - no; Dyspepsia -  
yes; Nature - intermittent; Peptic ulcer - no; Bowel  
habits - regular, constipation; Piles - no

### Genitourinary system

- Nil Significant

### Gynaec history

Last menstrual period - 17 01 24

### Central nervous system

Head ache - occasional; Dizziness - no;  
Concentration - good; Sleep - inadequate

### Musculoskeletal system

Spine and joints  
- Nil Significant

### Weight

- stable

## General symptoms

Happiness score  
Sleeping well - Disturbed; Stress at home - Mild;  
Stress at work - Severe

## Mind Health screening

Emotional Wellness  
Assessment (PHQ9)  
Score - 3  
Depression Level -  
None-Minimal



## Present medications

On immunosuppressive - No



## Past medical history

Allergies - dust, pollens  
Others - No



## Surgical history

Surgical history - Nil

## Immunization history

- Covid Dose2



## Personal history

Marital status - Married  
Diet - Non Vegetarian  
How many meals in a  
week do you eat hotel  
food? - 2  
Alcohol - does not consume alcohol  
Smoking - No  
Chews tobacco - No  
Physical activity - Moderate  
Ethnicity - Indian Asian



## Family history

Father - alive

Aged - 64 YRS  
 Mother - alive  
 Aged - 60 YRS  
 Sisters - 1  
 Coronary artery disease - none  
 Cancer - None

Eye vision - BE 6/6. N6  
 Colour vision - Normal  
 Pupil - Normal  
 Intraocular pressure - 16 mmHg (R), 18 mmHg (L)  
 Advice for spectacle - Yes

## PHYSICAL EXAMINATION



### General

Height - 151  
 Weight - 49  
 BMI - 21.49  
 Waist circumference - 73  
 Hip - 89  
 Waist/ Hip ratio - 0.82  
 Pallor - No  
 Oedema - no  
 SpO2 - 99% RA



### Head and ENT

Others - Nose Bilateral HIT +



### Cardiovascular system

Heart rate (Per minute) - 96  
 Rhythm - Regular  
 - B.P. Sitting  
 Systolic(mm of Hg) - 120  
 Diastolic(mm of Hg) - 70  
 Heart sounds - S1S2+

### Respiratory system

Rate of respiration(per minute) - 18  
 Breath sounds - Normal vesicular breath sounds



### Abdomen

Organomegaly - No  
 Tenderness - No





### Eyes

Eye vision - Normal

Printed By : SAMIMA YASMIN

**Executive Summary**

-  1. Mild normochromic normocytic anaemia (Hb 11.8 g/dl)
-  2. Eosinophilia (E 9.1%)

**Wellness Prescription**

**Advice On Diet :-**



Dietician consultation

**Advice On Physical Activity :-**



Regular exercise

**Recommended Follow-up Tests**

Test Name	Test Schedule	Repeat Frequency	Remarks
HB ELECTROPHORESIS	Immediate/Urgent		
VITAMIN D-SERUM	Immediate/Urgent		

**Dr.PRABIN KUMAR SAIKIA**

AHC Physician / Consultant Internal Medicine

Printed By : HEALTH CHECK REPORT

Dr. Prabin Kumar Saikia  
 MD (Gen Medicine), FCGP, FICP, PGDHHM  
 Registration No.-7523, Assam  
 Consultant Physician, APHC  
 Apollo Hospitals Guwahati-781005

**Note :-** The Health Check-up examinations and routine investigations have certain limitations and may not be able to detect all the diseases. Any new or persisting symptoms should be brought to the attention of the Consulting Physician. Additional tests, consultations and follow up may be required in some cases.

Name : Mrs. PUSPA SONOWAL

Age : 31Yr 0Mth 0Days

Gender : Female

UHID : AHLG2.0000036834 / APHCAH20929

W/BNo/RefNo : AHC

SIN \ LRN : 123158356 \ 123158403 \ 123158358 \ 10254439

Specimen : Serum

Ref Doctor : Dr. Prabin Kumar Saikia



Collected on : 27-JAN-2024 08:52:41 AM

Received on : 27-JAN-2024 10:07:59 AM

Reported on : 27-JAN-2024 12:52:30 PM

MediWheel Full Body Health Check up-Female below 40Yrs

TEST NAME	RESULT	BIOLOGICAL REFERENCE INTERVALS	UNITS
TOTAL T3: TRI IODOTHYRONINE - SERUM (Eclia)	1.8	Healthy Adults Euthyroid:1.3-3.1	nmol/L
TOTAL T4: THYROXINE - SERUM (Eclia)	109	Healthy Adults Euthyroid: 66-181	nmol/L
TSH: THYROID STIMULATING HORMONE - SERUM (Eclia)	1.99	Healthy Adults Euthyroid: 0.270-4.20	uIU/mL
ALT(SGPT) - SERUM (UV With P5P-IFCC)	41	Healthy Females:14-59 U/L	U/L
ALBUMIN - SERUM (Brom Cresol Green)	4.1	Healthy Adults-3.5-5.2	g/dL
GLOBULIN-SERUM(Calculated)	3.7 *	Healthy Adults: 1.8 - 3.6	
ALBUMIN:GLOBULIN-SERUM(RATIO)(Calculated)	1 *	0 - 0	
ALKALINE PHOSPHATASE - SERUM PNPP,AMP Buffer-IFCC	47	Healthy Adults:40-150	U/L
AST (SGOT) - SERUM (UV With P5P-IFCC)	24	Healthy Adults:15 - 37	U/L
BILIRUBIN, TOTAL - SERUM (Modified Doumas Ref. method/Jendrassik & Grof.)	1.1 *	Healthy Adults:<=1.0	mg/dL



MC-3480

Name : Mrs. PUSPA SONOWAL      Age : 31Yr 0Mth 0Days      Gender : Female  
 UHID : AHLG2.0000036834 / APHCAH20929      W/BNo/RefNo : AHC  
 SIN \ LRN : 123158356 \ 123158403 \ 123158358 \ 10254439  
 Specimen : Serum  
 Ref Doctor : Dr. Prabin Kumar Saikia



Collected on : 27-JAN-2024 08:52:41 AM      Received on : 27-JAN-2024 10:07:59 AM      Reported on : 27-JAN-2024 12:52:30 PM

CHOLESTEROL - SERUM (Cholesterol Oxidase)	131	Desirable:<200 Borderline:200 - 240 High Risk:>=240	mg/dL
GGTP: GAMMA GLUTAMYL TRANSPEPTIDASE - SERUM (L-gamma-glutamyl-3-carboxy-4-nitranilide)	22	Healthy Women:5 - 55	U/L
GLUCOSE -PLASMA (FASTING) Hexokinase	82	Non-Diabetic: <=100 Pre-Diabetic: 100-125 Diabetic: >=126	mg/dL
HDL CHOLESTEROL - SERUM / PLASMA (Direct Measurement)	53	Low: <40 High: >=60	mg/dL
TOTAL CHOLESTEROL/HDL CHOLESTEROL RATIO(Calculated)	2.5	Desirable :< 4.5	
LDL CHOLESTEROL - SERUM(DIRECT LDL) (Homogenous Method)	76	Optimal:<100 Near Optimal:100-129 Borderline High:130-159 High:160-189 Very High:>=190	mg/dL
PROTEIN, TOTAL - SERUM (Biuret)	7.8	Healthy Adults:6.4-8.3	mg/dl

Page 2 of 4  
**CONSULTANTS**

- |                   |                   |                            |                                 |
|-------------------|-------------------|----------------------------|---------------------------------|
| DR. I. KALITA, MD | DR. T. SARMA, DCP | DR. P. GOSWAMI, MD         | DR. M. SAIKIA, MD(BIOCHEMISTRY) |
| DR. A. VERMA, DCP | DR. M. BARMAN, MD | DR. D.J. LAHON, MD (MICRO) | DR. M. SARMA, MD (MICRO)        |

\* The results relate to sample tested only. Partial reproduction of reports is prohibited.

Name : Mrs. PUSPA SONOWAL Age : 31Yr 0Mth 0Days Gender : Female  
 UHID : AHLG2.0000036834 / APHCAH20929 W/BNo/RefNo : AHC  
 SIN \ LRN : 123158356 \ 123158403 \ 123158358 \ 10254439  
 Specimen : Serum  
 Ref Doctor : Dr. Prabin Kumar Saikia



DEPARTMENT OF BIOCHEMISTRY



Collected on : 27-JAN-2024 08:52:41 AM Received on : 27-JAN-2024 10:07:59 AM Reported on : 27-JAN-2024 12:52:30 PM

TRIGLYCERIDES - SERUM (Glycerol Phosphate Oxidase)	76	Normal : <150 Borderline High :150-199 High : 200-499 Very High : >=500	mg/dL
UREA - SERUM (Enzymatic,Urease-GLDH) (Urease)	19	<50 years:15-40	mg/dL
URIC ACID - SERUM (Modified Uricase)	4.2	Healthy Women:2.6 - 6.0	mg/dL
VLDL CHOLESTEROL - SERUM CALCULATED.	15	Desirable:<30	
BILIRUBIN CONJUGATED (DIRECT) - SERUM (Jendrassik & Grof)	0.2	Healthy Adults:0.0-0.5	mg/dL
CREATININE - SERUM JAFTE METHOD	0.6	Healthy Women: 0.57 - 1.11	mg/dL
GLUCOSE - PLASMA (POST PRANDIAL) Hexokinase	89	Normal: <140 Pre-Diabetic: 140-199 Diabetic :->=200	mg/dL

ApollO  
HOSPITALS  
GUWAHATI  
TOUCHING LIVES

Page 3 of 4  
CONSULTANTS

DR. I. KALITA, MD

DR. T. SARMA, DCP

DR. P. GOSWAMI, MD

DR. M. SAIKIA, MD(BIOCHEMISTRY)

DR. A. VERMA, DCP

DR. M. BARMAN, MD

DR. D.J. LAHON, MD (MICRO)

DR. M. SARMA, MD (MICRO)

\* The results relate to sample tested only. Partial reproduction of reports is prohibited.



MC-3480


Name : Mrs. PUSPA SONOWAL Age : 31Yr 0Mth 0Days Gender : Female  
UHID : AHLG2.0000036834 / APHCAH20929 W/BNo/RefNo : AHC  
SIN \ LRN : 123158356 \ 123158403 \ 123158358 \ 10254439  
Specimen : Serum  
Ref Doctor : Dr. Prabin Kumar Saikia



Collected on : 27-JAN-2024 08:52:41 AM Received on : 27-JAN-2024 10:07:59 AM Reported on : 27-JAN-2024 12:52:30 PM

Report Status:Final

\* END OF REPORT \*



CHECKED BY 1078452  
1078546

Printed On : 28-JAN-2024 08:46:54 AM

*Ashwin*

DR. ASHWIN VERMA, D.C.P  
ASSOCIATE CONSULTANT PATHOLOGIST  
REGD NO. 5340 AMC

Page 4 of 4  
**CONSULTANTS**

DR. I. KALITA, MD

DR. T. SARMA, DCP

DR. P. GOSWAMI, MD

DR. M. SAIKIA, MD(BIOCHEMISTRY)

DR. A. VERMA, DCP

DR. M. BARMAN, MD

DR. D.J. LAHON, MD (MICRO)

DR. M. SARMA, MD (MICRO)

\* The results relate to sample tested only. Partial reproduction of reports is prohibited.

Name : Mrs. PUSPA SONOWAL Age : 31Yr 0Mth 0Days Gender : Female  
 UHID : AHLG2.0000036834 / APHCAH20929 W/BNo/RefNo : AHC  
 SIN \ LRN : 123158361 \ 10254439  
 Specimen : Whole blood  
 Ref Doctor : Dr. Prabin Kumar Saikia



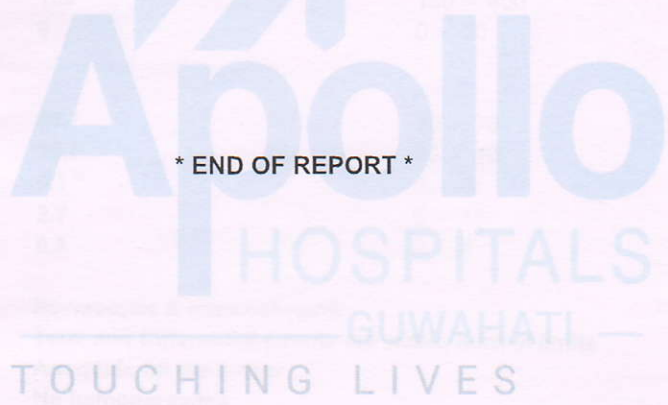
Collected on : 27-JAN-2024 08:52:41 AM Received on : 27-JAN-2024 10:15:32 AM Reported on : 27-JAN-2024 11:18:19 AM

MediWheel Full Body Health Check up-Female below 40Yrs

TEST NAME	RESULT	BIOLOGICAL REFERENCE INTERVALS	UNITS
GLYCOSYLATED HEMOGLOBIN (HBA1C) - WHOLE BLOOD	5.2	GOAL:<6.5% Prediabetic:5.7-6.4%	%
GLYCOSYLATED HEMOGLOBIN (HbA1C) - WHOLE BLOOD		Diabetic:>6.5% Non-diabetic:<5.7%	
		Uncontrolled-diabetics>8%	
Mean Plasma Glucose (MPG) Estimate:	102.5400		mg/dL

Report Status:Final

\* END OF REPORT \*



CHECKED BY 1078443  
155038

First Report Printed On : 28-JAN-2024 08:47:53 AM  
Printed On : 28-JAN-2024 08:47:54 AM

Dr.Pooja Keshan MBBS,MD  
Reg No 21460 AMC



Name : Mrs. PUSPA SONOWAL Age : 31Yr 0Mth 0Days Gender : Female  
 UHID : AHLG2.0000036834 / APHCAH20929 W/BNo/RefNo : AHC  
 SIN ILRN : 123158357 \ 123158360 \ 10254439  
 Specimen : Urine  
 Ref Doctor : Dr. Prabin Kumar Saikia



Collected on : 27-JAN-2024 08:52:41 AM Received on : 27-JAN-2024 12:14:08 PM Reported on : 27-JAN-2024 12:39:51 PM

**MediWheel Full Body Health Check up-Female below 40Yrs**

TEST NAME	RESULT	BIOLOGICAL REFERENCE INTERVALS	UNITS
<b>HEMOGRAM(CBC+ESR+RECTIC+PS)</b>			
Hemoglobin	11.8 *	12.0 - 15.0	g/dl
RBC COUNT	4.77	3.8 - 4.8	Million/ul
MCV	81.1 *	82.0 - 92.0	fl
MCH	24.7 *	26.0 - 32.0	pg
MCHC	30.5 *	31.0 - 36.0	g/dl
RDW-CV	14.1 *	11.6 - 14	%
RETICULOCYTE COUNT	1.28	Healthy Adult :-0.5-2.5%	%
Corrected TLC/WBC Count	7.36		
Platelet Count	158	150 - 400	10 <sup>3</sup> /mm <sup>3</sup>
ERYTHROCYTE SEDIMENTATION RATE (ESR)	9	0 - 20	mm/1st hr
<b>Differential Count</b>			
Neutrophils	61.7	40 - 70	%
Lymphocytes	25.7	20 - 40	%
Eosinophils	9.1 *	1 - 6	%
Monocytes	2.7	2 - 10	%
Basophils	0.8	0 - 2	%
<b>PERIPHERAL SMEAR</b>			
RBC:	Normocytic & normochromic		
WBC:	Total and Differential counts are within normal limits		
Platelets:	Adequate on the smear		
Hemoparasites	No hemoparasites		
PACKED CELL VOLUME [PCV]	38.7	36 - 46	%

Page 1 of 1 **CONSULTANTS**

DR. I. KALITA, MD

DR. T. SARMA, DCP

DR. P. GOSWAMI, MD

DR. M. SAIKIA, MD(BIOCHEMISTRY)

DR. A. VERMA, DCP

DR. M. BARMAN, MD

DR. D.J. LAHON, MD (MICRO)

DR. M. SARMA, MD (MICRO)

\* The results relate to sample tested only. Partial reproduction of reports is prohibited.

Name : Mrs. PUSPA SONOWAL Age : 31Yr 0Mth 0Days Gender : Female  
 UHID : AHLG2.0000036834 / APHCAH20929 W/BNo/RefNo : AHC  
 SIN ILRN : 123158357 \ 123158360 \ 10254439  
 Specimen : Urine  
 Ref Doctor : Dr. Prabin Kumar Saikia



Collected on : 27-JAN-2024 08:52:41 AM Received on : 27-JAN-2024 12:14:08 PM Reported on : 27-JAN-2024 12:39:51 PM

URINE- BENCE JONES PROTEINS	Negative	Negative
URINE ROUTINE (CUE)		
Color,:	Pale yellow	Pale Yellow/amber
Transparency:	Clear	Clear
Specific Gravity(Strip Method)	1.015 *	1.016 - 1.026
pH(Strip Method+ Ph Paper)	6.0	4.6 - 8
Glucose:(Benedicts+Strip Method)	Nil	Negative
Protein :(Strip+Heat Method)	Nil	Negative
DEPOSITS:(Microscopy)		
RBC	Not seen	Upto 3 Cells/hpf
WBC/Pus Cells	1-2/HPF	Upto to 5 Cells/hpf
Squamous epithelial cells	0-1/HPF	Up to 20
Casts:(Microscopy)	Not Detected	Absent /lpf
Crystals:	Not Detected	Absent /lpf
Nitrite	Negative	Negative
URINE SUGAR	Nil	
Report Status:Final		

\* END OF REPORT \*

ApollO  
HOSPITALS  
GUWAHATI  
TOUCHING LIVES

CHECKED BY : 1078438

Printed On : 28-JAN-2024 08:51:38 AM

DR. ASHWIN VERMA, D.C.P  
ASSOCIATE CONSULTANT PATHOLOGIST  
REGD NO. 5340 AMC

Page 2 of 2 CONSULTANTS

DR. I. KALITA, MD      DR. T. SARMA, DCP      DR. P. GOSWAMI, MD      DR. M. SAIKIA, MD(BIOCHEMISTRY)  
 DR. A. VERMA, DCP      DR. M. BARMAN, MD      DR. D.J. LAHON, MD (MICRO)      DR. M. SARMA, MD (MICRO)

\* The results relate to sample tested only. Partial reproduction of reports is prohibited.



# APOLLO HOSPITALS GUWAHATI

Unit : International Hospital  
(A unit of Assam Hospitals Ltd.)

CHECKED AND VERIFIED BY

## DEPARTMENT OF RADIOLOGY & IMAGING

Division of Colour Doppler & Ultrasonography

Patient ID:	0000036834	Patient Name:	PUSPA SONOWAL
Age:	31 Years	Sex:	F
Accession Number:		Modality:	US
Referring Physician:	DR P KR SAIKIA	Study:	W/A
Study Date:	27-Jan-2024		

### USG OF WHOLE ABDOMEN

#### LIVER

The liver is normal in size with homogenous midlevel parenchymal echotexture. No focal lesion is seen. The intrahepatic portal and hepatic venous system are normal. The intrahepatic bile ducts are not dilated.

#### GALL BLADDER

The gall bladder is normally distended and shows smooth contour. There is no obvious echoreflexive calculus in the gall-bladder. GB wall thickness is within normal limit.

#### CBD

The CBD is normal in course and calibre. No obvious luminal pathology in visualized portion.

#### SPLEEN

The spleen is normal in size and echotexture. No focal lesion is noted.

#### PANCREAS

The pancreas is normal in size and echotexture. No focal lesion is seen. Pancreatic duct is not dilated.

#### KIDNEYS

Both the kidneys are normal in size, shape, position and echotexture. Cortico-medullary differentiation is maintained. No evidence of calculi or calyceal dilatation on either side. Ureters are not dilated.

Right kidney measures – 109 mm

Left kidney measures – 111 mm

#### URINARY BLADDER

The urinary bladder is normal in capacity and contour. The wall is not thickened. No intraluminal calculus or mass is seen.

#### UTERUS

The uterus is normal in size and is anteverted in position. The midline endometrial echo is normal. The myometrium shows homogenous echotexture. No focal myometrial lesion is seen. Cervix appears normal. Uterus measures about 67 x 50 x 30 mm.

#### ADNEXAE

Both the ovaries are normal in size and echoanatomy. There is no evidence of any abnormal solid or cystic lesion in the ovaries. The right and left ovary respectively measures 27 x 19 mm & 24 x 14 mm in size.

No ascites is seen.

**Impression: No significant abnormality is noted on this scan.**

Dr. Zohaib Hussain, MD, DNB  
Consultant Radiologist  
Reg No - 26584 (AMC)

Date: 27-Jan-2024 10:01:14

S Hazarika, MD R. Baruah, DMRD P. Hatimota, MD R. Sarmah, MD A. Agarwal, MD M. Gohain, MD, S. Choudhury, MD Zohaib Hussain MD DNB  
Discrepancy or transcription error if detected should be sent for correction

**DEPARTMENT OF RADIOLOGY & IMAGING**

Division of Colour Doppler & Ultrasonography

Patient ID:	AHLG20000036834	Patient Name:	PUSPA SONOWAL
Age:	31 Years	Sex:	F
Accession Number:	17002.124022795	Modality:	DX
Referring Physician:	Prabin Kumar Saikia	Study:	Chest PA
Study Date:	27-Jan-2024		

**CHEST PA VIEW**

- No active parenchymal lesion is seen in the lung fields.
- Hilar shadows are normal.
- Cardiac size is normal.
- Hemidiaphragms are normal. CP angles are normal.
- Bony thorax is intact.

*Zohaib Hussain*

Dr. Zohaib Hussain, MD, DNB  
Consultant Radiologist  
Reg No - 26584 (AMC)

Date: 27-Jan-2024 17:01:25

**Apollo**  
HOSPITALS  
GUWAHATI  
TOUCHING LIVES

S Hazarika, MD R. Baruah, DMRD P. Hatimota, MD R. Sarmah, MD A. Agarwal, MD M. Gohain, MD, S. Choudhury, MD Zohaib Hussain MD DNB  
*Discrepancy or transcription error if detected should be sent for correction*

APOLLO HOSPITALS GHY  
RG BARUAH ROAD  
GUWAHATI

Station  
Telephone:

## EXERCISE STRESS TEST REPORT

Patient Name: MRS. PUSPĀ SONOWAL,  
Patient ID: 46181  
Height:  
Weight:

DOB: 21.11.1992  
Age: 31yrs  
Gender: Female  
Race: Indian

Study Date: 27.01.2024  
Test Type: --  
Protocol: BRUCE

Referring Physician: --  
Attending Physician: --  
Technician: --

Medications:

--

Medical History:

--

Reason for Exercise Test:

--

### Exercise Test Summary

Phase Name	Stage Name	Time in Stage	Speed (km/h)	Grade (%)	HR (bpm)	BP (mmHg)	Comment
PRETEST	SUPINE	00:50	0.00	0.00	93	120/80	
	STANDING	00:18	0.00	0.00	77		
	HYPERV.	00:02	0.00	0.00	75		
EXERCISE	WARM-UP	00:06	1.00	0.00	68		
	STAGE 1	03:00	2.80	10.00	111	130/80	
	STAGE 2	03:00	4.00	12.00	131	130/80	
	STAGE 3	03:00	5.50	14.00	150	136/80	
	STAGE 4	00:47	6.80	16.00	164	140/80	
RECOVERY		03:12	0.00	0.00	100	110/80	

The patient exercised according to the BRUCE for 9:46 min:s, achieving a work level of Max. METS: 12.70. The resting heart rate of 69 bpm rose to a maximal heart rate of 164 bpm. This value represents 86 % of the maximal, age-predicted heart rate. The resting blood pressure of 120/80 mmHg, rose to a maximum blood pressure of 140/80 mmHg. The exercise test was stopped due to Target heart rate achieved.

### Interpretation

Summary: Resting ECG: normal.  
Functional Capacity: normal.  
HR Response to Exercise: appropriate.  
BP Response to Exercise: normal resting BP - appropriate response.  
Overall impression: Normal stress test.

### Conclusions

TMT IS NEGATIVE FOR INDUCIBLE MYOCARDIAL ISCHAEMIA.

Physician DR. MOITREYEE BARUAH  
MBBS, PGDCC  
Jr. Consultant Cardiologist  
Apollo Hospitals, Guwahati  
Unit: International Heart  
Technician

Patient Details : Mrs. PUSPA SONOWAL | Female | 31Yr 0Mth 0Days

UHID : AHLG2.0000036834 Patient Location: AHC

Patient Identifier: APHCAH20929



DRN : 100016487

Completed on : 27-JAN-2024 08:54


Ref Doctor : Dr. Prabin Kumar Saikia

ECG

IMPRESSION .:

ECG TRACING IS WITHIN NORMAL LIMITS

--- END OF THE REPORT ---

  
DR. MOTTREYEE BARUAH  
MBBS, PGDCC  
Jr. Consultant Cardiologist  
Apollo Hospitals, Guwahati  
Unit: International Hospital