



HEALTH CHECK-UP SUMMARY

Name: Shravy Sahay

Date: 10/02/2024

Email ID:

Sex: Male Age: 40 Years Contact No: 9049600665 Remarks:

Under-weight	-
Normal	-
Over-weight	✓

i> BMI

Height (in Cm): <u>174</u>	Weight (in Kg): <u>81</u>	BMI: <u>26.8</u>
Hip (in Cm): <u>99</u>	Waist (in Cm): <u>92</u>	Hip to Waist Ratio: <u>1.07</u>

ii> Blood Pressure & Pulse

160/90 mm/hg
78/min Regular

If high or low, whether the person is on medication: YES / (NO)

iii> Blood Tests & Lung Function Remarks

PS
CVS
CNS } ⊕

If abnormal, whether the person is on medication: YES / (NO)

iv> Eye Test Remarks

Eye Sight: (R) 6/9 (L) 6/9 with specs

Color Vision: (2)

v> Heart Disease

Whether any specific heart ailment detected (ECG findings):

NAD

vi> Any other problems needing attention / Overall Assessment:

Hypothyroidism

Chirag Patel
Dr. Chirag Patel
M.B.B.S. G-49432

ⓐ Shravy Sahay

Revival Diagnostic
401, Aqua Corridor,
B/s. Star Bazar, Surat-395009
No. 8106228601

Laboratory Test Result are Subject to technical limitation and should be clinically correlate for final diagnosis

📍 4th Floor, Aqua Corridor, Hazira Road, Adajan Pal, Surat-395009.

☎ 0261 2747788, 9825947712 ✉ revivaldiagnostics.surat@gmail.com 🌐 www.revivaldiagnostics.com

This medical report is not intended for medico-legal purposes.



Department Of Ophthalmology

Demographic Information:

EMP ID :		SR.NO :	
Name :	Sunny Sahay	Date :	10/02/2024
Age :	40 yrs		
Sex :	Male		
Department :			

EYE TEST

1. VISION :-

RIGHT EYE :- 6/9 J with spec

LEFT EYE :- 6/9

2. COLOR VISION :-

RIGHT EYE :- (2)

LEFT EYE :- (2)

3. NIGHT VISION :-

RIGHT EYE :- (2)

LEFT EYE :- (2)

REMARKS :-

NO

Revival Diagnostic
 401, Aqua Corridor,
 J/S. Star Bazar, Surat-395009
 Mo. 91062-28601

Laboratory Test Result are Subject to technical limitation and should be clinically correlate for final diagnosis

4th Floor, Aqua Corridor, Hazira Road, Adajan Pal, Surat-395009.

0261 2747788, 9825947712 revivaldiagnostics.surat@gmail.com www.revivaldiagnostics.com

This medical report is not intended for medico-legal purposes.



REVIVAL DIAGNOSTICS

Name	SUNNY SAHAY	Age/Gender	40Yrs/Male
Reg No.	1278/24	Receipt No	16800
Referred By	Bank of Baroda (BOB) - MEDI WHEEL()	Mode of Payment	CREDIT
Collection Type	CENTER	Collection DateTime	10-Feb-2024 09:11 AM

BLOOD GROUP - 100224564 Released at 10-Feb-2024 12:52 PM

Parameter	Result	Biological Ref.Range	Method
-Blood Group	"O"		
-Rh Factor	POSITIVE		

CBC - 100224564 Released at 10-Feb-2024 01:13 PM

Parameter	Result	Biological Ref.Range	Method
-Haemoglobin	14.0 gm/dL	(13.5 - 18 gm/dL)	Auto
-RBC Count	4.91 mill/cumm	(4.6 - 6.2 mill/cumm)	Auto
-Total WBC Count	7300 /cumm	(4000 - 10000 /cumm)	Auto
-Platelet Count	1.69 lakh/cumm	(1.5 - 4.5 lakh/cumm)	Auto

Blood Indices


-HCT	44.1 %	(40 - 55 %)	Auto
-MCV	89.8 fl	(80 - 92 fl)	Auto
-MCH	28.4 pg	(27 - 31 pg)	Auto
-MCHC	31.7 gm/dL	L (32 - 36 gm/dL)	Auto
-RDW	13.2 %	(11 - 15 %)	Auto

Diff WBC Count

-Polymorphs	66 %	(40 - 80 %)	Microscopically
-Lymphocytes	30 %	(20 - 40 %)	Microscopically
-Eosinophils	02 %	(1 - 6 %)	Microscopically
-Monocytes	02 %	(2 - 7 %)	Microscopically
-Basophils	00 %	(0 - 1 %)	Microscopically
-PLATELET ON SMEAR	Adequate		Microscopically
-MALARIAL PARASITES	Malarial Parasites Not Detected		Microscopically

[Test performed on Fully Automated Hematology Analyzer ERBA H-360]

Revival Diagnostics
401-Aqua Corridor,
Beside Star Bazar, Adajan,
Surat-395009. Mo. 9825947712


Dr. Shivangi Gandhi
M.B.B.S, M.D (Pathology)

 0261-2747788, 98259 47712

 4th Floor, Aqua Corridor, Hazira Road, Adajan Pal, Surat - 395009.

 revivaldiagnostics.surat@gmail.com

 www.revivaldiagnostics.com

This Medical Report is Not Intended for Medico-legal Purposes. Laboratory Test Results are Subject to Technical limitation and Should be Clinically Correlate for Final Diagnosis



REVIVAL DIAGNOSTICS

Name	SUNNY SAHAY	Age/Gender	40Yrs/Male
Reg No.	1278/24	Receipt No	16800
Referred By	Bank of Baroda (BOB) - MEDI WHEEL()	Mode of Payment	CREDIT
Collection Type	CENTER	Collection DateTime	10-Feb-2024 09:11 AM

ESR - 100224564 Released at 10-Feb-2024 01:13 PM

Parameter	Result	Biological Ref.Range	Method
-E.S.R	02 mm/hr	(1 - 10 mm/hr)	

Revival Diagnostics
401-Aqua Corridor,
Beside Star Bazar, Adajan,
Surat-395009. Mo. 9825947712

Dr. Shivangi Gandhi
M.B.B.S, M.D (Pathology)

0261-2747788, 98259 47712

4th Floor, Aqua Corridor, Hazira Road, Adajan Pal, Surat - 395009.

revivaldiagnostics.surat@gmail.com

www.revivaldiagnostics.com



REVIVAL DIAGNOSTICS

Name	SUNNY SAHAY	Age/Gender	40Yrs/Male
Reg No.	1278/24	Receipt No	16800
Referred By	Bank of Baroda (BOB) - MEDI WHEEL()	Mode of Payment	CREDIT
Collection Type	CENTER	Collection DateTime	10-Feb-2024 09:11 AM

FBS & PPBS - 100224565 Released at 10-Feb-2024 01:13 PM

Parameter	Result	Biological Ref.Range	Method
-Fasting Blood Sugar (FBS)	94 mg/dL	70-100 mg/dl Impaired Tolerance: 100-125 Diabetes Mellitus: \geq 126 (American diabetes association guidelines 2022)	
-Fasting Urine Sugar	Absent		
-Fasting Urine Acetone	Absent		
-PPBS	118 mg/dL	(90 - 140 mg/dL)	
-PP2BS URINE SUGAR	Absent		
-PP2BS URINE ACETONE	Absent		

HBA1C - 100224564 Released at 10-Feb-2024 01:13 PM

Parameter	Result	Biological Ref.Range	Method
-HBA1C	5.3 %	HbA1C Degree of Glucose Control <5.6 % Non Diabetics 5.7 - 6.4 % Prediabetics > =6.5 % Diabetics (REF:Wallace, 11th Edition) REMARKS: 6 - 7 % Excellent Control 7 - 8 % Good Control 8 - 10 % Unsatisfactory Control >10 % Poor Control	Immuno-Turbidometry method
-Method[]		High Performance Liquid Chromatography (HPLC)	

Revival Diagnostics
401-Aqua Corridor,
Beside Star Bazar, Adajan,
Surat-395009. Mo. 9825947712

Dr. Shivangi Gandhi
M.B.B.S, M.D (Pathology)

0261-2747788, 98259 47712

4th Floor, Aqua Corridor, Hazira Road, Adajan Pal, Surat - 395009.

revivaldiagnostics.surat@gmail.com

www.revivaldiagnostics.com



REVIVAL DIAGNOSTICS

Name	SUNNY SAHAY	Age/Gender	40Yrs/Male
Reg No.	1278/24	Receipt No	16800
Referred By	Bank of Baroda (BOB) - MEDI WHEEL()	Mode of Payment	CREDIT
Collection Type	CENTER	Collection DateTime	10-Feb-2024 09:11 AM

TOTAL PROTEIN - 100224566 Released at 10-Feb-2024 11:19 AM

Parameter	Result	Biological Ref.Range	Method
-Protein	6.8 g/dL	(6.4 - 8.3 g/dL)	Biuret
-Albumin (ALB)	4.4 gm/dL	(3.5 - 5.2 gm/dL)	BCG
-Globulin	2.4 gm/dL	(2.3 - 3.6 gm/dL)	Calculated
-A/G Ratio	1.83 gm/dL	(1 - 2.3 gm/dL)	Calculated

Bilirubin - 100224566 Released at 10-Feb-2024 01:14 PM

Parameter	Result	Biological Ref.Range	Method
-Serum Total Bilirubin	0.6 mg/dL	(0 - 1.3 mg/dL)	DIAZO
-Serum Direct Bilirubin	0.2 mg/dL	(0 - 0.4 mg/dL)	DIAZO
-Serum InDirect Bilirubin	0.4 mg/dL	(0.1 - 1.3 mg/dL)	Calculated

Alkaline Phosphatase - 100224566 Released at 10-Feb-2024 01:13 PM

Parameter	Result	Biological Ref.Range	Method
-Alkaline Phosphate	92 U/L	(53 - 128 U/L)	4-NPP with AMP Buffer

Uric Acid - 100224563 Released at 10-Feb-2024 01:13 PM

Parameter	Result	Biological Ref.Range	Method
-Uric Acid	7.5 mg/dL	H (3.5 - 7.2 mg/dL)	Uricase-POD

Revival Diagnostics

401-Aqua Corridor,
Beside Star Bazar, Adajan,
Surat-395009. Mo. 9825947712

Sg

Dr. Shivangi Gandhi
M.B.B.S, M.D (Pathology)

0261-2747788, 98259 47712

4th Floor, Aqua Corridor, Hazira Road, Adajan Pal, Surat - 395009.

revivaldiagnostics.surat@gmail.com

www.revivaldiagnostics.com



REVIVAL DIAGNOSTICS

Name	SUNNY SAHAY	Age/Gender	40Yrs/Male
Reg No.	1278/24	Receipt No	16800
Referred By	Bank of Baroda (BOB) - MEDI WHEEL()	Mode of Payment	CREDIT
Collection Type	CENTER	Collection DateTime	10-Feb-2024 09:11 AM

Lipid Profile - 100224566 Released at 10-Feb-2024 01:13 PM

Parameter	Result	Biological Ref.Range	Method
-Serum Cholesterol	186 mg/dL	Desirable < 200 mg/dl Borderline High : 200-239 mg/dl High : > 240 mg/dl	CHOD-PAP
-Serum Triglyceride	202 mg/dL	H Normal < 150 mg/dl Borderline High : 150 - 199 mg/dl High : 200 - 499 mg/dl Very High : 500 mg/dl	GPO-POD Method
-Serum HDLD(Direct)	46 mg/dL	Normal :> 55 mg/dl Borderline : 35-55 mg/dl Undesirable: < 35 mg/dl	PVS-PEGME Precipitation with CHOD-POD
-Serum VLDL	40 mg/dL	H (5 - 30 mg/dL)	Calculated
-Serum LDL(Direct)	100 mg/dL	Optimal:< 100 mg/dl Above Optimal : 100- 129 mg/dl Borderline High : 130-159 mg/dl High : > 160-189mg/dl Very High : >190 mg/dl	Calculated
-Chol/HDL	4.04	Low risk: <3.8 Medium Risk: 3.8 to 5.9 High Risk: > 6	Calculated
-LDL/Chol	1.87	Low risk: <3.55 Medium Risk: 3.55 to 4.0 High Risk: > 6	Calculated

[Test performed on Fully Automated Biochemistry Analyzer ERBA EM200]

Revival Diagnostics
401-Aqua Corridor,
Beside Star Bazar, Adajan,
Surat-395009. Mo. 9825947717

☎ 0261-2747788, 98259 47712

📍 4th Floor, Aqua Corridor, Hazira Road, Adajan Pal, Surat - 395009.

Dr. Shivangi Gandhi
M.B.B.S, M.D (Pathology)

@ revivaldiagnostics.surat@gmail.com

🌐 www.revivaldiagnostics.com



REVIVAL DIAGNOSTICS

Name	SUNNY SAHAY	Age/Gender	40Yrs/Male
Reg No.	1278/24	Receipt No	16800
Referred By	Bank of Baroda (BOB) - MEDI WHEEL()	Mode of Payment	CREDIT
Collection Type	CENTER	Collection DateTime	10-Feb-2024 09:11 AM

Urine Routine & Micro Examination - 100224567 Released at 10-Feb-2024 01:02 PM

Parameter	Result	Biological Ref.Range	Method
Physical Examination			
-Quantity	25		Manual
-Colour	Pale Yellow	Pale Yellow	Manual
-Appearance	Clear	Clear	Manual
-Reaction (pH)	Acidic		Dipstick
-Specific Gravity	1.025		Dipstick
Chemical Examination			
-Proteins.	Absent		Dipstick
-Sugar	Absent		Dipstick
-Acetone.	Absent		Dipstick
-Bile Salts	Absent	Absent	Dipstick
-Bile Pigments	Absent	Absent	Dipstick
-Occult Blood Test (OBT).	Negative		Dipstick
Microscopic Examination			
-Pus Cells	1-2		Microscopically
-Red Blood Cells	Absent		Microscopically
-Epithelial Cells	1-2		Microscopically
-Bacteria.	Absent		Microscopically
-Crystals	Absent	Absent	Microscopically
-Others	NIL	Absent	Microscopic Examination

Revival Diagnostics
401-Aqua Corridor,
Beside Star Bazar, Adajan,
Surat-395009. Mo. 9825947717

Dr. Shivangi Gandhi
M.B.B.S, M.D (Pathology)

0261-2747788, 98259 47712

4th Floor, Aqua Corridor, Hazira Road, Adajan Pal, Surat - 395009.

revivaldiagnostics.surat@gmail.com

www.revivaldiagnostics.com



REVIVAL DIAGNOSTICS

Name	SUNNY SAHAY	Age/Gender	40Yrs/Male
Reg No.	1278/24	Receipt No	16800
Referred By	Bank of Baroda (BOB) - MEDI WHEEL()	Mode of Payment	CREDIT
Collection Type	CENTER	Collection DateTime	10-Feb-2024 09:11 AM

Total T3 T4 TSH - 100224566 Released at 10-Feb-2024 12:44 PM

Parameter	Result	Biological Ref.Range	Method
-Total T3	0.99 ng/ml	(0.87 - 1.78 ng/ml)	Fluorescence Enzyme Immunoassay
-Total T4	8.19 ug/dl	(4.6 - 11 ug/dl)	Fluorescence Enzyme Immunoassay
-TSH	1.98 uIU/ml	0.50 - 5.50 uIU/ml 5.5 to 15 ul U/ml - Suggested Clinical co-relation or Repeat test with new sample as physiological factors can give falslely high TSH Above 15uIU/ml Hypopyhyroid PREGNANT WOMEN normal ranges for TSH: 1st Trimester : 0.0878 - 2.8293 uIU/ml 2nd Trimester : 0.1998 - 2.7915 uIU/ml 3rd Trimester : 0.307 - 2.9028 uIU/ml Ref: TIETZ Fundamentals of Clinical Chemistry	Fluorescence Enzyme Immunoassay

[Test performed on Fully Automated Immunology Analyzer Maglumi-600]

Revival Diagnostics

401-Aqua Corridor,
Beside Star Bazar, Adajan,
Surat-395009. Mo. 9825947712

 0261-2747788, 98259 47712

 4th Floor, Aqua Corridor, Hazira Road, Adajan Pal, Surat - 395009.

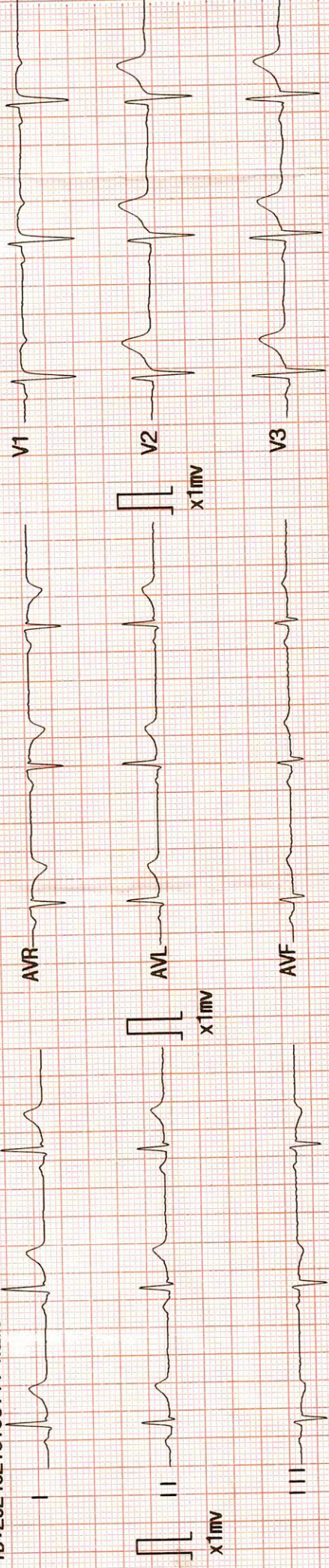
Sg

Dr. Shivangi Gandhi
M.B.B.S, M.D (Pathology)

 revivaldiagnostics.surat@gmail.com

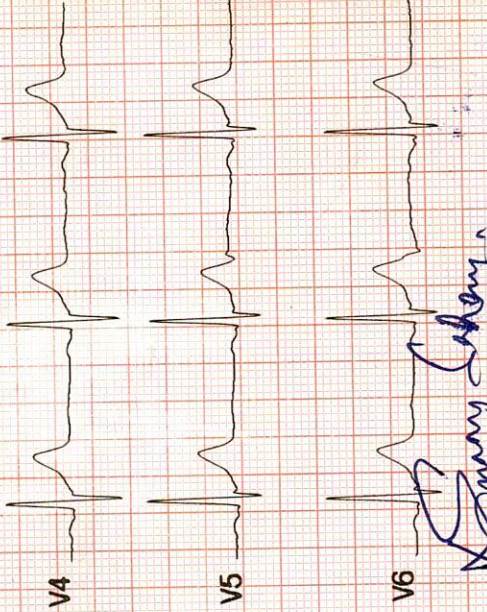
 www.revivaldiagnostics.com

ID: 20240210105144 Name: --- 25mm/s 0.5-35Hz AC: off 10mm/mv



Organization: --- Doctor: ---

ID	: 20240210105144	001: Sinus Rhythm
Name	: <i>S. G. G. G.</i>	171: Normal ECG
Sex	: <input checked="" type="checkbox"/> male	
Age	: 40	
HR	: 62 bpm	
R-R	: 962 ms	
P-R	: 156 ms	Reference Report Confirmed b
QRS	: 83 ms	
QT/QTc	: 374/382 ms	
P/QRS/T	: 38/ 5/ 20	02-10-2024 10:52:03
RV5/SV1	: 1.018/-0.881 mV	
RV5+SV1	: 0.137 mV	
QTcf	: 0.388	



S. G. G. G.

Revival Diagnostics
 401-Aqua Cortidor,
 Beside Star Bazar, Adajan,
 Surat-395009. Mo. 9825947712

DR. ADITYA S. BORA
 MBBS, DNB, PGDCC
 PHYSICIAN & CLINICAL CARDIOLOGIST
 G-54906



REVIVAL DIAGNOSTICS


Name	SUNNY SAHAY	Age/Gender	40Yrs/Male
Reg No.	1278/24	Receipt No	16800
Referred By	Bank of Baroda (BOB) - MEDI WHEEL()	Mode of Payment	CREDIT
Collection Type	CENTER	Collection DateTime	10-Feb-2024 08:40 AM

Ecg

1. The rhythm is sinus.
2. Heart rate is 62 beats per minute.
3. Normal P,QRS,T wave axis.
4. Normal PR,QRS,Q.T. Duration.
5. No pathological q wave or ST-T changes seen.
6. No evidence of chamber hypertrophy or enlargement seen.

IMPRESSION : ECG WITHIN NORMAL LIMITS

Revival Diagnostics
401-Aqua Corridor,
Beside Star Bazar, Adajan,
Surat-395009. Mo. 9825947712


DR. ADITYA S. BORA
MBBS, DNB, PGCC
PHYSICIAN & CLINICAL CARDIOLOGIST
G-54906
Signature



REVIVAL DIAGNOSTICS

Name	SUNNY SAHAY	Age/Gender	40Yrs/Male
Reg No.	1278/24	Receipt No	16800
Referred By	Bank of Baroda (BOB) - MEDI WHEEL()	Mode of Payment	CREDIT
Collection Type	CENTER	Collection DateTime	10-Feb-2024 08:40 AM

2D ECHO

2D ECHOCARDIOGRAPHY & COLOR DOPPLER REPORT

INDICATION: Preventive Health check up

- **CARDIAC CHAMBERS :** Left Ventricle : Normal size , Left Atrium: Normal size.
- NO e/o thrombus in LA/LV
- Right Atrium: Normal size. Right Ventricle: Normal Size,
- **Normal Right Ventricular function.** (TAPSE=20mm)
- **Normal Left Ventricular systolic function.** LVEF = 60%
- **No regional wall abnormality. No thinning / scarring / dyskinesia of LV wall**
- **Concentric Left Ventricular Hypertrophy.** (IVSd= 11 mm),
- **LV Compliance:**
- **NO Left Ventricular Diastolic Dysfunction [LVDD].**

VALVES :

- Structurally Normal Mitral valve/ Aortic valve/Tricuspid valve/ Pulmonary valve .
- No significant Valvular Stenosis
- **Doppler findings: AV max = 1.23 m/s, PV max = 0.91 m/s.**
- Trivial MR, Trivial Tricuspid regurgitation.
- **No Pulmonary Arterial Hypertension.** PASP by TRjet vel.method = 24 mmHg.
- **SEPTAE:** IAS / IVS Appear Intact.
- **IVC :** Normal in dimension and shows good inspiratory 13mm collapse.
- **OTHERS:** No e/o Pericardial effusion / vegetation.

IMPRESSION:

**NORMAL LV SYSTOLIC FUNCTION, LVEF= 60 %, NO RWMA,
MILD LVH , NO LVDD , NO PAH.**

Revival Diagnostics

401-Aqua Corridor,
Beside Star Bazar, Adajan,
Surat-395009. Mo. 9825947712


DR. ADITYA S. BORA
MBBS, DNB, PGDCC
PHYSICIAN & CLINICAL CARDIOLOGIST
G-54906

10-02-24, 13:28

R

NAME : SUNNY SAHAY
AGE: 40 YRS / MALE
REF BY: MEDI WHEEL





REVIVAL DIAGNOSTICS

Name	SUNNY SAHAY	Age/Gender	40Yrs/Male
Reg No.	1278/24	Receipt No	16800
Referred By	Bank of Baroda (BOB) - MEDI WHEEL()	Mode of Payment	CREDIT
Collection Type	CENTER	Collection DateTime	10-Feb-2024 08:40 AM

CHEST RADIOGRAPH (PA VIEW)

- Hilar shadows are within normal limits.
- Pulmonary vasculature appears normal.
- Cardiac appears normal in size.
- Both dome of the diaphragm are smooth.
- Both costophrenic recesses are clear.
- Both lung fields appear normal.
- Visualized bones and soft tissue shadows appear normal.

IMPRESSION: NORMAL STUDY.

DR. CHIRAG K PATEL
RADIOLOGIST

Dr. Chirag K. Patel

MBBS-DMPD

Reg. No. G-23509

Revival Diagnostics
Signature

4th Floor, Aqua Corridor,

Nr. Star Bazar, Hazira Main Road,

Adajan, Surat-395009.

Mo. 97266 726683

 0261-2747788, 98259 47712

 4th Floor, Aqua Corridor, Hazira Road, Adajan Pal, Surat - 395009.

 revivaldiagnostics.surat@gmail.com

 www.revivaldiagnostics.com



REVIVAL DIAGNOSTICS

Name	SUNNY SAHAY	Age/Gender	40Yrs/Male
Reg No.	1278/24	Receipt No	16800
Referred By	Bank of Baroda (BOB) - MEDI WHEEL()	Mode of Payment	CREDIT
Collection Type	CENTER	Collection DateTime	10-Feb-2024 08:40 AM

USG OF ABDOMEN & PELVIS

LIVER:

Liver is normal in size and increased echotexture.

No evidence of focal SOL or dilatation of IHBR seen.

Portahepatis appear normal.

GALLBLADDER:

Gallbladder distended and shows 14 mm calculus within it

PANCREAS:

Pancreas appears normal in size and echotexture.

No focal lesion, mass or pancreatitis.

SPLEEN:

Spleen appears normal in size and echotexture.

PARAAORTIC REGION:

Aorta grossly appears normal.

No paraaortic lymphnodes seen.

KIDNEYS:

left renal small cyst

Both kidneys appear normal in size, shape and in position.

Cortex and collecting system of both kidneys appears normal.

No evidence of calculus or obstructive uropathy on either side.

URINARY BLADDER:

Bladder appears normal. No calculus or mass lesion is seen.

PROSTATE:

Prostate appears normal in size and echotexture.

No evidence of free fluid in pelvis.

COMMENTS:

fatty liver

gall bladder calculus

Dr. Chirag K. Patel

MBBS-DMPD

Reg. No. G-23509

Revival Diagnostic

4th Floor, Aqua Corridor,

Nr. Star Bazar, Radiologist,

Adajan, Surat-395009.

Mo. 97266 726683



0261-2747788, 98259 47712



4th Floor, Aqua Corridor, Hazira Road, Adajan Pal, Surat - 395009.



revivaldiagnostics.surat@gmail.com



www.revivaldiagnostics.com