

Acc no:4182XB008711	Name: Mrs. Ramya	Age: 41 y	Sex: Female	Date:24.02.24
---------------------	------------------	-----------	-------------	---------------

**RADIOLOGY DIVISION**

**US SCAN WHOLE ABDOMEN (TAS + TVS)**

**LIVER** is enlarged in size (16.7 cm). Margins are regular. **Hepatic parenchyma shows increased echogenicity.** No focal lesions seen. No dilatation of intrahepatic biliary radicles. CBD is not dilated. Portal vein is normal in caliber (10.7 mm).

**GALL BLADDER** is distended and lumen clear. No calculi / polyp noted. Wall thickness is normal. No pericholecystic fluid seen.

**SPLEEN** is borderline enlarged in size (12 cm) and shows normal parenchymal echotexture. No focal lesion seen.

**PANCREAS** Head and body visualized, appears normal in size and parenchymal echotexture. Pancreatic duct is not dilated.

**RIGHT KIDNEY** is normal in size (10.3 x 4.7 cm) and shows normal parenchymal echotexture. Cortico medullary differentiation is maintained. Parenchymal thickness is normal. No echogenic focus with shadowing suggestive of renal calculi seen. No dilatation of pelvicalyceal system seen. Ureter is not dilated. Perinephric spaces are normal.

**LEFT KIDNEY** is normal in size (11.3 x 4.2 cm) and shows normal parenchymal echotexture. Cortico medullary differentiation is maintained. Parenchymal thickness is normal. No echogenic focus with shadowing suggestive of renal calculi seen. No dilatation of pelvicalyceal system seen. Ureter is not dilated. Perinephric spaces are normal.

**PARAAORTIC AREA** No retroperitoneal lymphadenopathy or mass seen.

**URINARY BLADDER** is distended, normal in wall thickness, lumen clear.

**UTERUS** is bulky in size measures 8.9 x 3.9 x 4.2 cm, myometrial echopattern is inhomogeneous. No focal lesions seen. Endometrial thickness is 11.2 mm. **Nabothian cysts noted in cervix largest measuring 1 x 0.6 cm. Sub endometrial tiny cysts noted.**

Both ovaries are normal. Right ovary vol - 7.4 cc and shows *dominant follicle measuring 1.5 x 1.5 cm.* Left ovary vo - 6.9 cc. No adnexal mass seen. No fluid in pouch of Douglas.

No ascites or pleural effusion.

**Gaseous distension of bowel loops noted. No obvious bowel wall thickening seen sonologically.**

**CONCLUSION:-**

- **Hepatomegaly with grade II / III fatty changes - Correlate with LFT.**
- **Borderline splenomegaly - Suggest clinical correlation.**
- **Possibility of adenomyosis uterus. D / D - seedling fibroids**

Duplicate copy

  
**Dr. Nisha Unni MD, DNB (RD)**  
Consultant radiologist.

Thanks for referral. Your feedback will be appreciated.

(Please bring relevant investigation reports during all visits)

Because of technical and technological limitations complete accuracy cannot be assured on imaging.

Suggested correlation with clinical findings and other relevant investigations, consultations, and if required repeat imaging recommended in the event of controversies. AR

DDRC Agilus Pathlabs Limited.  
Corp. Office - Express House, Second Floor, Opp. Rothys Silks, Banerjee Road, Kaloor - 682017  
Contact :- 93334 93334, Web :- www.ddrcagilus.com Email :- info.ddrc@agilus.in

**ECHO REPORT**

**RADIOLOGY DIVISION**

SRD No :XB008711	Name:RAMYA	Age:41Y	Sex:F	Date: 24/02/24
------------------	------------	---------	-------	----------------

**Left Ventricle:-**

	Diastole	Systole
IVS	1.09cm	1.24cm
LV	4.42cm	2.99cm
LVPW	1.16cm	1.24cm

EF -66%      FS- 35%

AO	LA
3.15cm	3.41cm

PV            -    0.96m/s  
AV            -    1.19m/s  
MVE          -    1.03m/s  
MVA          -    0.76m/s  
E/A           -    1.36

**IMPRESSION:-**

- Normal chambers dimension
- No RWMA
- Good LV systolic function
- No diastolic dysfunction
- No AS,AR,MR,MS,TR,PAH
- IAS/IVS intact.No clots/effussion/coarctation



**Dr. SAJITH. K**  
MD,DNB

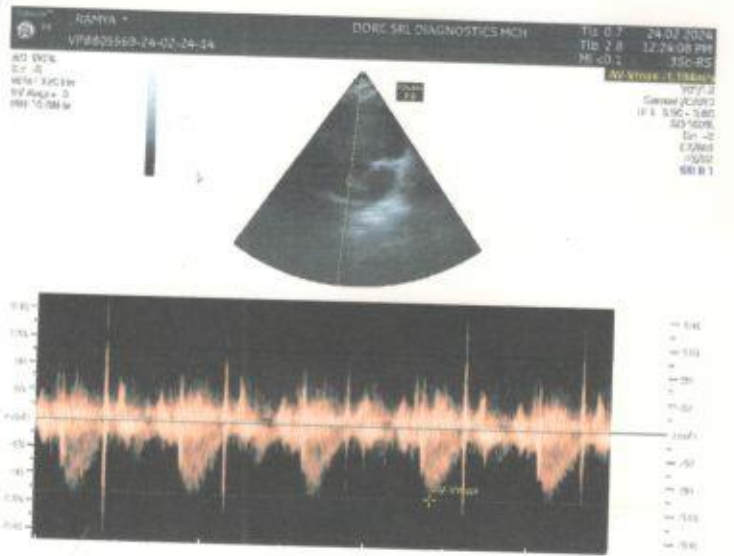
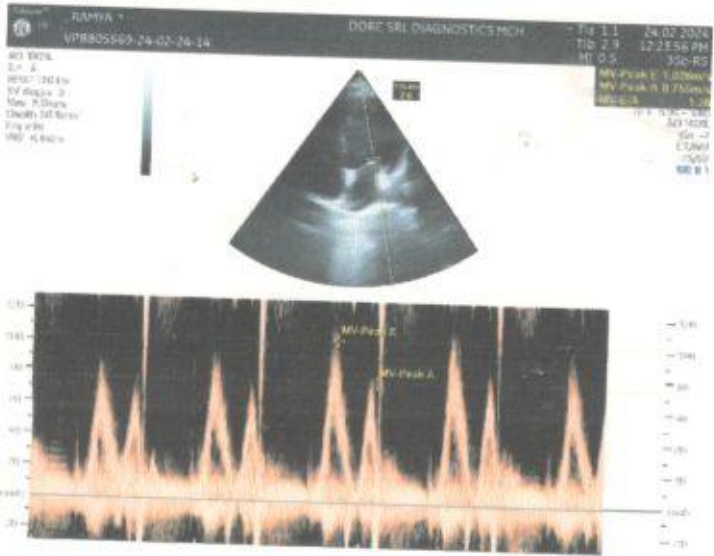
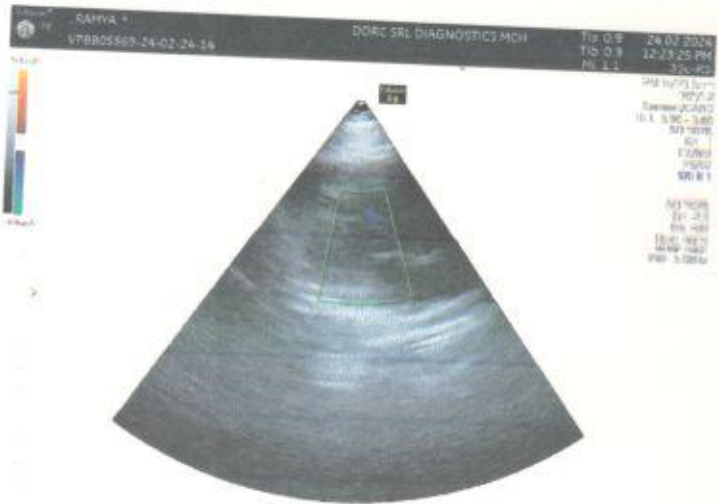
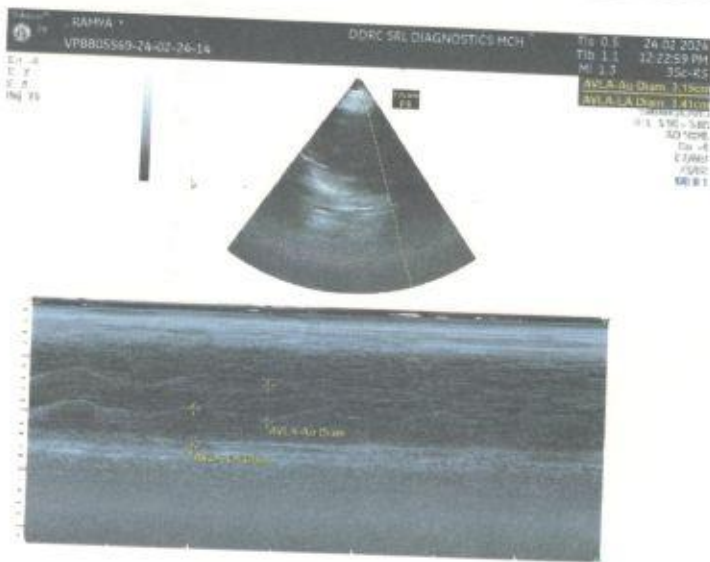**CONSULTANT CARDIOLOGIST**  
Reg.No: 19436

*(Handwritten signature)*

*Consultant Cardiologist*

**DDRC agilus Pathlabs Limited.**





PATIENT NAME : RAMYA

REF. DOCTOR : SELF

CODE/NAME &amp; ADDRESS : CA00010147 -

MEDIWHEEL ARCOFEMI HEALTHCARE LIMITED  
F701A, LADO SARAI, NEW DELHI,SOUTH DELHI,  
DELHI,  
SOUTH DELHI 110030  
8800465156ACCESSION NO : **4182XB008711**

PATIENT ID : RAMYF2511834021

CLIENT PATIENT ID:

ABHA NO :

AGE/SEX : 41 Years Female

DRAWN :

RECEIVED : 24/02/2024 09:56:20

REPORTED : 27/02/2024 09:52:39

Test Report Status **Final**

Results

Biological Reference Interval Units

**MEDIWHEEL HEALTH CHECKUP ABOVE 40(F)2DECHO****PHYSICAL EXAMINATION**

PHYSICAL EXAMINATION

REPORT GIVEN

**DR NISHA UNNI, MBBS,MD**  
**(RD),DNB (Reg.No:50162)**  
Consultant Radiologist

Page 1 Of 11



View Details



View Report

**PERFORMED AT :**DDRC AGILUS PATHLABS LIMITED  
ASTER SQUARE BUILDING, ULLOOR,  
MEDICAL COLLEGE P.O  
TRIVANDRUM, 695011  
KERALA, INDIA  
Tel : 93334 93334, Fax : CIN - U85190MH2006PTC161480  
Email : customercare.ddrc@agilus.in

Patient Ref. No. 66600007978576

PATIENT NAME : RAMYA

REF. DOCTOR : SELF

CODE/NAME &amp; ADDRESS : CA00010147 -

MEDIWHEEL ARCOFEMI HEALTHCARE LIMITED  
F701A, LADO SARAI, NEW DELHI,SOUTH DELHI,  
DELHI,  
SOUTH DELHI 110030  
8800465156ACCESSION NO : **4182XB008711**

PATIENT ID : RAMYF2511834021

CLIENT PATIENT ID:

ABHA NO :

AGE/SEX : 41 Years Female

DRAWN :

RECEIVED : 24/02/2024 09:56:20

REPORTED : 27/02/2024 09:52:39

Test Report Status **Final**

Results

Units

**MEDIWHEEL HEALTH CHECKUP ABOVE 40(F)2DECHO****ECG WITH REPORT****REPORT****REPORT GIVEN****2D - ECHO WITH COLOR DOPPLER****REPORT****REPORT GIVEN****USG ABDOMEN AND PELVIS****REPORT****REPORT GIVEN****CHEST X-RAY WITH REPORT****REPORT****REPORT GIVEN****MAMMOGRAPHY -BOTH****REPORT****REPORT GIVEN****HAEMATOLOGY****MEDIWHEEL HEALTH CHECKUP ABOVE 40(F)2DECHO****GLYCOSYLATED HEMOGLOBIN(HBA1C), EDTA WHOLE BLOOD**

HBA1C

5.4

Non-diabetic Adult &lt; 5.7

%

Pre-diabetes 5.7 - 6.4

*Nisha***DR.NISHA UNNI, MBBS,MD  
(RD),DNB (Reg.No:50162)  
Consultant Radiologist***Hari Shankar***DR.HARI SHANKAR, MBBS MD  
(Reg No - TCMC:62092)  
HEAD - Biochemistry &  
Immunology***Vaishali***DR.VAISHALI RAJAN, MBBS DCP  
(Pathology)  
(Reg No - TCC 27150)  
HOD - HAEMATOLOGY**

View Details



View Report

Page 2 Of 11

**PERFORMED AT :**DDRC AGILUS PATHLABS LIMITED  
ASTER SQUARE BUILDING, ULLOOR,  
MEDICAL COLLEGE P.O  
TRIVANDRUM, 695011  
KERALA, INDIA  
Tel : 93334 93334, Fax : CIN - U85190MH2006PTC161480  
Email : customercare.ddrc@agilus.in

Patient Ref. No. 66600007978576

PATIENT NAME : RAMYA

REF. DOCTOR : SELF

CODE/NAME & ADDRESS : CA00010147 -  
MEDIWHEEL ARCOFEMI HEALTHCARE LIMITED  
F701A, LADO SARAI, NEW DELHI, SOUTH DELHI,  
DELHI,  
SOUTH DELHI 110030  
8800465156

ACCESSION NO : **4182XB008711**  
PATIENT ID : RAMYF2511834021  
CLIENT PATIENT ID:  
ABHA NO :

AGE/SEX : 41 Years Female  
DRAWN :  
RECEIVED : 24/02/2024 09:56:20  
REPORTED : 27/02/2024 09:52:39

Test Report Status	Final	Results	Units
		Diabetes diagnosis: > or = 6.5 Therapeutic goals: < 7.0 Action suggested : > 8.0 (ADA Guideline 2021)	
MEAN PLASMA GLUCOSE		108.3 < 116.0	mg/dL

**BLOOD COUNTS, EDTA WHOLE BLOOD**

HEMOGLOBIN	12.1	12.0 - 15.0	g/dL
RED BLOOD CELL COUNT	<b>4.81 High</b>	3.80 - 4.80	mil/ $\mu$ L
WHITE BLOOD CELL COUNT	7.01	4.0 - 10.0	thou/ $\mu$ L
PLATELET COUNT	313	150 - 410	thou/ $\mu$ L

**RBC AND PLATELET INDICES**

HEMATOCRIT	38.1	36.0 - 46.0	%
MEAN CORPUSCULAR VOL	<b>79.2 Low</b>	83.0 - 101	fL
MEAN CORPUSCULAR HGB.	<b>25.2 Low</b>	27.0 - 32.0	pg
MEAN CORPUSCULAR HEMOGLOBIN CONCENTRATION	31.8	31.50 - 34.50	g/dL
RED CELL DISTRIBUTION WIDTH	<b>14.8 High</b>	11.60 - 14.0	%
MENTZER INDEX	16.5		
MEAN PLATELET VOLUME	9.3	6.80 - 10.90	fL

**WBC DIFFERENTIAL COUNT**

SEGMENTED NEUTROPHILS	62	40.0 - 80.0	%
LYMPHOCYTES	31	20.0 - 40.0	%
MONOCYTES	4	2.0 - 10.0	%
EOSINOPHILS	3	1.0 - 6.0	%
BASOPHILS	0	0.0 - 1.0	%
ABSOLUTE NEUTROPHIL COUNT	4.35	2.0 - 7.0	thou/ $\mu$ L



**DR. HARI SHANKAR, MBBS MD**  
(Reg No - TCMC:62092)  
HEAD - Biochemistry &  
Immunology



**DR. VAISHALI RAJAN, MBBS DCP**  
(Pathology)  
(Reg No - TCC 27150)  
HOD - HAEMATOLOGY

Page 3 Of 11



View Details



View Report

**PERFORMED AT :**

DDRC AGILUS PATHLABS LIMITED  
ASTER SQUARE BUILDING, ULLOOR,  
MEDICAL COLLEGE P.O  
TRIVANDRUM, 695011  
KERALA, INDIA  
Tel : 93334 93334, Fax : CIN - U85190MH2006PTC161480  
Email : customercare.ddrc@agilus.in



Patient Ref. No. 66600007978576

PATIENT NAME : RAMYA

REF. DOCTOR : SELF

CODE/NAME & ADDRESS : CA00010147 -  
MEDIWHEEL ARCOFEMI HEALTHCARE LIMITED  
F701A, LADO SARAI, NEW DELHI, SOUTH DELHI,  
DELHI,  
SOUTH DELHI 110030  
8800465156

ACCESSION NO : **4182XB008711**  
PATIENT ID : RAMYF2511834021  
CLIENT PATIENT ID:  
ABHA NO :

AGE/SEX : 41 Years Female  
DRAWN :  
RECEIVED : 24/02/2024 09:56:20  
REPORTED : 27/02/2024 09:52:39

Test Report Status	Final	Results	Units	
ABSOLUTE LYMPHOCYTE COUNT		2.20	1.0 - 3.0	thou/ $\mu$ L
ABSOLUTE MONOCYTE COUNT		0.26	0.20 - 1.0	thou/ $\mu$ L
ABSOLUTE EOSINOPHIL COUNT		0.23	0.02 - 0.50	thou/ $\mu$ L
ABSOLUTE BASOPHIL COUNT		0.00		thou/ $\mu$ L
NEUTROPHIL LYMPHOCYTE RATIO (NLR)		1.9		

**ERYTHROCYTE SEDIMENTATION RATE (ESR), EDTA BLOOD**

SEDIMENTATION RATE (ESR)	15	0 - 20	mm at 1 hr
--------------------------	----	--------	------------

**SUGAR URINE - POST PRANDIAL**

SUGAR URINE - POST PRANDIAL	NOT DETECTED	NOT DETECTED
-----------------------------	--------------	--------------

**SUGAR URINE - FASTING**

SUGAR URINE - FASTING	NOT DETECTED	NOT DETECTED
-----------------------	--------------	--------------

**IMMUNOHAEMATOLOGY**
**MEDIWHEEL HEALTH CHECKUP ABOVE 40(F)2DECHO**
**ABO GROUP & RH TYPE, EDTA WHOLE BLOOD**

ABO GROUP	TYPE A
RH TYPE	POSITIVE

METHOD : COLUMN AGGLUTINATION TECHNOLOGY

&lt;b&gt;Interpretation(s)&lt;/b&gt;

Page 4 Of 11



**DR. HARI SHANKAR, MBBS MD**  
(Reg No - TCMC:62092)  
HEAD - Biochemistry &  
Immunology



**DR. VAISHALI RAJAN, MBBS DCP**  
(Pathology)  
(Reg No - TCC 27150)  
HOD - HAEMATOLOGY



View Details



View Report

**PERFORMED AT :**

DDRC AGILUS PATHLABS LIMITED  
ASTER SQUARE BUILDING, ULLOOR,  
MEDICAL COLLEGE P.O  
TRIVANDRUM, 695011  
KERALA, INDIA  
Tel : 93334 93334, Fax : CIN - U85190MH2006PTC161480  
Email : customercare.ddrc@agilus.in



Patient Ref. No. 66600007978576





**PATIENT NAME : RAMYA**

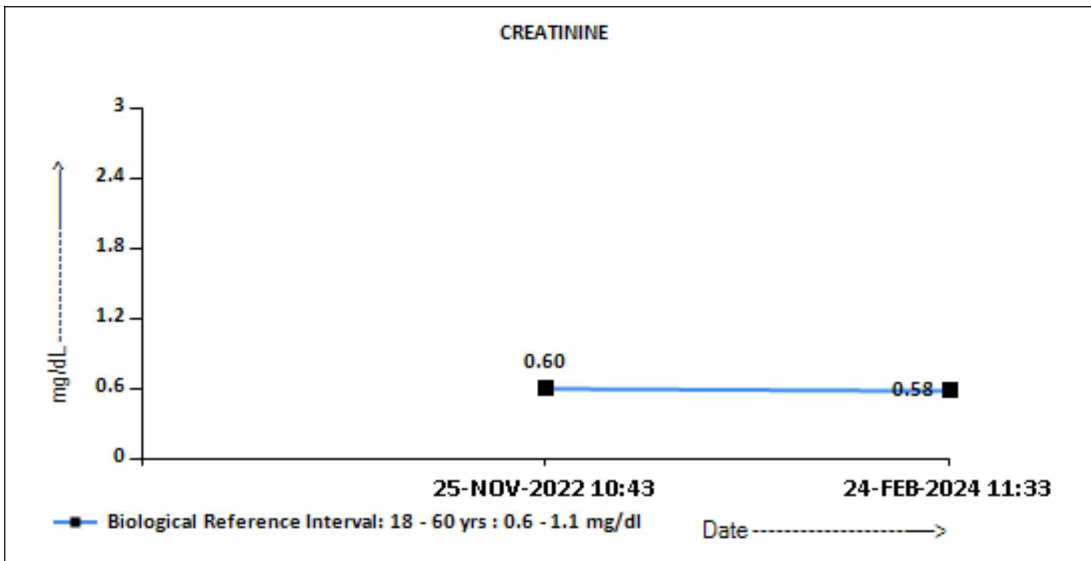
**REF. DOCTOR : SELF**

**CODE/NAME & ADDRESS :** CA00010147 -  
MEDIWHEEL ARCOFEMI HEALTHCARE LIMITED  
F701A, LADO SARAI, NEW DELHI,SOUTH DELHI,  
DELHI,  
SOUTH DELHI 110030  
8800465156

**ACCESSION NO :** **4182XB008711**  
**PATIENT ID :** RAMYF2511834021  
**CLIENT PATIENT ID:**  
**ABHA NO :**

**AGE/SEX :** 41 Years Female  
**DRAWN :**  
**RECEIVED :** 24/02/2024 09:56:20  
**REPORTED :** 27/02/2024 09:52:39

Test Report Status	Final	Results	Units
--------------------	-------	---------	-------



**GLUCOSE, POST-PRANDIAL, PLASMA**

GLUCOSE, POST-PRANDIAL, PLASMA	106	Diabetes Mellitus : > or = 200. mg/dL Impaired Glucose tolerance/ Prediabetes : 140 - 199. Hypoglycemia : < 55.
--------------------------------	-----	--

**GLUCOSE FASTING,FLUORIDE PLASMA**

FBS (FASTING BLOOD SUGAR)	104	Diabetes Mellitus : > or = 126. mg/dL Impaired fasting Glucose/ Prediabetes : 101 - 125. Hypoglycemia : < 55.
---------------------------	-----	--

**DR.HARI SHANKAR, MBBS MD**  
(Reg No - TCMC:62092)  
**HEAD - Biochemistry & Immunology**



View Details



View Report

**PERFORMED AT :**

DDRC AGILUS PATHLABS LIMITED  
ASTER SQUARE BUILDING, ULLOOR,  
MEDICAL COLLEGE P.O  
TRIVANDRUM, 695011  
KERALA, INDIA  
Tel : 93334 93334, Fax : CIN - U85190MH2006PTC161480  
Email : customercare.ddrc@agilus.in



**Patient Ref. No. 66600007978576**



**PATIENT NAME : RAMYA**

**REF. DOCTOR : SELF**

**CODE/NAME & ADDRESS :** CA00010147 -  
 MEDIWHEEL ARCOFEMI HEALTHCARE LIMITED  
 F701A, LADO SARAI, NEW DELHI,SOUTH DELHI,  
 DELHI,  
 SOUTH DELHI 110030  
 8800465156

**ACCESSION NO :** **4182XB008711**  
**PATIENT ID :** RAMYF2511834021  
**CLIENT PATIENT ID:**  
**ABHA NO :**

**AGE/SEX :** 41 Years Female  
**DRAWN :**  
**RECEIVED :** 24/02/2024 09:56:20  
**REPORTED :** 27/02/2024 09:52:39

Test Report Status	Final	Results	Units
--------------------	-------	---------	-------

TOTAL PROTEIN	7.2	Ambulatory : 6.4 - 8.3 Recumbant : 6 - 7.8	g/dL
---------------	-----	---	------

**URIC ACID, SERUM**

URIC ACID	5.1	Adults : 2.4-5.7	mg/dL
-----------	-----	------------------	-------

**BIOCHEMISTRY - LIPID**

**MEDIWHEEL HEALTH CHECKUP ABOVE 40(F)2DECHO**

**LIPID PROFILE, SERUM**

CHOLESTEROL	199	Desirable : < 200 Borderline : 200-239 High : >or= 240	mg/dL
TRIGLYCERIDES	<b>201 High</b>	Normal : < 150 High : 150-199 Hypertriglyceridemia : 200-499 Very High : > 499	mg/dL
HDL CHOLESTEROL	43	General range : 40-60	mg/dL
LDL CHOLESTEROL, DIRECT	142	Optimum : < 100 Above Optimum : 100-129 Borderline High : 130-159 High : 160-189 Very High : >or= 190	mg/dL
NON HDL CHOLESTEROL	156	Desirable : < 130 Above Desirable : 130 -159 Borderline High : 160 - 189 High : 190 - 219 Very high : > / = 220	mg/dL
VERY LOW DENSITY LIPOPROTEIN CHOL/HDL RATIO	<b>40.2 High</b>	</= 30.0	mg/dL
LDL/HDL RATIO	4.6	Low Risk : 3.3 - 4.4 Average Risk : 4.5 - 7.0 Moderate Risk : 7.1 - 11.0 High Risk : > 11.0	
	3.3	Desirable/Low Risk - 0.5-3	

**DR.HARI SHANKAR, MBBS MD**  
 (Reg No - TCMC:62092)  
**HEAD - Biochemistry & Immunology**



View Details



View Report

**PERFORMED AT :**

DDRC AGILUS PATHLABS LIMITED  
 ASTER SQUARE BUILDING, ULLOOR,  
 MEDICAL COLLEGE P.O  
 TRIVANDRUM, 695011  
 KERALA, INDIA  
 Tel : 93334 93334, Fax : CIN - U85190MH2006PTC161480  
 Email : customercare.ddrc@agilus.in



PATIENT NAME : RAMYA

REF. DOCTOR : SELF

CODE/NAME &amp; ADDRESS : CA00010147 -

MEDIWHEEL ARCOFEMI HEALTHCARE LIMITED  
F701A, LADO SARAI, NEW DELHI, SOUTH DELHI,  
DELHI,  
SOUTH DELHI 110030  
8800465156

ACCESSION NO : **4182XB008711**

PATIENT ID : RAMYF2511834021

CLIENT PATIENT ID:

ABHA NO :

AGE/SEX : 41 Years Female

DRAWN :

RECEIVED : 24/02/2024 09:56:20

REPORTED : 27/02/2024 09:52:39

Test Report Status **Final**

Results

Units

Borderline/Moderate Risk- 3.1-  
6  
High Risk- >6.0

### HISTOPATHOLOGY

#### MEDIWHEEL HEALTH CHECKUP ABOVE 40(F)2DECHO

#### CYTOLOGY - CS (PAP SMEAR)

CYTOLOGY - CS (PAP SMEAR)

#### CERVICAL CYTOLOGY REPORT (2014) BETHESDA SYSTEM.

CR No:295/2/24

SPECIMEN TYPE : Conventional pap smear.

SPECIMEN ADEQUACY : Satisfactory for evaluation. Transformation zone component present.  
Endocervical cells and metaplastic squamous cells noted.

GENERAL CATEGORIZATION : Negative for intraepithelial lesion / malignancy.

INTERPRETATION /RESULT : Negative for intraepithelial lesion / malignancy.

OTHER MALIGNANT NEOPLASM : Nil


EDUCATIONAL NOTES &amp; SUGGESTIONS: Nil

### SPECIALISED CHEMISTRY - HORMONE

#### MEDIWHEEL HEALTH CHECKUP ABOVE 40(F)2DECHO



**DR.HARI SHANKAR, MBBS MD**  
(Reg No - TCMC:62092)  
HEAD - Biochemistry &  
Immunology



**DR.ANNI BELTHAZAR M.D**  
(Path) (Reg No:TCMC 8397)  
CONSULTANT PATHOLOGIST

Page 9 Of 11



View Details



View Report

#### PERFORMED AT :

DDRC AGILUS PATHLABS LIMITED  
ASTER SQUARE BUILDING, ULLLOOR,  
MEDICAL COLLEGE P.O  
TRIVANDRUM, 695011  
KERALA, INDIA  
Tel : 93334 93334, Fax : CIN - U85190MH2006PTC161480  
Email : customercare.ddrc@agilus.in



Patient Ref. No. 66600007978576

**PATIENT NAME : RAMYA**

**REF. DOCTOR : SELF**

**CODE/NAME & ADDRESS :** CA00010147 -  
MEDIWHEEL ARCOFEMI HEALTHCARE LIMITED  
F701A, LADO SARAI, NEW DELHI,SOUTH DELHI,  
DELHI,  
SOUTH DELHI 110030  
8800465156

**ACCESSION NO :** **4182XB008711**  
**PATIENT ID :** RAMYF2511834021  
**CLIENT PATIENT ID:**  
**ABHA NO :**

**AGE/SEX :** 41 Years Female  
**DRAWN :**  
**RECEIVED :** 24/02/2024 09:56:20  
**REPORTED :** 27/02/2024 09:52:39

Test Report Status	Final	Results	Units
--------------------	-------	---------	-------

**THYROID PANEL, SERUM**

T3	123.00	Non-Pregnant : 80-200 Pregnant Trimester-wise 1st : 81-190 2nd : 100-260 3rd : 100-260	ng/dL
T4	6.46	Adults : 4.5-12.1	µg/dl
TSH 3RD GENERATION	2.530	Non-Pregnant : 0.4-4.2 Pregnant Trimester-wise : 1st : 0.1 - 2.5 2nd : 0.2 - 3 3rd : 0.3 - 3	µIU/mL

**CLINICAL PATH - URINALYSIS**

**MEDIWHEEL HEALTH CHECKUP ABOVE 40(F)2DECHO**

**PHYSICAL EXAMINATION, URINE**

COLOR	YELLOW
APPEARANCE	CLEAR

**CHEMICAL EXAMINATION, URINE**

PH	5.0	4.7 - 7.5
SPECIFIC GRAVITY	1.023	1.003 - 1.035
PROTEIN	NEGATIVE	NOT DETECTED
GLUCOSE	NEGATIVE	NOT DETECTED
KETONES	NEGATIVE	NOT DETECTED
BLOOD	NOT DETECTED	NOT DETECTED
BILIRUBIN	NEGATIVE	NOT DETECTED
UROBILINOGEN	NORMAL	NORMAL

METHOD : DIPSTICK



**DR.HARI SHANKAR, MBBS MD**  
(Reg No - TCMC:62092)  
**HEAD - Biochemistry & Immunology**



**DR.VAISHALI RAJAN, MBBS DCP**  
(Pathology)  
(Reg No - TCC 27150)  
**HOD - HAEMATOLOGY**



View Details



View Report

**PERFORMED AT :**

DDRC AGILUS PATHLABS LIMITED  
ASTER SQUARE BUILDING, ULLLOOR,  
MEDICAL COLLEGE P.O  
TRIVANDRUM, 695011  
KERALA, INDIA  
Tel : 93334 93334, Fax : CIN - U85190MH2006PTC161480  
Email : customercare.ddrc@agilus.in



**Patient Ref. No. 66600007978576**



**PATIENT NAME : RAMYA**

**REF. DOCTOR : SELF**

**CODE/NAME & ADDRESS :** CA00010147 -  
 MEDIWHEEL ARCOFEMI HEALTHCARE LIMITED  
 F701A, LADO SARAI, NEW DELHI,SOUTH DELHI,  
 DELHI,  
 SOUTH DELHI 110030  
 8800465156

**ACCESSION NO :** **4182XB008711**  
**PATIENT ID :** RAMYF2511834021  
**CLIENT PATIENT ID:**  
**ABHA NO :**

**AGE/SEX :** 41 Years Female  
**DRAWN :**  
**RECEIVED :** 24/02/2024 09:56:20  
**REPORTED :** 27/02/2024 09:52:39

Test Report Status	Final	Results	Units
--------------------	-------	---------	-------

NITRITE		NEGATIVE	NOT DETECTED
---------	--	----------	--------------

**MICROSCOPIC EXAMINATION, URINE**

RED BLOOD CELLS	NOT DETECTED	NOT DETECTED	/HPF
WBC	<b>10-15</b>	0-5	/HPF
EPITHELIAL CELLS	<b>10-15</b>	0-5	/HPF
CASTS	NEGATIVE		
CRYSTALS	NEGATIVE		
REMARKS	NIL		

METHOD : AUTOMATED ANALYSER, MICROSCOPY

**\*\*End Of Report\*\***

Please visit <https://ddrcagilus.com> for related Test Information for this accession

**DR.VAISHALI RAJAN, MBBS DCP**  
**(Pathology)**  
**(Reg No - TCC 27150)**  
**HOD - HAEMATOLOGY**



View Details



View Report

**PERFORMED AT :**

DDRC AGILUS PATHLABS LIMITED  
 ASTER SQUARE BUILDING, ULLOOR,  
 MEDICAL COLLEGE P.O  
 TRIVANDRUM, 695011  
 KERALA, INDIA  
 Tel : 93334 93334, Fax : CIN - U85190MH2006PTC161480  
 Email : customercare.ddrc@agilus.in



**Patient Ref. No. 66600007978576**

<b>NAME : MRS. RAMYA</b>	<b>AGE:41/F</b>	<b>DATE: 24/02/2024</b>
--------------------------	-----------------	-------------------------

**CHEST X-RAY REPORT**

CHEST X-RAY PA VIEW : Trachea central  
No cardiomegaly  
Normal vascularity  
No parenchymal lesion.  
Costophrenic and cardiophrenic angles clear

**IMPRESSSION** : Normal Chest Xray

ELECTRO CARDIOGRAM : NSR:-75/minute  
No evidence of ischaemia

**IMPRESSSION** : Normal Ecg.



**Dr. SERIN LOPEZ. MBBS**  
Reg. No. 77656  
MEDICAL OFFICER  
DDRC AGILUS PATHLABS LTD.  
Aster Square, Medical College. P.O, TVM



**DR SERIN LOPEZ MBBS**  
Reg No 77656  
**DDRC AGILUS PATHLABS LTD**