

<b>Patient Name</b>	: Mrs. BANDITA SARKAR	<b>Age/Gender</b>	: 32 Y/F
<b>UHID/MR No.</b>	: CMAN.0000096558	<b>OP Visit No</b>	: CMANOPV197149
<b>Sample Collected on</b>	:	<b>Reported on</b>	: 12-03-2024 11:04
<b>LRN#</b>	: RAD2261655	<b>Specimen</b>	:
<b>Ref Doctor</b>	: SELF		
<b>Emp/Auth/TPA ID</b>	: 117670		

## DEPARTMENT OF RADIOLOGY

### ULTRASOUND - WHOLE ABDOMEN

**Liver** appears normal in size and **Increased echotexture**. No focal lesion is seen. PV and CBD normal. No dilatation of the intrahepatic biliary radicals.

**Gall bladder** is **Partially distended**.

**Spleen** appears normal. No focal lesion seen. Splenic vein appears normal.

**Pancreas** appears normal in echopattern. No focal/mass lesion/calcification. No evidence of peripancreatic free fluid or collection. Pancreatic duct appears normal.

**Both the kidneys** appear normal in size, shape and echopattern. Cortical thickness and CM differentiation are maintained. No calculus / hydronephrosis seen on either side.

**Urinary Bladder** is well distended and appears normal. No evidence of any wall thickening or abnormality. No evidence of any intrinsic or extrinsic bladder abnormality detected.

**Uterus** appears normal in size. It shows normal shape & echo pattern. Endometrial echo-complex appears normal and measures 3.8 mm. No intra/extra uterine gestational sac seen.

**Both ovaries** appear normal in size, shape and echotexture.

**Multiple small follicles noted arranged at periphery of both ovaries.**

R/K : 34 x 17 mm.

L/K : 30 x 16 mm.

No evidence of any adnexal pathology noted.

### **IMPRESSION:-**

- **GRADE - I FATTY LIVER.**
- **BILATERAL PCOD**

**Suggest – clinical correlation.**

(The sonography findings should always be considered in correlation with the clinical and other investigation finding where applicable.) It is only a professional opinion, Not valid for medico legal purpose.



**Patient Name** : Mrs. BANDITA SARKAR

**Age/Gender** : 32 Y/F

**Dr. MOHD ABDUL RAWOOF**  
**MBBS,DNB(RADIO DIAGNOSIS)**  
Radiology

Name <u>Mr. Mohan Bandita Sanku</u>	Date <u>09/03/24</u>
Age <u>32</u>	UHID No. <u>CMAM. 96558</u>
<input type="checkbox"/> Male <input checked="" type="checkbox"/> Female	Ref. Physician <u>Tripai Deb</u>
Ref. Diagnosis	

THYROID - Supplement 25mgms  
**Echocardiogram Report**

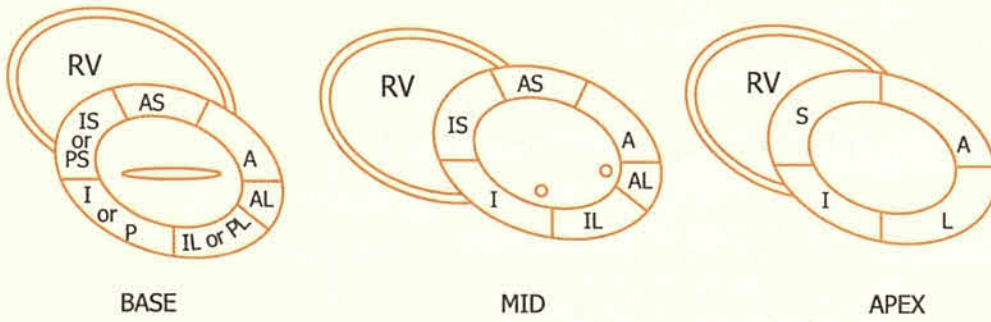
Echogenicity  Poor  Adequate  Good      Ht. \_\_\_\_\_ Wt. \_\_\_\_\_ BSA \_\_\_\_\_

DIMENSIONS		NORMAL	DIMENSIONS		NORMAL
Ao (ed) <u>2.95</u>	cm	(1.5cm / m2)	IVS (Ed) <u>1.28</u>	cm	(0.6 - 1.2 cm)
LA (es) <u>2.41</u>	cm	(1.5cm / m2)	LVPW (Ed) <u>1.03</u>	cm	(0.6 - 1.1 cm)
RVID (ed) <u>9.3</u>	cm	(0.9 cm / m2)	EF <u>65</u>	%	(0.62 - 0.85)
LVID (ed) <u>3.93</u>	cm	(2.6 - 3.4 cm / m2)	% FD <u>35</u>	%	(2.8% - 42%)
LVID (es) <u>2.56</u>	cm				

### MORPHOLOGICAL DATA

Mitral Valve	AML <u>N</u>	Interatrial septum <u>N</u>
	PML <u>N</u>	Interventricular septum <u>N</u>
Aortic Valve	<u>N</u>	Pulmonary artery <u>N</u>
Tricuspid valve	<u>N</u>	Aorta <u>N</u>
Pulmonary valve	<u>N</u>	Right atrium <u>N</u>
Right ventricle	<u>N</u>	Left atrium <u>N</u>

**Left ventricle : LV WALL MOTION ANALYSIS**



1. Normal
2. Hypokinesia
3. Akinesia
4. Dyskinesia
5. Aneurysmal

**Pericardium** \_\_\_\_\_

N

**Doppler studies**

ASV = 0.67 mls

A = 0.55 mls

PJV = 0.7 mls

E = 0.68 mls

Normal colour Doppler

**Impression**

Normal Diastolic

Normal Echo flow study

Done by

Checked by

Signature  
Consultant - Cardiology

The Apollo Clinic- Manikonda,  
PHYSICAL EXAMINATION FORM

DATE 9/3/23

UHID Chan - 96558

Name Mrs. Bandita  
Sarkar

Age 32/F

Height  Cms

Weight  Kgs

Chest Measurement  (In) Cm  (Out) Cm

Waist  Cm

Hip

Pulse  Bt/Min

BMI

BP  mmHg

SPO2



Mrs. bandita sarkar  
ID: cman.96558

32 Years  
Female

Technician:  
Ordering Ph:  
Referring Ph:  
Attending Ph:

09.03.2024 11:25:19  
APOLLO CLINIC  
MANIKONDA  
HYDERABAD

Location:  
Order Number:  
Visit:  
Indication:  
Medication 1:  
Medication 2:  
Medication 3:

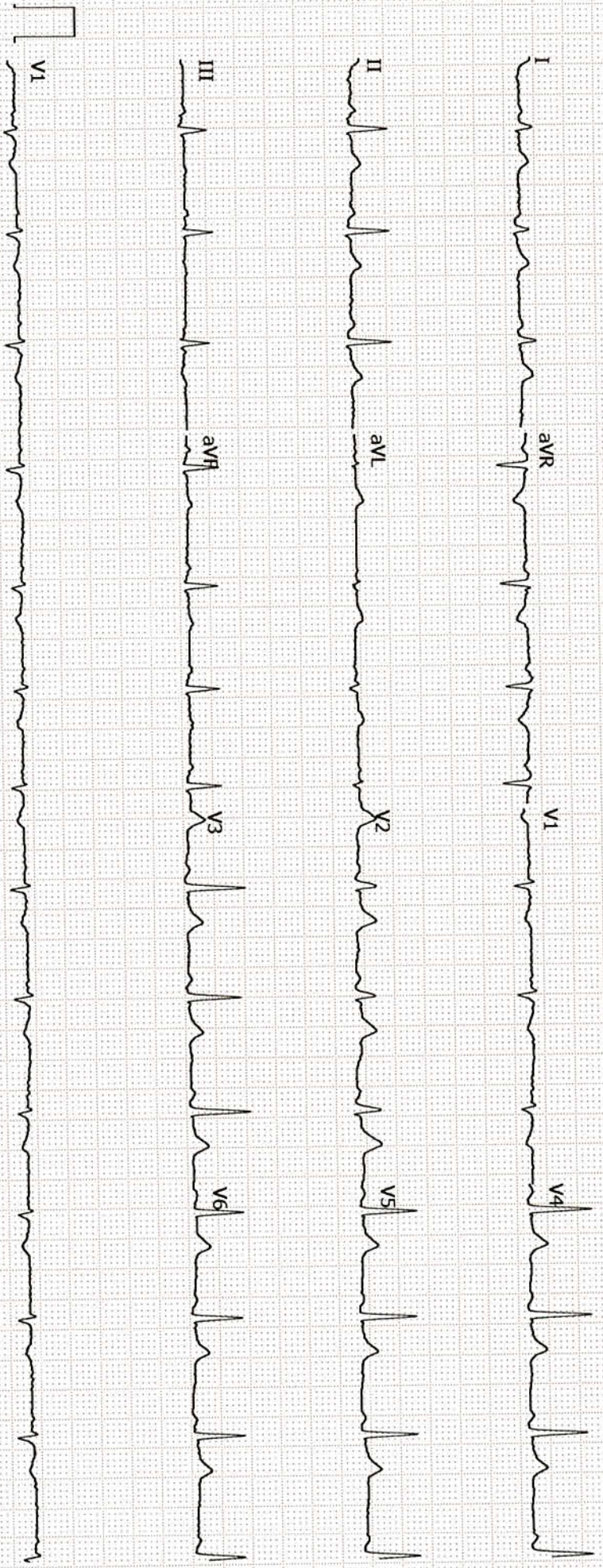
Room:

83 bpm  
--/-- mmHg

QRS : 68 ms  
QT / QTcBaz : 348 / 408 ms  
PR : 128 ms  
P : 94 ms  
RR / PP : 724 / 722 ms  
P / QRS / T : 38 / 70 / 37 degrees

Normal sinus rhythm with sinus arrhythmia  
Normal ECG

*Handwritten signature*



GE MAC2000 1.1 12SL™ V241 25 mm/s 10 mm/mV ADS 0.56-20 Hz 50 Hz 4X2.5X3\_25\_R1 1/1

Unconfirmed



# POWER PRESCRIPTION

NAME: *Bondita Sarkar*

GENDER: *M/F*

DATE: *9/13/24*

AGE: *32*

UHID: *96558*

## RIGHT EYE

	SPH	CYL	AXIS	VISION
DISTANCE	<i>-2.50</i>	<i>-1.00</i>	<i>90</i>	<i>6/6</i>
NEAR	<i>—————</i>			<i>N/A</i>

## LEFT EYE

	SPH	CYL	AXIS	VISION
DISTANCE	<i>-3.50</i>	<i>-1.00</i>	<i>90</i>	<i>6/6</i>
NEAR	<i>—————</i>			<i>N/A</i>

### INSTRUCTIONS:

*Colour Vision, wear*

  
SIGNATURE

## CERTIFICATE OF MEDICAL FITNESS

This is to certify that I have conducted the clinical examination  
of Mrs. Randita Sarika on 11/03/2024

After reviewing the medical history and on clinical examination it has been found that  
he/she is

	Tick
<ul style="list-style-type: none"> <li>• Medically Fit</li> </ul>	✓
<ul style="list-style-type: none"> <li>• Fit with restrictions/recommendations</li> </ul> <p>Though following restrictions have been revealed, in my opinion, these are not impediments to the job.</p> <p>1.....</p> <p>2.....</p> <p>3.....</p> <p>However the employee should follow the advice/medication that has been communicated to him/her.</p> <p>Review after _____</p>	
<ul style="list-style-type: none"> <li>• Currently Unfit. Review after _____ recommended</li> <li>• Unfit</li> </ul>	

Dr.   
Medical Officer  
The Apollo Clinic, (Location) 

*This certificate is not meant for medico-legal purposes*



**Patient Name** : Mrs. BANDITA SARKAR

**Age/Gender** : 32 Y/F

**UHID/MR No.** : CMAN.0000096558

**OP Visit No** : CMANOPV197149

**Sample Collected on** :

**Reported on** : 09-03-2024 19:44

**LRN#** : RAD2261655

**Specimen** :

**Ref Doctor** : SELF

**Emp/Auth/TPA ID** : 117670

---

**DEPARTMENT OF RADIOLOGY**

---

**X-RAY CHEST PA**

Cardiac is normal.

Both lung fields and hila are normal .

No obvious active pleuro-parenchymal lesion seen .

Both costophrenic and cardiophrenic angles are clear .

Both diaphragms are normal in position and contour .


Thoracic wall and soft tissues appear normal.

**CONCLUSION :**

No obvious abnormality seen




**Dr. MD RAHEEMUDDIN QURESHI**  
Radiology


 बैंक ऑफ़ बड़ौदा  
Bank of Baroda



सन्थाल  
Sanyal

कर्मचारी  
E.C. No. 117670

  
जारीकर्ता प्राधिकारी  
Issuing Authority

  
धारक के हस्ताक्षर  
Signature of Holder

मिलने पर, भिन्नलेखित को जौटाए  
बैंक ऑफ़ बड़ौदा, बड़ौदा भवन,  
कानुन मुनिमंतिरी रोड, गांधीनगर  
हैदराबाद-500032, भारत

If found, please return to  
Bank of Baroda, Baroda Bhavan,  
Urdu University Road, Gachibowli  
Hyderabad-500032, India

रक्त समूह / Blood Group  
पहचान चिह्न / Identification Marks

O-ve

