

R

SUNITA TOMAR 49Y/F P1208379 CHEST PA 09 03 2024 10 53 AM  
RADIOX HEALTHCARE CHEST PA 09 03 2024 10 53 AM



UHID	PT208379	LAB No.	XRY2310605
Name	Mrs. SUNITA TOMAR	Regn. No.	GEN2341862
Age / Sex	49 Yrs / F	Receiving Dt/Time	09-Mar-2024 10:53
		Reporting Dt/Time	09-Mar-2024 10:52 AM



**XRAY**

CHEST (PA)

Both lung fields are normal.

Cp angles are clear.

Hila are normal...

Heart size appears within normal limits.

Soft tissue shadows and bony thorax are normal.

**IMP- NORMAL CHEST X-RAY**

Advised....please correlate clinically.

\*\*\*\*\* END OF REPORT \*\*\*\*\*

DR. K.K. SINHA  
 M.B.B.S., D.M.R.D.  
 SENIOR CONSULTANT  
 Reg. No. 25437 (DMC)

DR. RAJESH MALHOTRA  
 MBBS, MD (RADIOLOGY)  
 CONSULTANT RADIOLOGY  
 Reg.No.DMC9299

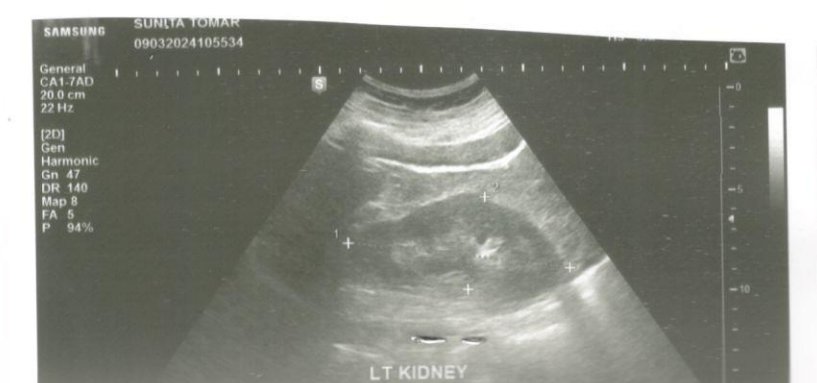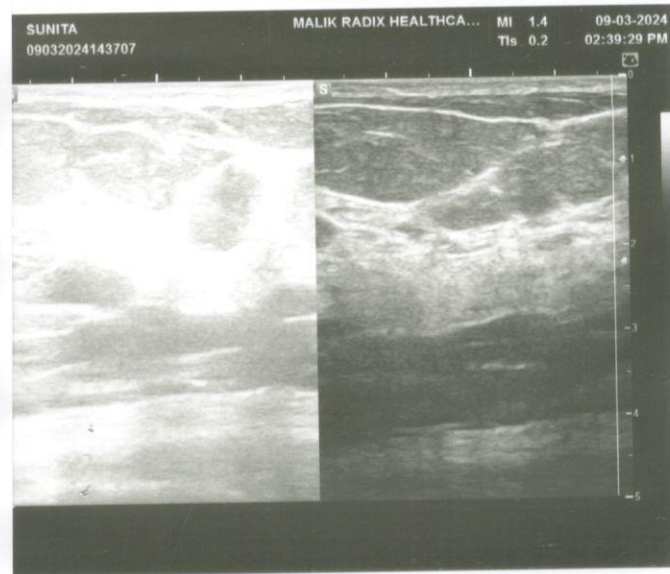
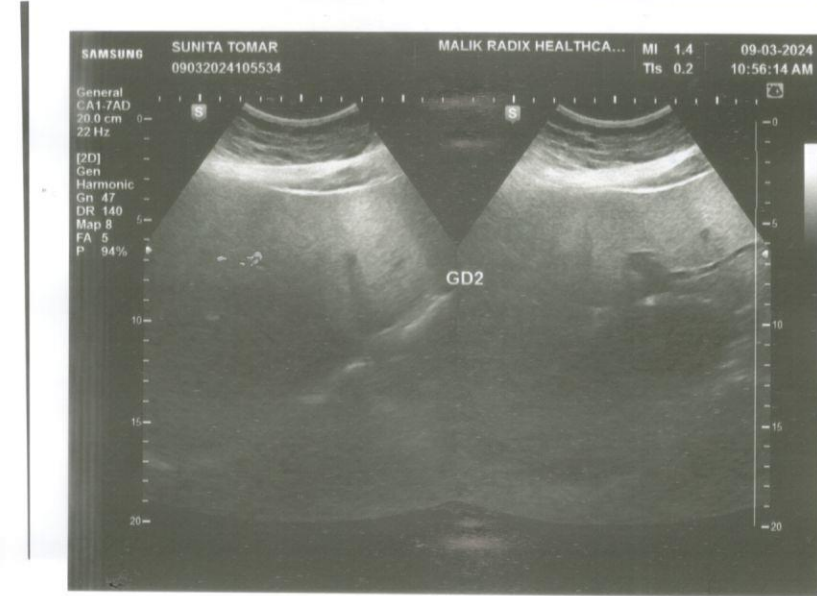
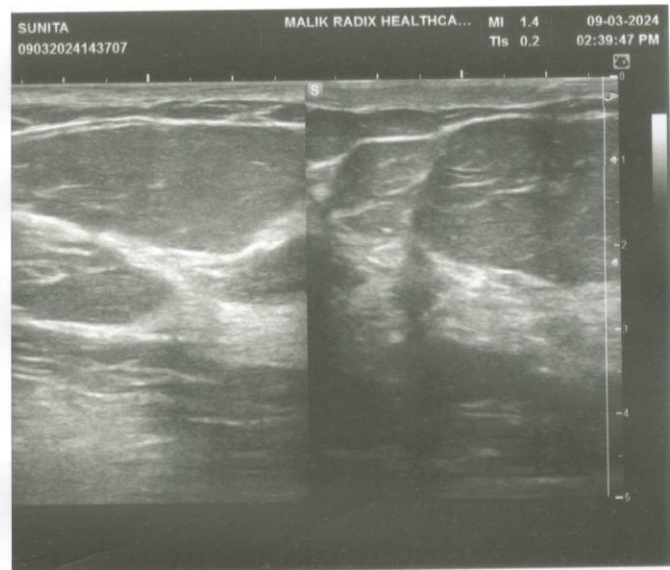
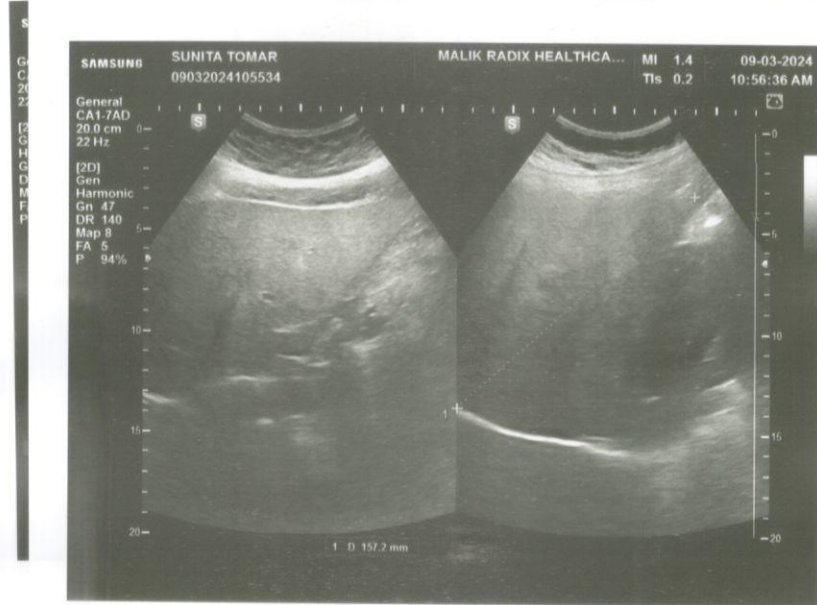
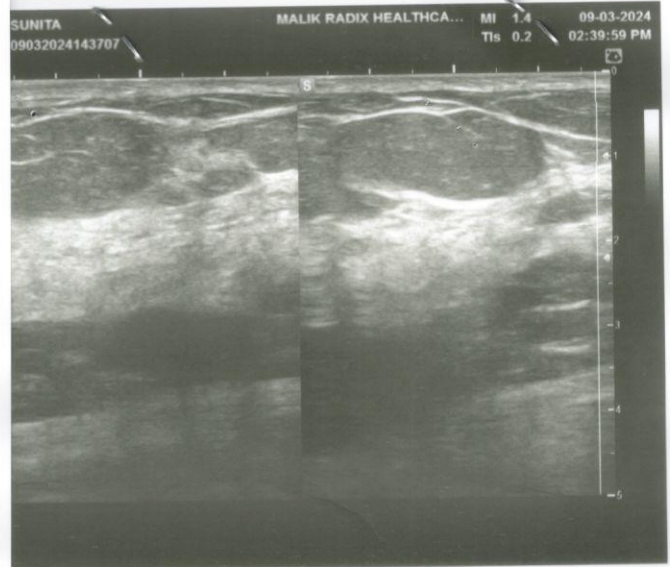
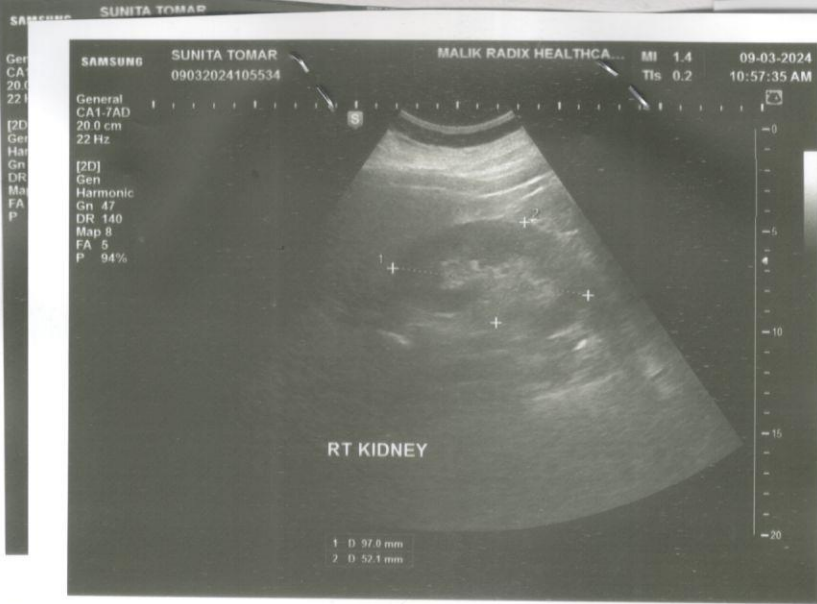
DR. T. K VOHRA  
 MD (RADIODIAGNOSIS)  
 SENIOR CONSULTANT  
 Reg. No. 3272 (DMC)

DR. MUKESH KOSHAL  
 MBBS, MD (RADIOLOGY)  
 CONSULTANT RADIOLOGY  
 Reg.No.DMC10407

DR. SHREYASH TIWARY  
 MBBS, MD (RADIOLOGY)  
 CONSULTANT RADIOLOGY  
 Reg.No.DMC85802

**Facilities Available**







NAME	MRS SUNITA TOMER	AGE	49 Y/F
REFD. BY.	HEALTH CHECK UP	DATE	09.03.24

**Ultrasound Examination of Whole Abdomen & Pelvis:**

**Liver:** Liver is enlarged in size (15.7 cm) with normal outlines and shows increased parenchymal echotexture. No focal lesion is seen. IHBR & portal radicles are normal.

**Gallbladder:** Gallbladder is well distended. No evidence of cholecystitis or cholelithiasis seen. Common bile duct is normal in course & caliber.

**Pancreas:** Pancreas shows normal size, outlines & echotexture. No focal lesion is seen. MPD is not dilated.

**Spleen:** Spleen shows normal size (7.6 cm), outline & echotexture.

**Kidneys:** Kidneys show normal size, shape, position & echotexture. No calculus/ hydronephrosis or SOL is seen in kidneys. Cortico- medullary differentiation and cortical thickness is normal on both sides.

Right kidney measures –9.7 x 5.2 cm

Left kidney measures – 10.9 x 4.6 cm

Great abdominal vessels are normal.

No ascites seen.

No para-aortic lymph nodes seen.

**Urinary bladder:** Urinary bladder is well distended. Walls and lumen appear normal.

Uterus is normal in size outline and echotexture. **Anterior myometrial fibroid measuring 22 x 23 mm.**

**Endometrium** is central and measures 3.9 mm. Cervix appears normal.

Both adnexa appear unremarkable.

**IMPRESSION:**

**Hepatomegaly with Grade II Fatty Changes.**

**Uterine fibroid**

**Dr Shreyash Tiwary MD ( Rad- diag)**

Regn. No. DMC 85802

**RADIOLOGIST :**

**Facilities Available**




**RADIX  
HEALTH  
care**



**Malik Radix Healthcare**

C/217, C/218, Vikas Marg, Nirman Vihar, New Delhi-110092  
A Unit of Malik Radix Healthcare  
Toll Free - 1800-120-5457  
Whatsapp No. - 9811550650  
E-mail: info@radixhealthcare.org  
Website: www.radixhealthcare.org



**MRS SUNITA TOMER**

**Age :- 49 Y/F**

**09.03.24**

**REFD BY -HEALTH CHECK UP**

**USG B/L BREAST**

USG Breast was done with high frequency linear probe.

Both breast parenchyma shows normal echopattern .

No obvious solid or cystic lesion seen.

No calcification/shadowing seen.

No obvious duct dilatation seen.

Retromammary space appears normal.

No significant axillary lymph nodes seen.

**IMF— No significant abnormality seen ultrasonographically  
BIRAD-1**

**Clinical correlation.**

**DR T K VOHRA  
MBBS MD  
REG NO -3272(DMC)**

**DR.K.K. SINHA  
M. B. B. S. D.M.R. D.  
SENIOR CONSULTANT - RADIOLOGIST  
REG NO-25437 (DMC)**

**RADIOLOGIST :**

**Facilities Available**

- Multispeciality Hospital - 24 Hours Emergency - X-Ray/ ECG/ Ultrasound/ CT Scan - Dental - Fully Equipped Operation Theatre  
- Fully Functional Lab - 24/7 Casualty/ ICU-Nursery 24/7 Pharmacy - Labour Room - All Speciality OPD - Laproscopic Surgery -  
- ICU - Plastic Surgery



भारत सरकार

GOVERNMENT OF INDIA

सुनीता तोमर

Sunita Tomar

जन्म तिथि/ DOB: 01/02/1975

लिंग / FEMALE

Sunita



MALIK RADIX HEALTH CARE PVT. LTD.

C-217, C-218, Nirman Vihar,

Delhi-110052

Ph.: 011-49267455, 011-61081379

Regd. No. 607

2619 9154 3932

सुनीता तोमर - 2619 9154 3932

49







Ms. Sunita  
Age - 48/1f

09-03-24


Revised chart

Very 6/9 ~~2/2~~  
6/9 ~~2/2~~

BOB

Nfo  
Nfo  
not brought near for

Color. was (PS)



  
Dr. Nidhi Gupta  
MBBS, MS, DNB  
Casualty Ophthalmologist  
Malik Radix Healthcare Pvt. Ltd.  
DMC No. 121661

Facilities Available

- Multispeciality Hospital - 24 Hours Emergency - X-Ray/ ECG/ Ultrasound/ CT Scan - Dental- Fully Equipped Operation Theatre
- Fully Functional Lab - 24/7 Casualty/ ICU-Nursery 24/7 Pharmacy - Labour Room - All Speciality OPD - Laproscopic Surgery - ECHO - Plastic Surgery



# RADIX COSMO DENTAL

(UNIT OF MALIK RADIX HEALTHCARE PVT. LTD.)  
C-216, 217, 218, Nirman Vihar, Vikas Marg, Delhi - 110092  
Ph. : 011-22508272, 22520249 • M. : 9999254639  
E-mail : radixhealthcare@yahoo.co.in • www.radixhealthcare.org



## CONSULTANTS ON PANEL

### PAEDIATRICS

Dr Ravi Malik (MBBS, MD)  
Dr Harit Prasad (MBBS, MD, Pdf)  
Dr Ritu Jain (MBBS, MD)

### GYNAECOLOGY

Dr Renu Malik (MBBS, MD)  
Dr Meena Malhotra (MBBS, MD)  
Dr Rajni (MBBS, MD)  
Dr Manju Gupta (MBBS, MS)  
Dr Vaishali Saini (MBBS, DGO)  
Dr Rupam Arora (MBBS, MD)

### DENTAL

Dr Shruti Malik (BDS, MDS)  
Dr Annu Saini (BDS, MDS)  
Dr Rachit Thukral (BDS, MDS)  
Dr Mohit Mangla (BDS, MDS)  
Dr Tarun Mittal (BDS, MDS)  
Dr Geetika Sharma (BDS)  
Dr Shilpa Verma (BDS)

### CHILD GASTROENTEROLOGY

Dr S. K Mittal (MBBS, MD)

### MEDICINE

Dr A S Talwar (MBBS, MD)  
Dr Sunny Uppal (MBBS, MD)  
Dr Surendra Rajpal (MBBS, MD)

### RESPIRATORY MEDICINE / PULMONOLOGY

Dr Abhinav Bhanot (MBBS, DNB)

### LAPAROSCOPY SURGERY

Dr Ajay Jain (MBBS, MS)  
Dr Deepak Saran (MBBS, MS)  
Dr Pradeep Saini (MBBS, MS)  
Dr G. S Garg (MBBS, MS)

### ORTHOPAEDICS

Dr Vikas Bhardwaj (MBBS, MS ORTHO, DNB)  
Dr Prabhakar Aggarwal (MBBS, MS ORTHO)  
Dr KB Tiwari (MBBS, MS ORTHO)  
Dr Deepak Kumar Arora (MBBS, MS ORTHO)

### EYE/OPTHALMOLOGY

Dr Nidhi Gupta (MBBS, MS, DNB, PGDM)  
Dr Himanshu Singh Pundir (MBBS, MS)

### ENT

Dr Sharad Kumar Singhi (MBBS, MS)  
Dr Prateek Sharma (MBBS, MS)  
Dr Ashok Singh (MBBS, MS)  
Dr A K Lahiri (MBBS, MS)

### RADIOLOGY (ULTRASOUND)

Dr K K Sinha (MBBS DNRB)  
Dr T K Vohra (MBBS, MD)  
Dr Rajesh Malhotra (MBBS, MD)  
Dr Ashish Tomar (MBBS, MD)

### PATHOLOGY

Dr Reema Dahiya (MBBS, MD PATH)  
Dr Meenu Aggarwal (MBBS, MD PATH)

### ANAESTHESIA

Dr Rajesh Dhall (MBBS, MD)  
Dr Rakesh Atrey (MBBS, MD)  
Dr R K Arora (MBBS, MD)  
Dr Swaraj Garg (MBBS, MD)

### DERMATOLOGY

Dr Nihanka Jha (MBBS, MD)

### PLASTIC & COSMETIC SURGERY

Dr Ayush Jain (MBBS, MS, MCh)

### PAEDIATRIC SURGERY

Dr Dharmendra Singh (MBBS, MS, M.Ch)  
Dr Satish Aggarwal (MBBS, MS, M.Ch)

### PAEDIATRIC NEPHROLOGY

Dr A S Vasudev (MD, Dip.in. Paed.)

### NEPHROLOGY

Dr Javed (MBBS, MD, Nephro)

### CARDIOLOGY

Dr Nishant Tyagi (MBBS, MD)

### NEUROLOGY

Dr Amit Batra (MBBS, MD)

### GASTROENTEROLOGY

Dr Deepak Lahoti (MBBS, MD)  
Dr Naresh Aggarwal (MBBS, MD)  
Dr Ashok Goyal (MBBS, MD)  
Dr Ankur Singhal (MBBS, MD)

### UROLOGY

Dr Nikhil Sharma (MBBS, Mch)  
Dr Ankur Singhal (MBBS, MD)

### PSYCHIATRY

Dr Mohit Sharma (MBBS, MD)

### PHYSIOTHERAPY

Dr Kirti Dwivedi  
Dr Ravi Kumar

### NUTRITIONIST

Dr Deepika Kohli  
Dr Sakshi Rana

### CLINICAL PSYCHOLOGIST

Dr. Sarika Singh

## Dr. Shruti Malik

BDS, MDS (Endodontics)

+91-9899561092

Timings : 10:00 am. to 2:00 pm.  
6:00 pm. to 8:30 pm.

### CLINICAL EXAMINATION:-

1. TMJ:-

Routine checkup

2. DENTAL STATUS:

- a. Caries Teeth :
- b. Fracture Teeth :
- c. Root Stumps :
- d. Gingivitis :
- e. Periodontitis :
- f. Impacted Teeth :
- g. Malaligned Teeth :

O/E

Calculus ++

Stains ++

Root stump	8 6	6
	8 7 6	6

3. ORAL LESIONS:-

Missing

4	
	7

4. DIAGNOSIS:-

Adv.

5. TREATMENT PLANNING:

- OPG

6. FOLLOW UP:-

Referral To Other Consultant: Yes/ No

- f-Kit + oral Prophyaxis

If Yes, please mention the Name: .....

Gellina

Doctor's Signature .....

## Facilities Available :

- ★ MULTI-SPECIALITY HOSPITAL ★ MODULAR FULLY EQUIPPED OT ★ NURSERY ★ LAPROSCOPIC SURGERY
- ★ 24X7 EMERGENCY ★ OPG ★ DENTAL ★ 24X7 DIAGNOSTICS ★ LABOUR ROOM ★ ECHO ★ EEG ★ DIGITAL X-RAY ★ CT SCAN
- ★ ECG ★ ULTRASOUND ★ RICU/ICU ★ ALL SPECIALITY OPD ★ PLASTIC & COSMETIC SURGERY ★ DIALYSIS ★ PHARMACY



Sunita Tomar

ID: 0903202444

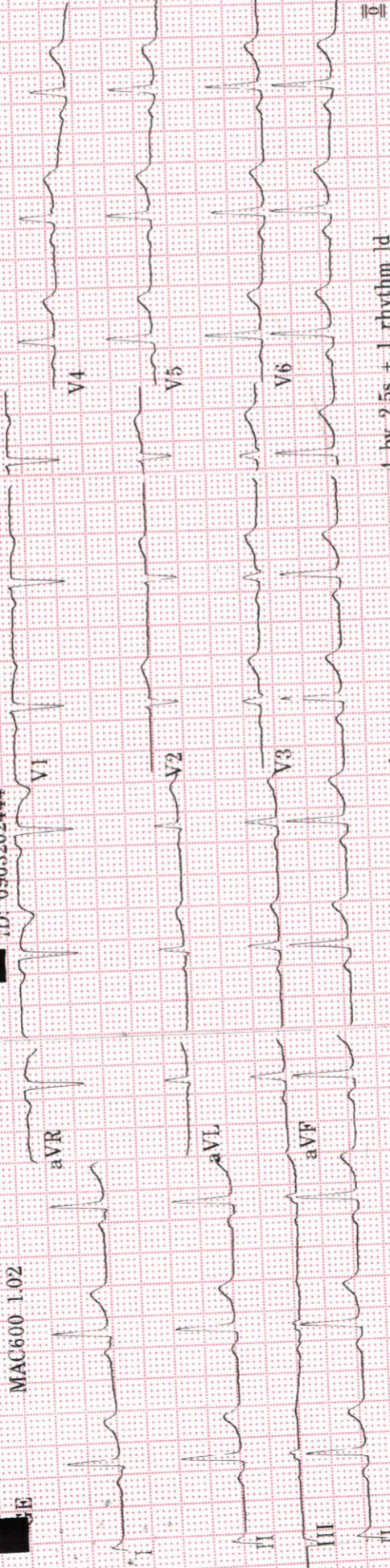
49years Female

Vent. rate 74 bpm  
QRS duration 70 ms  
QT/QTc 374/415 ms  
PR interval 150 ms  
P duration 100 ms  
RR interval 810 ms  
P-R-T axes 48 40 29

MAC600 1.02 12SL™ v239

9-Mar-2024 10:28:47

ID: 0903202444



MAC600 1.02

74 bpm

50Hz

t by 2.5s + 1 rhythm ld

25.0 mm/s 10.0 mm/mV

0.16-20Hz



# Malik Radix HealthCare.

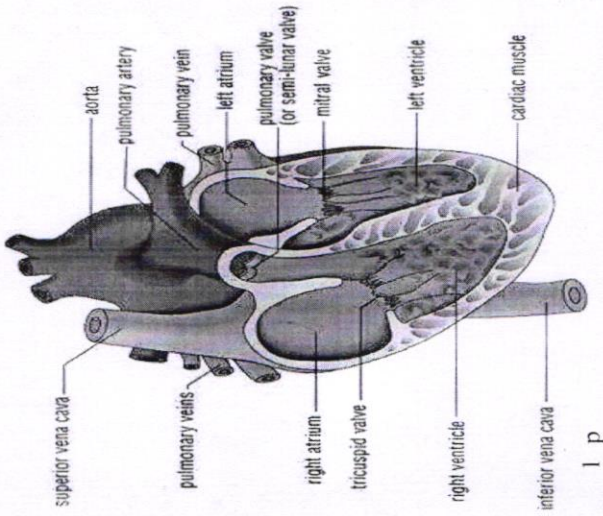
## ELECTROCARDIOGRAM

Name: MRS. SUNITA TOMAR

Age & Sex: 49YR/FEMALE

Ref by: MEDIWHEEL

Date: 09/03/2024



I P

### ECG FINDINGS:

Rate 74bpm Rhythm Sinus Mechanism Normal

Axis Normal Wave Normal PR Interval 0.15/Sec

QRS Complex Normal QT Interval Normal Q Wave Normal

ST Segment Normal T Wave Normal

Conclusion Sinus Rhythm, Normal Axis, WNL

Doctors Signature

*[Signature]*  
**Dr. SHEIKH NAZIR AHMED**  
 M.D. "Physician"  
 PGDCC  
 DMC-46499





## Echocardiogram Report

Patient Name	MRS. SUNITA TOMAR
Date of Test	09/03/2024
Age	49 YRS/ FEMALE
Ref. by	MEDIWHEEL

Dimensions	Result	Normal Range
AO (ed)	2.6 cm	( 2.1 -3.7cm)
LA (es)	3.2 cm	(2.1 -3.7cm)
RVID (ed)	2.6 cm	(1.1-3.0cm)
LVID (ed)	4.0 cm	(3.6 – 5.5 cm)
LVID (es)	2.8 cm	(2.3-3.9cm)
IVS (ed)	1.1 cm	(0.6 – 1-2 cm)
LVPW (ed)	1.1 cm	(0.6 – 1-2 cm)
EF	58 %	
FS	30 %	(28 % - 42 %)

### Impression

- NO REGIONAL WALL MOTION ABNORMALITY SEEN.
- LVEF= 58 %
- NORMAL CHAMBER DIMENSIONS.
- NORMAL MIP.
- NORMAL COLOR FLOW.
- NO INTRA CARDIAC CLOT/MASS/ VEGETATION/PERICARDIAL EFFUSION SEEN.

Dr. Sheikh Nazir Ahmed  
 M.D. "Physician" PGDCC  
 (Consultant Non – Invasive Cardiologist)

#### Facilities Available

- Multispeciality Hospital - 24 Hours Emergency - X-Ray/ ECG/ Ultrasound/ CT Scan - Dental - Fully Equipped Operation Theatre  
 - Fully Functional Lab - 24/7 Casualty/ ICU-Nursery 24/7 Pharmacy - Labour Room - All Speciality OPD - Laproscopic Surgery -  
 ECHO - Plastic Surgery





**LAB REPORT**

Reg. Date	09/03/2024	Patient Id	2403090016	DOB.
Name	MRS. SUNITA TOMAR	Gender	F	Perm. ID
Age	49 Yrs.	Panel	MEDIWHEEL	Reported
Ref. By	MEDIWHEEL			10/03/2024 12:25:33

Test Name	Result	Units	Ref. Range
-----------	--------	-------	------------

**PLUS CHECK ADVANCED F ANNUAL**

**HAEMATOLOGY**

**COMPLETE HAEMOGRAM**

HAEMOGLOBIN (HB%)	12.9	gm/dl	12 - 15
TOTAL LEUCOCYTE COUNT (TLC)	6,100	/cumm	4000 - 11000
<b>DIFFERENTIAL LEUCOCYTE COUNT (DLC)</b>			
NEUTROPHIL	57	%	40 - 80
LYMPHOCYTE	34	%	28 - 55
MONOCYTE	06	%	02 - 10
EOSINOPHIL	03	%	01 - 06
BASOPHIL	00	%	0 - 0
ESR (WESTEGREN'S METHOD)	13	mm/1st hr.	0 - 15
R B C COUNT	3.79	Millions/cmm	4.247 - 5.4
P.C.V / HAEMATOCRIT	38.4	%	35 - 45
M C V	101.3	fl.	80 - 100
M C H	34.0	Picogram	27.0 - 31.0
M C H C	33.6	gm/dl	33 - 37
PLATELET COUNT	0.90	Lakh/cu mm	1.50 - 4.50

Urine Routine Examination

**PHYSICAL EXAMINATION**

QUANTITY	30	ml.	
COLOUR	Pale Yellow		Pale Yellow
TRANSPARENCY	Clear		
SPECIFIC GRAVITY	1.010		
PH	6.0		

Checked by : -----  
Page 1 Contd...2

If test results are alarming or unexpected, patient is advised to contact the laboratory immediately for possible remedial action.

**Facilities Available**

- Multispeciality Hospital - 24 Hours Emergency - X-Ray/ ECG/ Ultrasound/ CT Scan - Dental- Fully Equipped Operation Theatre  
- Fully Functional Lab - 24/7 Casualty/ ICU-Nursery 24/7 Pharmacy - Labour Room - All Speciality OPD - Laproscopic Surgery -  
ECHO - Plastic Surgery





**LAB REPORT**

Reg. Date	09/03/2024	Patient Id	2403090016	DOB.
Name	MRS. SUNITA TOMAR	Gender	F	Perm. ID
Age	49 Yrs.	Panel	MEDIWHEEL	Reported
Ref. By	MEDIWHEEL			10/03/2024 12:25:33

Test Name	Result	Units	Ref. Range
<b>CHEMICAL EXAMINATION</b>			
ALBUMIN	Nil		
SUGAR	Nil		
<b>MICROSCOPIC EXAMINATION</b>			
PUS CELLS	2-3	/HPF	
RBC'S	Nil	/HPF	
CASTS	Nil		
CRYSTALS	NIL		
EPITHELIAL CELLS	1-2	/HPF	
BACTERIA	Nil		
OTHERS	Nil		
BLOOD GROUP ABO	" O "		
RH TYPING	Positive		
BLOOD SUGAR FASTING	111.12	mg/dl	70 - 100
BLOOD SUGAR PP	112.80	mg/dl	90 - 140
<b><u>THYROID PROFILE</u></b>			
Free T3 ELFA	3.29	ng/ml	02 - 04
Free T4 ELFA	1.10	ug/dl	0.8 - 2.7
TSH Serum/ELFA	2.990	uIU/ml	0.25 - 5.50 uIU/ml

**Interpretation**

**Clinical Use**

- Diagnose Hypothyroidism and Hyperthyroidism

Checked by : \_\_\_\_\_  
Page 2 Contd...3

If test results are alarming or unexpected, patient is advised to contact the laboratory immediately for possible remedial action.

**Facilities Available**

- Multispeciality Hospital - 24 Hours Emergency - X-Ray/ ECG/ Ultrasound/ CT Scan - Dental- Fully Equipped Operation Theatre - Fully Functional Lab - 24/7 Casualty/ ICU-Nursery 24/7 Pharmacy - Labour Room - All Speciality OPD - Laproscopic Surgery - ECHO - Plastic Surgery





**LAB REPORT**

Reg. Date	09/03/2024	Patient Id	2403090016	DOB.	
Name	MRS. SUNITA TOMAR	Gender	F	Perm. ID	
Age	49 Yrs.	Panel	MEDIWHEEL	Reported	10/03/2024 12:25:33
Ref. By	MEDIWHEEL				

Test Name	Result	Units	Ref. Range
-----------	--------	-------	------------

- Monitor T4 replacement or T4 suppressive Therapy
- Quantify TSH levels in the subnormal range

Increased Levels : Primary Hypothyroidism Subclinical Hypothyroidism, TSH dependent, Thyroid Hormone Resistance.

Decreased Levels : Grave's Disease, Autonomous Thyroid Hormone Secretion, TSH Deficiency

**LIPID PROFILE**

TOTAL CHOLESTEROL	<b>200.60</b>	mg/dL	130.0 - 200.0 (<200)
TRIGLYCERIDES	149.40	mg/dL	80.5 - 150.0 (<150)
H D L CHOLESTEROL DIRECT	<b>41.75</b>	mg/dL	42.0 - 60.0 (<40->59)
V L D L	29.9	mg/dL	4.0 - 30. (23-45)
L D L CHOLESTEROL	129.0	mg/dL	50.0 - 150.0 (50-150)
TOTAL CHOLESTEROL / HDL RATIO	4.8		3.3 - 5.1
LDL / HDL CHOLESTEROL RATIO	3.1		1.5 - 3.5
SERUM URIC ACID	<b>6.02</b>	mg/dl	2.4 - 6.0
BLOOD UREA NITROGEN (BUN)	8.42	mg/dl	6.0 - 21.0
SERUM CREATININE	0.60	mg/dl	0.6 - 1.2
BUN/CREAT RATIO	14.03	mg/dl	

10 - 20

**LIVER FUNCTION TEST (LFT)**

BILIRUBIN TOTAL	1.12	mg/dl	0.2 - 1.2
CONJUGATED (D. BILIRUBIN)	0.24	mg/dl	0.00 - 0.3
UNCONJUGATED (I.D.BILIRUBIN)	0.88	mg/dl	0.2 - 0.9

Checked by : \_\_\_\_\_  
 Page 3 Contd...4

If test results are alarming or unexpected, patient is advised to contact the laboratory immediately for possible remedial action.

**Facilities Available**

- Multispeciality Hospital - 24 Hours Emergency - X-Ray/ ECG/ Ultrasound/ CT Scan - Dental- Fully Equipped Operation Theatre - Fully Functional Lab - 24/7 Casualty/ ICU-Nursery 24/7 Pharmacy - Labour Room - All Speciality OPD - Laproscopic Surgery - ECHO - Plastic Surgery





**LAB REPORT**

Reg. Date	09/03/2024	Patient Id	2403090016	DOB.	
Name	MRS. SUNITA TOMAR	Gender	F	Perm. ID	
Age	49 Yrs.	Panel	MEDIWHEEL	Reported	10/03/2024 12:25:33
Ref. By	MEDIWHEEL				

Test Name	Result	Units	Ref. Range
SGOT / AST	74.10	IU/L	0 - 35
SGPT / ALT	41.5	IU/L	0 - 35
ALKALINE PHOSPHATASE	108.70	U/L	64 - 306
TOTAL PROTEIN	8.70	gm/dl	6.0 - 8.3
ALBUMIN	4.61	gm/dl	3.2 - 5.0
GLOBULIN	4.09	gm/dl	2.5 - 5.6
A/G RATIO	1.13		0.9 - 2.0
GAMMA GT	24.90	IU/L	0.0 - 35.0

*Dr. Reema Dahiyaa*  
**DR. REEMA DAHIYA**  
 M.B.B.S, MD (Path.)  
 Checked by: \_\_\_\_\_  
 Malik Radix Healthcare Pvt. Ltd.  
 C-217, C-218, Nirman Vihar, Delhi-92

**DR. MEENU AGGARWAL**  
 M.B.B.S, MD (Path.)

If test results are alarming or unexpected, patient is advised to contact the laboratory immediately for possible remedial action.

**Facilities Available**

- Multispeciality Hospital - 24 Hours Emergency - X-Ray/ ECG/ Ultrasound/ CT Scan - Dental- Fully Equipped Operation Theatre
- Fully Functional Lab - 24/7 Casualty/ ICU-Nursery 24/7 Pharmacy - Labour Room - All Speciality OPD - Laproscopic Surgery - ECHO - Plastic Surgery



Patient Name : Mrs SUNEETA TOMAR  
 DOB/Age/Gender : 49 Y/Female  
 Patient ID / UHID : 7500947/OF7500947  
 Referred By : Dr.DR SELF  
 Sample Type : Whole blood EDTA  
 Barcode No : HY236942

Bill Date : Mar 09, 2024, 03:43 PM  
 Sample Collected : Mar 09, 2024, 03:43 PM  
 Sample Received : Mar 09, 2024, 06:48 PM  
 Report Date : Mar 09, 2024, 08:26 PM  
 Report Status : Final Report



Test Description Value(s) Unit(s) Reference Range

HEMATOLOGY REPORT

**HbA1C (Glycosylated Haemoglobin)**

Glycosylated Hemoglobin (HbA1c) 5.7 % <5.7  
 Method HPLC  
 Estimated Average Glucose 116.89

Interpretation:

Interpretation For HbA1c% As per American Diabetes Association (ADA)

Reference Group	HbA1c in %
Non diabetic adults >=18 years	<5.7
At risk (Prediabetes)	5.7 - 6.4
Diagnosing Diabetes	>= 6.5
Therapeutic goals for glycemic control	Age > 19 years Goal of therapy: < 7.0 Age < 19 years Goal of therapy: <7.5

Note:

- Since HbA1c reflects long term fluctuations in the blood glucose concentration, a diabetic patient who is recently under good control may still have a high concentration of HbA1c. Converse is true for a diabetic previously under good control but now poorly controlled.
- Target goals of < 7.0 % may be beneficial in patients with short duration of diabetes, long life expectancy and no significant cardiovascular disease. In patients with significant complications of diabetes, limited life expectancy or extensive co-morbid conditions, targeting a goal of < 7.0 % may not be appropriate

Comments :

HbA1c provides an index of average blood glucose levels over the past 8 - 12 weeks and is a much better indicator of long term glycemic control as compared to blood and urinary glucose determinations ADA criteria for correlation between HbA1c & Mean plasma glucose levels.

HbA1c(%)	Mean Plasma Glucose (mg/dL)	HbA1c(%)	Mean Plasma Glucose (mg/dL)
6	126	12	298
8	183	14	355
10	240	16	413

Sohini Sengupta

Dr. Sohini Sengupta  
 MD (Cl Biochemistry), DNB,  
 FNB (Lab Medicine)  
 Medical Laboratory Director  
 HOD (Biochemistry & Special Assays)

Booking Centre :- Malik Radix Healthcare (Delhi), C-218, Nirman Vihar, Vikas Marg  
 Processing Lab :- Redcliffe Lifetech Pvt.Ltd., H-15, Sector-63, Noida, Uttar Pradesh - 201301

All Lab results are subject to clinical interpretation by qualified medical professional and this report is not subject to use for any medico-legal purpose.

